

Thrombotic thrombocytopenic purpura with typical pentalogy in a child: a case report and literature review

Qian Wan (✉ 1029353139@qq.com)

Jiangxi provincial children's hospital

Yao Ye

Jiangxi provincial children's hospital

Xiaohong Zhong

Jiangxi provincial children's hospital

Zhongjin Xu

Jiangxi provincial children's hospital

Jian Li

Nanchang University Second Affiliated Hospital

Case report

Keywords: thrombotic thrombocytopenic purpura, acute TTP, thrombotic microangiopathy

Posted Date: October 28th, 2021

DOI: <https://doi.org/10.21203/rs.3.rs-1000584/v1>

License:   This work is licensed under a Creative Commons Attribution 4.0 International License.

[Read Full License](#)

Abstract

Thrombotic thrombocytopenic purpura (TTP) is a rare and life-threatening thrombotic microangiopathy with clinical quintuple symptoms, including fever, thrombocytopenia, microangiopathic hemolytic anemia, neurological symptoms, and renal insufficiency. TTP onset in children is rare, and the percentage of acute TTP with these five symptoms at the same time is <10%. In this study, we reported a typical case of TTP onset in a child with clinical quintuple symptoms.

Background

Thrombotic thrombocytopenic purpura (TTP) is a rare and life-threatening thrombotic microangiopathy characterized by hemolytic anemia, severe thrombocytopenia, and end-organ damage caused by microvascular platelet thrombosis [1, 2]. Currently, the annual incidence of TTP in the population is about 10/1 million, with an annual increase of about 1/1 million, and the ratio of male to female is about 1:2 [2, 3]. Strikingly, the TTP onset in children is rare, with an incidence rate of <1/1 million [4, 5]. Moreover, the onset of this disease is rapid and dangerous, and the fatality rate is up to 90% if not treated promptly. The classic clinical manifestations for this microangiopathy were defined as clinical quintuple symptoms, including fever, thrombocytopenia, microangiopathic hemolytic anemia, neurological symptoms, and renal insufficiency; however, the percentage of acute TTP with these five symptoms at the same time is <10% [1, 2]. Herein, we reported a typical case of children-onset TTP with clinical quintuple symptoms. The current study aimed to improve the understanding of TTP onset in children for clinicians and increase the diagnosis and treatment rate.

Case Presentation

In this study, a case of a 13-year-old Asian female patient was presented to the intensive care unit of Jiangxi Provincial Children's Hospital with the symptoms of fever, headache, and vomiting for 2 days and soy sauce-colored urine. About 1.5 months ago, this patient was admitted to the intensive care unit of our hospital due to fever with headache, vomiting, paleness, and poor spirit for 4 days but was discharged with a diagnosis of severe viral encephalitis, anemia, and thrombocytopenia. The patient presented an initial temperature of 36.4°C, a heart rate of 114 bpm, blood pressure of 120/91 mmHg, respiratory rate of 21 bpm, oxygen saturation of 95% in room air, and weight 35 kg. The patient also displayed bruises without trauma.

A complete blood count revealed severe thrombocytopenia (platelet (PLT): $4 \times 10^9/L$) and low hemoglobin (Hb:51 g/L). Bone marrow cytology showed proliferative anemia bone marrow image and thrombocytopenia. Blood testing revealed lactate dehydrogenase (LDH) 1538 U/L, aspartate transferase 393 U/L, total bilirubin 70 mmol/L, indirect bilirubin 32.58 mmol/L, negative direct antiglobulin test, and normal coagulation function. Urine examination revealed that urine occult blood was >3+, urine protein was 2+, and 24-h urine protein was 0.94 g/L. The renal function of the girl was normal. The complement C3 was 0.82 g/L, and the antinuclear antibodies (ANA) were positive, including anti-Ro52.

From day 1 of admission, methylprednisolone (400 mg/time for 1 day, 1 mg/kg, q12h for 2 days), gamma globulin, infusion of red blood cell suspension, and platelet therapy was implemented. However, the concentration of Hb and PLT did not increase as high as expected after the transfusion (before transfusion: Hb: 51 g/L, PLT: 4×10^9 /L; after infusion: Hb: 55 g/L, PLT: 11×10^9 /L). Hence, the patient was suspected of having systemic lupus erythematosus (SLE) because of the symptoms of fever, headache, thrombocytopenia, low C3, and elevated ANA titer. Therefore, the shock methylprednisolone therapy (1000 mg/time) was given for 2 days from day 4 of admission but no significant increase was noted in the concentration of Hb and PLT (Hb: 67 g/L, PLT: 5×10^9 /L). On day 5 of admission, the girl fell into a coma after the convulsion; hence, TTP was suspected, and therapeutic plasma exchange (TPE) was performed. The ADAMTS-13 enzyme activity was <5%, indicating a severe enzyme deficiency, which further confirmed the diagnosis of TTP. In the follow-up treatment, five TPE (fresh frozen plasma 2000 mL/time) was combined with steroid (intravenous infusion of methylprednisolone 1 mg/kg, q12h) on day 6 of admission. After plasma exchange, the PLT and Hb showed an upward trend, with the concentration of 88 g/L Hb and 277×10^9 /L PLT at the fifth plasma exchange. During the therapy, the total bilirubin, indirect bilirubin, and LDH decreased significantly (Figure 1). A hematological response with PLT $>150 \times 10^9$ /L for 2 days was observed with the fourth TPE treatment, and the child became conscious after the fifth TPE. After the girl was discharged, the oral steroid therapy was reduced gradually and stopped after 2 months when the Hb and PLT levels were normal.

Interestingly, a partial overlap was noted in the symptoms of SLE and TTP, and due to the lack of SLE-specific antibody results, this disease could not be diagnosed as SLE temporarily. The retests of ANA profile, complement, and urine protein would be essential.

Discussion

Clinical diagnosis of TTP in children is rare. Approximately 33% of children-onset TTP is misdiagnosed as hemolytic uremic syndrome (HUS), immune thrombocytopenic purpura (ITP), Ivan's syndrome, and hematological malignancy which lead to delayed treatment and affect the prognosis. The clinical manifestations of HUS are similar to those of TTP. However, the pathophysiology and treatment of the two diseases are different. The specific diagnostic index of TTP is ADAMTS-13 enzyme deficiency (<10%), while normal activity is observed in HUS. Thus, when TTP is suspected in a child, the enzyme activity of ADAMTS13 should be measured [6]. Conversely, the diagnosis of TTP should be considered during lack of response to specific immunotherapy in patients with organ damage and a decrease in blood routine or the diagnosed autoimmune cytopenia (such as HUS, ITP, and Ivan's syndrome). This phenomenon is consistent with the consideration of TTP diagnosis in our case of poor effect after hormone and gamma therapy. In summary, the case reported in this article has clinical quintuple symptoms of TTP, and the ADAMTS13 enzyme activity was <5%, which further confirmed the diagnosis. However, due to the difficult economic conditions of the child's family, the ADAMTS13 genetic test could not be completed. Also, the ADAMTS13 antibody test was not performed because the TPE was

conducted in the intensive care unit. In order to distinguish this type of TTP case, the ADAMTS-13 antibody and ADAMTS-13 genetic tests should be complemented during the follow-up.

Notably, the positive results of the ANA spectrum were related to SLE. Recently, a pediatric case of SLE complicated by TTP was reported [7]. The diagnosis of TTP patients with SLE is difficult because of the overlap of symptoms, such as fever, blood system damage, and nervous system damage of the two diseases. In addition, the proportion of immune-mediated TTP (iTTP) patients with positive antinuclear antibodies was up to 71%, while the incidence of secondary SLE with primary iTTP was 7.1–11.1% [8–10]. The SLE patients with TTP also have moderate to severe lupus disease [1] and a high mortality rate of 34–62.5% [11, 12]. The symptoms of microangiopathic hemolytic anemia (MAHA) in TTP and autoimmune hemolytic anemia (AIHA) in SLE are partially overlapped, but the difference between the two anemias could be distinguished by blood smears and Coombs test. In blood smears, the fragmentation of peripheral red blood cells is the feature for MAHA, while AIHA is characterized by autoantibodies against red blood cells. Moreover, the positive result of the Coombs test is observed in AIHA and the negative result for MAHA [13]. In this study, the negative result of the Coombs test did not support the MAHA of SLE. Supposedly, the results of the peripheral red blood cell smear were not traced at the time of admission. According to the SLE diagnostic criteria announced in 2019 [14], the diagnosis of SLE could not be confirmed in the short term because the symptoms of the child, including lack of specific antibody, slightly reduced complement C3, and the damage of the nervous and renal system, overlapped with those of TTP. Therefore, follow-up is imperative.

Furthermore, TPE therapy is the preferred treatment method for the removal of ADAMTS-13 antibodies and Ultralage vWF (ULvWF) multimers and should be conducted immediately when the TTP diagnosis is established [15]. The TPE should be maintained to guarantee the normal PLT count ($\geq 150 \times 10^9/L$) of the patient for 2 days and a normal concentration of LDH [5, 16]. Herein, the child was treated with TPE after the disease was considered as TTP on day 6 of admission. On day 9, a normal PLT level was detected, which lasted for 2 days. Moreover, the LDH of the patient was normal, and the symptoms were improved on day 10 of admission. These findings were consistent with the above treatment program. Furthermore, another therapeutic drug used in this case was steroids, which exerted immunosuppressive effects by reducing the tissue inflammation caused by microvascular thrombus and improved the success rate of the treatment [17].

As a monoclonal CD20 antibody targeting B cells, rituximab is mainly used for the treatment of patients with poor response to TPE and relapsed TTP. A meta-analysis showed that the recurrence and mortality rate of the acute secondary TTP patients were reduced by rituximab [18]. According to the clinical guidelines, the standard dose of rituximab was 375 mg/m^2 for a week for four doses. In addition, a small prospective trial [19] and retrospective studies [20] reported the curative effects of the low dose of rituximab (100–200 mg/time), but this treatment method was not widely accepted by clinical guidelines. In order to improve the therapeutic effects, many new drugs, including bortezomib, caplacizumab, recombinant ADAMTS13, and N-acetylcysteine, targeting new therapeutic candidates were developed and tested in several clinical trials.

In conclusion, we reported a case of TTP with clinical quintuple symptoms in a child. With further understanding of the pathogenesis of TTP and the improvement in the clinical trials of new drugs, highly effective treatments for TTP are expected in the future, especially for refractory patients.

Abbreviations

TTP

Thrombotic thrombocytopenic purpura

PLT

platelet

Hb

hemoglobin

LDH

lactate dehydrogenase

ANA

antinuclear antibodies

SLE

systemic lupus erythematosus

TPE

therapeutic plasma exchange

HUS

hemolytic uremic syndrome

ITP

immune thrombocytopenic purpura

iTTP

immune-mediated TTP

MAHA

microangiopathic hemolytic anemia

AIHA

autoimmune hemolytic anemia

ULvWF

Ultralage vWF.

Declarations

Consent

Informed consent was obtained from the father of the patient and the patient for publication of this case report.

Acknowledgements

The authors thank the department of Hematology of the The Affiliated Children's Hospital of Nanchang University for providing help in the diagnosis and management of the patient described in the case report

Author details

a Department of Hematology, The Second Affiliated Hospital of Nanchang University, (Minde Road 1), Jiangxi (330006), China,

²Department of Hematology, Jiangxi Provincial Children's Hospital, Nanchang, China

¹The Affiliated Children's Hospital of Nanchang University, Nanchang, China

²Department of Hematology, Jiangxi Provincial Children's Hospital, Nanchang, China

b Department of Hematology, The Affiliated Children's Hospital of Nanchang University, (1666 Diezihu Avenue, Honggutan New Area), Jiangxi 330199, China;

⁺These authors contributed equally to this work.

^{*}Correspondence to: Prof. Jian Li. E-mail: thj127900@163.com

Authors' contributions

QW and YY wrote the initial draft. JL revised the manuscript. XHZ and ZJX collected cases and statistics. QW and JL read and approved the final manuscript.

Competing interests

The authors declare that they have no competing interest.

Funding

This study was financially supported by the National Natural Science Foundation of China (81260231).

References

1. Joly BS, Coppo P, Veyradier A: **Pediatric thrombotic thrombocytopenic purpura.** *Eur J Haematol* 2018;**1(4)**:425–34.
2. Mariotte E, Azoulay E, Galicier L, et al: **Epidemiology and pathophysiology of adulthood-onset thrombotic microangiopathy with severe ADAMTS13 deficiency (thrombotic thrombocytopenic purpura): a cross-sectional analysis of the French national registry for thrombotic microangiopathy.** *Lancet Haematol* 2016;**3(5)**: e237-e245.

3. George JN, Al-Nouri ZL: **Diagnostic and therapeutic challenges in the thrombotic thrombocytopenic purpura and hemolytic uremic syndromes.** *Hematology* 2012; **2012**:604-609.
4. George JN, Nester CM: **Syndromes of thrombotic microangiopathy.** *N Engl J Med* 2014; **371**:654-666.
5. Joly BS, Stepanian A, Leblanc T, et al: **Child-onset and adolescent-onset acquired thrombotic thrombocytopenic purpura with severe ADAMTS13 deficiency: a cohort study of the French national registry for thrombotic microangiopathy.** *Lancet Haematol* 2016;**3**: e537-e546.
6. Sukumar S, Lmmle B, Cataland SR: **Thrombotic Thrombocytopenic Purpura: Pathophysiology, Diagnosis, and Management.** *J Clin Med* 2021; **10**:536.
7. Ran H, Fang D: **Systemic lupus erythematosus with thrombotic thrombocytopenic purpura: a case report.** *J Clin pediatr* 2020;**38(4)**:285-288.
8. George JN: **How I treat patients with thrombotic thrombocytopenic purpura:2010.** *Blood* 2010;**116(20)**:4060–4069.
9. Coppo P, Bengoufa D, Veyradier A, et al: **Severe ADAMTS13 deficiency in adult idiopathic thrombotic microangiopathies defines a subset of patients characterized by various autoimmune manifestations, lower platelet count, and mild renal involvement.** *Medicine* 2004;**83(4)**:233–244.
10. Roriz M, Landais M, Desprez J, et al: **Risk factors for autoimmune diseases development after thrombotic thrombocytopenic Purpura.** *Medicine* 2015;**94(42)**: e1598.
11. Musio F, Bohlen EM, Yuan CM, Welch PG: **Review of thrombotic thrombocytopenic purpura in the setting of systemic lupus erythematosus.** *Semin arthritis rheum* 1998;**28(1)**:1-19.
12. Letchumanan P, Ng HJ, Lee LH, Thumboo J: **A comparison of thrombotic thrombocytopenic purpura in an inception cohort of patients with and without systemic lupus erythematosus.** *Rheumatology (Oxford)* 2009;**48(4)**:399–403.
13. Li J, Jiang J-J, Wang C-Y, et al: **Clinical features and prognosis of patients with thrombotic thrombocytopenic purpura associated with systemic lupus erythematosus: a review of 25 cases.** *Ital J Pediatr* 2019; **45**:55.
14. Aring M, Costenbader K, Daikh D, et al: **2019 European League Against Rheumatism/American College of Rheumatology classification criteria for systemic lupus erythematosus.** *Ann Rheum Dis* 2019;**71(9)**:1400-1412.
15. Han Y, Qi J-Q: **Progress in diagnosis and treatment of thrombotic thrombocytopenic purpura.** *J Clin Heamatol* 2021;**34(1)**:5–8.

16. Rock GA, Shumak KH, Buskard NA, et al: **Comparison of plasma exchange with plasma infusion in the treatment of thrombotic thrombocytopenic purpura.** Canadian Apheresis Study Group. *N Engl J Med* 1991;**325(6)**:393-397.
17. Balduini CL, Gugliotta L, Luppi M, et al: **High versus standard dose methylprednisolone in the acute phase of idiopathic thrombotic thrombocytopenic purpura: a randomized study.** *Ann Hematol* 2010;**89(6)**:591-596.
- 18 Owattanapanich, W, Wongprasert, C, Rotchanapanya, W, et al: **Comparison of the Long-Term Remission of Rituximab and Conventional Treatment for Acquired Thrombotic Thrombocytopenic Purpura: A Systematic Review and Meta-Analysis.** *Clin Appl Thromb Hemost* 2019;**25**: 1076029618825309.
19. Zwicker, J.I, Muia, J, Dolatshahi, L et al: **Adjuvant low-dose rituximab and plasma exchange for acquired TTP.** *Blood* 2019; **134**:1106–1109.
20. Reddy, M.S, Hofmann, S, Shen, Y.M, et al: **Comparison of low fixed dose versus standard-dose rituximab to treat thrombotic thrombocytopenic purpura in the acute phase and preemptively during remission.** *Transfus Apher Sci* 2020;**59(6)**:102885.

Figures

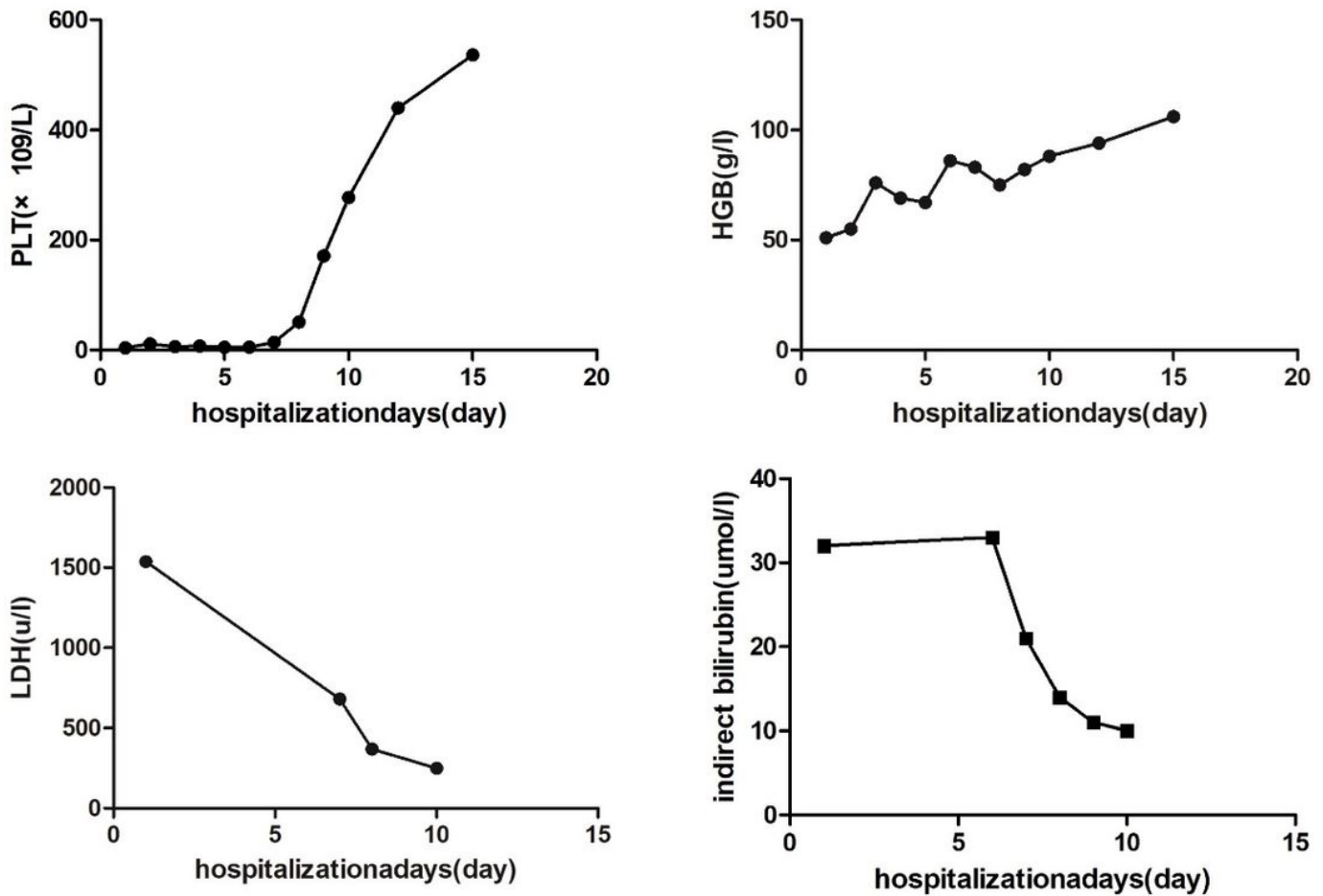


Figure 1

Trend of PLT, Hemoglobin, LDH level, and bilirubin level related to therapeutic management. The concentration of hemoglobin and PLT did not increase as expected after the transfusion on day 1 of admission (before transfusion: Hb: 51 g/L, PLT: $4 \times 10^9/L$; after infusion: Hb: 55 g/L, PLT: $11 \times 10^9/L$). The shock methylprednisolone therapy (1 g/time) was administered for 2 days from day 4 of admission, while no significant increase was observed in the concentration of hemoglobin and PLT (Hb: 67 g/L, PLT: $5 \times 10^9/L$). On day 5 of admission, five times of TPE was combined with a steroid. After three TPE treatments, the PLT and hemoglobin showed a rising trend, with 88 g/L Hb and $277 \times 10^9/L$ PLT at the fifth TPE, while LDH and bilirubin showed a significant downward trend after the start of TPE treatment. (PLT: platelet; HGB: hemoglobin; LDH, lactate dehydrogenase; TPE, therapeutic plasma exchange).