Clinical Report of Six-Month Follow-Up After Cementing PEEK Crown On Molars

Hitomi Kimura
Hiroshima University Graduate School of Biomedical & Health Sciences

Koji Morita (moritak@hiroshima-u.ac.jp)
Hiroshima University Graduate School of Biomedical & Health Sciences

Fumiko Nishio
Hiroshima University Graduate School of Biomedical & Health Sciences

Hiroshi Abekura
Hiroshima University Graduate School of Biomedical & Health Sciences

Kazuhiro Tsuga
Hiroshima University Graduate School of Biomedical & Health Sciences

---

Research Article

Keywords: PEEK, clinical research, crown, masticatory ability, clinical evaluation

Posted Date: November 3rd, 2021

DOI: https://doi.org/10.21203/rs.3.rs-1007047/v1

Abstract

To investigate the therapeutic effect of polyetheretherketone (PEEK) crowns, a six-month clinical study on CAD/CAM-fabricated molar PEEK crowns was conducted. Twenty-three cases of PEEK crowns placed on the molars of 20 subjects (7 males and 13 females, mean age: 60.6 ± 14.4 years) were included in the study. The evaluation items were the condition of the crowns at the time of cementation and after six months, patient satisfaction, masticatory ability, and occlusal force. A Wilcoxon signed-rank test with a significance level of 5% was used to examine the difference in masticatory ability with and without PEEK crowns. The occlusion, margin fit, and contact of all 23 cases at the time of cementing was good. Six months after cementation, there was no crown desorption, no fracture or crack, and no prosthodontics was needed in the 22 cases where one patient dropped out. No wear of the dental antagonist was observed. Patient satisfaction was generally high. There was no significant difference in masticatory ability between the groups with and without PEEK crowns. The subject's occlusal force was within normal range. PEEK crowns on molars are highly therapeutic methods and can be fully used as a crown prosthetic material to replace metal.

Introduction

There has been an increasing demand for metal substitutes for crown prosthetic materials towing to esthetics, metal allergies, and price surge of precious metals in the recent years [1]. In addition, as the cost of precious metals for dental use is skyrocketing, there is an urgent need to introduce materials with fewer price fluctuations. Hybrid resin and zirconia are often used as non-metal crown prosthetic materials, but the former is prone to fracture, and delamination [2], and the latter is prone to damage by the antagonistic portion of the tooth owing to its extreme hardness [3, 4].

Therefore, we focused on polyetheretherketone (PEEK), a high-performance plastic material with excellent mechanical strength, wear resistance, heat resistance, water absorption resistance, chemical resistance, biosafety, and processability as an adaptable dental material. As a thermoplastic resin, PEEK is used in automobile and aircraft parts that require durability. PEEK has been applied to spinal implants in clinical medicine, and its biological safety has been confirmed [5]. However, since PEEK has a gray color tone and low bond strength with cement, PEEK has been used infrequently as a crown material [6]. To solve the above problems, changing the color of PEEK to milky white by adding 20% titanium dioxide, which exerts very low risk of metal allergy, and increasing the bond strength by various surface treatments such as high-concentration sulfuric acid treatment, sandblasting, or laser grooving were possible [7–9]. Furthermore, the use of primers and selection of types of cement have also been studied, and clinically applicable bond strengths have been achieved by using appropriate surface treatments, primers, and types of cement [9]. Therefore, we applied to the Hiroshima University Clinical Research Review Committee for a clinical study of PEEK crowns for molar teeth fabricated with a CAD/CAM system (Clinical assessment of PEEK crown for molar teeth: jRCTs062180040), after which a clinical study was conducted at the Hiroshima University Hospital. In this study, we report the clinical evaluation of 23 PEEK crowns for molar teeth at six-months follow-up after cementation.

Materials And Methods

This study was approved by the Hiroshima University Clinical Research Ethics Review Committee (jRCTs062180040, Clinical evaluation of PEEK crowns for molars). This clinical study was a prospective cohort with a six-month follow-up conducted at the Hiroshima University Hospital Dentistry from March 29, 2018, to October 2020. The subjects of this study were 23 cases of PEEK crowns for molar teeth in 20 patients (7 males and 13 females, mean age 60.6±14.4 years (23-82 years)) who required prosthetic treatment with a single crown in the molars after treatment for dental caries or apical periodontitis. All patients provided written and verbal informed consent for prosthetic treatment with PEEK crowns.

Inclusion and exclusion criteria

Inclusion criteria were as follows: 1. Age: > 20 years 2. Dental antagonists to test teeth for the single crown of the upper and lower molars (two consecutive single crowns are also possible). Abutment teeth height can be secured on the buccal and lingual sides of approximately 3 mm after preparation. The exclusion criteria were as follows: (i) abutment tooth for removable partial dentures (ii). Severe periodontal disease (pocket of 6 mm or more, bone resorption/attachment loss of root length 1/2 or more, and root bifurcation lesion of level 2 or more). Patients are deemed inappropriate by the responsible person or coordinator.

Materials

The PEEK material used in this study was Vestakeep DC4450 PEEK (tooth-colored / polyetheretherketone, titanium dioxide pigments) (Daical-Evonik Ltd., Tokyo). The following primers were used: Visio.link (Bredent, Chesterfield), V-primer (Sun Medical, Moriyama), Superbond PZ primer (Sun Medical, Moriyama), Scotchbond ™ Universal Adhesive (3M ESPE, Neuss), Super-Bond ™ Universal Adhesive (3M ESPE, Neuss), and Super-Bond C&B (Sun Medical, Moriyama), and RelyX Ultimate Resin Cement (3M ESPE, Neuss).

Surgical protocol

After taking preliminary impressions and preoperative examinations to check the antagonism of the teeth, metal core or resin core abutments were fabricated as needed. Thereafter, the abutment teeth were formed according to the usual method, and impression taking using a custom tray and silicone impression material was performed. A computer-aided design/computer-aided manufacturing (CAD/CAM) system was used to fabricate PEEK crowns (Figs. 1 and 2). The CAD/CAM system consisted of a scanner (S600 ARTI SCANNER, Zirkonzahn Products, South Tyrol), milling machine (DWX-52D, SHOFU INC., Kyoto), and CAM software (WORKNC DENTAL, Vero Software KK, Tokyo). After trial fitting, the adjacent and occlusal surfaces were adjusted and polished using a large silicon point (SHOFU, Kyoto). The inner surface of the PEEK crown was sandblasted with alumina particles at a spray distance of 10 mm, air pressure of 0.1 MPa, and spray time of 10 s. Then, Visio.link® was applied, dried with air, and irradiated with light for 90 s. Meanwhile, the surfaces of the abutment teeth were treated with the recommended primer for cementation. Two types of adhesive resin cement, MMA-based Super-Bond C&B,

and composite-based RelyX Ultimate Resin Cement, which are known to have promising adhesive strength with PEEK, were used in a total of 23 cases (super-Bond C&B: 11 cases, RelyX Ultimate Resin Cement: 12 cases) [9]. In the case of Super-Bond C&B, V-primer was applied to the metal core, and Super-Bond PZ primer was applied to the resin core and dried. In the case of RelyX Ultimate Resin Cement, Scotchbond Universal Adhesive was applied to the metal and resin cores, dried, and then exposed to light for 20 s for bonding.

Evaluation items and methods

The 23 cases of PEEK crowns were evaluated at the time of cementation and after six months of placement. The evaluation items included the following: height of the abutment teeth and clearance to the opposite tooth before placement; occlusion at the time of cementation; margin fit and contact surface condition; occlusal contact condition at the time of cementation and after six months (cracking, fracture, dehiscence, pain, secondary caries, occlusal surface condition, surface texture, discoloration and staining, plaque adhesion, occlusal surface condition of the dental antagonist, discoloration and staining, plaque adhesion, occlusal surface condition of the opposite tooth, adjacent surface contact condition, and crown condition for the need for retreatment), and patient satisfaction. In addition, masticatory ability, occlusal force, and occlusal pressure were measured as oral functions.

Evaluation of the abutment morphology, crown, and oral cavity

The height of the abutment teeth and the distance from the finish line to the functional cusp was measured at the four central points of the buccal, lingual, proximal, and centrifugal region of the working model using digital calipers (Mitutoyo, Kawasaki). The clearance between the abutment and the opposing tooth was measured from the functional occlusal of the abutment to the central fossa of the opposing tooth of the working model using a clearance gauge (CeraSmart Clearance Gauge, GC, Tokyo). The contact between the adjacent teeth and the crown was determined using a contact gauge (GC, Tokyo, Japan). The occlusal contact status at the time of cementation and after six months was judged by one dentist using an articulating paper, and point contact at the functional occiput was judged as "excellent," surface contact as "good," and no contact as "poor." Adjacent surface contact during cement bonding was determined using a 50 μm contact gauge. Margin conformation at the time of cementation, cracks, fractures, plaque adherence, dehiscence, secondary caries, surface properties, occlusal surface condition of the opposing teeth, discoloration and staining, and the need for retreatment six months after cementation was determined by visual examination by one dentist. Patient satisfaction and pain were assessed by asking the patients. Intraoral photographs and X-rays were taken if necessary to check the condition of the PEEK crowns and abutment teeth.

Evaluation of oral function

After cementing, the oral function was quantified by occlusal force and masticatory ability test in a month or three months. Occlusal force testing was performed using a film for measuring occlusal force (Dental Prescale II, GC) and bite force analysis software (Bite Force Analyzer, GC, Tokyo) to measure

occlusal pressure and occlusal force. For the measurement, a pressure-sensitive film was prepared on the oral cavity while the occlusal surface of the subject was kept horizontal, and the subject was asked to bite down with the maximum bite force for 3 s. Then, the occlusal pressure and occlusal force were calculated by analyzing the color change of the film by pressure using analysis software [10]. To test masticatory ability, gummy jelly with standardized ingredients, shape, and glucosensors were used. Immediately after the subject chewed gummy jelly for 20 seconds, 10 ml of water was placed in the mouth, and all the liquid in the mouth, including gummy jelly, was spat out onto the filtration mesh. The masticatory ability was calculated by measuring the glucose concentration from the spit-out liquid [11]. Measurements were performed three times: right-side chewing, left-side chewing, and free chewing. The standard value was set at 150 mg/dL or higher [12], which is within the healthy range for edentulous individuals.

Statistical analysis

A Wilcoxon signed-rank test with a significance level of 5% was used to examine the difference in masticatory ability between the sites with and without PEEK crowns in 20 subjects, excluding the three subjects with bilateral PEEK crowns.

Results

Subjects

One subject of the 20 subjects was lost to follow-up at six months; thus, no data were available for that subject after six months. Therefore, the total number of subjects in this study was 19, and the total number of cases installed was 22.

Surgical protocol

Eleven cases (case numbers: 6, 12-22) had six full metal crowns, one temporary crown, two ceramic crowns, one hard resin tooth, and one natural tooth. The mean age of the subjects in the 11 cases with Super-Bond C&B cement (case numbers: 1-5, 7-11, and 20) was 60.5 years, and the target teeth were four maxillary 6, two maxillary 7, one mandibular 6, three mandibular 7, and one mandibular 8. Meanwhile, the mean age of the subjects in the 12 cases using RelyX Ultimate Resin Cement was 58.9 years, and the target teeth were six maxillary 6, three maxillary 7, one mandibular 6, and two mandibular 7. In addition, the opposite teeth for the target teeth were one PEEK crown, two zirconia crowns, one full-metal crown, three partially covered metal crowns, two ceramic-fired cast crowns, and three natural teeth (Tables 1).

Table 1
Patient Data

SB				
No.	Sex	Age	FDI	Pairing tooth
1	Male	67	16	Full metal crown
2	Female	51	26	Full metal crown
3	Female	70	17	Full metal crown
4	Female	47	46	Full metal crown
5	Female	41	47	Temporary crown
7	Female	78	17	Ceramic
8	Male	79	47	Hard resin teeth (Removable denture)
9	Male	79	48	Full metal crown
10	Female	67	16	Ceramic (Implant)
11	Male	82	16	Full metal crown
23	Male	23	47	Normal tooth
RU				
No.	Sex	Age	FDI	Pairing tooth
6	Female	41	17	PEEK crown
12	Male	64	16	Zirconia crown
13	Female	53	46	Full metal crown
14	Female	46	16	Metal inlay
15	Male	65	26	Zirconia crown
16	Male	58	37	Normal tooth
17	Female	67	26	Metal ceramic crown
18	Female	67	27	Metal ceramic crown
19	Female	63	27	Metal inlay
20	Female	50	47	Normal tooth
21	Female	76	16	Normal tooth
22	Female	64	16	Metal inlay

Evaluation items and methods

The measured height of the abutment teeth ranged from approximately 1.2 mm at the lowest site to approximately 7 mm at the highest site, and the clearance was 1.0 to 2.0 mm (Table 2). The color tone was milky white, as shown in one example of a PEEK crown on a maxillary right second molar (Fig. 3). The radiographs taken six months after placement showed that the PEEK crown was slightly opaque, and the outline of the crown was visible (Fig. 4). 22 of the 23 PEEK crowns in the 20 patients showed good fit and contact. The margins of 21 cases were also in good condition, and no problems were found in the remaining cases (Table 3). The status of the PEEK crowns, abutment teeth, and dental antagonist six months after the placement is shown in Table 4. One of the subjects could not be followed up after six months of follow-up, but the remaining 19 subjects (22 cases) showed no dehiscence, fractures, or cracks after six months of placement, and no cases required retreatment. There were slight bite marks in 2 cases, slight surface roughness in 6 cases, slight staining in 7 cases, and mild gingivitis in 5 cases. The results of the satisfaction questionnaire are shown in Table 5. There was four comments each about chewing gum adhesion, but subjects' satisfaction was generally high regarding recovery of the main complaint, mastication, and esthetics.

Table 2. Abutment tooth data

SB	No.	Abutment tooth height(mm)				Clearance (mm)
		B□Buccal side	L□Lingual side	M□Mesial side	D□distal side	
	1	B□7.47	L□5.15	M□3.00	D□5.80	2.0≦
	2	B□3.34	L□4.19	M□2.19	D□2.47	1.5 - 2.0
	3	B□6.36	L□4.61	M□4.25	D□3.76	1.5 - 2.0
	4	B□3.67	L□3.12	M□1.23	D□1.48	1.5 - 2.0
	5	B□4.27	L□2.99	M□2.32	D□2.65	1.5 - 2.0
	7	B□3.85	L□3.93	M□4.16	D□3.17	1.0 - 1.5
	8	B□5.59	L□4.16	M□3.86	D□5.44	2.0≦
	9	B□4.36	L□3.86	M□5.12	D□2.36	1.5 - 2.0
	10	B□4.37	L□4.75	M□2.67	D□2.30	2.0≦
	11	B□6.19	L□4.78	M□4.73	D□5.01	1.5 - 2.0
	23	B□5.01	L□3.06	M□2.02	D□4.40	1.5 - 2.0

RU	No.	Abutment tooth height(mm)				Clearance
		B□Buccal side	L□Lingual side	M□Mesial side	D□distal side	
	6	B□5.91	L□3.90	M□3.31	D□2.72	1.0 - 1.5
	12	B□6.13	L□4.02	M□3.25	D□4.82	2.0≦
	13	B□2.55	L□3.11	M□1.86	D□2.22	1.0 - 1.5
	14	B□6.27	L□5.07	M□2.80	D□2.93	2.0≦
	15	B□7.18	L□5.39	M□6.40	D□4.86	2.0≦
	16	B□3.62	L□2.37	M□2.11	D□1.22	2.0≦
	17	B□5.41	L□5.92	M□3.14	D□3.86	2.0≦
	18	B□5.72	L□3.47	M□3.11	D□3.66	2.0≦
	19	B□3.30	L□4.17	M□3.26	D□1.64	2.0≦
	20	B□3.83	L□2.92	M□2.44	D□1.40	1.0 - 1.5
	21	B□5.12	L□3.55	M□2.63	D□2.69	1.0 - 1.5
	22	B□6.20	L□3.53	M□1.60	D□3.28	1.0 - 1.5

Table 3
At the time of cementing

Evaluation items	Score		
	Excellent	Good	Poor
Occlusion*	22	1	0
Margin fit**	21	2	0
Contact***	22	1	0
* Excellent: ideal occlusal condition, Good: needs slight adjustment but generally good, Poor: needs extensive adjustment or too large			
* Excellent: almost no pore space, Good: pore space is palpable, but there is little clinical problem, Poor: pore space is too large			
*** Excellent: ideal contact condition, Good: contact position, form and strength are generally good, Poor: no contact or apparently inappropriate contact			

Table 4. Six-months after installation

Evaluation items	Score			
	A	B	C	
Crack	22	0	-	A□None B□Occurred
Broken	22	0	-	A□None B□Occurred
Desorption	22	0	-	A□None B□Occurred
Occlusal contact	20	2	0	A□No problem B□Good C□Loss
Pain	22	0	-	A□No pain B□Pain
Caries	22	0	-	A□None B□Occurred
Occlusal surface	20	2	0	A□No problem B□Small attrition C□Large attrition
Surface texture	16	6	0	A□No problem B□Slight roughening C□Crater formation
Discoloration / Stain	15	7	0	A□None B□A little C□Conspicuous
Plaque	22	0	-	A□Equivalent B□Conspicuous
Marginal gingiva	17	5	-	A□None B□Mild inflammation
Occlusal surface of pairing tooth	22	0	0	A□No problem B□Small attrition C□Large attrition
Contact	22	0	-	A□None B□Food impaction
Retreatment	22	0	-	A□None B□Occurred

Table 5
Patient satisfaction

Evaluation items	Score		
	Excellent	Good	Poor
Improvement of chief complaint	21	1	0
Chewing	21	1	0
Aesthetic	13	9	0
Other	"Gum sticks" "I'm worried about stain" (Male 1, Female:3)		

Evaluation of oral function

The results of the masticatory ability test using gummy bears are shown in Figs. 5 and 6. The mean values of the 23 cases were 245.2 mg/dl for free mastication, 254.2 mg/dl for right-side mastication, and 236.0 mg/dl for left-side mastication. There was no statistically significant difference in masticatory ability between sites with and without PEEK crowns (p=0.093) (Fig. 7). The results of the occlusal force measurement are shown in Figures 8 and 9. The mean pressure and occlusal force of the 23 subjects were 33 MPa and 794.5 N, respectively.

Discussion

The inclusion criteria for this clinical study were: age 20 years or older, single crown, presence of opposing teeth, and buccal and lingual height of 3 mm. The age of 20 years or older was defined as the age of adulthood in Japan and the establishment of an occlusal relationship: the single crown was used to confirm the wearing condition of a single tooth, the presence of opposing teeth was to restore occlusion and masticatory ability through occlusal contact, and a 3 mm height diameter was used to prevent fracture. Meanwhile, the exclusion criteria were planned abutment teeth for partial dentures and teeth with severe periodontal disease that may have a poor prognosis, considering the occurrence of breakage or dehiscence.

From the results in Table 5, in the evaluation 6 months after implantation, the occlusal contact score B was 2 (male: 1, female: 1), occlusal surface score B was 2 (male: 2, female: 0), surface roughness score B was 6 (male: 3, female: 3), staining score B was 7 (male: 2, female: 5), and gingivitis score B was 5 (male: 2, female: 3). The results of surface roughness, staining, and gingivitis were poor. This indicates that the poor polishing method of the PEEK crowns may have produced these results, and there is room for improvement. However, other than the items mentioned above, there were no problems with crack, broken, desorption, pain, caries, plaque, the occlusal surface of pairing teeth, contact, and retreatment, and good results were obtained. As shown in Table 5, chewing gum adherence (male: 1, female: 3) was attributed to personal lifestyle. Conversely, in the Good 9 cases, the proportion of females (male: 1, female: 8) was high. The color tone was milky white, and the esthetic quality was much better than that of metal crowns.

However, according to the subjects' satisfaction questionnaire results, although the color tone was white, it was far from the color tone of natural teeth. It was likely to be identified as an obvious artificial product. The PEEK crowns did not delaminate, fracture, or crack, but there was some occlusion, coloration, and surface roughness. The good processability of PEEK may have caused this; on the contrary, it may have been related to the softness of the material.

In this clinical study, sandblasting treatment, which is widely used in clinical dentistry, was used as a pretreatment for bonding PEEK crowns, a primer, and two types of luting cement material, which have been reported to improve bond strength [13]. Reportedly, sandblasting on the inner surface of PEEK improves bond strength [7, 8, 14, 15]. Visio.link®, V-Primer, Superbond PZ Primer, and Scotchbond™ Universal Adhesive were used as primers. This study used these materials as they are commonly used in adhesive resin types of cement or as the optimal priming process published in the literature. Two types of typical adhesive resin types of cement, composite and MMA, mainly used in clinical practice, were used. In six months, no crown dehiscence was observed with either RelyX Ultimate Resin Cement, a composite cement, or Super-Bond C&B cement, an MMA cement. This suggests that the use of adhesive resin may prevent PEEK crowns from delaminating.

In the masticatory ability test, most of the measured values of free mastication, right-sided mastication, and left-sided mastication in 20 subjects with 23 cases reached the glucose concentration that is within the healthy range for edentulous people, and it was found that the PEEK crowns provided sufficient masticatory strength. Twenty-three cases had glucose concentrations of 150 mg/dl or higher [12], within the healthy range for edentulous subjects. Furthermore, there was no significant difference in masticatory ability between the same subject with and without PEEK crowns, indicating that PEEK crowns may not reduce masticatory ability. In addition, the average value of occlusal force was 794.5 N, which was higher than the standard value of 500 N for declining occlusal force. The mean pressure of the case was not significantly lower than 500 N. Six cases were below the standard value of 500 N for occlusal force reduction. Therefore, it can be predicted that the subject has an occlusal force within the normal range. Therefore, PEEK crowns can withstand occlusal forces.

Regardless of the height of the abutment teeth, no dropouts, fractures, or cracks were observed even after 6 months of placement. However, this result may be limited to only this study because of the subjects' differences in occlusal forces. In some cases, slight wear, staining, roughness, or gingivitis were observed on the surface of the PEEK crowns. This suggests that wear and occlusion may have occurred. However, no study to date has reported a relationship between PEEK and gingivitis. PEEK has been reported to prevent bacterial adhesion [16]. These results suggest that PEEK crowns are suitable for continuous patient wear.

The limitations of this study are as follows: First, the number of cases in this study was small, and only a limited statistical analysis was performed. Therefore, it is necessary to increase the number of cases for adequate statistical analysis and conduct long-term clinical evaluations. Second, establishing a chairside polishing method for PEEK crowns is essential for the clinical application of PEEK crowns, but it has not

yet been established. However, this requires further research. Third, although the masticatory ability and bite force tests are effective indicators for the entire oral cavity, we could not test the area where the PEEK crown was placed. Future studies should examine the site at which the PEEK crown is attached.

Conclusion

Based on our limited research results, PEEK crowns fabricated using the CAD/CAM system did not fall off, fracture, or had any significant adverse effect on the marginal gingiva or reduced the ability to masticate at 6 months after placement, indicating that PEEK is a promising alternative to metal crowns for molars.

Declarations

Acknowledgments

All authors would like to thank Dr. Tsuka H, Dr. Kagawa K, Dr. Yokoi M, Dr. Higa C, Dr. Kuroki A, and Dr. Asahara E for their cooperation in selecting and treating the subjects in this study, K-S Dental Laboratory, Shofu Company, Daicel Evonik Company, and Ulti-Medical Company for providing the materials.

Author contributions

H.K., K.M., F. N., and H.A. provided conception and design. H.K., K.M., F. N., and H.A. performed experiments. H.K., K.M., F. N., and H.A. wrote the main manuscript. H.K. and K.M. prepared figures and tables. K.M., H.A., and K. T. planned research. All authors reviewed the manuscript.

Compliance with Ethical Standards

Conflict of Interest: All authors declare that they have no conflicts of interest regarding the contents of this article.

Funding

This research was performed without any special funding.

Ethical approval

All procedures performed in this study involving human participants were in accordance with the ethical standards of Hiroshima University Clinical Research Ethics Review Committee (jRCTs062180040, Clinical evaluation of PEEK crowns for molars) and with the 1964 Helsinki declaration and its later amendments or comparable ethical standards.

Informed consent

Informed consent was obtained from all individual participants included in this study.

References

1. Najeeb S, Zafar MS, Khurshid Z, Siddiqui F (2016) Applications of polyetheretherketone (PEEK) in oral implantology and prosthodontics. J Prosthodont Res 60:12–19. DOI: 10.1016/j.jpor.2015.10.001

2. Shinya A, Miura S, Koizumi H, Hikita K, Mine A (2017) Current status and future prospect of CAD/CAM composite crown. Ann Jpn Prosthodont Soc 9:1–15. DOI: 10.2186/ajps.9.1

3. Kim MJ, Oh SH, Kim JH, Ju SW, Seo DG, Jun SH, Ahn JS, Ryu JJ (2012) Wear evaluation of the human enamel opposing different Y-TZP dental ceramics and other porcelains. J Dent 40:979–988. DOI: 10.1016/j.jdent.2012.08.004

4. Pathan MS, Kheur MG, Patankar AH, Kheur SM (2019) Assessment of antagonist enamel wear and clinical performance of full-contour monolithic zirconia crowns: One-year results of a prospective study. J Prosthodont 28:e411–e416. DOI: 10.1111/jopr.12960

5. Lee WT, Koak JY, Lim YJ, Kim SK, Kwon HB, Kim MJ (2012) Stress shielding and fatigue limits of poly-ether-ether-ketone dental implants. J Biomed Mater Res B Appl Biomater 100:1044–1052. DOI: 10.1002/jbm.b.32669

6. Tsuka H, Morita K, Kato K, Kawano H, Abekura H, Tsuga K (2017) Evaluation of shear bond strength between PEEK and resin-based luting material. J Oral Biosci 59:231–236. DOI: 10.1016/j.job.2017.09.003

7. Stawarczyk B, Beuer F, Wimmer T, Jahn D, Sener B, Roos M, Schmidlin PR (2013) Polyetheretherketone—a suitable material for fixed dental prostheses? J Biomed Mater Res B Appl Biomater 101:1209–1216. DOI: 10.1002/jbm.b.32932

8. Schmidlin PR, Stawarczyk B, Wieland M, Attin T, Hämmerle CH, Fischer J (2010) Effect of different surface pre-treatment and luting materials on shear bond strength to PEEK. Dent Mater 26:553–559. DOI: 10.1016/j.dental.2010.02.003

9. Tsuka H, Morita K, Kato K, Kimura H, Abekura H, Hirata I, Kato K, Tsuga K (2019) Effect of laser groove treatment on shear bond strength of resin-based luting agent to polyetheretherketone (PEEK). J Prosthodont Res 63:52–57. DOI: 10.1016/j.jpor.2018.08.001

10. Maruyama M, Morita K, Kimura H, Nishio F, Yoshida M, Tsuga K (2020) Association between masticatory ability and oral functions. J Clin Exp Dent 12:e1011–e1014. DOI: 10.4317/jced.56747

11. Nokubi T, Yoshimuta Y, Nokubi F, Yasui S, Kusunoki C, Ono T, Maeda Y, Yokota K (2013) Validity and reliability of a visual scoring method for masticatory ability using test gummy jelly. Gerodontology 30:76–82. DOI: 10.1111/j.1741-2358.2012.00647.x

12. Sakaguchi K, Chino K, Yokoyama A (2017) Current status of clinical examinations for dental occlusion and masticatory function. Hokkaido J Dent Sci 37:177–180

13. Stawarczyk B, Jordan P, Schmidlin PR, Roos M, Eichberger M, Gernet W, Keul C (2014) PEEK surface treatment effects on tensile bond strength to veneering resins. J Prosthet Dent 112:1278–1288. DOI: 10.1016/j.prosdent.2014.05.014

14. Uhrenbacher J, Schmidlin PR, Keul C, Eichberger M, Roos M, Gernet W, Stawarczyk B (2014) The effect of surface modification on the retention strength of polyetheretherketone crowns adhesively bonded to dentin abutments. J Prosthet Dent 112:1489–1497. DOI: 10.1016/j.prosdent.2014.05.010

15. Zhou L, Qian Y, Zhu Y, Liu H, Gan K, Guo J (2014) The effect of different surface treatments on the bond strength of PEEK composite materials. Dent Mater 30:e209–e215. DOI: 10.1016/j.dental.2014.03.011

16. Barkarmo S, Longhorn D, Leer K, Johansson CB, Stenport V, Franco-Tabares S, Kuehne SA, Sammons R (2019) Biofilm formation on polyetheretherketone and titanium surfaces. Clin Exp Dent Res 5:427–437. DOI: 10.1002/cre2.205

Figures

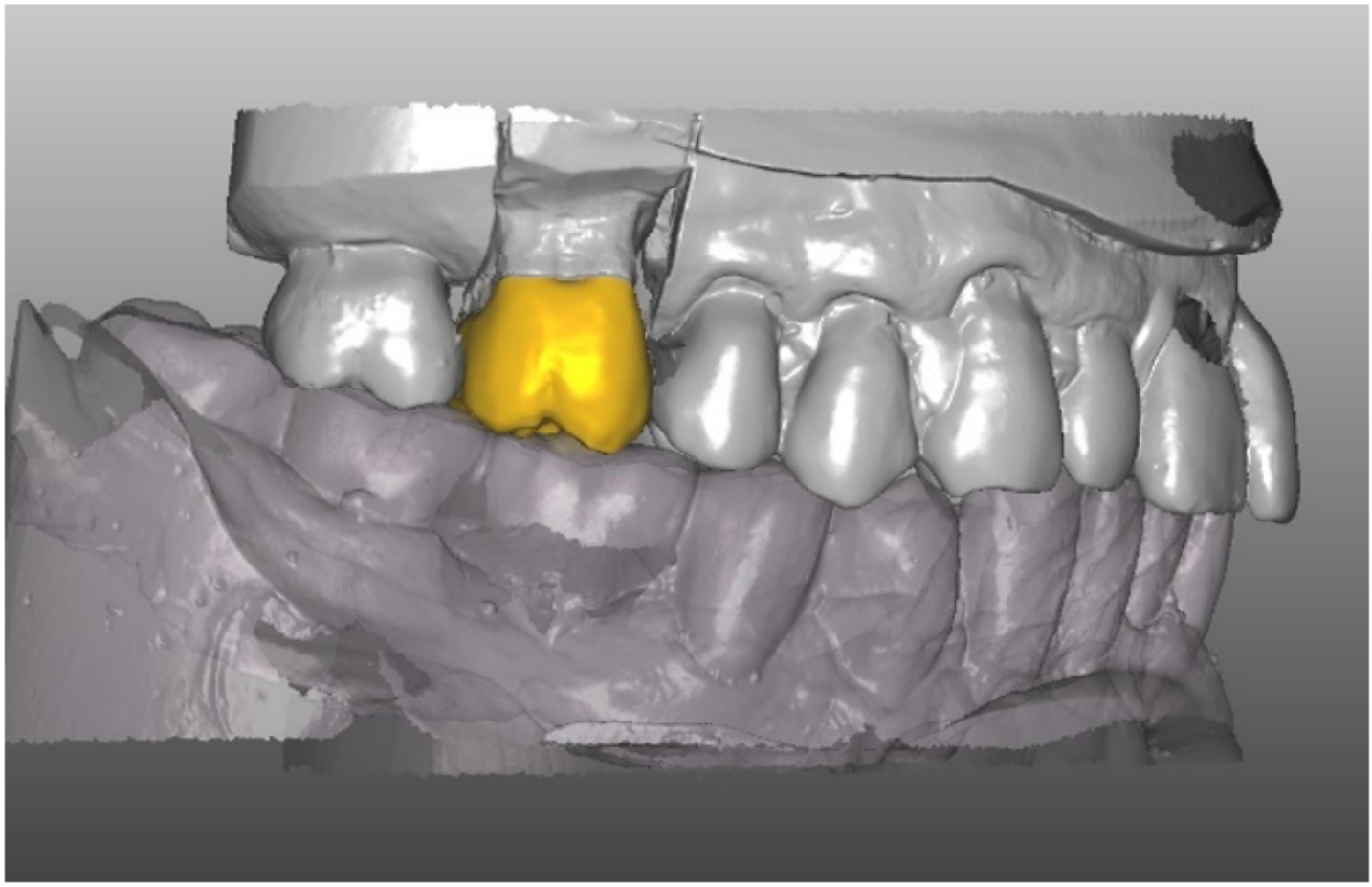

Figure 1

CAD data

Figure 2

Exterior view of PEEK crown

Figure 3

Intraoral photograph

Figure 4

X-ray after cementing

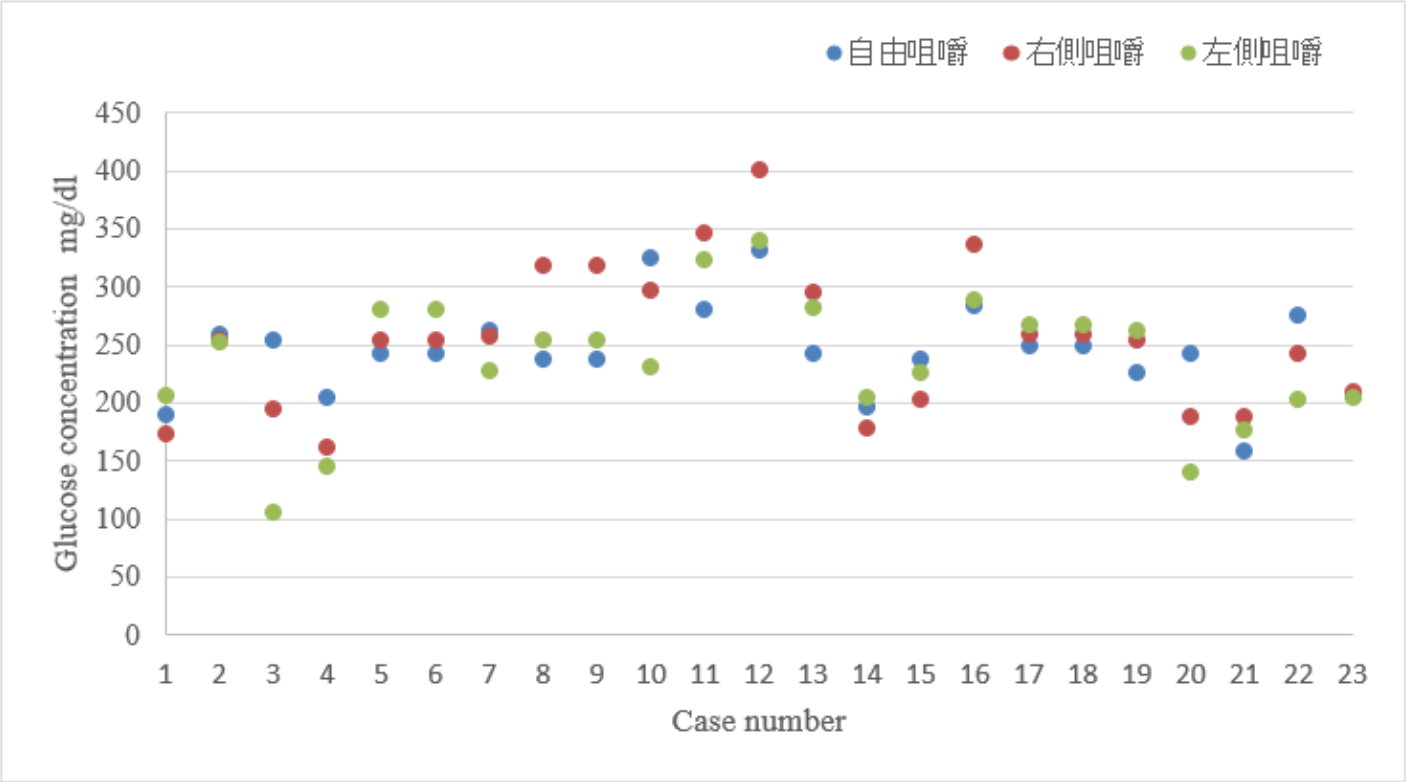

Figure 5

Masticatory ability test *Classification by free mastication, right-sided mastication and left-sided mastication

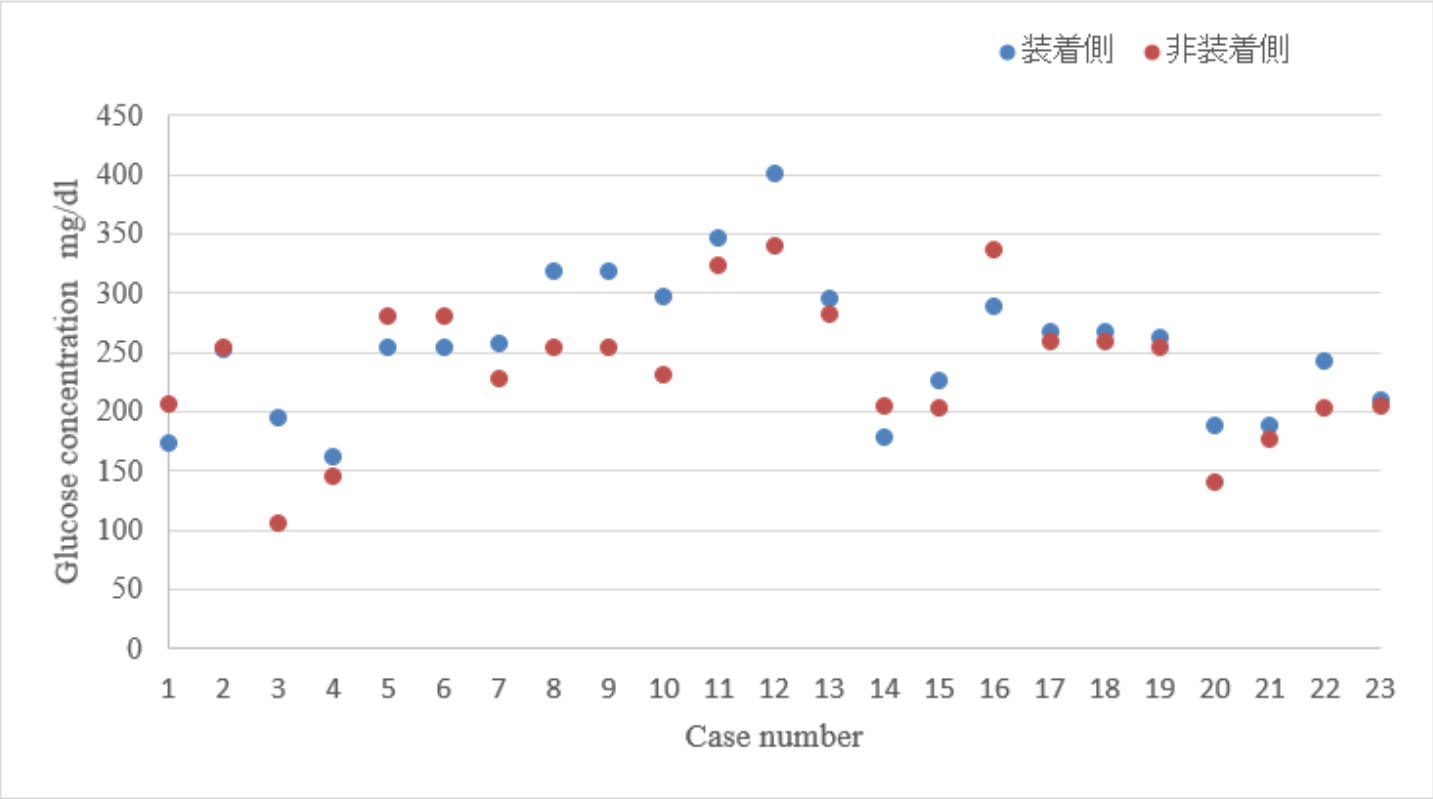

Figure 6

Masticatory ability test *Classified by wearing PEEK side and non-wearing PEEK side

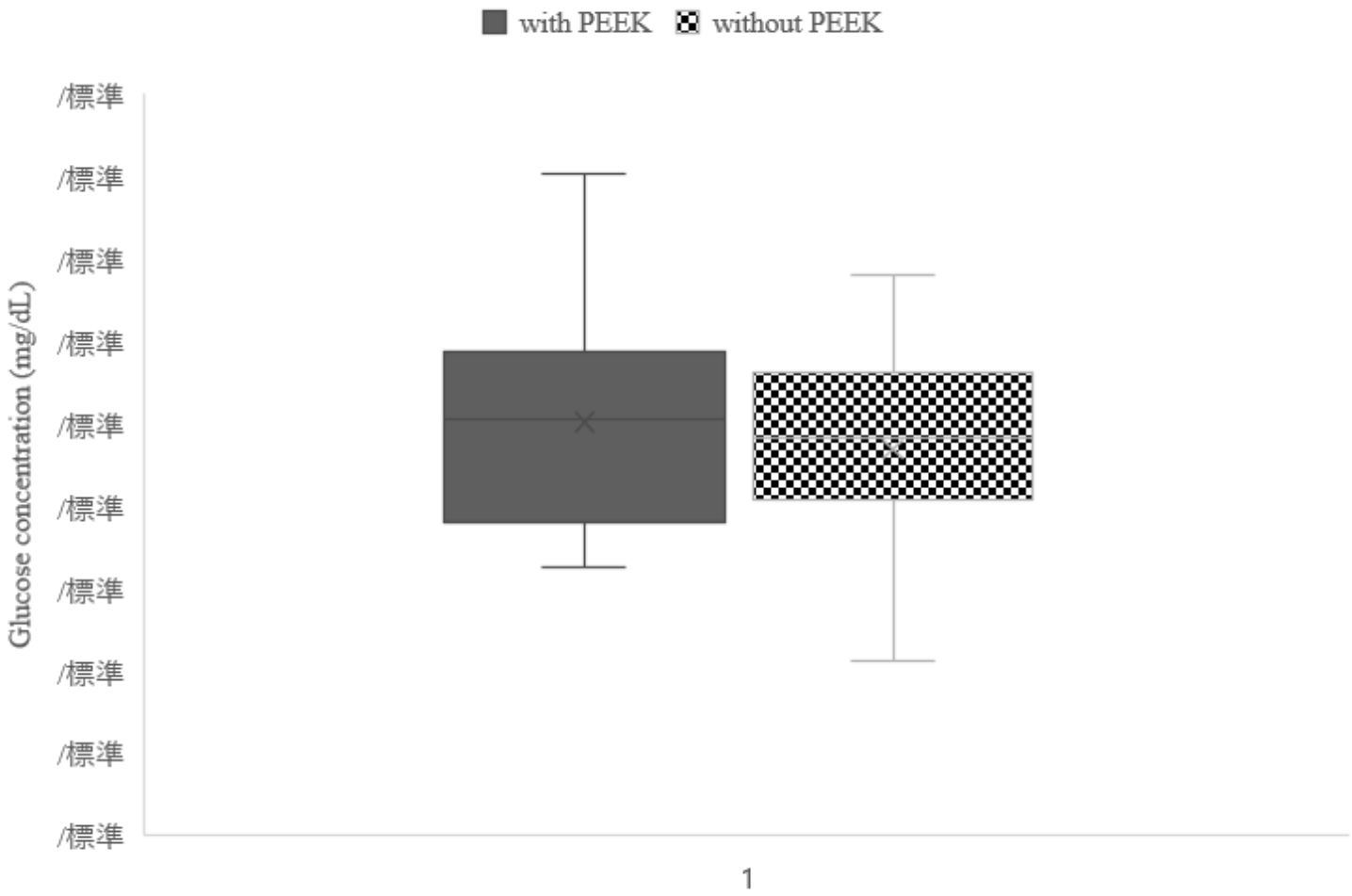

Figure 7

Glucose concentration in PEEK crown with and without (mg/dL)

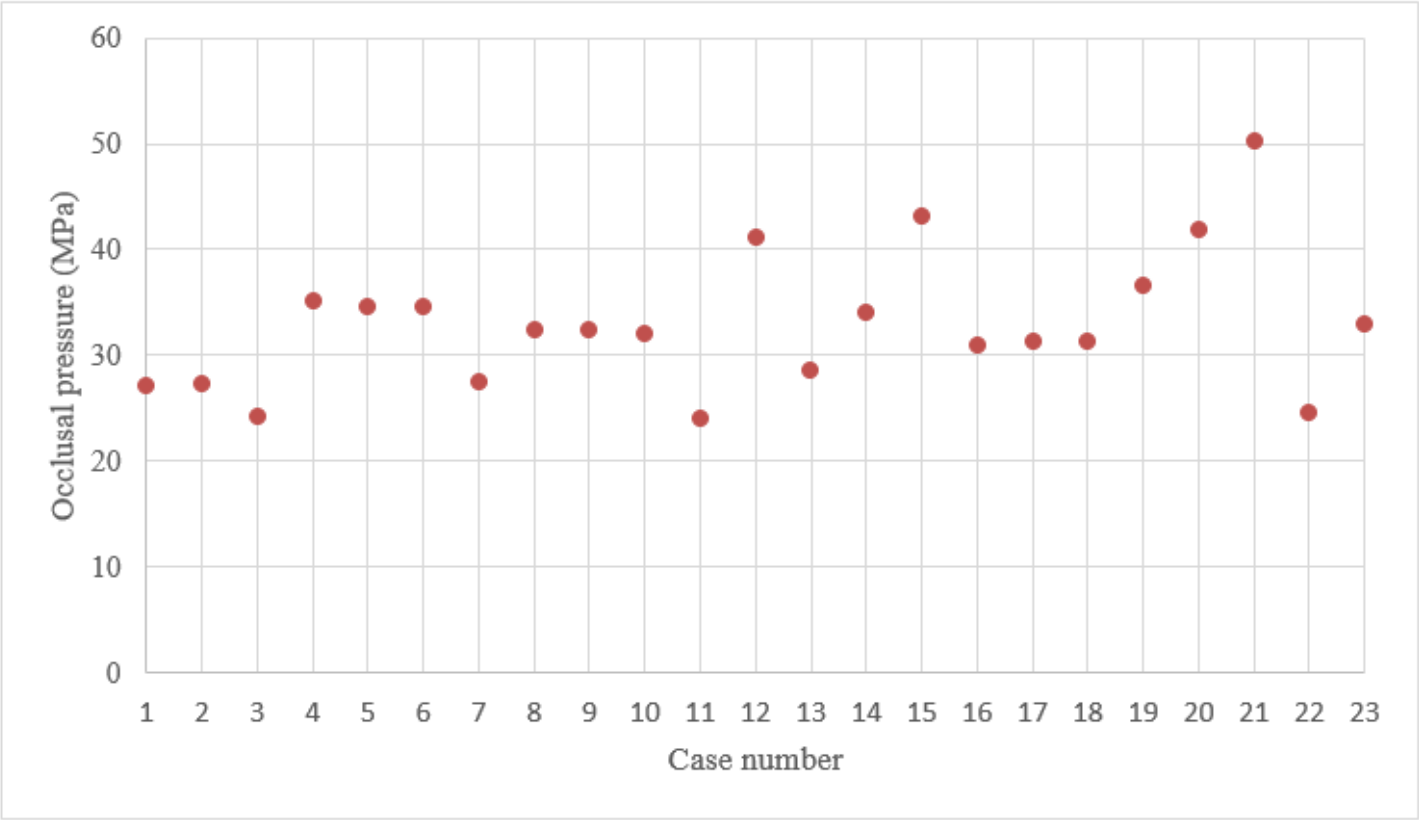

Figure 8

Occlusal pressure (Mpa)

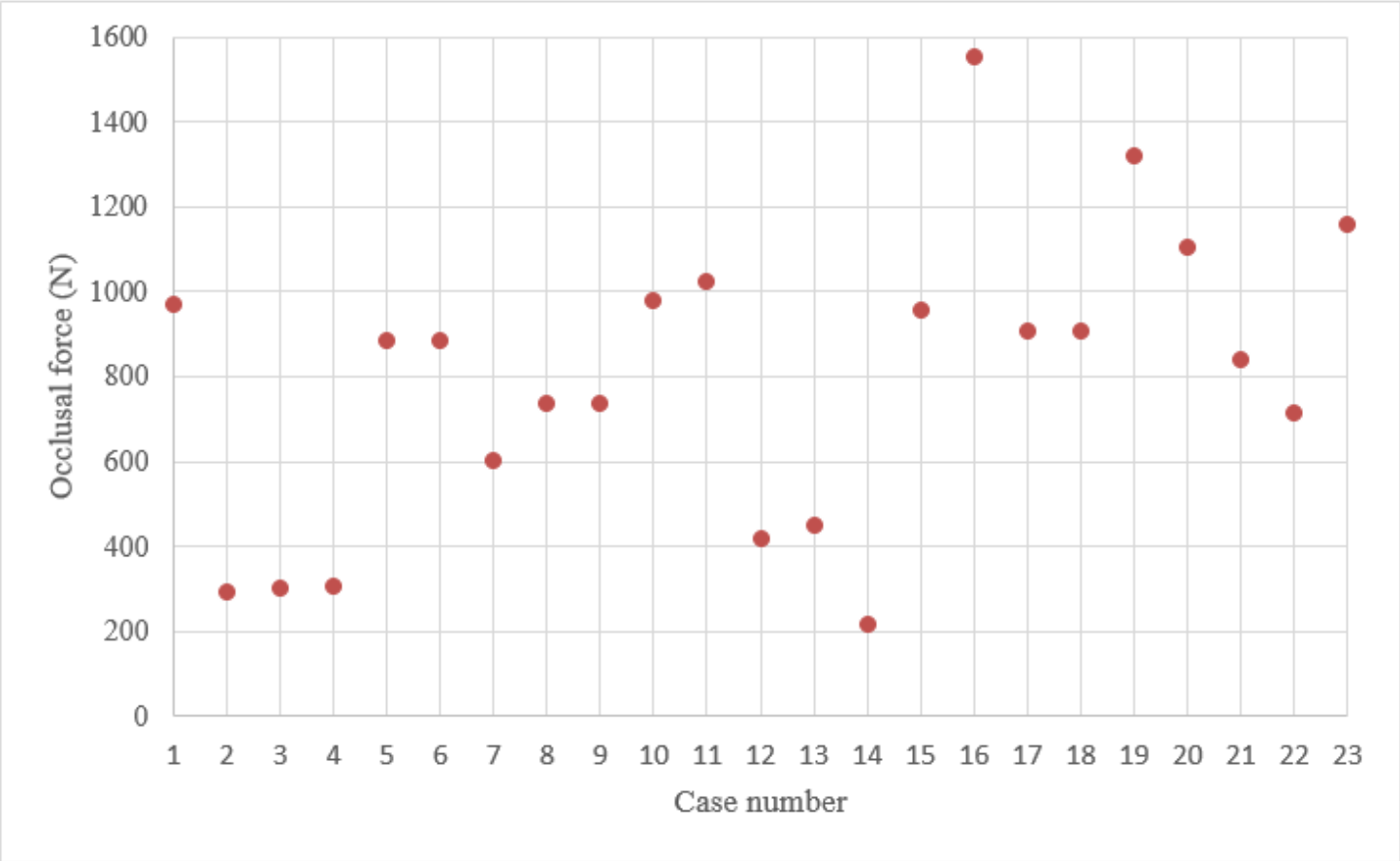

Figure 9

Occlusal force (N)