

Incidence And Risk Factor Analysis For Swelling After Apical Microsurgery

Cheng Bi

VIP Center, Hangzhou Dental Hospital

Siqi Xia

Zhejiang Chinese Medical University

Yuchi Zhu

Zhejiang Chinese Medical University

Xinzhu Lian

Zhejiang Chinese Medical University

Lijun Hu

Zhejiang Chinese Medical University

Chenxing Rao

Zhejiang Chinese Medical University

Haibin Jin

Zhejiang Chinese Medical University

Xiaodan Shang

Zhejiang Chinese Medical University

Feifan Jin

Zhejiang Chinese Medical University

Jingyu Li

Zhejiang Chinese Medical University

Pei Zheng

Zhejiang Chinese Medical University

Shuhua Wang (✉ 386154787@qq.com)

Zhejiang Chinese Medical University

Research Article

Keywords: swelling, density, shadow, gender, volume

Posted Date: November 12th, 2021

DOI: <https://doi.org/10.21203/rs.3.rs-1013128/v1>

License:  This work is licensed under a Creative Commons Attribution 4.0 International License.

[Read Full License](#)

Abstract

The aim of this prospective observational cohort study is to evaluate developing periapical swelling after apical microsurgery and determine potential risk factors. Ninety-eight apical microsurgery patients were selected for this study. Before surgery, bone shadow volume and density of pathological tissue were measured by CBCT. The other variables (age, gender, operative teeth number, fistula, preoperative swelling, drug use and pre-surgery root canal treatments) were assessed during examination. Swelling degree was confirmed by questionnaires for patients on the 1st, 7th, 14th, and 21st days respectively after surgery. Statistical analyses were performed to identify predictors for swelling. Majority of patients reported moderate (45.9%) or severe (34.7%) swelling on day 1, and moderate (44.9%) or mild (45.9%) on day 7. 99% patients had no or mild swelling on day 14. The average swelling level peaked on day 1 postoperatively and gradually decreased. Of statistical significance, age, bone shadow volume and density of pathological tissue acted as predictors of swelling ($P < 0.05$). However, there was no significant difference in gender, tooth number, fistula, preoperative swelling, drug use, or pre-surgery root canal treatments ($P > 0.05$). We conclude that younger patients with larger shadow volume and density were significantly more likely to develop swelling after apical microsurgery.

Introduction

Apical microsurgery is a newly-developed procedure, which consists of periapical curettage, apicoectomy, retro preparation and retro filling of a root canal while under dental microscope¹. It holds a high success rate of controlling periapical infection, so as to promote periapical healing and periapical tissue regeneration². This may be due to its accuracy, minimally invasive nature, and high curative effect through the use of microscopic magnification, illumination, ultrasonic instrument tips and root-end filling materials³⁻⁵.

On the other hand, apical microsurgery cannot avoid a certain degree of swelling, which is one of the most common postoperative complications⁶. Kvist⁷ stated that almost all patients developed swelling and pain, with these complications mostly peaking on the first day after surgery. Additionally, swelling of the mucoperiosteum flap was also reported after tooth extraction surgery, where the triangular flap had a greater increase in swelling than the envelope flap within a week⁸. Further, a low probability of swelling was reported after root canal treatment, especially after root canal filling⁹. However, single or multiple root canal treatments had no significant effect on the degree of swelling. Most short- and long-term complications (pain and swelling) showed a similar frequency. However, people who made a single clinical visit were more likely to experience pain and to take painkillers¹⁰.

To date, many studies have focused on swelling after tooth extraction surgery and root canal treatments. There has also been some research that illustrates predictors of pain after apical microsurgery¹¹. However, few studies have clarified predictors of swelling after apical microsurgery. The aim of this study,

therefore, is to evaluate the characteristics and degree of periapical swelling after apical microsurgery and to determine the potential risk factors of periapical swelling.

Materials And Methods

Ethics and Sample Selection

This study was conducted according to the Declaration of Helsinki principles. The study protocol was approved by the Medical Ethics Committee of Hangzhou Dental Hospital (2021-6-9). Written informed consent was obtained from each subject before participating in the study. Patients who need Apical Microsurgery were recruited at Microscopic Dentistry Center of Dentistry, Hangzhou Dental Hospital, from 2018 to 2020.

Basic patient information, preoperative and postoperative physical examination notes, clinical symptoms and other relevant patient records were considered in patient selection. Imaging data from preoperative and postoperative follow-up visits were included. Eligible patients were identified according to the following inclusion criteria:

1. patients graded as Classification \geq or Grade A by the American Society of Anesthesiologists,
2. patients between 18 and 65 years of age who meet the indications for apical microsurgery surgery,
3. patients who had a preoperative CBCT scan taken that was of good diagnostic quality and with teeth treated by unified and standardized apical microsurgery,
4. patients with a follow-up period of more than half a year.

Ninety-eight patients' records met the inclusion criteria and were included in this study for further analysis. All apical microsurgeries were performed by a single endodontic specialist at the VIP Center in Hangzhou Dental Hospital.

Surgery Protocol

First, for mandibular posterior teeth, 2 ml of 2% lidocaine with 1:100000 adrenaline was administered by inferior alveolar nerve block, and 3.4 ml of 4% articaine hydrochloride with 1:100000 adrenaline was administered by infiltration to the maxillary and mandibular anterior teeth. A single vertical incision was made distant to the periapical lesion and sulcular incisions in the corresponding region, and the mucoperiosteal envelope flap was elevated. Secondly, from this stage on, all surgical procedures were performed under a dental operating microscope (OMS2350; ZUMAX, Jiangsu, China) with coaxial illumination and a zoom magnification changer. Magnifications between 3.4 and 20.4 were used. The periapical region was curetted, and the granulation tissue removed. A following apicoectomy was performed with a fissure bur 3 mm coronal to the apex. Thirdly, subsequent smoothing with a piriform bur applied rectangularly to the axis of the root resulted in a bevel of approximately 10. The resulting surface was stained with 50 mg/5 mL methylthioninium chloride and inspected by using a micromirror (JIMM2; B&L Biotech, Ansan-si, South Korea) under high magnification to detect individual canal anatomy, in

particular, any additional canals, isthmuses or root fractures. After cleaning with 30% hydrogen peroxide and then 96% alcohol, and subsequent drying, the prepared cavity was filled with Intermediate Restorative Material (IRM; Dentsply Caulk, Milford, DE). Finally, the filling and the apical surface were smoothed with a piriform stainless-steel bur. The flap was closed with single interrupted sutures, and a postoperative digital radio graph was taken. Patients were instructed to take 20 mg serrapeptase enteric-coated tablets or 1.5 mg dexamethasone acetate tablets after meals t.i.d., and 60 mg loxoprofen sodium tablets as needed.

Data Collection

On the 1st, 7th, 14th and 21st days after operation, patients were given questionnaires with a visual analogue scale to evaluate the degree of swelling. The VAS score of swelling was as follows:

0 (no swelling): the patient felt like usual,

1-3 (mild swelling): the patient can tolerate symptoms, the appearance did not affect his/her life and work, and no drug treatment was needed,

4-6 (moderate swelling): the patient was anxious due to changed appearance caused by swelling, which affected his/her work and life, and drug intervention was needed, indicating that the swelling was hard to tolerate,

7-10 (severe swelling): the patient felt severe anxiety and unhappiness due to changed appearance caused by swelling, which seriously affected his/her work and life, and an extended period of time was needed for drug intervention to alleviate symptoms, indicating that the swelling was severe or intolerable.

All patients' degree of swelling was collected and gathered into electronic records, which indicated their degree of swelling at different points in time.

On day 1, severe tissue damage in the surgical area led to severe swelling, which affected the judgment of predictors. Thus, swelling conditions on the 7th day post-operation were chosen for data comparison in order to speculate on risk factors. The patients were finally divided into two groups for comparison. No swelling and mild swelling were classified as one group, while moderate swelling and severe swelling were the other group. Independent data analysis was performed for the following predictors: age, gender, tooth number, fistula, preoperative swelling, drug use, pre-surgery root canal treatment, bone shadow volume, and density of pathological tissue.

Statistical Analysis

The Mann-Whitney U test and chi-square test were used to analyze and compare the basic characteristics of patients included in each group. SPSS v.26.0 software (IBM Corp, Armonk, NY) was used for all analyses.

Results

Prediction of Risk Factors for Swelling

Tables 1 show the statistical comparison of different predictors between the no or mild swelling group and the moderate or severe swelling group on the 7th day after surgery. In the analysis of 98 people, the patients with moderate or severe swelling were significantly younger than those of the no or mild swelling group ($P < 0.05$).

Additionally, larger preoperative bone shadow volume statically demonstrated severe swelling ($P < 0.05$). The density of pathological tissue was statistically different between two groups ($P < 0.05$), the deeper density being more swollen.

However, there was no significant difference in gender, tooth number, tooth position, fistula, preoperative swelling, drug use or pre-surgery root canal treatment ($P > 0.05$).

Trends and Characteristics of Postoperative Swelling

Fig. 1 shows the trends after operation. Severe swelling was most dominant on the 1st day (34.7%), and gradually decreased until the 14th day. Most patients reported moderate (45.9%) and severe (34.7%) swelling on day 1, while moderate (44.9%) and mild (45.9%) swelling on day 7 were most reported. Ninety-nine percent of patients had no or mild swelling on day 14.

Discussion

Swelling is one of the most common complications after apical surgery and is directly related to the degree of tissue trauma during operation^{6,7}. It is considered a normal, predictable physiological reaction after surgery which may reduce patients' life quality during healing. Symptoms of swelling must therefore be minimized¹².

Postoperative swelling is a pathological process of transformation. In the early stages after operation, a series of inflammatory reactions and oxidative stress occur in tissue at the surgical site. Moreover, stitched wounds increase local tension, causing local arterial congestion and dilation, leading to blocked lymphatic reflux and retention of large amounts of fluid in the tissue¹³. After 7 days, the wound gradually contracts, basal cells proliferate, and granulation tissue and corresponding fibers reconstruct^{14,15}. Fourteen days post-operation, the wound heals, and the swelling is reduced.

Younger patients were more likely to experience moderate and severe swelling after surgery. This may be related to a relative decline in immunity and inflammatory response in older patients¹⁶. In addition, protective pulp calcification, reduced root canal attenuation and dentin tubule calcification in the elderly may also lead to reducing swelling after surgery¹⁷.

Swelling is a type of increase in tissue volume caused by reacting of stress in tissue. In apical microsurgery, the number of teeth operated on is not the main factor of swelling, but rather the severity of pathological changes prior to operation¹⁸. In this study, the main indicators were bone shadow volume and density of pathological tissue. Bone destruction was one of the most salient causes of poor prognosis. Clinical and radiological investigations by Mikkonen et al.¹⁹ found that periodontal crest absorption and traumatic occlusion might impede the healing process after apical surgery. Another study found that peripheral bone destruction and marginal bone loss also affected tissue healing²⁰.

In this study, gender, tooth number, fistula, preoperative swelling, drug use after operation, and pre-surgery root canal therapy showed no significant difference ($P > 0.05$). Results related to gender were different from Cory and Lqbal et al.^{11,21}, who investigated the degree of pain after apical microsurgery. They found that gender had a significant impact on the incidence of severe pain, which may be related to the different pain thresholds between men and women. Mostly, periapical inflammation was controlled after apical microsurgery. Apical microsurgery promoted the closure of fistula, but was not significant in the degree of swelling. The appropriate amount of dexamethasone was reported to both reduce swelling and improve the patient's prognosis^{13,22}.

The value of bone shadow volume and density of pathological tissue as predictors of postoperative pain has been highlighted in the current study. This information can guide physicians to take appropriate measures in patient treatment plans to reduce the degree of swelling after apical microsurgery and improve patient prognosis.

Conclusions

Based on this clinical analysis, periapical swelling after apical microsurgery occurred frequently. Risk factors may be younger age, larger bone shadow volume and deeper density of pathological tissue. However, other related risk factors and methods to improve prognosis must still be further elaborated.

Declarations

Data availability

The datasets used and/or analyzed during the current study are available from the corresponding author on reasonable request.

Author contributions

C.B., S.Q.X., P.Z. and S.H.W.: conception and design, analysis and interpretation of the data, drafting the article, critical revision of the manuscript for important intellectual content and final approval of the version to be published. Y.C.Z., X.Z.L., L.J.H., C.X.R. H.B.J. X.D.S., F.F.J. and J.Y.L.: conception and design, interpretation of the data, critical revision of the manuscript for important intellectual content and final approval of the version to be published. All authors have read and approved the submitted manuscript.

Funding This research was supported by the Natural Science Foundation of Zhejiang Province (No. LQ21H270001).

Competing interests The authors declare no competing interests.

References

- 1 von Arx, T. & Walker, W. A., 3rd. Microsurgical instruments for root-end cavity preparation following apicoectomy: a literature review. *Endod Dent Traumatol* **16**, 47-62, <https://doi.org/10.1034/j.1600-9657.2000.016002047.x> (2000).
- 2 Kim, S. & Kratchman, S. Microsurgery in Endodontics. (2017).
- 3 Tsesis, I., Fuss, Z., Lin, S., Tilinger, G. & Peled, M. Analysis of postoperative symptoms following surgical endodontic treatment. *Quintessence Int* **34**, 756-760 (2003).
- 4 Floratos, S. & Kim, S. Modern Endodontic Microsurgery Concepts: A Clinical Update. *Dent Clin North Am* **61**, 81-91, <https://doi.org/10.1016/j.cden.2016.08.007> (2017).
- 5 Setzer, F. C., Shah, S. B., Kohli, M. R., Karabucak, B. & Kim, S. Outcome of endodontic surgery: a meta-analysis of the literature—part 1: Comparison of traditional root-end surgery and endodontic microsurgery. *J Endod* **36**, 1757-1765, <https://doi.org/10.1016/j.joen.2010.08.007> (2010).
- 6 Christiansen, R., Kirkevang, L. L., Horsted-Bindslev, P. & Wenzel, A. Patient discomfort following periapical surgery. *Oral Surg Oral Med Oral Pathol Oral Radiol Endod* **105**, 245-250, <https://doi.org/10.1016/j.tripleo.2007.08.023> (2008).
- 7 Kvist, T. & Reit, C. Postoperative discomfort associated with surgical and nonsurgical endodontic retreatment. *Endod Dent Traumatol* **16**, 71-74, <https://doi.org/10.1034/j.1600-9657.2000.016002071.x> (2000).
- 8 Coulthard, P. *et al.* Surgical techniques for the removal of mandibular wisdom teeth. *Cochrane Database Syst Rev*, CD004345, <https://doi.org/10.1002/14651858.CD004345.pub2> (2014).
- 9 Wang, C., Xu, P., Ren, L., Dong, G. & Ye, L. Comparison of post-obturation pain experience following one-visit and two-visit root canal treatment on teeth with vital pulps: a randomized controlled trial. *Int Endod J* **43**, 692-697, <https://doi.org/10.1111/j.1365-2591.2010.01748.x> (2010).
- 10 Figini, L., Lodi, G., Gorni, F. & Gagliani, M. Single versus multiple visits for endodontic treatment of permanent teeth: a Cochrane systematic review. *J Endod* **34**, 1041-1047, <https://doi.org/10.1016/j.joen.2008.06.009> (2008).
- 11 Malagise, C. J., Khalighinejad, N., Patel, Y. T., Jalali, P. & He, J. Severe Pain after Endodontic Surgery: An Analysis of Incidence and Risk Factors. *J Endod* **47**, 409-414,

<https://doi.org/10.1016/j.joen.2020.12.012> (2021).

12 Zandi, M., Amini, P. & Keshavarz, A. Effectiveness of cold therapy in reducing pain, trismus, and oedema after impacted mandibular third molar surgery: a randomized, self-controlled, observer-blind, split-mouth clinical trial. *Int J Oral Maxillofac Surg* **45**, 118-123, <https://doi.org/10.1016/j.ijom.2015.10.021> (2016).

13 Mojsa, I. M. *et al.* Effect of submucosal dexamethasone injection on postoperative pain, oedema, and trismus following mandibular third molar surgery: a prospective, randomized, double-blind clinical trial. *Int J Oral Maxillofac Surg* **46**, 524-530, <https://doi.org/10.1016/j.ijom.2016.11.006> (2017).

14 Matsuda, M., Huh, Y. & Ji, R. R. Roles of inflammation, neurogenic inflammation, and neuroinflammation in pain. *J Anesth* **33**, 131-139, <https://doi.org/10.1007/s00540-018-2579-4> (2019).

15 Margraf, A., Ludwig, N., Zarbock, A. & Rossaint, J. Systemic Inflammatory Response Syndrome After Surgery: Mechanisms and Protection. *Anesth Analg* **131**, 1693-1707, <https://doi.org/10.1213/ANE.0000000000005175> (2020).

16 Vitlic, A., Lord, J. M. & Phillips, A. C. Stress, ageing and their influence on functional, cellular and molecular aspects of the immune system. *Age (Dordr)* **36**, 9631, <https://doi.org/10.1007/s11357-014-9631-6> (2014).

17 Carvalho, T. S. & Lussi, A. Age-related morphological, histological and functional changes in teeth. *J Oral Rehabil* **44**, 291-298, <https://doi.org/10.1111/joor.12474> (2017).

18 Penarrocha, M., Garcia, B., Marti, E. & Balaguer, J. Pain and inflammation after periapical surgery in 60 patients. *J Oral Maxillofac Surg* **64**, 429-433, <https://doi.org/10.1016/j.joms.2005.11.014> (2006).

19 Mikkonen, M., Kullaa-Mikkonen, A. & Kotilainen, R. Clinical and radiologic re-examination of apicoectomized teeth. *Oral Surg Oral Med Oral Pathol* **55**, 302-306, [https://doi.org/10.1016/0030-4220\(83\)90332-8](https://doi.org/10.1016/0030-4220(83)90332-8) (1983).

20 Hirsch, J. M., Ahlstrom, U., Henrikson, P. A., Heyden, G. & Peterson, L. E. Periapical surgery. *Int J Oral Surg* **8**, 173-185, [https://doi.org/10.1016/s0300-9785\(79\)80016-2](https://doi.org/10.1016/s0300-9785(79)80016-2) (1979).

21 Iqbal, M. K., Kratchman, S. I., Guess, G. M., Karabucak, B. & Kim, S. Microscopic periradicular surgery: perioperative predictors for postoperative clinical outcomes and quality of life assessment. *J Endod* **33**, 239-244, <https://doi.org/10.1016/j.joen.2006.11.017> (2007).

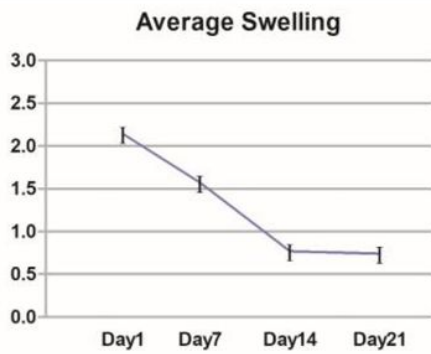
22 Al-Khateeb, T. H. & Nusair, Y. Effect of the proteolytic enzyme serrapeptase on swelling, pain and trismus after surgical extraction of mandibular third molars. *Int J Oral Maxillofac Surg* **37**, 264-268, <https://doi.org/10.1016/j.ijom.2007.11.011> (2008).

Table

Due to technical limitations, table 1 is only available as a download in the Supplemental Files section.

Figures

A



B

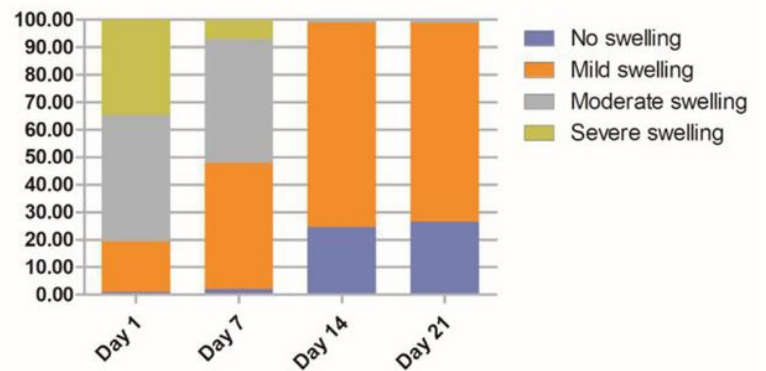


Figure 1

Postoperative swelling from day 1 to day 21. (A) Changes in the average swelling level over time. (B) The distribution of patients with no swelling, mild swelling, moderate swelling, and severe swelling over time.

Supplementary Files

This is a list of supplementary files associated with this preprint. Click to download.

- [Table1102.docx](#)