# Evaluation of Safety and Efficacy of Cell Therapy Based on Osteoblast Derived from Umbilical Cord Mesenchymal Stem Cell for Osteonecrosis of the Femoral Head: Study Protocol for a Single-Center, Open-Label, Phase I Clinical Trial

**Heejae Won**
Kyungpook National University Hospital
**Shin-Yoon Kim**
Kyungpook National University Hospital
**Sunray Lee**
BTRC: Biotechnology Research Center
**Hyun Sook Park**
Cell Engineering For Origin (CEFO) Biotechnology Research Center
**Seung-Hoon Baek** ( insideme@paran.com )
Kyungpook National University Hospital https://orcid.org/0000-0002-8909-3287

**Research Article**

**Keywords:** Hip, Osteonecrosis of femoral head, core decompression, stem cell therapy

**Posted Date:** November 1st, 2021

**DOI:** https://doi.org/10.21203/rs.3.rs-1014385/v1

# Abstract

### Background

Various techniques for joint preservation have been attempted in early stage of osteonecrosis of femoral head (ONFH), but the effects are still controversial. Recently, a combination therapy of core decompression (CD) and MSCs collected from bone marrow, adipocytes or human umbilical cord has been introduced, and satisfactory results have been reported. However, there is no study in which human umbilical cord-derived osteoblasts (hUC-O) were administered directly to the lesion in early ONFH. We have classified the location and size of lesions in early-stage ONFH, and will evaluate the hypothesis that the application of hUC-O is a safe and effective treatment.

### Methods

This is a prospective, single-center, phase I and open-labeled clinical trial. Nine patients with Association Research Circulation Osseous (ARCO) stage 1 or 2 ONFH will be assigned to a low-dose (n = 3, 1 ´ $10^7$ hUC-O cells), medium-dose (n = 3, 2 ´ $10^7$ cells), and high-dose group (n = 3, 4 ´ $10^7$ cells) in the order of their arrival at the facility, and up to 18 patients will be enrolled depending on whether dose limiting toxicity occurs. We will perform CD on the participants, administer hUC-O according to the assigned group, and followed up for 12 weeks, including a total of 5 visits. This study will have 3 aims; first, to evaluate the safety of hUC-O through adverse events assessment, laboratory tests, vital sign assessment, physical examination, and electrocardiogram (ECG) test.; and second, to assess the clinical outcomes after hUC-O application by comparing pain visual analog scale (VAS), Harris Hip scores (HHS), and Western Ontario and McMaster Universities Osteoarthritis Index (WOMAC) before and after surgery; and third, to evaluate the radiographic results after hUC-O application by comparing extent of necrotic lesions according to the ARCO and Japanese Investigation Committee (JIC) classification on magnetic resonance imaging.

### Discussion

This clinical trial is a pilot phase 1 study evaluating the safety and efficacy of hUC-O local application combined with CD in early-stage ONFH patients. This study will provide the useful information on the treatment with hUC-O for those suffering from ONFH.

**Trial registration:** Clinical Research Information Center (CRIS) established at the Korea Centers for Disease Control and Prevention (KDCA), KCT0006627. Registered 30 September 2021,

https://cris.nih.go.kr/cris/search/detailSearch.do/20332


# Background

Osteonecrosis of femoral head (ONFH) usually affects young adults in their 30s to 50s and becomes symptomatic or progresses to femoral head collapse in 60% of asymptomatic patients [1, 2]. Total hip

arthroplasty (THA) is an effective treatment for ONFH that can cause complications such as infection and periprosthetic fracture and may require revisions due to osteolysis or loosening later [3]. Therefore, joint-preserving surgery must be considered in the treatment of early stage ONFH to reduce the medical costs and potential risks by THA, particularly in young patients.

Core decompression (CD) is a joint-preserving procedure that can be performed for early-stage ONFH. It has been reported to reduce pressure within the femoral head and promote revascularization to induce bone formation and remodeling [4]. However, a previous study reported that 38% of patients with early-stage ONFH underwent THA at an average of 26 months after CD [5], and there has been a controversy regarding the effect of CD on early-stage ONFH in previous studies [6, 7].

Mesenchymal stem cells (MSCs) injection, which was used as an adjunctive technique for CD, has recently gained attention as a joint-preserving procedure for early-stage ONFH [8–10]. MSC may cause an increase of local cell populations and promote vascular repair and angiogenesis, thereby effectively promoting osteogenesis in the femoral head [11, 12]. Several studies have reported satisfactory clinical outcomes and survivorship in patients with early-stage ONFH in combination with MSCs injection than CD alone [8, 9, 13]. However, bone marrow or adipocyte-derived MSCs have very diverse cell sourcing and processing strategies, and progenitor cells involved in angiogenesis or bone formation may be insufficient [14]. On the contrary, human umbilical cord-derived MSCs have been reported to have osteogenic potential similar to bone marrow- or adipose-derived MSCs and secrete larger amounts of transforming growth factor beta (TGF-β) and vascular endothelial growth factors (VEGFs) [15–17]. To date, little to no research has been conducted regarding the safety and efficacy of human umbilical cord-derived osteoblast (hUC-O) based cell therapy on ONFH. The present phase 1 clinical trial will assess the safety and efficacy of hUC-O based cell therapy in patients with early-stage ONFH.

## Methods

# Aims of the study

1. This study assesses the safety of hUC-O. Safety is determined through adverse event assessment, laboratory tests, a vital sign assessment, a physical examination, and an electrocardiogram (ECG) test.
2. This study assesses the clinical outcomes of hUC-O. Subjective preoperative and postoperative patient reports, specifically, pain visual analog scale (VAS)[18], Harris Hip scores (HHS)[19], and Western Ontario and McMaster Universities Osteoarthritis Index (WOMAC)[20], are compared to assess the clinical outcomes.
3. This study assesses the radiological results after hUC-O based cell therapy using simple radiography and magnetic resonance imaging (MRI). The preoperative and postoperative necrotic lesion size, the Association Research Circulation Osseous (ARCO) stage [21], and Japanese Investigation Committee (JIC) [22] stage are compared.

# Study Design

The present study is an investigator-sponsored, prospective, single-institution, open-label, phase 1 clinical trial and has been approved by the institutional review board (IRB) of Kyungpook National University Hospital (IRB No. KNUH 2021-07-015) and Korea Food and Drug Administration (No. 10052). The trial was registered at the Korean Clinical Trials Register (KCT0006627) on September 30, 2021.

# Study population

Inclusion criteria: Participants must fulfill all of the following conditions to qualify for study enrollment:

1) Males or females between 19 and 60 years old

2) Radiographically diagnosed with osteonecrosis on at least one side of the femoral head.

3) Have ARCO stage 1 or 2.

4) Symptom improvement or relief following 3 months of conservative treatment are deemed improbable by a researcher.

5) Have voluntarily consented to participate in this clinical trial.

Exclusion criteria: Participants who fulfill at least one of the following conditions must be excluded:

1) ONFH is deemed as rapidly progressing by a researcher.

2) Have shown clinically significant abnormal values in a screening test (Aspartate aminotransferase [AST] or alanine transaminase [ALT] levels over 2.5-fold the upper normal limit [UNL] specified by the research facility).

3) Malignant bone tumor or bone metastasis in the femoral head or proximal femur.

4) Previous history of malignant tumors (but can be included if there was no relapse within 5 years after completing a treatment).

5) Diagnosed with inflammatory arthritis of the operated joint.

6) Diagnosed with acetabular dysplasia with a lateral center-edge angle <20°.

7) Post-traumatic ONFH.

8) Systemic or local inflammatory response requiring systemic antibiotic treatment.

9) Diagnosed with human immunodeficiency virus (HIV), hepatitis B or hepatitis C infection

10) Requires continuous, systemic, and high-dose corticosteroid therapy (prednisone administration at 7.5 mg/day) or administration of immunosuppressants within 6 months after CD.

11) Stem cell therapy for ONFH before screening.

12) Heavy alcohol consumption within 6 months of screening (males ≥ 13 standard drink [10g of pure alcohol]/week, females ≥ 7 standard drink/week)

13) Have undergone CD or other treatments or procedures that can affect the femoral head at the site of the operation.

14) Body mass index (BMI) ≥ 40 kg/$m^2$ at the time of a screening visit.

15) Females with a possibility of pregnancy and do not agree to use medically approved contraceptive methods (e.g., hormonal contraceptives, intrauterine device [IUD], intrauterine system [IUS], tubal ligation, double-barrier contraception [e.g., combined use of male and female condoms, cervical cap, contraceptive diaphragm, and contraceptive sponge], and single-barrier contraception using spermicides) during the study period.

16) Pregnant or breastfeeding.

17) Received an investigational new drug (IVD) from another clinical trial within 4 months before participating in this clinical trial.

18) Are deemed inadequate for participation in this study by a researcher.

Of the patients who consent to participate in this clinical trial, those who satisfy the inclusion and exclusion criteria will be assigned to a low-dose (n = 3), middle-dose (n = 3), and high-dose group (n = 3) in the order of their arrival at the facility without random allocation and followed up for 12 weeks. Nine patients will be assigned if no dose limiting toxicity (DLT) develops up to the highest dose. Up to 18 patients can be enrolled, depending on the development of DLT.

# Procedure

CD restores normal blood circulation within the femoral head by drilling a tunnel at the site of necrosis [4]. It reduces the increased intramedullary pressure and pain by promoting revascularization within the necrotic site [7]. In this clinical trial, a competent researcher or a designated physician will perform CD and administer hUC-O through the following steps.

1) Check the size and location of the lesion before the procedure, and place the patient on the operating table.

2) Make an incision on the lateral femoral region after anesthetizing the patient. Insert a guide pin for core decompression under the fluoroscopic guidance (Fig 1).

3) Create an insertion hole using reamer along the guide pin to administer the hUC-O and collect an autogenous bone chip (which is later mixed with hUC-O) (Fig 2).

4) Create a tunnel for drug administration along the guide pin and collect an autogenous bone block (which will be inserted as a bone plug following inserting mixture of hUC-O) and insert an 8–12-mm biopsy cannula into the tunnel until it reaches the site of the lesion (Fig 3).

5) Perform curettage to remove the necrotic bone debris and wash the site of the lesion (Fig 4).

6) Mix the autogenous bone chip collected in Step 3 with hUC-O, thrombin glue, collagen putty, hydroxyapatite (HA) and tri-calcium phosphate (TCP) chips (biodegradable and osteoconductive agents).

7) Insert the mixture from Step 6 into the site of the lesion.

8) Fill the remaining space and proximal portion of the bone tunnel with the autogenous bone block collected in Step 4 after performing Step 7.

9) If there is still large amount of space and tunnel remained in distal portion of the tunnel remained after Step 8, insert HA and TCP block may be inserted (Fig 5).

10) Restrict the participant from weight-bearing for 6 weeks. After 6 weeks, the participant is allowed partial weight-bearing using crutches or a walker for 6 weeks.

# Characteristics of the hUC-O

An off-white cell suspension is stored in deep freezer (≤−135℃) and can be used for 2 years from the date of manufacture. Vials are stored in a freezer prior to use, thawed for 3 to 5 minutes at 35–37°C, and must be used within 2 hours. A syringe is filled with the whole volume of cell suspension, shaken to achieve an even cell suspension before administration. A vial has a volume of 1 mL and contains $1 \times 10^7$ human umbilical cord-derived osteoblasts. In this study, hUC-O will be administered into the site of ONFH at a low (1 vial, $1 \times 10^7$ cells), middle (2 vial, $2 \times 10^7$ cells), or high dose (4 vial, $4 \times 10^7$ cells) in the order of group allocation.

# Timeline and study protocol

After a volunteer provides written consent to participate in the clinical trial, necessary examinations and tests will be performed within 3 weeks before hUC-O administration (Visit 1) according to the study protocol (Table 1). Participants who meet the inclusion/exclusion criteria in the eligibility assessment will be subjected to CD and hUC-O administration (Visit 2). Participants will be checked for acute adverse

events for 3 days after administer hUC-O and visit the facility after 2 (Visit 3), 6 (Visit 4) and 12 (Visit 5) weeks for a safety assessment. The safety assessment will be performed based on the same schedule for all participants with only the administration dose varying.

Table 1

Protocol and timeline for outcome assessments

| Period | Screening | Treatment[g)] | Follow-up 1 | Follow-up 2 | Study Completion / Dropout[i)] |
|---|---|---|---|---|---|
| Visit | 1 | 2 | 3 | 4 | 5[i)] |
| Week | Within -3 | 0 | 2 | 6 | 12 |
| Visit window (days) | - | - | ±3 | ±7 | ±7 |
| Written consent form[a)] | X | | | | |
| Demographic information | X | | | | |
| Body weight and height measurement | X | | | | |
| Review medical/operation history | X | X[h)] | | | |
| Review medication history | X | X[h)] | | | |
| Vital signs[b)] | X | X[h)] | X | X | X |
| Physical examination | X | X[h)] | X | X | X |
| Clinical laboratory tests[c)] | X [C-1), C-2)] | | X | X | X [C-1)] |
| ECG test | X | | X | X | X |
| Pregnancy test[d)] | X | | | | X |
| Radiographic examination | X[e)] | | X | X | X |
| MRI examination | X | | | | X |
| ARCO classification | X | | | | X |
| JIC classification | X | | | | X |
| Review inclusion/exclusion criteria | X | X | | | |
| Patient selection | | X | | | |
| Group allocation | | X | | | |
| CD | | X | | | |
| hUC-O administration | | X | | | |

| | | | | |
|---|---|---|---|---|
| Pain VAS assessment | X[h)] | | | X |
| HHS assessment | X[h)] | | | X |
| WOMAC assessment | X[h)] | | | X |
| Adverse events assessment | X [f)] | X | X | X |
| Check concomitant drug use | X | X | X | X |

ECG, electrocardiogram; MRI, magnetic resonance imaging; ARCO, Association Research Circulation Osseous; JIC, Japanese Investigation Committee; CD, core decompression; hUC-O, human umbilical cord derived-osteoblast; VAS, visual analog scale; HHS, Harris hip score; WOMAC, Western Ontario and McMaster Universities

a) Written consent can be obtained from participants before the screening visit.

b) For vital signs, pulse, blood pressure, and body temperature will be measured. At Visit 2, vital signs will be measured before hUC-O administration.

c) For screening tests, test results obtained within 4 weeks after a visit can be used. A retest may also be performed once at the discretion of a researcher during the screening period. The following parameters are assessed during the laboratory tests.

• Blood test: red blood cell (RBC) count, hemoglobin, hematocrit, platelet count, white blood cell (WBC) count, WBC differential count (neutrophil, lymphocyte, monocyte, eosinophil, and basophil), and erythrocyte sedimentation rate (ESR)

•Blood chemistry test: total protein, albumin, total bilirubin, AST, ALT, gamma glutamyl transpeptidase (r-GTP), blood urea nitrogen (BUN), creatinine, glucose, alkaline phosphatase (ALP), total cholesterol, triglyceride, uric acid, c-reactive protein (CRP), panel reactive antibody (PRA)[C-1)], virus infection test (human immunodeficiency virus antigen/antibody, hepatitis B surface antibody, anti-hepatitis C virus antibody, venereal disease research laboratory [VDRL])[C-2)]

•Urinalysis: protein (albumin), glucose, ketones, WBC, RBC

d) A serum or urine human chorionic gonadotropin (HCG) test will be performed for women of childbearing age except for those who have been sterilized or are menopausal. Women of childbearing age refer to women who have had their first period, have not been successfully surgically sterilized (via hysterectomy, bilateral tubal ligation, or bilateral oophorectomy), and are not menopausal. Menopause is defined as not having a period for >12 months after the final menstrual period.

e) Test results obtained within 4 weeks after screening can be used.

f) Acute adverse events that occur within 3 days after hUC-O administration will be investigated.

g) Patients will be hospitalized starting 1 day before hUC-O administration and will be monitored throughout the hospitalization period for adverse events.

h) Performed within 3 days and restrict intake of analgesics within 1 day before hUC-O administration.

i) For participants who were withdrawn following the group allocation, the procedures scheduled for the last visit will be performed.

To determine the maximal tolerated dose (MTD) of hUC-O, three participants will be sequentially allocated to a group starting with the low-dose group (1 ´ $10^7$ cells) according to the standard 3+3 dose escalation scheme [23]. The first participants in each dose group will be monitored for acute adverse events including dose-limiting toxicity (DLT) for 3 days after the first hUC-O administration. DLT refers to when adverse events related to hUC-O with grade ≥3 are observed based on the definition from the National Cancer Institute-Common Toxicity Criteria (NCI-CTC) version 5.0 [24]. Another two participants will be assigned to the group when dose-limiting toxicity (DLT) does not occur. Up to 18 patients can be enrolled, depending on the development of DLT.

1. If none of the three participants experiences DLT, the dose will be increased to the next level.
2. If one of the three participants experiences DLT, three participants will be additionally assigned to the same dose group. If one of the six participants (initial three + additional three participants) experience DLT, the dose will be increased to the next level. However, if at least two of the six participants experience DLT, dose escalation will be canceled, and the MTD becomes the previous dose level.
3. If at least two of the three participants experience DLT, dose escalation will be canceled, and the MTD becomes the previous dose level.
4. If one of the three additional participants show DLT, no additional participants will be assigned to a dose group, and current participants will be monitored for safety.

Participants who do not complete the DLT assessment due to reasons independent of DLT are deemed an inadequate basis for making decisions regarding dose escalation and an MTD assessment and can be replaced by participants who are added to the same dose group.

# Safety assessment

Clinically significant abnormal findings from screening or before hUC-O administration (during a screening test) will be recorded as medical history, and those that satisfy the definition of adverse events following hUC-O administration will be recorded as adverse events. The safety assessment will be performed in accordance with the study protocol.

# 1. Adverse event

Participants will be instructed to report any adverse events, and researchers will examine participants for adverse events through regular or additional visits, interviews, and their history. DLT is included as an adverse event. Any adverse events observed will be reported to the IRB throughout the study period.

# 2. Laboratory tests

Laboratory tests will be performed for all participants according to the clinical trial schedule to assess the overall health condition of participants. Participants will be instructed to fast (not allowed to drink beverages except for water or eat food within 8 hours before the test) before visiting the facility for blood collection in preparation for laboratory tests. For screening tests (Visit 1), test results obtained in the last 4 weeks may be used instead. One retest may be performed at the discretion of the researcher during the screening period. If a retest has been performed, the results of the retest will be used to determine whether the participant meets the final inclusion and exclusion criteria. The following parameters are assessed during the laboratory tests.

| | |
|---|---|
| • Blood test | Red blood cell (RBC) count, hemoglobin, hematocrit, platelet count, white blood cell (WBC) count, WBC differential count (neutrophil, lymphocyte, monocyte, eosinophil, and basophil), and erythrocyte sedimentation rate (ESR) |
| • Blood chemistry test | Total protein, albumin, total bilirubin, AST, ALT, gamma glutamyl transpeptidase (r-GTP), blood urea nitrogen (BUN), creatinine, glucose, alkaline phosphatase (ALP), total cholesterol, triglyceride, uric acid, c-reactive protein (CRP), panel reactive antibody (PRA), virus infection test (HIV antigen/antibody, hepatitis B surface antibody, anti-hepatitis C virus antibody, venereal disease research laboratory [VDRL]) |
| • Urinalysis | Protein (albumin), glucose, ketones, WBC, RBC |

Among the blood chemistry tests for viral infections, HIV Antigen/Antibody, hepatitis B Antibody, Anti-hepatitis C antibody, and VDRL tests are performed at Visit 1. Allogeneic immunity (PRA) test is performed at Visit 1 and Visit 5 (Week 12).

# 3. Vital sign

For vital signs, blood pressure, pulse, breathing rate, and body temperature will be measured. Vital signs are measured before the scheduled test for each visit in accordance with the clinical trial schedule. Participants will be directed to relax for 5 minutes and be seated during the measurement.

# 4. Physical examination

Each participant will be physically examined through inspection, palpation, percussion, and auscultation in accordance with the clinical trial schedule to check their health conditions and find any adverse events. Physical examination includes examination of the external appearance, head and neck, chest and lungs, heart, abdomen, urinary and reproductive systems, limbs, musculoskeletal system, nervous system, and lymph nodes.

# 5. ECG test

An ECG test will be performed for all participants at visits 1, 3, 4 and 5. The examiner will determine whether ECG results are normal or abnormal. If the results are abnormal, the examiner will record the

clinical significance of the findings on the case report form.

## Clinical assessment

### 1. Pain VAS assessment [18]

Participants will mark on a scale that ranges from “no pain (0)” to “severe pain (10)” their subjective pain level around hip joint. The examiner will determine the number corresponding to the point marked on the scale and record it to one out of 10 decimal place. To examine the changes in pain VAS at different time points after hUC-O administration, pain VAS assessment will be performed at visits 2 and 5.

### 2. HHS assessment [19]

HHSs will be assessed at visits 2 and 5 to examine the participants’ hip joint function. The highest possible score is 100, and the following domains will be assessed: pain (44 points), gait function (11 points), support devices (11 points), distance walked (11 points), stairs (4 points), putting on shoes (4 points), sitting (5 points), entering public transportation (1 point), presence of deformity (4 points), and hip joint range of motion (5 points).

### 3. WOMAC score assessment [20]

WOMAC scores will be assessed at visits 2 and 5 to examine the changes in WOMAC scores after hUC-O administration and assess participants’ joint function. WOMAC assesses three domains, namely pain, stiffness, and physical function.

## Radiologic assessment

### 1. Measuring changes in necrotic lesion size

To examine changes in the size of a necrotic lesion in the femoral head following hUC-O administration, the Koo and Kim index will be measured on mid-coronal and mid-sagittal MRI images acquired during visits 1 and 5 [25].

### 2. ARCO classification [21]

The ARCO classification is an improved version of the Ficat and Arlert classification based on the presence and severity of femoral head collapse and Steinberg classification based on lesion size and

progression, which are commonly used to stage ONFH. The ARCO classification determines the site, size, and location of necrosis using radiographs and MRI. Two independent examiners will analyze radiographs and MRI of the hip joint during visit 1 and 5 to examine the changes in the ARCO stage following hUC-O administration. They will then classify the patients who show changes in the ARCO stage following hUC-O administration and femoral head collapse using the ARCO classification. Femoral head collapse corresponds to ARCO stage III.

# 3. JIC classification [22]

The JIC classification classifies ONFH based on the location of the lesion. It is a radiographic classification method with three major types of ONFH and is based on the location of the lesion in respect to the weight-bearing surface. Two independent examiners will examine the changes in the JIC stage after hUC-O administration by evaluating radiographs and MRI of the femoral region during visit 1 and 5 and classify the lesions according to the JIC classification.

## Discussion

Cell therapy is becoming more popular as a means to restore deficient local cell populations due to disease or injury. ONFH is associated with a decrease in progenitor cells in the femoral head that can influence bone repair due to alteration of intramedullary vascularity [26, 27]. MSC are multipotent cells that can differentiate into fibroblastic, osteogenic, myogenic, adipogenic, and reticular cells [26, 28] and mainly harvested from bone marrow, adipose tissue, and umbilical cord. Most of the reported studies used bone marrow derived MSC (BMSC) and satisfactory results have been obtained [8, 9, 13, 29, 30]. A previous study with the longest follow-up duration of 25 years which administered BMSC to one side while performing CD in 125 bilateral ONFH patients reported that the BMSC group had significantly lower THA conversion rates than the CD alone group (24% vs 76%, $p<0.001$) [13]. However, considering the natural course of ONFH according to the location and size of the lesion [2], their study did not analyze the lesion before procedure, it is difficult to accurately evaluate the effect of BMSC. Moreover, according to a recent systemic review, standardization is still insufficient for the collection technique, cell-processing, and delivery method of MSC [14]. This study is the first clinical trial to be conducted for early-stage ONFH by differentiating human umbilical cord-derived MSC, especially osteoblasts.

In animal experiments, human umbilical cord-derived stem cells (hUCSC) had an effect applicable to ONFH treatment. Kuang et al. [31] reported that hUCSC inhibited osteocyte apoptosis in steroid-induced ONFH rat models, and You et al. [16] showed that hUCSC promoted angiogenesis in a rat brochopulmonary dysplasia model. In canine experiments comparing hUCSC with MSCs derived from the adipose tissue and bone marrow, hUCSC showed higher osteogenic potential than other cell sources [15]. To the best of our knowledge, there has been one study that applied hUCSC to ONFH patients. Chen et al. [32] performed intra-arterial injection of hUCSC to nine patients with ONFH at ARCO stage 2–3a and reported increased oxygen delivery at 3 days and reduced extent of ONFH at 2 years postoperatively.

However, intra-arterial injection requires a higher dose than injection directly into the lesion, and safety has not yet been established [11].

This study has several strengths. As the first clinical trial to apply hUC-O to ONFH lesion directly, it is possible to evaluate the adverse events and safety of hUC-O and to determine the appropriate cell concentration for treatment. In addition, this study will assess the clinical outcomes and evaluate the extent of necrotic lesions using MRI evaluation before and after treatment. We are also fully aware of the limitations of this study. This study is non-blinded and may have selection and detection biases. Furthermore, due to the short final follow-up duration of 12 weeks after surgery, it is difficult to conclude that hUC-O is effective in the treatment of ONFH..

This Phase I clinical trial aims to identify the safety and therapeutic doses of hUC-O, assess cell regeneration effects, and improve current knowledge of the pathology and treatment of ONFH and the treatment of these types of lesions. We hope that this clinical trial may serve as a cornerstone of future clinical trials to evaluate the effectiveness of hUC-O in ONFH.

# Abbreviations

| | |
|---|---|
| ALP | : Alkaline phosphatase |
| ALT | : Alanine aminotransferase |
| ARCO | : Association research circulation osseous |
| AST | : Aspartate aminotransferase |
| BMI | : Body mass index |
| BMSC | : Bone marrow derived mesenchymal stem cell |
| BUN | : Blood urea nitrogen |
| CD | : Core decompression |
| CRP | : C-reactive protein |
| DLT | : Dose limiting toxicity |
| ECG | : Electrocardiogram |
| ESR | : Erythrocyte sedimentation rate |
| HA | : Hydroxyapatite |
| HCG | : Human chorionic gonadotropin |
| HHS | : Harris hip score |
| HIV | : Human immunodeficiency virus |
| hUC-O | : Human umbilical cord-derived osteoblast |
| hUCSC | : Human umbilical cord-derived stem cells |
| IRB | : Institutional review board |
| IUD | : Intrauterine device |
| IUS | : Intrauterine system |
| IVD | : Investigational new drug |
| JIC | : Japanese investigation committee |
| MRI | : Magnetic resonance imaging |
| MSC | : Mesenchymal stem cells |
| MTD | : Maximal tolerated dose |
| NCI-CTC | : National Cancer Institute-Common Toxicity Criteria |
| ONFH | : Osteonecrosis of the femoral head |
| PRA | : Panel reactive antibody |

| | |
|---|---|
| RBC | : Red blood cell |
| r-GTP | : gamma glutamyl transpeptidase |
| TCP | : Tri-calcium phosphate |
| TGF | : Transforming growth factor |
| THA | : Total hip arthroplasty |
| UNL | : Upper normal limit |
| VAS | : Visual analog scale |
| VDRL | : Venereal disease research laboratory |
| VEGF | : Vascular endothelial growth factor |
| WBC | : White blood cell |
| WOMAC | : Western Ontario & McMaster Universities |

## Declarations

# Ethics approval and consent to participate

The protocol was approved by the IRB of Kyungpook National University Hospital (IRB No. KNUH 2021-07-015) and Korea Food and Drug Administration (No. 10052). We obtained informed consent from all participants in the study.

# Consent for publication

Not applicable.

# Availability of data and materials

Not applicable.

# Competing interests

The authors declare that they have no competing interests.

# Funding

This study supported by Cell Engineering For Origin (CEFO) biotechnology company, Seoul, Korea.

# Authors' contributions

HW and SHB are the major contributor in writing this manuscript as well as the patient recruitment. SYK envisioned the study, participated in its design and coordination. SL and HSP are responsible for the design and implementation of the study. SHB participated in the study design and implementation, involved patient recruitment and performed procedure. All authors read and approved the final manuscript.

# Acknowledgements

Not applicable.

## References

1. Shah KN, Racine J, Jones LC, Aaron RK (2015) Pathophysiology and risk factors for osteonecrosis. Current reviews in musculoskeletal medicine 8:201–209. DOI 10.1007/s12178-015-9277-8
2. Mont MA, Zywiel MG, Marker DR, McGrath MS, Delanois RE (2010) The natural history of untreated asymptomatic osteonecrosis of the femoral head: a systematic literature review. J Bone Joint Surg Am 92:2165–2170. DOI 10.2106/jbjs.i.00575
3. Prokopetz JJ, Losina E, Bliss RL, Wright J, Baron JA, Katz JN (2012) Risk factors for revision of primary total hip arthroplasty: a systematic review. BMC Musculoskelet Disord 13:251. DOI 10.1186/1471-2474-13-251
4. Pierce TP, Jauregui JJ, Elmallah RK, Lavernia CJ, Mont MA, Nace J (2015) A current review of core decompression in the treatment of osteonecrosis of the femoral head. Current reviews in musculoskeletal medicine 8:228–232. DOI 10.1007/s12178-015-9280-0
5. Andronic O, Weiss O, Shoman H, Kriechling P, Khanduja V (2020) What are the outcomes of core decompression without augmentation in patients with nontraumatic osteonecrosis of the femoral head? Int Orthop. DOI 10.1007/s00264-020-04790-9
6. Koo KH, Kim R, Ko GH, Song HR, Jeong ST, Cho SH (1995) Preventing collapse in early osteonecrosis of the femoral head. A randomised clinical trial of core decompression. The Journal of bone and joint surgery British volume 77:870–874
7. Mont MA, Carbone JJ, Fairbank AC (1996) Core decompression versus nonoperative management for osteonecrosis of the hip. Clin Orthop Relat Res:169–178. DOI 10.1097/00003086-199603000-00020
8. Li X, Xu X, Wu W (2014) Comparison of bone marrow mesenchymal stem cells and core decompression in treatment of osteonecrosis of the femoral head: a meta-analysis. International journal of clinical and experimental pathology 7:5024–5030
9. Tabatabaee RM, Saberi S, Parvizi J, Mortazavi SM, Farzan M (2015) Combining Concentrated Autologous Bone Marrow Stem Cells Injection With Core Decompression Improves Outcome for

Patients with Early-Stage Osteonecrosis of the Femoral Head: A Comparative Study. J Arthroplasty 30:11–15. DOI 10.1016/j.arth.2015.06.022

10. Hernandez A, Nuñez JH, Sallent A, Gargallo-Margarit A, Gallardo-Calero I, Barro V (2020) Core Decompression Combined with Implantation of Autologous Bone Marrow Concentrate with Tricalcium Phosphate Does Not Prevent Radiographic Progression in Early Stage Osteonecrosis of the Hip. Clin Orthop Surg 12:151–157
11. Jin H, Xia B, Yu N, He B, Shen Y, Xiao L, Tong P (2012) The effects of autologous bone marrow mesenchymal stem cell arterial perfusion on vascular repair and angiogenesis in osteonecrosis of the femoral head in dogs. Int Orthop 36:2589–2596. DOI 10.1007/s00264-012-1674-7
12. Peng WX, Wang L (2017) Adenovirus-Mediated Expression of BMP-2 and BFGF in Bone Marrow Mesenchymal Stem Cells Combined with Demineralized Bone Matrix For Repair of Femoral Head Osteonecrosis in Beagle Dogs. Cellular physiology and biochemistry: international journal of experimental cellular physiology, biochemistry, and pharmacology 43:1648–1662. DOI 10.1159/000484026
13. Hernigou P, Dubory A, Homma Y, Guissou I, Flouzat Lachaniette CH, Chevallier N, Rouard H (2018) Cell therapy versus simultaneous contralateral decompression in symptomatic corticosteroid osteonecrosis: a thirty year follow-up prospective randomized study of one hundred and twenty five adult patients. Int Orthop 42:1639–1649. DOI 10.1007/s00264-018-3941-8
14. Piuzzi NS, Chahla J, Jiandong H, Chughtai M, LaPrade RF, Mont MA, Muschler GF, Pascual-Garrido C (2017) Analysis of Cell Therapies Used in Clinical Trials for the Treatment of Osteonecrosis of the Femoral Head: A Systematic Review of the Literature. J Arthroplasty 32:2612–2618. DOI 10.1016/j.arth.2017.02.075
15. Kang BJ, Ryu HH, Park SS, Koyama Y, Kikuchi M, Woo HM, Kim WH, Kweon OK (2012) Comparing the osteogenic potential of canine mesenchymal stem cells derived from adipose tissues, bone marrow, umbilical cord blood, and Wharton's jelly for treating bone defects. Journal of veterinary science 13:299–310. DOI 10.4142/jvs.2012.13.3.299
16. You J, Zhou O, Liu J, Zou W, Zhang L, Tian D, Dai J, Luo Z, Liu E, Fu Z, Zou L (2020) Human Umbilical Cord Mesenchymal Stem Cell-Derived Small Extracellular Vesicles Alleviate Lung Injury in Rat Model of Bronchopulmonary Dysplasia by Affecting Cell Survival and Angiogenesis. Stem cells and development 29:1520–1532. DOI 10.1089/scd.2020.0156
17. Hoang DH, Nguyen TD, Nguyen HP, Nguyen XH, Do PTX, Dang VD, Dam PTM, Bui HTH, Trinh MQ, Vu DM, Hoang NTM, Thanh LN, Than UTT (2020) Differential Wound Healing Capacity of Mesenchymal Stem Cell-Derived Exosomes Originated From Bone Marrow, Adipose Tissue and Umbilical Cord Under Serum- and Xeno-Free Condition. Frontiers in molecular biosciences 7:119. DOI 10.3389/fmolb.2020.00119
18. Hawker GA, Mian S, Kendzerska T, French M (2011) Measures of adult pain: Visual Analog Scale for Pain (VAS Pain), Numeric Rating Scale for Pain (NRS Pain), McGill Pain Questionnaire (MPQ), Short-Form McGill Pain Questionnaire (SF-MPQ), Chronic Pain Grade Scale (CPGS), Short Form-36 Bodily

Pain Scale (SF-36 BPS), and Measure of Intermittent and Constant Osteoarthritis Pain (ICOAP). Arthritis Care Res (Hoboken) 63 Suppl 11:S240-252. DOI 10.1002/acr.20543

19. Harris WH (1969) Traumatic arthritis of the hip after dislocation and acetabular fractures: treatment by mold arthroplasty. An end-result study using a new method of result evaluation. J Bone Joint Surg Am 51:737–755
20. Bellamy N, Buchanan WW, Goldsmith CH, Campbell J, Stitt LW (1988) Validation study of WOMAC: a health status instrument for measuring clinically important patient relevant outcomes to antirheumatic drug therapy in patients with osteoarthritis of the hip or knee. The Journal of rheumatology 15:1833–1840
21. Yoon BH, Mont MA, Koo KH, Chen CH, Cheng EY, Cui Q, Drescher W, Gangji V, Goodman SB, Ha YC, Hernigou P, Hungerford MW, Iorio R, Jo WL, Jones LC, Khanduja V, Kim HKW, Kim SY, Kim TY, Lee HY, Lee MS, Lee YK, Lee YJ, Nakamura J, Parvizi J, Sakai T, Sugano N, Takao M, Yamamoto T, Zhao DW (2020) The 2019 Revised Version of Association Research Circulation Osseous Staging System of Osteonecrosis of the Femoral Head. J Arthroplasty 35:933–940. DOI 10.1016/j.arth.2019.11.029
22. Sugano N, Atsumi T, Ohzono K, Kubo T, Hotokebuchi T, Takaoka K (2002) The 2001 revised criteria for diagnosis, classification, and staging of idiopathic osteonecrosis of the femoral head. J Orthop Sci 7:601–605. DOI 10.1007/s007760200108
23. Neuenschwander B, Branson M, Gsponer T (2008) Critical aspects of the Bayesian approach to phase I cancer trials. Statistics in medicine 27:2420–2439. DOI 10.1002/sim.3230
24. (2017) Common Terminology Criteria for Adverse Events (CTCAE) version 5.0. In. National Cancer Institute.
25. Koo KH, Kim R (1995) Quantifying the extent of osteonecrosis of the femoral head. A new method using MRI. The Journal of bone and joint surgery British volume 77:875–880
26. Koo KH, Dussault RG, Kaplan PA, Ahn IO, Kim R, Devine MJ, Cui Q, Cho SH, Wang GJ (1999) Fatty marrow conversion of the proximal femoral metaphysis in osteonecrotic hips. Clin Orthop Relat Res:159–167. DOI 10.1097/00003086-199904000-00021
27. Hernigou P, Poignard A, Manicom O, Mathieu G, Rouard H (2005) The use of percutaneous autologous bone marrow transplantation in nonunion and avascular necrosis of bone. The Journal of bone and joint surgery British volume 87:896–902. DOI 10.1302/0301-620x.87b7.16289
28. Liu XN, Yang CJ, Kim JE, Du ZW, Ren M, Zhang W, Zhao HY, Kim KO, Noh KC (2018) Enhanced Tendon-to-Bone Healing of Chronic Rotator Cuff Tears by Bone Marrow Aspirate Concentrate in a Rabbit Model. Clin Orthop Surg 10:99–110. DOI 10.4055/cios.2018.10.1.99
29. Zhao D, Cui D, Wang B, Tian F, Guo L, Yang L, Liu B, Yu X (2012) Treatment of early stage osteonecrosis of the femoral head with autologous implantation of bone marrow-derived and cultured mesenchymal stem cells. Bone 50:325–330. DOI 10.1016/j.bone.2011.11.002
30. Piuzzi NS, Chahla J, Schrock JB, LaPrade RF, Pascual-Garrido C, Mont MA, Muschler GF (2017) Evidence for the Use of Cell-Based Therapy for the Treatment of Osteonecrosis of the Femoral Head:

A Systematic Review of the Literature. J Arthroplasty 32:1698–1708. DOI 10.1016/j.arth.2016.12.049

31. Kuang MJ, Huang Y, Zhao XG, Zhang R, Ma JX, Wang DC, Ma XL (2019) Exosomes derived from Wharton's jelly of human umbilical cord mesenchymal stem cells reduce osteocyte apoptosis in glucocorticoid-induced osteonecrosis of the femoral head in rats via the miR-21-PTEN-AKT signalling pathway. International journal of biological sciences 15:1861–1871. DOI 10.7150/ijbs.32262
32. Chen C, Qu Z, Yin X, Shang C, Ao Q, Gu Y, Liu Y (2016) Efficacy of umbilical cord-derived mesenchymal stem cell-based therapy for osteonecrosis of the femoral head: A three-year follow-up study. Molecular medicine reports 14:4209–4215. DOI 10.3892/mmr.2016.5745

# Figures

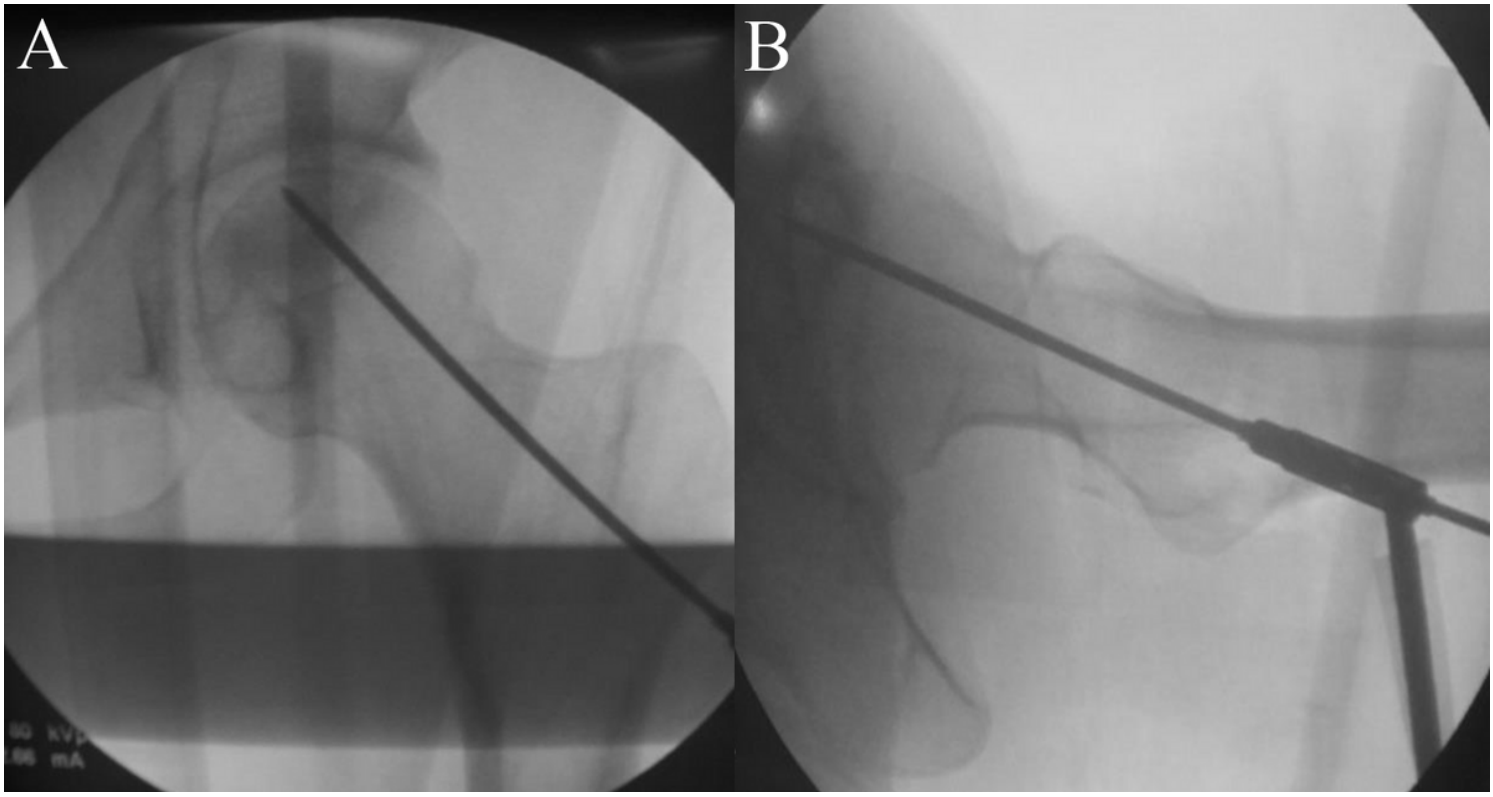


**Figure 1**

A guide pin is targetted and inserted under the fluoroscopic guidance toward necrotic area for core decompression and mesenchymal stem cell implantation. (A) Anteriorposterior view (B) Lateral view.

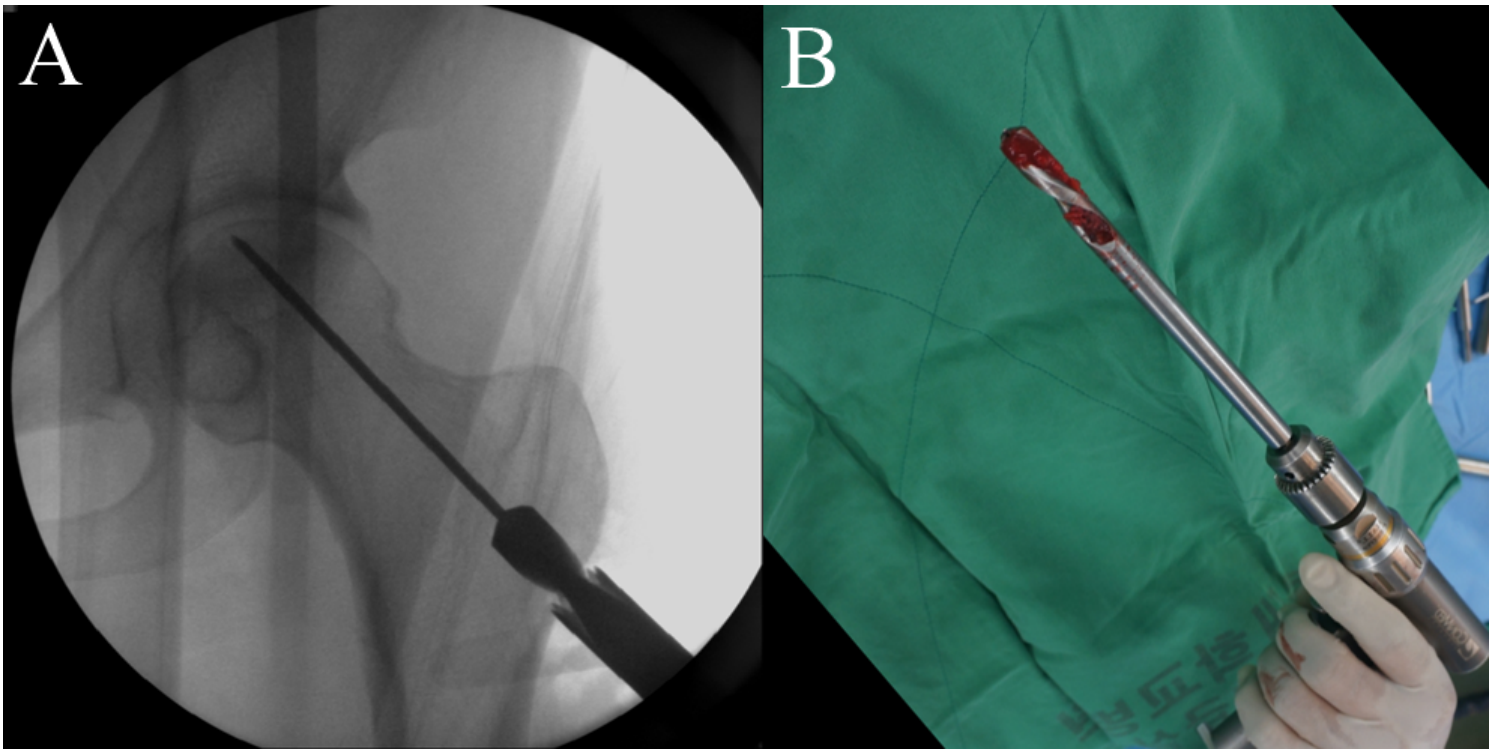


**Figure 2**

Entry hole is created using reamer along the guide pin (A) and autogenous bone chip during reaming is collected (B).

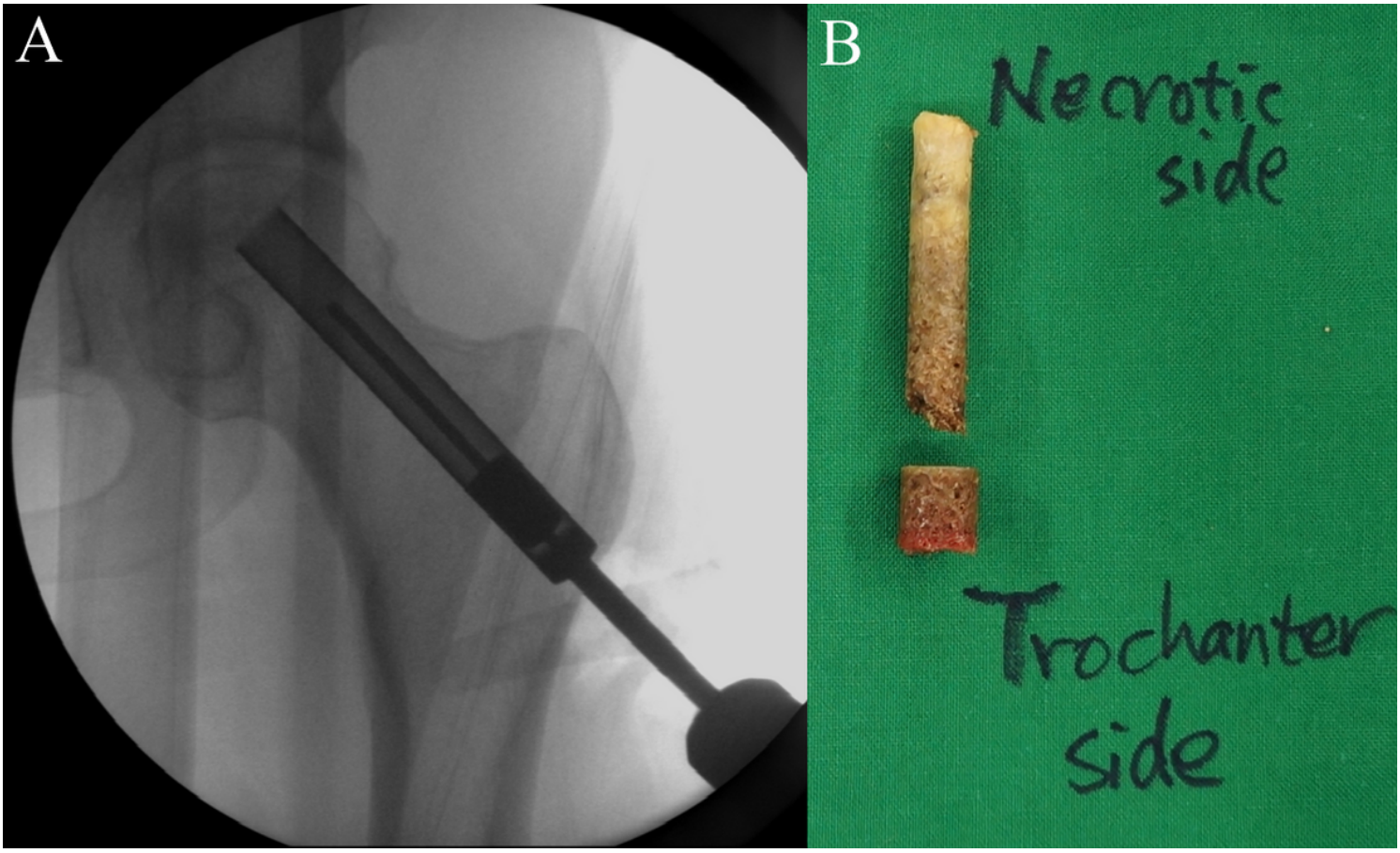

## Figure 3

A tunnel is created for core decompression and mesenchymal stem cell insertion (A). During this procedure, autogenous bone block is collected, of which necrotic side will be sent for pathologic evaluation and trochanteric side will be implanted as a bone plug after stem cell insertion (B).

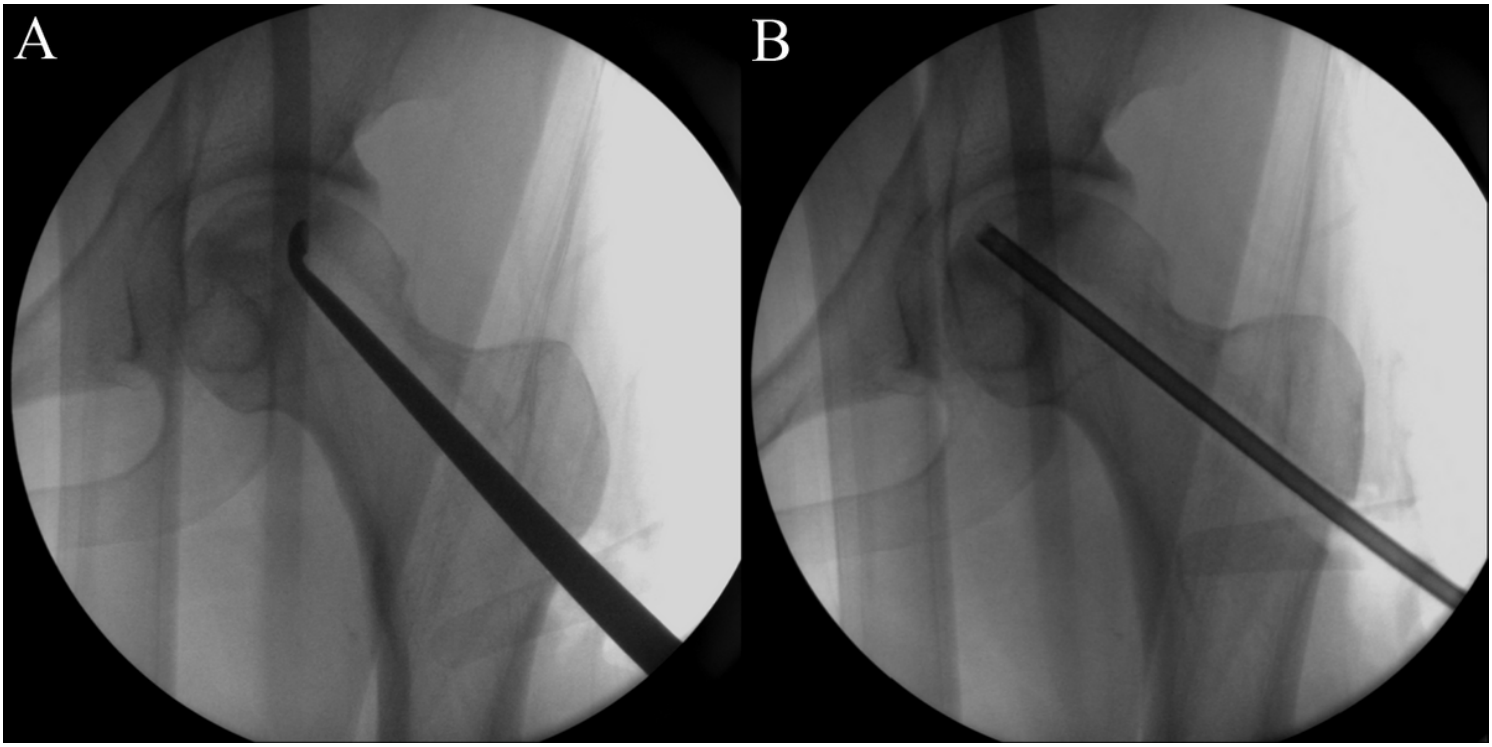


## Figure 4

A curette is inserted to remove necrotic bone debris (A) followed by washing the lesion site (B).

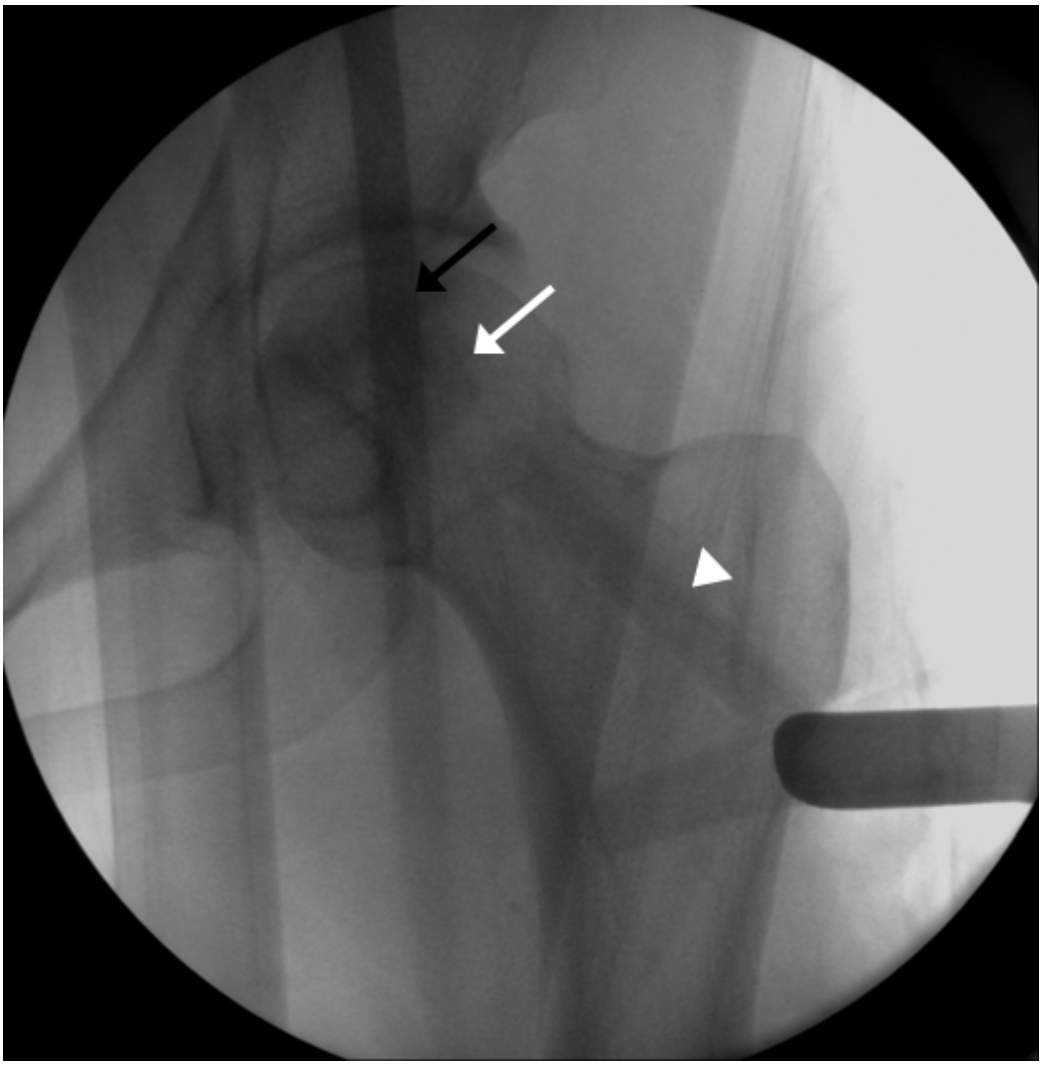

**Figure 5**

Mixture of autogenous bone chip, mesenchymal stem cell, thrombin glue, collagen putty, hydroxyapatite and tri-calcium phosphate is implanted into the lesion (black arrow) and autogenous bone block is inserted into remaining space and the proximal portion of the bone tunnel (white arrow). If there is still large amount of space remained in distal portion of the tunnel, hydroxyapatite and tri-calcium phosphate block may be inserted (arrowhead).