Femoral periosteal reaction in the mid-piece of the prosthesis: a potential predictor of hip prosthetic joint infection

Zijie Zhang
Fujian Medical University
Zida Huang
First Affiliated Hospital of Fujian Medical University
Wenbo Li
First Affiliated Hospital of Fujian Medical University
Xinyu Fang
First Affiliated Hospital of Fujian Medical University
Wenming Zhang (zhangwm0591@fjmu.edu.cn)
https://orcid.org/0000-0003-1567-7279

Research article

Keywords: Periosteal reaction, Hip prosthetic joint infection, X-ray, Serum inflammation index, Diagnosis

Posted Date: December 23rd, 2019

DOI: https://doi.org/10.21203/rs.2.19556/v1

Abstract

[Background] Early diagnosis of HPJI is important. Periosteal reaction has been shown to diagnose osteomyelitis and bone tumours; however, research on artificial joint infections is not clear. The purpose of this study was to analyse the diagnostic possibility of FPR on X-ray films for HPJI.

[Methods] From January 2017 to June 2019, 105 patients who underwent artificial hip joint revision surgery were retrospectively included in the single joint surgery centre. Based on the description by the MSIS in 2013 and exclusion of patients with bone tumour revisions, 66 patients were reviewed and divided into the PJI group and aseptic failure (AF) group. The clinical outcome and radiographic results were examined by two experienced joint surgeons independently on hip X-ray images in all cases. Sensitivity, specificity, PPV and NPV were calculated for FPR in HPJI, and the imaging results were compared with those of serology and bacterial culture.

[Results] A total of 16 patients in the PJI group were positive for FPR with appearance in the mid-piece and distal part, while 6 patients in the AF group (43.3% vs 26.1%, p = 0.04) were positive for FPR. Only 1 patient in the AF group had a mid-piece FPR, and the rest were at the distal end. Separated measurements were unidimensional (Kappa value = 0.89). The process of FPR-positive patients in the PJI group was 13 ± 26.1 months, and it was 9.83 ± 8.2 months in the AF group, and the difference was not statistically significant (p = 0.67). There was no connection between the responsible pathogens and FPR in the PJI group. The sensitivity, specificity, PPV and NPV for FPR at any section were 43.2%, 79.3%, 72.7% and 52.7%, respectively. The mid-piece FPR improved by 43.2%, 96.5%, 94.1% and 57.1%, respectively. Combined with elevated serum CRP/ ESR, specificity and PPV could reach 100%.

[Conclusion] Preoperative X-ray examinations revealed that the mid-piece FPR requires a high degree of suspicion of PJI. If patients have elevated serum CRP/ESR at the same time, joint puncture and other methods should be used to obtain culture results to confirm the diagnosis.

Background

Prosthetic joint infection is a catastrophic complication after joint replacement. It has a relatively high disability and mortality rate(1), which will seriously increase the patient's mental and economic burden and bring great challenges to clinicians(2, 3). The key to treatment lies in early diagnosis(4). To date, many versions of PJI diagnosis consensus in the world have been published and greatly helped clinicians create diagnosis and treatment programmes accurately(5, 6).

Periosteal reaction is a physiological phenomenon in which a patient's periosteum undergoes subperiosteal osteogenesis under external stimuli (trauma, infection, tumour, etc.), and the periosteum can show a variety of different reaction forms, shapes and locations under imaging conditions(7–9). Previous studies have shown that the periosteal reaction has a high correlation and diagnostic value for a variety of bone diseases, including osteomyelitis and bone tumours(10, 11).

Current studies on the diagnosis of PJI focused on the improvement of traditional testing items such as culture and laboratory tests and emerging molecular diagnostic techniques. Nevertheless, there are few relative reports in imaging, especially for periosteal reactions. X-ray film, as the most commonly used impact diagnosis technology in orthopaedics, can roughly evaluate bone quality, prosthesis information, and various human pathological processes, including osteoporosis and the Codman triangle. The studies did not clearly point out the specific connection between the periosteal reaction and hip PJI, so its practical application in diagnosis is still undefined.

Our study retrospectively collected case data and X-ray films in a single joint revision centre to summarize the practical diagnostic value of femoral periosteal reaction (FPR) for HPJI and further analysed the regulation of its appearance.

Methods

General information

A total of 105 patients who underwent hip revision surgery were reviewed retrospectively from January 2016 to June 2019 in our institution. Patients who underwent revision surgery on two sides were selected only for the first one, and patients who underwent multiple revision surgery were selected for the primary side.

This study obtained informed consent from our ethics committee and all patients.

Sample collection

The criteria for exclusion were as follows: (1) patients undergoing primary replacement surgery for joint infection, bone tumours, etc, (2) patients infected after internal fixation of fracture, (3) patients with superficial soft tissue infection around the hip joint, (4) undefined prosthetic joint infection, (5) unavailable imaging data, and (6) arthroplasty performed for hip tuberculosis.

Medical records

Several data items were collected, including pathology, pathogenic bacteria based on culture, CRP, ESR, synovial fluid polymorphonuclear, intraoperative pus, and data such as gender, age, BMI, intraoperative pathological results, and X-ray films (both hips) orthotopic film were reviewed. All data were collected by two professional medical researchers through a double-blind method, and the patients’ imaging examination was analysed and finalized independently.

Group

We divided 66 patients into two groups according to the 2013 international consensus by MSIS(12) and Tsukayama classification(13): the chronic hip PJI group and the AF group.

Definition

On a standard hip joint scan, the range from 2 cm above the lower edge of the femoral prosthesis to the end was defined as the end-piece, and the rest of the prosthesis was defined as the mid-piece (shown in Fig. 1). Researchers defined serum CRP > 8 g / ml and ESR > 36 mm / H as positive indicators of inflammation.

Statistical analysis

The measurement data used the Kolmogorov-Smirnov test to determine whether the data conformed to a normal distribution. The age and BMI between the groups that met the normal distribution were compared using two independent sample t-tests. According to gender, the periosteal reaction positive rate, sensitivity, and specificity were compared between groups by the χ^2 test. For cases where the theoretical frequency was less than 5, Fisher's exact test was used. The simple Kappa coefficient was used to test the results obtained by two professional researchers for consistency. Statistical tests were carried out using SPSS software (SPSS Inc., Chicago, IL) with statistical significance set at $P < .05$.

Results

General situation

After sample collection, a total of 66 patients were included in our study. The study was divided into 37 cases in the hip PJI group and 29 cases in the AF group. There were no significant differences in demographic characteristics between the different groups (Table 1). Sixteen cases of positive periosteal reactions in the PJI group and 6 cases in the AF group were counted. The incidence of periosteal reaction was significantly different between the groups (Table 2) (43.3% vs 26.1%, $p = 0.04$). The average time for a positive periosteal reaction in the PJI group was 13 ± 26.1 months, compared with 9.83 ± 8.2 months in the AF group, which is not statistically significant ($p = 0.67$).

Case features of AF group

A total of 6 patients in the AF group had radiographic X-rays showing FPR. The details of the cases and the serological results are shown in Table 3. Among them, A3 is the only case where periosteal hyperplasia was observed at the mid-piece of the prosthesis as well as the end-piece (Fig. 2 1c). In the remaining cases, the periosteum lies at the end of the prosthesis, which is characterized as a circumscribed reaction. Most of the periosteal responses were reactive hyperplasia because of stress

concentration at the end of the prosthesis, showing uneven thickness of the periosteum. The lengths ranged from 2 to 4 cm.

Case features of the PJI group

A total of 16 patients in the PJI group showed femoral periosteal responses. The basic information, serology, and culture results of the patients are described in Table 4. All patients in the PJI group, including the end-piece of the prosthesis, showed a femoral periosteal response in the mid-piece of the prosthesis. The morphology of the periosteum was different from that in the AF group, such as even thickness, layered growth, and worm-eaten hyperplasia (Fig. 3). The length and thickness of the hyperplasia were also different. According to the culture results of pathogenic bacteria, including Staphylococcus aureus, epistasis, etc., researchers found that various types of pathogenic bacteria can cause patients to have a positive periosteal response in imaging.

FPR and serology in the diagnosis of HPJI

In this study, the overall positive rate of the periosteal reaction was not high, only 33.3%. When radiology was used to test for a positive femoral periosteal response, the diagnostic sensitivity was 43.2%, and the specificity was 79.3%. In addition, researchers found that the position of the periosteal reaction relative to the prosthesis was significantly different between the infected group and the non-infected group. According to the positive mid-piece periosteal reaction, its specificity and PPV can rise to 96.5% and 94.1%, respectively. The sensitivity and specificity of the serologic test, which are consistent with the results of previous studies, are listed in Table 5.

Research of the combined diagnostic test found that FPR with positive serological changes can improve diagnostic specificity to 100%. At the same time, due to the differences in the distribution of periosteal reactions, mid-piece FPR should be introduced with a positive serological test as the standard, and the specificity and positive predictive value will rise to 100%, which could diagnose the presence of PJI preoperatively.

Discussion

In our study, the most important finding was that the specificity of mid-piece FPR for PJI was 96.5%, and the PPV was 94.1%. When combined with elevated serum CRP / ESR, we doubted whether there was an infection. The results of this study suggest that FPR has certain diagnostic value in hip joint prosthesis infection.

To date, multiple research institutions and orthopaedic associations throughout the world have released a number of PJI diagnostic consensuses and still make every effort to improve criteria, which are focused on culture and involve laboratory tests of joint fluid/periprosthetic tissues/retrieved implants(6, 14, 15).

For conventional radiography, limited diagnostic research has been published for PJI, and it is more commonly used in the treatment stage to provide some degree of confidence in planning the extent of bone resection needed during resection arthroplasty(16, 17). The presence of osteolytic lesions and loosening and effusion of periprosthetic soft tissues indicate the presence of infection around the prosthesis(14, 18, 19). Esposito et al. found that bone erosion and new bone formation may indicate the presence of PJI in 3 to 6 months after surgery(20). Tigges et al. suggest that the diagnostic value of imaging can be considered very limited because no obvious abnormality was observed in most of the radiography imaging of 20 HPJI patients retrospectively(21). Kapadia et al. believe that the presence of wide radiolucency at the interface between bone and implants (cement-bone interface) and the presence of bone destruction may also indicate infection but have little practical effect on the diagnosis of disease(22). Periosteal response exists as a manifestation of periosteal inflammatory changes. Cytesval et al. have shown that imaging changes of bone abnormalities are significant in the diagnosis of hip joint prosthesis implantation, but the diagnostic value of joint infections remains uncertain(23). However, encouragingly, our study found that the periosteal reaction has a high specificity in HPJI, especially when this result is combined with a positive result of laboratory serology, which can obtain a very reliable diagnostic specificity and PPV. It is of great help in the early diagnosis of joint infection in clinics.

The periosteal reaction is a process in which a patient's periosteum is subjected to various stimuli, presenting as activity of osteoblasts in the inner layer of the bone increases and growth of periosteal new bone. There are numerous kinds of morphologies under the influence of different external stimuli, considering as an imaging feature of bone or surrounding and playing an extremely important role in identifying the location, characterization, and extent of lesions. All patients in our study were classified as chronic infections according to the Tsukayama classification. A number of studies in recent years have shown that chronic infections are mostly related to biofilm formation and immune escape(24, 25), and long-lasting local inflammation causes periosteal hyperplasia of the inner and outer cortical bone presented as layered or dense periosteal appearance(26, 27). In addition, studies in the infection group showed that not all patients had a positive periosteal reaction, which was similar to previous studies(21, 23, 28). X-ray imaging results can only reflect mineralization or periosteal osteogenesis with calcium salt deposition. Some studies have shown that periosteal mineralization takes approximately 10–21 days(29), which is why the neonatal periosteal reaction would be easily ignored by doctors. Therefore, patients with acute prosthetic infection in the acute stage are mostly normal on imaging or only have displacement of the prosthesis. In general, the periosteal reaction caused by infection is mostly attributed to pus infiltration under the periosteal stimulation(10). The severity of the infection is related to the bacterial virulence and local immune microenvironment.

On the other hand, the overall positive rate of periosteal reaction in patients was low, only approximately 33%, but some patients in the non-infected group also observed its existence, which led to a decrease in the sensitivity and specificity. However, through demographic characteristics and imaging tests of the cases, we found that the FPR-positive cases in the non-infected group were all overweight women approximately 50 years old, except for one case (Fig. 1c), and most of the reactions were located at the end-piece of the prosthesis characterized by expansive hyperplasia. Pawel Szulc et al. showed that

cortical bone loss was noticeable in perimenopausal women, while it was relatively slow in men(30). The bone-prosthesis-cement interface is formed at the end of the prosthesis after joint replacement, which belongs to the stress concentration point. By strong mechanical stimulation, local microfracture arises, and the periosteal reaction is obviously concentrated without spreading upward to the upper and middle parts of the prosthesis(31, 32). In addition, the routine laboratory tests in the non-infected group did not show significant positive changes, which can be ruled out by combined diagnosis.

There are several limitations in our research. First, our research is limited by the inherent shortcomings of retrospective studies. It is a single-centre case review, so the number of patients included in the study is relatively small. Although we set up a control group for comparative studies, the overall positive rate of periosteum response is not high. The study set up a double-blind imaging test to collect image data, but it could still not avoid the existence of selective migration. Second, although X-ray imaging has better spatial resolution, it is more inexpensive and much more convenient. Compared with CT scan, imaging still has many disadvantages, such as unclear resolution and easy missed diagnosis of periosteal reaction. Studies have shown that multi-detector CT can better compensate for the above disadvantages(33). In the future, research directions may need to use more advantageous imaging methods to assist in diagnosis.

Conclusion

In summary, our research indicates that when FPR appears on radiographic film, especially when it exists near the mid-piece of the femoral prosthesis with elevated serum CRP / ESR, suspected infection must be taken into account. Further examination would be performed to confirm the diagnosis in time.

Abbreviations

HPJI:Hip prosthetic joint infection; FPR:Femoral periosteal reaction; MSIS:Musculoskeletal Infection Society; AF:Aseptic failure; CRP:C-reaction protein; ESR:Erythrocyte sedimentation rate; PPV:Positive predictive value; NPV:Negative predictive value

Declarations

Ethics approval and consent to participate

This study was approved by the Ethics Committee of First Affiliated Hospital of Fujian Medical University, and participants provided informed consent before commencing the present study.

Consent for publication

Not applicable.

Availability of data and materials

The datasets supporting the conclusions of this article are included within the article.

Competing interests

The authors declare that they have no competing interests.

Funding

This study is supported by grants from the Fujian Education and Scientific Research Projects for Young Teachers (JAT170241), Natural Science Foundation of Fujian Province (2018I0006 2018Y4003, 2019I0011), and Startup Fund for scientific research, Fujian Medical University (2018QH1066).

Author contributions

ZZ and ZH designed the study and performed the data analysis. ZZ wrote the manuscript. ZZ, WL, XY, and WZ participated in the data collection. All authors read and approved the final manuscript.

Acknowledgements

Not applicable.

References

1. K H, M P, E J. The incidence of late prosthetic joint infections: a registry-based study of 112,708 primary hip and knee replacements. Acta orthopaedica. 2015;86(3):321-5.
2. MB V, AL W, WS H, CD S, DJ B. The Chitranjan Ranawat Award: Long-term survivorship and failure modes of 1000 cemented condylar total knee arthroplasties. Clinical orthopaedics and related research. 2006;452(undefined):28-34.
3. JP M-C, JP H-E, AS AG, A SV, A M-R. Prospective quality of life assessment after hip and knee arthroplasty: short- and mid-term follow-up results. Arthroplasty today. 2017;3(2):125-30.
4. KJ B, K O, E L, DJ B, TP V, SM K, et al. Estimating risk in Medicare patients with THA: an electronic risk calculator for periprosthetic joint infection and mortality. Clinical orthopaedics and related research. 2013;471(2):574-83.
5. J A, J C, J B-E, N B, G B, J C, et al. Executive summary of management of prosthetic joint infections. Clinical practice guidelines by the Spanish Society of Infectious Diseases and Clinical Microbiology (SEIMC). Enfermedades infecciosas y microbiologia clinica. 2017;35(3):189-95.
6. J P, TL T, K G, C H, C DV, AF C, et al. The 2018 Definition of Periprosthetic Hip and Knee Infection: An Evidence-Based and Validated Criteria. The Journal of arthroplasty. 2018;33(5):1309-14.e2.
7. X Z, HA A, RJ OK, RE G, EM S. A perspective: engineering periosteum for structural bone graft healing. Clinical orthopaedics and related research. 2008;466(8):1777-87.
8. MR A, JM H, DB B. Periosteum: biology, regulation, and response to osteoporosis therapies. Bone. 2004;35(5):1003-12.

9. BD R, JE M, DE S. Radiologic and pathologic analysis of solitary bone lesions. Part II: periosteal reactions. Radiologic clinics of North America. 1981;19(4):749-83.
10. D B, R K, MH L-P, M A, C P-C, JD L, et al. Periosteum: characteristic imaging findings with emphasis on radiologic-pathologic comparisons. Skeletal radiology. 2015;44(3):321-38.
11. JR D. The periosteum: what is it, where is it, and what mimics it in its absence? Skeletal radiology. 2010;39(4):319-23.
12. New definition for periprosthetic joint infection. The Journal of arthroplasty. 2011;26(8):1136-8.
13. DT T, VM G, R K. Diagnosis and management of infection after total knee arthroplasty. The Journal of bone and joint surgery American volume. 2003;null(undefined):S75-80.
14. EF B, SS K, TJ K, RO D, AF W, SK S, et al. 2015 Infectious Diseases Society of America (IDSA) Clinical Practice Guidelines for the Diagnosis and Treatment of Native Vertebral Osteomyelitis in Adults. Clinical infectious diseases : an official publication of the Infectious Diseases Society of America. 2015;61(6):e26-46.
15. AM C, AJ S, M J, A P, MA C, J P. Musculoskeletal Infection in Pediatrics: Assessment of the 2018 International Consensus Meeting on Musculoskeletal Infection. The Journal of bone and joint surgery American volume. 2019;undefined(undefined):undefined.
16. W Z. Infection and musculoskeletal conditions: Prosthetic-joint-associated infections. Best practice & research Clinical rheumatology. 2006;20(6):1045-63.
17. D Z, L W, S T, P B, T P, GF vS-S, et al. Diagnostic work-up strategy for periprosthetic joint infections after total hip and knee arthroplasty: a 12-year experience on 320 consecutive cases. Patient safety in surgery. 2015;9(undefined):20.
18. BD S. The Diagnosis of Periprosthetic Joint Infection. The Journal of arthroplasty. 2015;30(6):908-11.
19. A DA, ML B. The diagnosis of periprosthetic infection. The open orthopaedics journal. 2013;7(undefined):178-83.
20. S E, S L. Prosthetic joint infections: microbiology, diagnosis, management and prevention. International journal of antimicrobial agents. 2008;32(4):287-93.
21. S T, RG S, JR R. Appearance of septic hip prostheses on plain radiographs. AJR American journal of roentgenology. 1994;163(2):377-80.
22. BH K, RA B, JA D, J F, A B, MA M. Periprosthetic joint infection. Lancet (London, England). 2016;387(10016):386-94.
23. C C, V H, MP S, FM L, P M, P T. Painful infection at the site of hip prosthesis: CT imaging. Radiology. 2002;224(2):477-83.
24. A T, TH T, S V, K K, T H, J P, et al. Treating periprosthetic joint infections as biofilms: key diagnosis and management strategies. Diagnostic microbiology and infectious disease. 2015;81(3):192-200.
25. TL T, MM G, MM K, MG M, AF C. Should Preoperative Antibiotics Be Tailored According to Patient's Comorbidities and Susceptibility to Organisms? The Journal of arthroplasty. 2017;32(4):1089-94.e3.

26. TT M. Bone tumors and tumorlike conditions: analysis with conventional radiography. Radiology. 2008;246(3):662-74.
27. AE W, TA S, A S. Imaging of periosteal reactions associated with focal lesions of bone. Clinical radiology. 2005;60(4):439-56.
28. O A, L C, CS R. Imaging evaluation of complications of hip arthroplasty: review of current concepts and imaging findings. Canadian Association of Radiologists journal = Journal l'Association canadienne des radiologistes. 2013;64(4):306-13.
29. S K, IF A, MJ K, G H, MM L. Lesions of juxtacortical origin (surface lesions of bone). Skeletal radiology. 1993;22(5):337-57.
30. P S, E S, F D, E S-R, PD D. Bone fragility: failure of periosteal apposition to compensate for increased endocortical resorption in postmenopausal women. Journal of bone and mineral research : the official journal of the American Society for Bone and Mineral Research. 2006;21(12):1856-63.
31. JA M, MJ S. Comparing histological, vascular and molecular responses associated with woven and lamellar bone formation induced by mechanical loading in the rat ulna. Bone. 2011;48(2):250-8.
32. SA F, G E, DM C, SM R-A. Periosteal response in translation-induced bone remodelling. Journal of anatomy. 1990;171(undefined):69-84.
33. KV R, SS A, UC G. Multi-detector computed tomography in evaluating locally aggressive and malignant bone tumours. Journal of clinical and diagnostic research : JCDR. 2015;9(4):TC10-3.

Tables

Due to technical limitations, Tables 1-6 are provided as Supplementary Material.

Figures

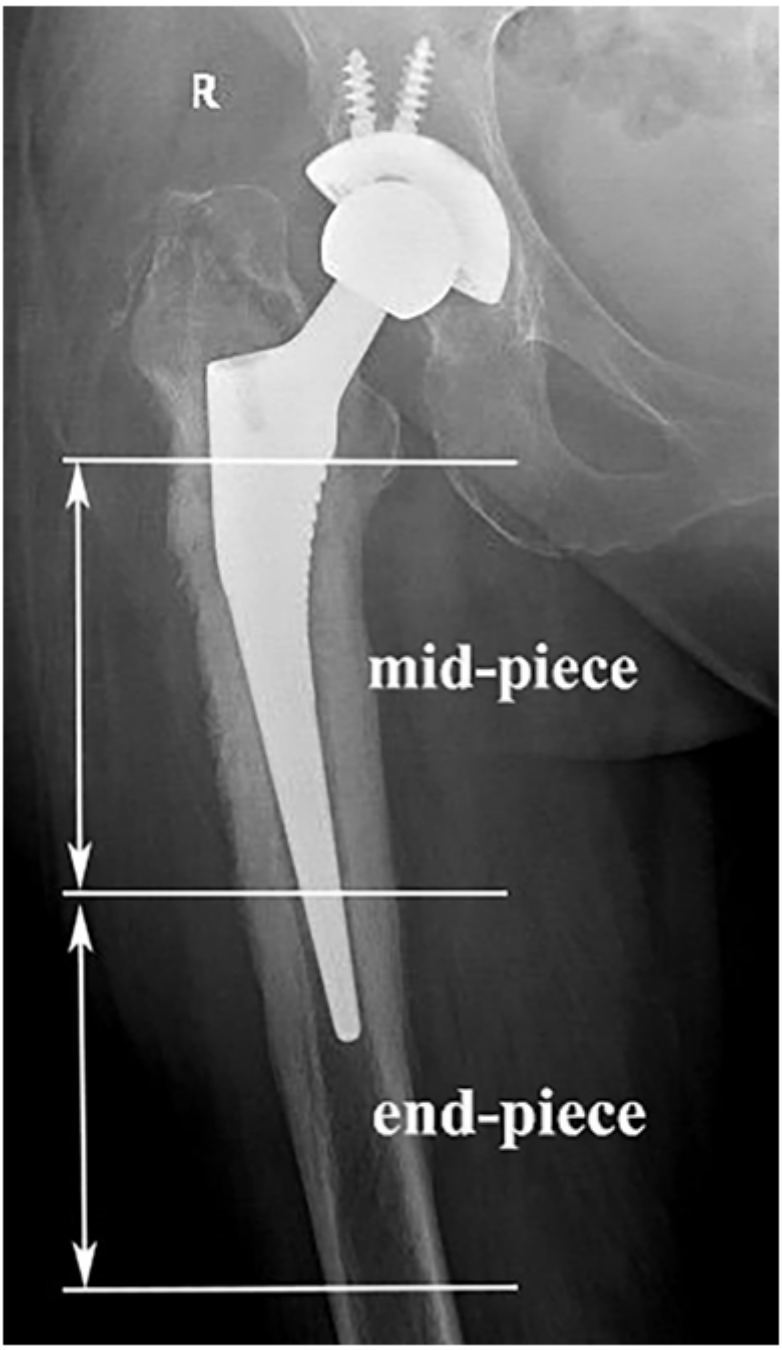

Figure 1

Femoral periosteal reaction and definition of its position

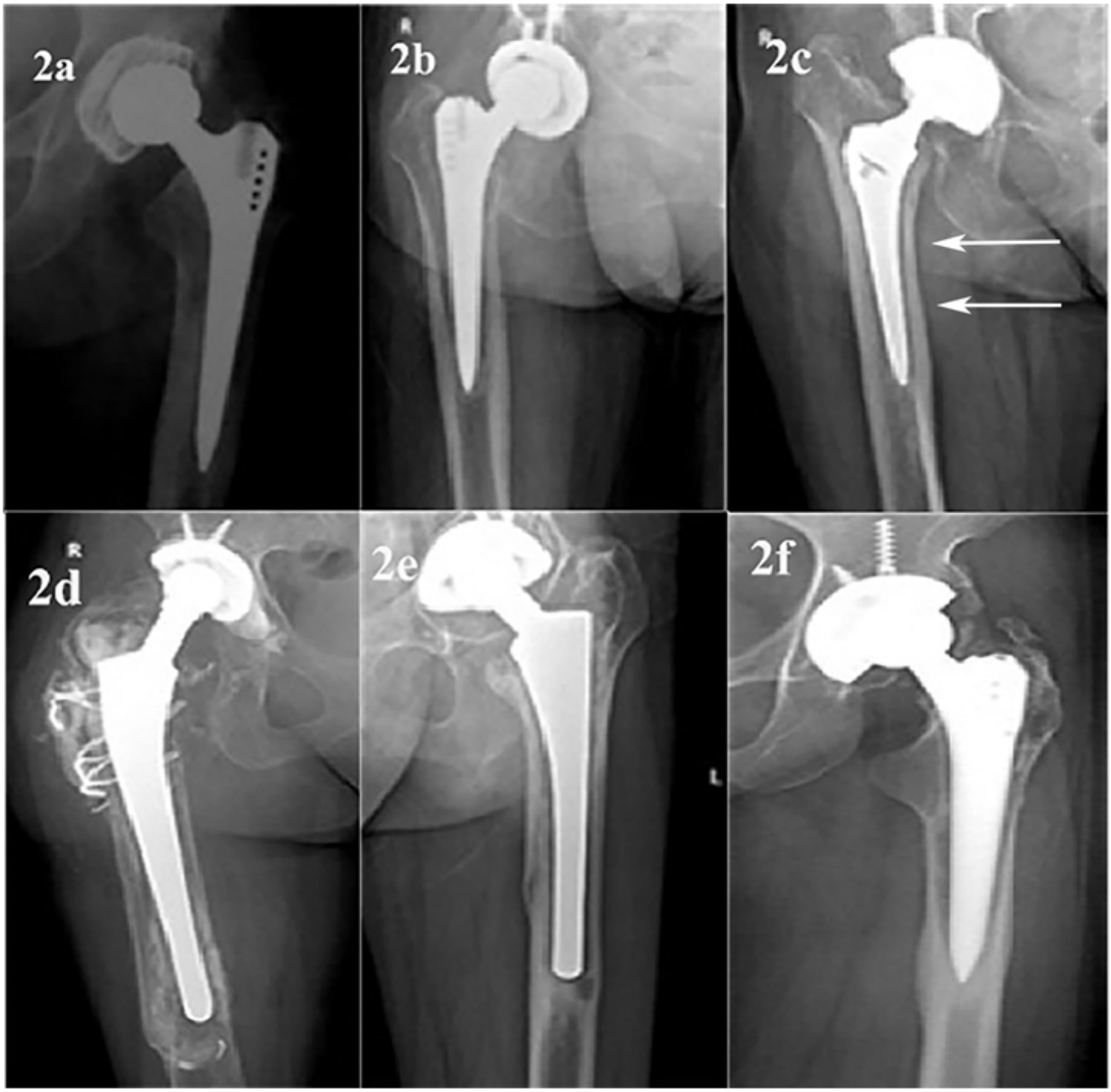

Figure 2

X-ray images of the periosteal reaction for A1-A6 in the AF group. Figure 1a-1f shows periosteum hyperplasia at the end of the prosthesis, and 1c shows the periosteal reaction located in the middle of the prosthesis in the AF group.

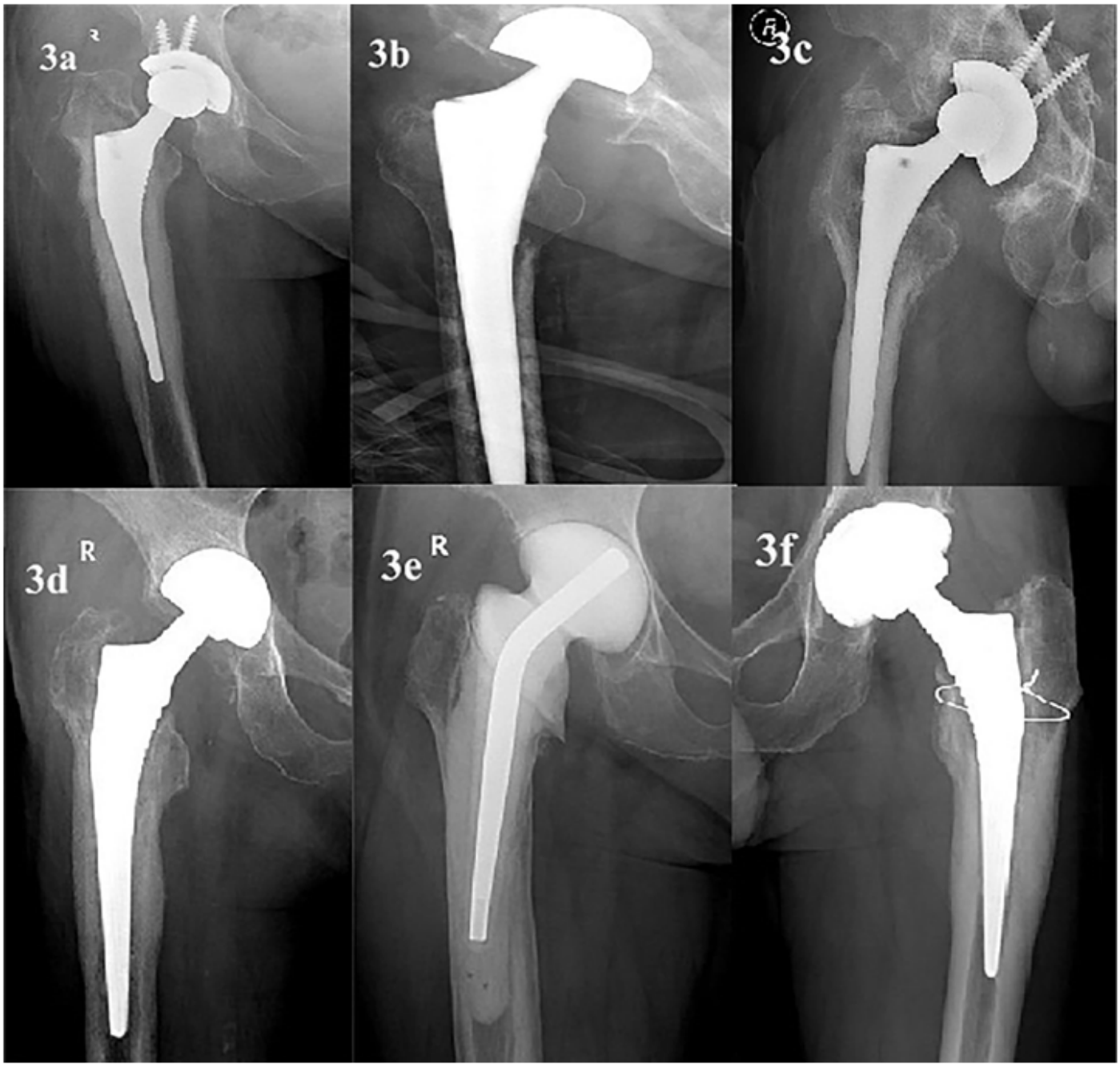

Figure 3

X-ray images of the periosteal reaction in A1-A6 in the PJI group. Figure 3a-3f shows that periosteal hyperplasia in the PJI group varied in different degrees and forms, characterized as evenly in the middle part of the prosthesis and wide basement.

Supplementary Files

This is a list of supplementary files associated with this preprint. Click to download.

- Table1.xlsx
- Table3.xlsx
- Table4.xlsx
- Table5.xlsx
- Table6.xlsx
- Table2.xlsx