

Acromioclavicular Joint Instability on Cross-Body Adduction View: The Biomechanical Effect of Acromioclavicular and Coracoclavicular Ligaments Sectioning

Shimpei Kurata (✉ kurashin24@gmail.com)

Nara Medical University

Kazuya Inoue

Nara Medical University

Takamasa Shimizu

Nara Medical University

Mitsuyuki Nagashima

Nara Medical University

Hirakazu Murayama

Nara Medical University

Kenji Kawamura

Nara Medical University

Shohei Omokawa

Nara Medical University

Pasuk Mahakkanukrauh

Chiang Mai University

Yasuhito Tanaka

Nara Medical University

Research Article

Keywords: Biomechanical study, fresh frozen cadaver study, acromioclavicular joint dislocation, cross-body adduction view, Rockwood classification, biomechanics

Posted Date: November 1st, 2021

DOI: <https://doi.org/10.21203/rs.3.rs-1018718/v1>

License:   This work is licensed under a Creative Commons Attribution 4.0 International License.

[Read Full License](#)

Version of Record: A version of this preprint was published at BMC Musculoskeletal Disorders on March 23rd, 2022. See the published version at <https://doi.org/10.1186/s12891-022-05245-5>.

Abstract

Background

The relationship between acromioclavicular (AC) joint dislocation, corresponding radiological evaluation, and ligament injuries remains controversial. We hypothesized that AC and trapezoid ligament injuries induce AC joint instability, and the clavicle can override the acromion on cross-body adduction view without conoid ligament injury. We aimed to investigate how biomechanically sectioning the AC and coracoclavicular (CC) ligaments contributes to AC joint instability in the cross-body adduction position using fresh-frozen cadaver models.

Methods

Six fresh-frozen cadaveric shoulders were used in this study, comprising five male and one female specimen, with a mean age of 68.7 (range, 51–87) years). The left side of the trunk and upper limb, and the cervical and thoracic vertebrae and sternum were firmly fixed with an external fixator. The displacement of the distal end of the clavicle relative to the acromion was measured using an electromagnetic tracking device. We simulated AC joint dislocation by sequential resection of AC ligament, AC joint capsule, and CC ligaments in the following order of stages. Stage 0: Intact AC and CC ligaments and acromioclavicular joint capsule; stage 1: Completely sectioned AC ligament and joint disc; stage 2: Sectioned trapezoid ligament; and stage 3: Sectioned conoid ligament. The superior clavicle displacement related to the acromion was measured in the horizontal adduction position, and clavicle overriding on the acromion was assessed radiologically at each stage. Data were analyzed using a one-way analysis of variance and post-hoc tests.

Results

Superior displacement was 0.3 mm at stage 1, 6.5 mm at stage 2, and 10.7 mm at stage 3. On the cross-body adduction view, there was no distal clavicle overriding at stages 0 and 1, and distal clavicle overriding was observed in five cases (5/6: 83%) at stage 2 and in six cases (6/6: 100%) at stage 3.

Conclusion

We found that AC and trapezoid ligament sectioning induced AC joint instability and that the clavicle could override the acromion on cross-body adduction view regardless of conoid ligament sectioning. AC and trapezoid ligament injuries may lead to significant AC joint instability, and the distal clavicle may subsequently override the acromion.

Introduction

Acromioclavicular (AC) joint dislocation is a common shoulder injury, that accounts for 9–10% of all shoulder injuries [1, 2]. The radiology-based Rockwood classification is commonly used to assess AC joint dislocation [3]. In this classification, types I and II are usually treated conservatively, whereas types IV to VI are usually treated surgically [4, 5, 6, 7]. The management of type III injuries remains controversial. The International Society of Arthroscopy, Knee Surgery and Orthopaedic Sports Medicine (ISAKOS)[8] subclassified type III injuries as type IIIA and type IIIB based on cross-body adduction radiographs and recommended that patients with type IIIA injury who have a stable AC joint without clavicle overriding on the cross-body adduction view should be treated non-surgically and that patients with type IIIB injury with an unstable overriding joint should also be considered for surgical treatment because both the coracoclavicular (CC) and AC ligaments are disrupted in this type of injury. Kurata et al. [9] reported that the AC ligament significantly contributes to AC joint stability in the superior direction, and AC joint displacement >50% may occur combined with isolated AC ligament injury in biomechanical loading experiments. They further mentioned the difficulty encountered in determining the type of injury using only the radiographic appearance of the AC joint. Murphy et al. [10] validated a novel radiological parameter, the circle measurements, that objectively evaluates AC joint displacement on the Alexander view, providing novel therapeutic recommendations. The relationship between AC joint dislocation, the corresponding radiological evaluation, and ligament injuries has attracted attention only recently. We hypothesized that AC and trapezoid ligament injuries induce AC joint instability and that the clavicle can override the acromion on the cross-body adduction view without conoid ligament injury. This study, using fresh-frozen cadaver models, aimed to investigate how sectioning the AC and CC ligaments can biomechanically contribute to AC joint instability in the cross-body adduction position.

Materials And Methods

Specimen preparation

Fresh-frozen human cadavers of this study were provided by Department of Anatomy in Chiang Mai University. Six shoulders from six fresh-frozen cadavers, comprising five male specimens and one female specimen, were used in this study, with a mean age of 68.7 (range, 51–87) years. The specimens were prepared by thawing overnight at room temperature one day before the experiment. The specimens were sectioned above the first cervical vertebrae, below the sternum, and on the right side of the sternum and thoracic vertebrae. The left upper extremity was sectioned at the midshaft of the humerus, and a hole was drilled in the humerus to pass a cord that could be used to apply stress to the upper limb. The moist state of all specimens were kept by spraying them with normal saline during the experiment. Standard anteroposterior (AP) radiographs were obtained for each specimen, and no specimens had osteoarthritis at the sternoclavicular, AC, and glenohumeral joints.

The specimens were firmly fixed on a customized wooden jig with external fixators (Orthofix®; Japan Medicalnext Co., Ltd., Osaka, Japan). Six fully threaded stainless rods were inserted into the cervical, thoracic vertebrae, and sternum, the rods were connected to external fixators (Fig. 1). The displacement of the distal end of the clavicle relative to the acromion was measured using an electromagnetic tracking

device (trakSTAR™; Ascension Technology Corporation, Shelburne, VT, USA). Sensors were inserted into the distal end of the clavicle and acromion. The proper location of the inserted sensors was verified with AP radiographs (BV Pulsera; Philips, Best, Netherlands).

Sectioning the distal clavicle stabilizers

We resected the AC, trapezoid and conoid ligaments sequentially, and simulated AC joint dislocation model (Fig. 2). Sectioning stages were defined as follows. Stage 0: the AC and CC ligaments and the AC joint capsule were intact; stage 1, the AC ligament, AC joint capsule, and disc were sectioned; stage 2, trapezoid ligament were sectioned; and stage 3, conoid ligaments were sectioned. The trapezius and deltoid muscle were incised parallel to the AC joint when the AC ligament and joint disc were removed. When resecting the trapezoid and conoid ligaments, the deltoid muscle was incised in the direction of the muscle fibers, and the ligaments were resected after clearly viewing them. Ligaments were sectioned according to previous biomechanical studies [9, 11, 12].

Loading testing and data acquisition

Stress was added to the AC joint by pulling the cord that was passed through the humerus. An examiner elevated the upper limb to 90° in the sagittal plane and adducted the upper limb manually until the maximum adduction angle was acquired in the horizontal plane, the cross-body adduction radiography was also performed in this position. Using this imaging technique, we assessed the degree to which the clavicle overlapped the acromion because of anteromedial scapula translation. Clavicle overriding on the cross-body adduction view was defined as the superior or lateral displacement of the inferior edge of the clavicle in the AC joint compared to the that of superior edge of the acromion in the AC joint (Fig. 3).

We defined the direction parallel to the AC joint is the X-axis, perpendicular to the AC joint is the Y-axis, and perpendicular to the ground is the Z-axis. The magnitude of the displacement was measured in each direction. In the horizontal adduction position, the direction of the AC joint changed, as demonstrated by the electromagnetic tracking device; yet, we did not evaluate the horizontal translation of the AC joint. We predicted posterior instability by determining whether the distal clavicle overrode the acromion. Displacement was measured in the Z-axis by calculating the difference between the values of both sensors in the acromion and the distal end of the clavicle. Values in stage 0 were used as control values.

Statistical analysis

Displacement magnitudes between each stage were compared using a one-way analysis of variance, and post-hoc tests were performed using the Tukey-Kramer method. P-values of <0.05 were considered statistically significant. Statistical analysis was performed using SPSS for Windows version 22.0 (IBM Corp., Armonk, NY, USA).

Results

Superior displacement

There were no statistically significant differences between stages 0 and 1 ($P=0.997$); yet, displacement increased significantly between stages 0 and 2 ($P=0.001$), between stages 0 and 3 ($P <0.001$), between stages 1 and 2 ($P=0.001$), between stages 1 and 3 ($P <0.001$), and between stages 2 and 3 ($P=0.026$).

Distal clavicle overriding the acromion on cross-body adduction view

The distal clavicle did not override the acromion in stages 0 and 1; yet, five of six distal clavicles (83%) overrode the acromion in stage 2, and all distal clavicles overrode the acromion in stage 3 (Fig. 4, Table 1).

Table 1
Superior AC joint displacement and distal clavicle overriding in each sectioning stage on cross-body adduction view

	Stage 0	Stage 1	Stage 2	Stage 3
Superior Displacement, mm ^a	0	0.3 ± 0.7	6.5 ± 1.1	10.7 ± 1.4
Distal clavicle overriding	0/6	0/6	5/6	6/6
^a Data are reported as mean ± standard deviations (range).				

Discussion

The most important findings of this study are that sectioning the AC and trapezoid ligaments causes AC joint instability and that the clavicle can override the acromion on cross-body adduction view regardless of conoid ligament sectioning. The findings of this study confirm our hypotheses. Alexander [13] described the shoulder-forward view (the Alexander view), which can be used to assess AC joint injuries by thrusting the shoulder forward and evaluating acromion displacement anteriorly and inferiorly under the distal end of the clavicle. A similar cross-body adduction view was reported and used by Barnes et al. [14] to help identify whether the AC joint is stable. ISAKOS [8] suggested distinguishing two variations of type III Rockwood injury using a cross-body adduction view. These reports suggest that evaluating ligament injuries is difficult using only plain radiographic examination. Zumstein et al. [15] reported the use of the acromial center line spanning to the dorsal clavicle (AC-DC) to assess vertical displacement and the use of the glenoid center line spanning to the posterior clavicle (GC-PC) to assess horizontal displacement; performing these evaluations in a single Alexander view is recommended to guide the appropriate management of AC joint dislocations. Karargyris et al. [16] reported that AC-DC measurement seemingly represents a more realistic AC joint injury magnitude than the CC distance. Murphy et al. [10] validated a novel radiological parameter, the circle measurements, that objectively evaluates AC joint

displacement on the Alexander view, providing novel therapeutic recommendations. Increasing attention has been given to the relationship between Alexander view evaluation and AC joint stability. In this study, we referred to radiological AC joint dislocation evaluation and investigated the relationship between ligament injury, cross-body adduction view, and AC joint instability. AC joint instability in both superior and posterior directions will make the distal clavicle override the acromion.

Regarding AC joint superior stability, Fukuda et al. [17] described the contributions of individual ligaments to joint stability by performing biomechanical loading experiments using fixed displacements and sequential ligament sectioning. At small displacements, the AC ligament primarily restrains the superior direction of the AC joint, and at large displacements, the conoid ligament primarily restrains the superior direction of the AC joint. Kurata et al. [9] reported that the AC ligament significantly contributes to AC joint stability in the superior direction, and AC joint displacement >50% may occur combined with isolated AC ligament injury in biomechanical loading experiments.

Regarding posterior stability, Fukuda et al. [17] reported that the AC ligament primarily restrains the posterior direction of the AC joint, and Dawson et al. [18] and Dyrna et al. [19] biomechanically investigated the kinematics of the AC joint and reported that the AC ligament strongly contributes to the horizontal stability of the AC joint. Oki et al. [11] conducted a biomechanical investigation using whole cadaver models and evaluated the function of the AC and CC ligaments in scapular and clavicular motions during humerothoracic motions and found that the AC ligament restrains clavicular retraction and that the trapezoid ligament restrains scapular internal rotation during horizontal plane adduction. Debski et al. [20] reported that the trapezoid ligament plays an important role in the posterior direction of the AC joint. Kurata et al. [9] reported that sectioning the trapezoid ligament after sectioning the AC ligament causes AC joint instability.

According to previous studies that examined superior and horizontal AC joint stability [9, 11, 17, 18, 19, 20], superior AC joint stability relies on the AC and conoid ligaments, whereas posterior AC joint stability relies on the AC and trapezoid ligaments. The results of this study revealed that five of the 6 clavicles overrode the acromion at stage 2, regardless of conoid ligament sectioning. Although the average superior displacement of the five clavicles was not large (average, 6.7 mm), sectioning the AC and trapezoid ligaments alone may cause AC joint instability enough to override the clavicle on the acromion in the horizontal adduction position. Our results suggest that there are variations of CC ligament injuries in type IIIB (unstable) injury of AC joint dislocation. There are many reports about arthroscopic CC ligament reconstruction for AC joint dislocation, and double bundle reconstruction is becoming a more common treatment [21, 22, 23]. Taking into account our study, it is possible that double bundle reconstruction includes reconstruction of the remaining ligament in type IIIB injury. Reconstructing only injured ligaments without altering remaining ligament could be used to reduce complications related to drilling holes in the distal clavicle and coracoid process [24, 25]. Diagnosis of AC joint dislocation should not only be based on the radiographic appearance of the AC joint. Recently, there are many reports about evaluation of the AC joint dislocation using magnetic resonance imaging (MRI) and the accuracy of

diagnosing ligament injuries [26, 27]. For cases of type IIIB injuries, we recommend additional MRI examination.

This study has some limitations. First, ligament sectioning was performed according to previous studies, and the sequences of ligament sectioning may differ from clinical settings. Second, this study used the cadavers of old people; yet, AC joint dislocation is common among young people. Third, when resecting the trapezoid and conoid ligaments, the deltoid muscle was incised in the direction of the muscle fibers, and the ligaments were resected after clearly viewing them. Fourth, the direction of the AC joint changed, and we did not evaluate the horizontal translation of the AC joint in the horizontal adduction position. Fifth, we used a limited number of specimens.

Conclusion

In the current fresh-frozen cadaver models, we found that AC and trapezoid ligament sectioning caused AC joint instability and that the clavicle can override the acromion on cross-body adduction view without conoid ligament sectioning. Accordingly, CC joint injury variations may exist in AC joint dislocation cases, and these injuries might override the acromion on cross-body adduction view. Further investigations will be required to evaluate the degree of AC joint dislocation.

Abbreviations

AC: acromioclavicular

CC: coracoclavicular

ISAKOS: International Society of Arthroscopy, Knee Surgery and Orthopaedic Sports Medicine

MRI: magnetic resonance imaging

Declarations

Acknowledgements

The authors thank the staffs of the surgical training center for their extensive help in this study.

Funding

The authors declare that they do not receive any source of funding.

Availability of data and materials

The datasets used during the present study are available from the corresponding author on reasonable request.

Authors' contributions

SK: research design, acquisition, analysis, and interpretation of data, drafting the paper. KI: interpretation of data, revising the paper critically. TS: acquisition, interpretation of data. MN: acquisition, analysis, and interpretation of data. HM: acquisition, analysis, and interpretation of data. KK: interpretation of data, revising the paper critically. SO: research design, interpretation of data, revising the paper critically. PM: acquisition, analysis, and interpretation of data, interpretation of data, preparing the cadavers. YT: research design, revising the paper critically, approval of the submitted and final versions. All authors have read and approved the final submitted manuscript.

Competing interests

The authors declare that they have no competing interests

Consent for publication

Not applicable.

Ethics approval and consent to participate

We obtained ethics approval from Research Ethics Committee of Chiang Mai University (STUDY CODE: ANA-2563-06977). The cadavers of this study were provided by Department of Anatomy in Chiang Mai University. The consent to use the cadavers was obtained from the patient before death.

References

1. Mazzocca AD, Arciero RA, Bicos J. Evaluation and treatment of acromioclavicular joint injuries. *Am J Sports Med.* 2007,35:316-29.
2. Nemeč U, Oberleitner G, Nemeč SF, Gruber M, Weber M, Czerny C, et al. MRI versus radiography of acromioclavicular joint dislocation. *AJR Am J Roentgenol.* 2011,197:968-73.
3. Rockwood CA, Williams GR, Young DC. Disorders of the acromioclavicular joint. In: Rockwood CA, Matsen FA, Wirth MA, Lippitt SB, eds. *The shoulder.* Philadelphia: WB Saunders, 2018:365-451. (ISBN No.: 978-0-323-29731-8)
4. Bradley JP, Elkousy H. Decision making: operative versus nonoperative treatment of acromioclavicular joint injuries. *Clin Sports Med.* 2003,22:277-90.
5. Farber AJ, Cascio BM, Wilckens JH. Type III acromioclavicular separation: rationale for anatomical reconstruction. *Am J Orthop (Belle Mead NJ).* 2008,37:349-55.
6. Pallis M, Cameron KL, Svoboda SJ, Owens BD. Epidemiology of acromioclavicular joint injury in young athletes. *Am J Sports Med.* 2012,40:2072-7.
7. Tischer T, Salzmänn GM, El-Azab H, Vogt S, Imhoff AB. Incidence of associated injuries with acute acromioclavicular joint dislocations types III through V. *Am J Sports Med.* 2009,37:136-9.

8. Beitzel K, Mazzocca AD, Bak K, Itoi E, Kibler WB, Mirzayan R, Imhoff AB, Calvo E, Arce G, Shea K. ISAKOS upper extremity committee consensus statement on the need for diversification of the Rockwood classification for acromioclavicular joint injuries. *Arthroscopy*. 2014;30:271-8.
9. Kurata S, Inoue K, Hasegawa H, Shimizu T, Iida A, Kawamura K, et al. The role of the Acromioclavicular Ligament in Acromioclavicular Joint Stability: A Cadaveric Biomechanical Study. *Orthop J Sports Med*. 2021;9:2325967120982947.
10. Murphy RJ, Moor BK, Lesniowski PJ, Hayoz A, Alcantara W, Zumstein MA. Evaluation of the Circles Measurement and the ABC Classification of Acromioclavicular Joint Injuries. *Am J Sports Med*. 2021;49:1619-25.
11. Oki S, Matsumura N, Iwamoto W, Ikegami H, Kiriya Y, Nakamura T, et al. The function of the acromioclavicular and coracoclavicular ligaments in shoulder motion: a whole-cadaver study. *Am J Sports Med*. 2012;40:2617-26.
12. Walley KC, Haghpanah B, Hingsammer A, Harlow ER, Vaziri A, DeAngelis JP, et al. Influence of disruption of the acromioclavicular and coracoclavicular ligaments on glenohumeral motion: a kinematic evaluation. *BMC Musculoskelet Disord*. 2016;17:480.
13. Alexander OM. Dislocation of the acromio-clavicular joint. *Radiography*. 1949;15:260.
14. Barnes CJ, Higgins LD, Major NM, Basamania CJ. Magnetic resonance imaging of the coracoclavicular ligaments: its role in defining pathoanatomy at the acromioclavicular joint. *J Surg Orthop Adv*. 2004;13:69-75.
15. Zumstein MA, Schiessl P, Ambuehl B, Bolliger L, Weihs J, Maurer MH, et al. New quantitative radiographic parameters for vertical and horizontal instability in acromioclavicular joint dislocations. *Knee Surg Sports Traumatol Arthrosc*. 2017;21:125-35.
16. Karargyris O, Murphy RJ, Arenas A, Bolliger L, Zumstein MA. Improved identification of unstable acromioclavicular joint injuries in a clinical population using the acromial center line to dorsal clavicle radiographic measurement. *J Shoulder Elbow Surg*. 2020;29:1599-605.
17. Fukuda K, Craig EV, An KN, Cofield RH, Chao EY. Biomechanical study of the ligamentous system of the acromioclavicular joint. *J Bone Joint Surg Am*. 1986;68:434-40.
18. Dawson PA, Adamson GJ, Pink MM, Kornswiet M, Lin S, Shankwiler JA, et al. Relative contribution of acromioclavicular joint capsule and coracoclavicular ligaments to acromioclavicular stability. *J Shoulder Elbow Surg*. 2009;18:237-44.
19. Dyrna FGE, Imhoff FB, Voss A, Braun S, Obopilwe E, Apostolakos JM, Morikawa D, et al. The Integrity of the Acromioclavicular Capsule Ensures Physiological Centering of the Acromioclavicular Joint Under Rotational Loading. *Am J Sports Med*. 2018;46:1432-40.
20. Debski RE, Parsons IM 4th, Woo SL, Fu FH. Effect of capsular injury on acromioclavicular joint mechanics. *J Bone Joint Surg Am*. 2001;83:1344-51. doi:10.2106/00004623-200109000-0000
21. Shin SJ, Jeon YS, Kim RG. Arthroscopic-Assisted Coracoclavicular Ligament Reconstruction for Acute Acromioclavicular Dislocation Using 2 Clavicular and 1 Coracoid Cortical Fixation Buttons with Suture Tapes. *Arthroscopy*. 2017;33:1458-66.

22. Yi Zhao, Lei Tan, Wan Tang, Tiecheng Yu. A New Coracoclavicular Guider for Minimally Invasive Anatomic Coracoclavicular Reconstruction with Two TightRope Systems in Acute Acromioclavicular Joint Dislocation. *Sci Rep.* 2019,9:14452.
23. Theopold J, Henkelmann R, Zhang C, Schöbel T, Osterhoff G, Hepp P. Clinical outcomes of arthroscopic and navigation-assisted two tunnel technique for coracoclavicular ligament augmentation of acute acromioclavicular joint dislocations. *BMC Musculoskelet Disord.* 2021,22:1-9.
24. Milewski MD, Tompkins M, Giugale JM, Carson EW, Miller MD, Diduch DR. Complications related to anatomic reconstruction of the coracoclavicular ligaments. *Am J Sports Med.* 2012,40:1628-34.
25. Panarello NM, Colantonio DF, Harrington CJ, Feeley SM, Bandarra TD, Dickens JF, et al. Coracoid or Clavicle Fractures Associated With Coracoclavicular Ligament Reconstruction. *Am J Sports Med.* 2021,49:3218-25.
26. White LM, Ehmann J, Bleakney RR, Griffin AM, Theodoropoulos J. Acromioclavicular Joint Injuries in Professional Ice Hockey Players: Epidemiologic and MRI Findings and Association With Return to Play. *Orthop J Sports Med.* 2020,8:2325967120964474.
27. Alyas F, Curtis M, Speed C, Saifuddin A, Connell D. MR imaging appearances of acromioclavicular joint dislocation. *Radiographics.* 2008,28:463-79.

Figures

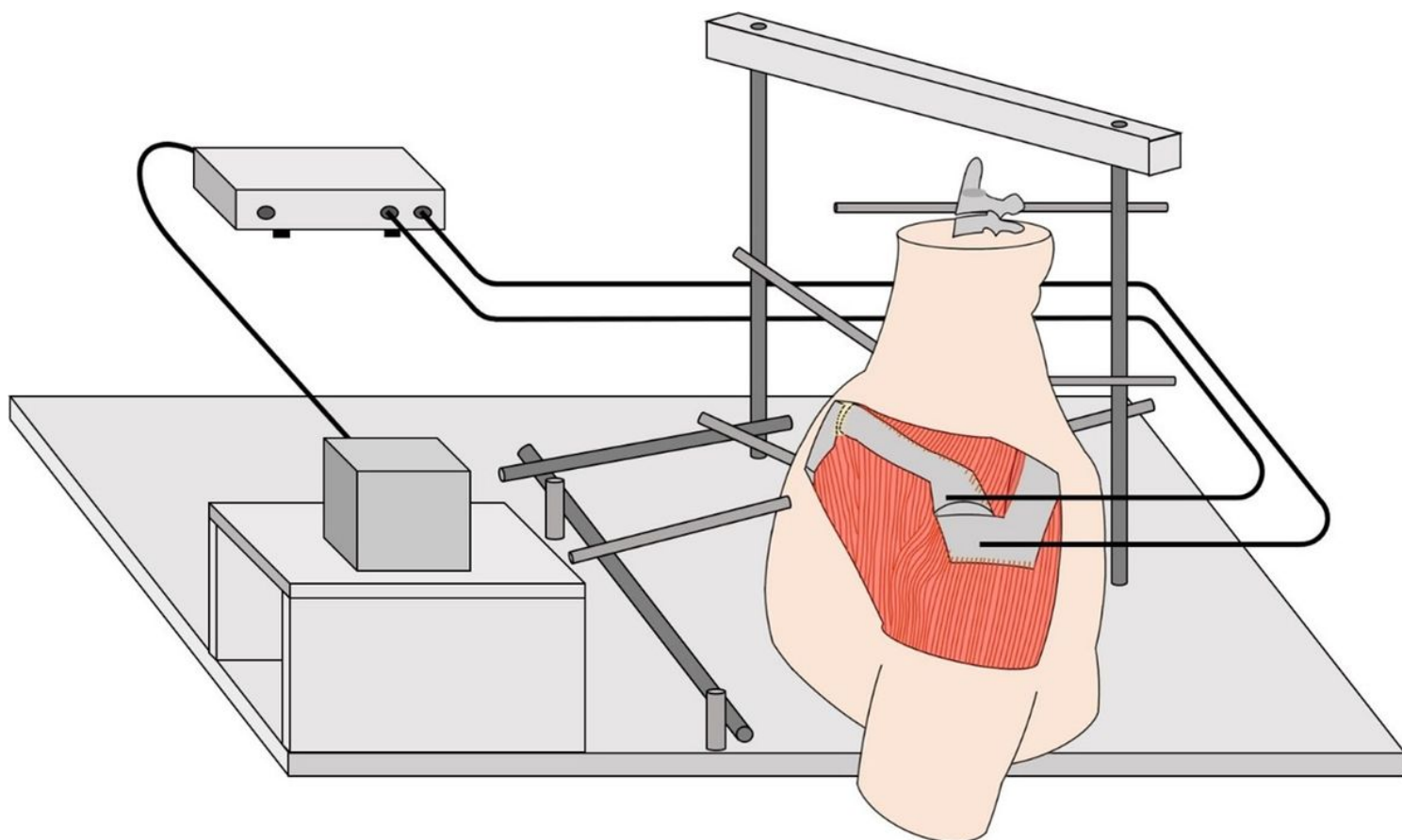


Figure 1

Experimental setup The specimens were firmly fixed on a customized wooden jig with external fixators (Orthofix®; Japan Medicalnext Co., Ltd., Osaka, Japan). An electromagnetic tracking device (trakSTAR™; Ascension Technology Corporation, Shelburne, VT, USA) was used to measure the displacement of the distal end of the clavicle relative to the acromion. Sensors were inserted into the distal end of the clavicle and acromion.

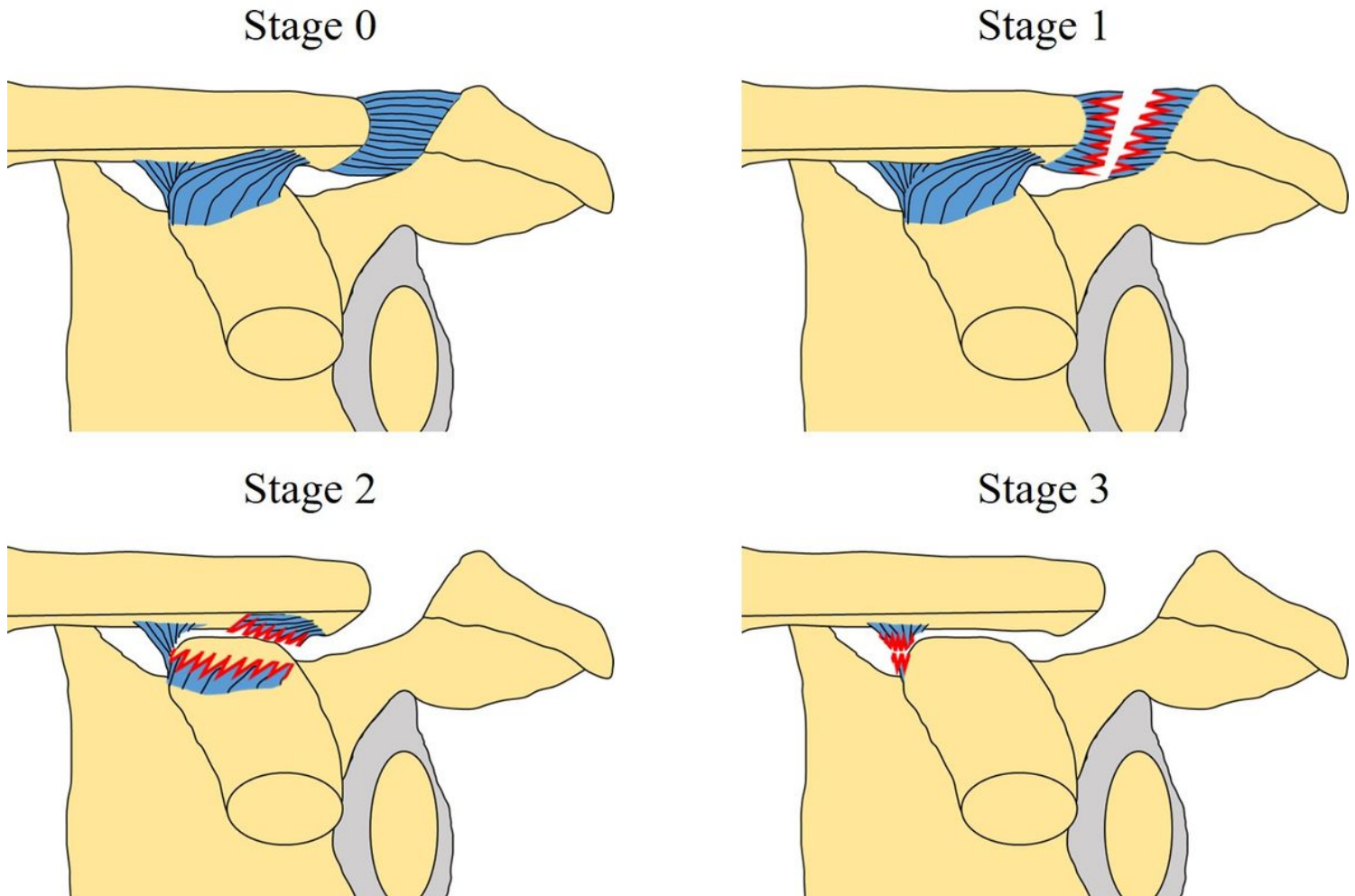


Figure 2

We simulated AC joint dislocation by sequential resection of AC ligament, AC joint capsule, trapezoid ligament, and conoid ligament in the following order of stages. Stage 0: The acromioclavicular and coracoclavicular ligaments and the acromioclavicular joint capsule were intact. Stage 1: The acromioclavicular ligament, acromioclavicular joint capsule, and disc were sectioned. Stage 2: The trapezoid ligament was sectioned. Stage 3: The conoid ligaments was sectioned. The sectioned ligaments in each stage are indicated by jagged lines.

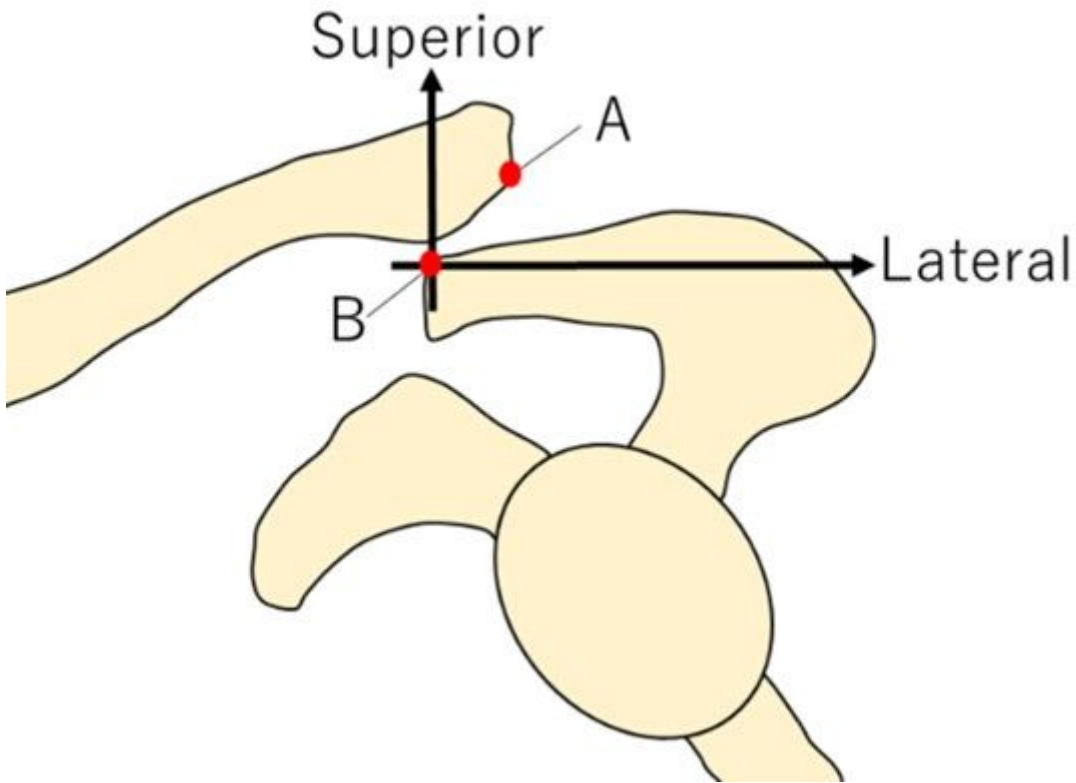


Figure 3

Point A: Inferior edge of the clavicle in the acromioclavicular joint Point B: Superior edge of the acromion in the acromioclavicular joint. Clavicle overriding on the cross-body adduction view was defined as the superior and lateral displacement of point A compared to that of point B.

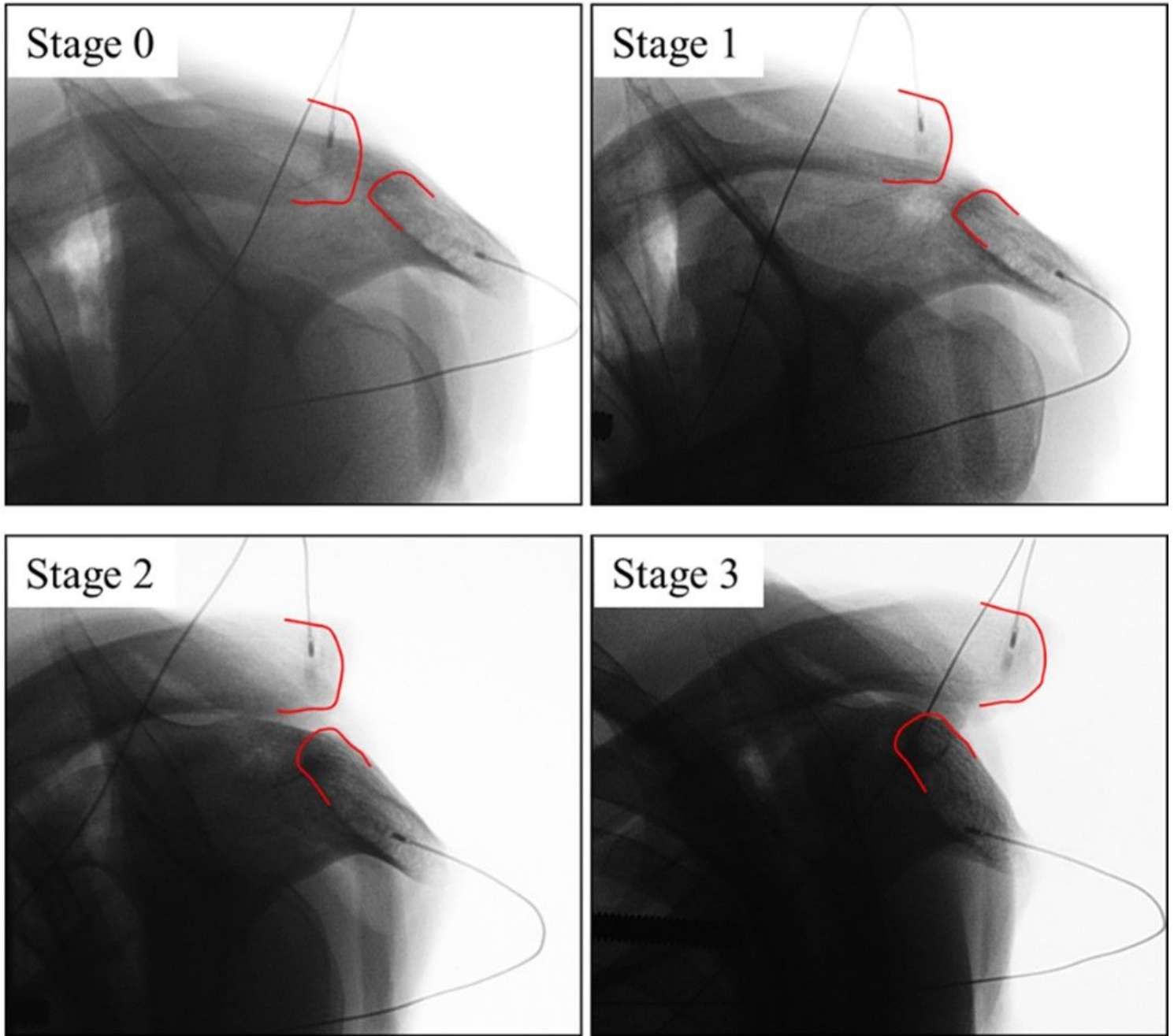


Figure 4

Cross-body adduction view in every stage The distal end of the clavicle and acromion in the acromioclavicular joint are marked with red lines.