The Vastus Medialis Oblique Compensates in Current Patellar Dislocation Patients with The Increased Femoral Anteversion

Conglei Dong
Third Hospital of Hebei Medical University
Chao Zhao
Third Hospital of Hebei Medical University
Fei Wang (doctorwfei@163.com)
Third Hospital of Hebei Medical University

Research Article

Keywords: Vastus medialis oblique, Femoral anteversion, Computed tomography, Patella dislocation, VMO/VLM area ratio

Posted Date: November 8th, 2021

DOI: https://doi.org/10.21203/rs.3.rs-1024311/v1

Abstract

Purpose The purpose of this study was to investigate whether the vastus medialis oblique (VMO) compensates in patella dislocation patients with the increase of femoral anteversion angle (FAA).

Methods From January 2016 to January 2021, a total of 30 knees of 27 patients with recurrent patellar dislocation (RPD Group) were reviewed for this study. Among these patients, 13 patients with patellar dislocation and excessive FAA, >30° were assigned to A Group, and 17 patients with the patellar dislocation without excessive FAA,≤30 were assigned to B Group. And 27 age and sex matched knees without patellofemoral disorders were enrolled as control (C Group). The area of the VMO and vastus lateralis muscle (VLM) was measured 20 mm above the upper edge of the patella, and the ratio of the VMO and VLM area was calculated. The correlation relationship of FAA and VMO, VLM was analyzed.

Results Comparing with the C Group, the RPD Group had a significantly larger FAA (30.10± 9.61°vs 15.00± 1.85°, P< 0.05), and smaller VMO/VLM ratio (3.49±1.00/4.18±1.51, P< 0.05), and the VMO/VLM ratio was significantly greater in A Group than the B Group (3.97±1.11 vs3.12±0.70, P< 0.05). There was no statistically significant difference in VMO/VLM ratio among A Group and C Group (3.12±0.70/3.97±1.11, P> 0.05). And the VMO/VLM ratio was decreased in the B Group compared with the C Group (3.12±0.70/4.18±1.51, P< 0.05). The VMO/VLM ratio was positively correlated with the FAA(r=0.42) in the RPD Group.

Conclusion Compared with the C Group, the patients with recurrent patellar dislocation had a smaller VMO/VLM ratio. Moreover, the FAA was positively correlated with the VMO/VLM in patients with patella dislocation. This finding explained the compensatory thickening of the VMO in response to excessive FAA in patients with patella dislocation.

Introduction

Patella dislocation was when the patella breaks out of the femoral trochlear groove during movement[1]. Repeated dislocation could lead to cartilage wear, ligament damage, knee joint, and hip joint instability. Correcting patella dislocation was of importance[2]. The causes of patellar dislocation were considered multifactorial, including congenital and acquired factors. Abnormal femoral torsion was a developmental deformity in which the femur suffered excessive internal rotation, clinically characterized by the appearance of in-toes, internal rotation of the hipbones and knees, and abnormal appearance of the lower limbs[3–5]. Abnormal femur torsion, also known as femoral anteversion, could cause a variety of diseases[6]. Excessive femoral anteversion could place excessive stress on the iliopsoas muscle and the upper glenoid, which may lead to pain in the front of the hip and tear of the labrum[7]. Studies had found that in frog-leg squatting mimicking patients, abnormal femoral torsion can be accompanied by gluteal muscle contracture[8]. In addition, excessive femoral anteversion was one of the important risk factors for patella dislocation in patients[9–11]. The main mechanism of patellofemoral dislocation induced by excessive femoral anteversion may increase abnormal contact stress of the patellofemoral joint, resulting

in instability of the patellofemoral joint. Quantitative indicators of femoral anteversion had been noticed by researchers. The femoral anteversion angle (FAA) was defined as the torsion between the proximal and distal femur and defined as the angle between the femoral neck axis and the transfemoral posterior condyle axis. The FAA was a commonly used indicator to guide clinical application. Surgical correction was recommended to improve the patient's axial alignments when the FAA was greater than 30 degrees. The relationship between femoral anteversion and knee pain was a biomechanical factor that is worthy of attention[12–14].

The Quadriceps femoris was an important part of the extensor mechanism of the knee joint. The quadriceps femoris played an important role in maintaining the stability of the knee joint. Quadriceps femoris were divided into musculus rectus femoris, vastus medialis oblique (VMO), vastus lateralis muscle (VLM), and musculus vastus intermedius[15]. The VMO played an important role in addition to extending the knee joint in the integrated musculoskeletal system of the knee joint. Such as maintaining the path of the patella and restricting its outward movement, together with the surrounding ligaments and bones[16–18]. In addition, it had the effect of limiting excessive rotation and torsion of the knee joint[19]. Previous studies had shown that the VMO was atrophied in patients with patellofemoral pain syndrome (PFPS)[20–22]. The researchers supposed that the VMO may disuse atrophy. This may be related to the decreased intensity of movement of the affected limb after patella dislocation, and the need to limit the strength of the trochlea of the femur to counter patella dislocation disappears. However, in patients with increased femoral anteversion, represented by abnormal torsion of the femur, an increase in force resistance to limit excessive knee joint torsion may result in an inappropriate or excessive extension of the VMO. Especially in patients with recurrent patellar dislocation, the properties of the VMO may be affected by changes in the mechanical requirements of it due to changes in the overall strength of the musculoskeletal system[19].

However, there was limited evidence on the impact of femoral anteversion on VMO in patients with patella dislocation. The purpose of this study was to investigate the compensatory thickening or atrophy of VMO and VLM in patella dislocation patients with large FAA, and whether the thickening or atrophy of VMO and VLM were correlated with FAA. We hypothesized compensatory thickening of VMO in patients with patella dislocation with large FAA and a positive correlation between FAA and VMO/VLM.

Materials And Methods

General information

The clinical charts of patients diagnosed with patella dislocation between January 2016 and January 2021 in our institution were retrospectively reviewed. The inclusion criteria were listed as follows: (1) at least two episodes of patellar dislocation (2) aged between 18 and 45 years; (3) Patients with complete CT scans of the knee and hip. Exclusion criteria were as follows :(1) history of past knee surgery (2) Other knee joint diseases, such as fracture, ligament injury, or meniscus injury; (3) Patellofemoral arthritis

greater than Iwano grade II, (4) incomplete medical history and data. This study divided the patients with patellar dislocation into two sub-groups with and without excessive FAA (sub-A group, FAA≥30, sub-B group FAA<30). And age and sex-matched patients in the group of musculoskeletal disorders without a history of patellofemoral instability were included in this study.

Radiological assessments

All patients received a 1-mm thickness CT scanning (Somatom, Sensation 16, Siemens Medical Solutions, Erlangen, Germany) in a supine position with the knee extended and quadriceps muscle relaxed. The limbs were immobilized with devices to reduce arbitrary movements. All measurements were conducted on axial CT images. The VMO and VML cross-sectional areas, FAA, was measured using the Image Storage and Communication System (PACS) workstation (Centricity, GE Healthcare, St. Gilles, UK).

The cross-sectional areas of the VMO and VML were measured 20 mm above the upper pole of the patella[18 23]. (Figure 1). The Angle formed by the projection of the line between the central axis of the neck of the femur and the midpoint of the internal and external condyle of the femur was defined as the FAA[12 24 25]. The central axis of the femoral neck was determined by the following two points: one was the center of the femoral head, the other was the center of the base of the femoral neck, and the connection between the two points was defined as the axis of the femoral neck. Bilateral condylar axis: The line parallels the last two points of the medial and lateral femoral condyle and passing through the center point of the knee. (Figure 2). Two trained observers independently repeated the measurements with an interval of four weeks.

Statistical analysis

The statistical difference of all measurements was examined using software SPSS (version 21.0; SPSS Inc., Chicago, IL, USA). The normality of measurements was examined using the Shapiro-Wilk test. The study was designed as an exploratory study and prior power analysis was not performed. The results were expressed as mean ± standard deviation. $P < 0.05$ was considered statistically significant. Spearman correlation analysis was used to explore the correlation between the FAA and VMO/VML. Intraclass correlation coefficients (ICC) were calculated to test the intra-observer and inter-observer reliability. The ICC agreement was poor when ranged from 0 to 0.2, fair from 0.21 to 0.4, moderate from 0.41to 0.6, substantial from 0.61 to 0.8, excellent from 0.81 to 1.0.

Results

The demographics of the patients were summarized in Table 1. All measurements had good intra-observer and inter-observer reliability (Table 2).

Table 1
Patient information and statistics.

Group	Age (years)	Gender (F/M)	Knees	Side (R/L)	VMO/VLM	FAA
C Group	18.85± 3.49	10/17	27	11/16	4.18± 1.51	15.00± 1.85°
RPD Group	18.80± 5.46	22/5	30	21/9	3.49± 1.00	30.10± 9.61°
A Group	17.88± 5.14	—	17	13/4	3.12± 0.70	23.65± 3.25°
B Group	20.00± 5.62	—	13	8/5	3.97± 1.11	38.54± 8.59°

Table 2
Intra-observer and inter-observer agreement of measurements with 95% confidence intervals.

Measurements	Intra-observer			Inter-observer		
	ICC	95%CI		ICC	95%CI	
Lower	Upper	Lower		Upper		Lower
FAA	0.996	0.993	0.997	0.991	0.984	0.994
VMO/VLM	0.993	0.989	0.996	0.991	0.985	0.995

Compared with the C Group, the RPD Group had a significantly larger FAA (30.10± 9.61°vs 15.00± 1.85°, $P< 0.05$), and smaller VMO/VLM ratio (3.49±1.00 vs 4.18±1.51, $P< 0.05$), and the VMO/VLM ratio was significantly greater in A Group than the B Group (3.97±1.11 vs3.12±0.70, $P< 0.05$). There was no statistically significant difference in VMO/VLM ratio among A Group and C Group (3.12±0.70 vs 3.97±1.11, $P> 0.05$). And the VMO/VLM ratio was decreased in the B group compared with the C Group (3.12±0.70 vs 4.18±1.51, $P< 0.05$). (Table 3). The VMO/VLM ratio was positively correlated with the FAA (r=0.42, $P< 0.05$) in the RPD Group.

Table 3
The statistics in FAA, and VMO/VLM among groups.

Group	VMO/VLM	FAA
C Group	4.18±1.51	15.00±1.85°
RPD Group	3.49±1.00	30.10±9.61°
P-value	<0.05	<0.05
A Group	3.12±0.70	23.65±3.25°
B Group	3.97±1.11	38.54±8.59°
P-value	<0.05	<0.05
C Group	4.18±1.51	15.00±1.85°
A Group	3.97±1.11	38.54±8.59°
P-value	0.67	<0.05
C Group	4.18±1.51	15.00±1.85°
B Group	3.12±0.70	23.65±3.25°
P-value	<0.05	<0.05

Discussion

The most important finding of this study was that patients with recurrent patellar dislocation had larger FAA and smaller VMO than normal people. There was a positive correlation between FAA and VMO/VLM ratio in patients with patella dislocation[18 23]. This finding explained the compensatory thickening of the VMO in response to large FAA with patella dislocation in humans. The present study supported that the rationale of the derotational femoral osteotomy (DFO) in correcting the malalignment of lower limbs in the treatment of patients with recurrent patellar dislocation[26 27].

Femoral anteversion was commonly larger in adolescents than the adults and returns to normal levels with grows[3]. In this study, the patients with open osteoepiphysis were excluded. Large FAA could cause the internal rotation of the distal femur and was reported related to the PFPS[12–14]. It had been reported in previous studies that the VMO was atrophied in patients with PFPS[20–22]. However, due to the complex etiologies of patellofemoral instability, including congenital force line and bone structure factors, as well as acquired factors such as muscles and ligaments, we believed that one of the important reasons was the increase of FAA. Musculoskeletal parameters were generally measured using MRIs and ultrasound. In this study, CT scans of the lower limbs were applied to analyze the anomalies of both the osseous and

musculoskeletal factors. We found that VMO/VLM ratio increased in patients with patella dislocation with FAA≥30, but the difference was not statistically significant compared with the normal population.

It was generally believed that the normal femoral anteversion had a large range between -10° to 22°, with the mean of 10° to 15° for most adults, and more than 30° indicating a more serious increase of femoral rotation[28 29]. The increase of FAA could lead to the in-toeing gait of humans, which changed the line of force of human lower limbs, leading to compensatory external torsion of the tibia and lateral patella tilt which was easy to cause the patellar instability and damage of VMO and VLM[3−5]. In addition, the internal rotation of the distal femur maked the lateralization of patellar tracking relative to the femoral trochlea, which may increase the burden on the VMO in patients with patella dislocation and might lead to compensatory thickening.

The medial soft tissue included in the VMO was an important stabilizer that restricts the patellar lateralization during the knee flexion and extension. When the FAA increased, the greater the axial stress of the patella might cause the greater demand of the VMO strength, which might result in compensatory thickening of the VMO. Surgical indications for increased FAA were patients with poor patellofemoral joint force line symptoms and FAA greater than 25° to 30°, and DFO was usually performed. The malalignment on the transverse plane could be corrected by DFO. This study may support the DFO as an additional treatment option combined with reconstruction of soft tissue for patients with recurrent patella dislocation and excessive femoral anteversion[27 30].

There were some limitations to our study. The sample size of the study was so small that we could not further explore how the results relate to more factors. Long-term and large-scale follow-up of the relationship between FAA and VMO was still necessary for future studies.

Conclusion

Compared with the C Group, the patients with recurrent patellar dislocation had a smaller VMO/VLM ratio. Moreover, the FAA was positively correlated with VMO/VLM in patients with patella dislocation. This finding explained the compensatory thickening of the VMO in response to excessive FAA in patients with patella dislocation.

Abbreviations

VMO: vastus medialis oblique;

FAA: femoral anteversion angle;

PFPS: patellofemoral pain syndrome;

VLM: vastus lateralis muscle;

FDO: femoral derotation osteotomy;

ICC: Intraclass correlation coefficients;

Declarations

Ethics approval and consent to participate

The present study was approved by the Academic Ethics Committee of the Third Hospital of Hebei Medical University, and all patients provided their informed consent for participation and publication. All of the data and materials are available.

Consent for publication

Not applicable.

Availability of data and materials

All of the data and materials are available.

Competing interests

The authors declare that they have no competing interests.

Funding

Funded by The National Natural Science Foundation of China (Grant No.81873983).

Authors' contributions

Fei Wang contributed to the conception of the study; Conglei Dong measured and collected the data; Chao Zhao contributed significantly to the analysis the manuscript; The authors read and approved the final manuscript.

Acknowledgments

Thanks for the technical support from the Department of Imaging of the Third Hospital of Hebei Medical University.

Authors' information

Conglei Dong yongqi869@qq.com Department of Orthopaedic Surgery, Third Hospital of Hebei Medical University, Shijiazhuang 050051, Hebei, China.

Chao Zhao chaozhao0311@163.com Department of Orthopaedic Surgery, Third Hospital of Hebei Medical University, Shijiazhuang 050051, Hebei, China.

Fei Wang doctorwfei@163.com Department of Orthopaedic Surgery, Third Hospital of Hebei Medical University, Shijiazhuang 050051, Hebei, China.

+Conglei Dong and Chao Zhao contributed equally to this work.

*Corresponding author: Fei Wang.

Corresponding author at Department of Orthopaedic Surgery, Third Hospital of Hebei Medical University, Ziqiang Road 139, 050051 Shijiazhuang, China E-mail addresses: doctorwfei@163.com Tel: +86 -311-88602613 Fax: +86 -311-88602613.

References

1. Batra S, Arora S. Habitual dislocation of patella: A review. *Journal of clinical orthopaedics and trauma* 2014;5(4):245-51. doi: 10.1016/j.jcot.2014.09.006 [published Online First: 2015/05/20]
2. Hubbard DD, Staheli LT, Chew DE, et al. Medial femoral torsion and osteoarthritis. *Journal of pediatric orthopedics* 1988;8(5):540-2. doi: 10.1097/01241398-198809000-00008 [published Online First: 1988/09/01]
3. Rerucha CM, Dickison C, Baird DC. Lower Extremity Abnormalities in Children. *Am Fam Physician* 2017;96(4):226-33. [published Online First: 2017/09/20]
4. Accadbled F, Cahuzac JP. ["In-toeing and out-toeing"]. *Rev Prat* 2006;56(2):165-71. [published Online First: 2006/04/06]
5. Honig EL, Haeberle HS, Kehoe CM, et al. Pediatric orthopedic mythbusters: the truth about flexible flatfeet, tibial and femoral torsion, W-sitting, and idiopathic toe-walking. *Curr Opin Pediatr* 2021;33(1):105-13. doi: 10.1097/mop.0000000000000977 [published Online First: 2020/12/15]
6. Kaiser P, Schmoelz W, Schoettle P, et al. Increased internal femoral torsion can be regarded as a risk factor for patellar instability - A biomechanical study. *Clinical biomechanics (Bristol, Avon)* 2017;47:103-09. doi: 10.1016/j.clinbiomech.2017.06.007 [published Online First: 2017/06/20]
7. Grisch D, Dreher T. [Torsion and torsional development of the lower extremities]. *Orthopade* 2019;48(6):523-30. doi: 10.1007/s00132-019-03752-3 [published Online First: 2019/05/16]
8. Chiang CL, Tsai MY, Chang WN, et al. Aberrant femoral torsion presenting with frog-leg squatting mimicking gluteal muscle contracture. *Clin Orthop Relat Res* 2012;470(4):1165-70. doi: 10.1007/s11999-011-2084-7 [published Online First: 2011/09/21]
9. Yang G, Dai Y, Dong C, et al. Distal femoral morphological dysplasia is correlated with increased femoral torsion in patients with trochlear dysplasia and patellar instability. *The bone & joint journal* 2020;102-b(7):868-73. doi: 10.1302/0301-620x.102b7.Bjj-2019-1331.R1 [published Online First: 2020/07/01]
10. Kang H, Lu J, Li F, et al. The effect of increased femoral anteversion on the morphological and trabecular microarchitectural changes in the trochlea in an immature rabbit. *Journal of advanced research* 2020;23:143-49. doi: 10.1016/j.jare.2020.02.002 [published Online First: 2020/03/04]

11. Xu Z, Zhang H, Chen J, et al. Femoral Anteversion Is Related to Tibial Tubercle-Trochlear Groove Distance in Patients with Patellar Dislocation. *Arthroscopy : the journal of arthroscopic & related surgery : official publication of the Arthroscopy Association of North America and the International Arthroscopy Association* 2020;36(4):1114-20. doi: 10.1016/j.arthro.2019.10.033 [published Online First: 2019/12/18]
12. Behaeghe O, Van Beeck A, Dossche L, et al. Femoral anteversion measurement : evaluation of inter- and intraobserver reliability. *Acta Orthop Belg* 2020;86(1):17-21. [published Online First: 2020/06/04]
13. Kaya D, Doral MN. Is there any relationship between Q-angle and lower extremity malalignment? *Acta orthopaedica et traumatologica turcica* 2012;46(6):416-9. doi: 10.3944/aott.2012.2883 [published Online First: 2013/02/23]
14. Piva SR, Fitzgerald K, Irrgang JJ, et al. Reliability of measures of impairments associated with patellofemoral pain syndrome. *BMC Musculoskelet Disord* 2006;7:33. doi: 10.1186/1471-2474-7-33 [published Online First: 2006/04/04]
15. Flandry F, Hommel G. Normal anatomy and biomechanics of the knee. *Sports medicine and arthroscopy review* 2011;19(2):82-92. doi: 10.1097/JSA.0b013e318210c0aa [published Online First: 2011/05/05]
16. Bose K, Kanagasuntheram R, Osman MB. Vastus medialis oblique: an anatomic and physiologic study. *Orthopedics* 1980;3(9):880-3. doi: 10.3928/0147-7447-19800901-12 [published Online First: 1980/09/01]
17. Irish SE, Millward AJ, Wride J, et al. The effect of closed-kinetic chain exercises and open-kinetic chain exercise on the muscle activity of vastus medialis oblique and vastus lateralis. *J Strength Cond Res* 2010;24(5):1256-62. doi: 10.1519/JSC.0b013e3181cf749f [published Online First: 2010/04/14]
18. Sawy MME, Mikkawy D, El-Sayed SM, et al. Morphometric analysis of vastus medialis oblique muscle and its influence on anterior knee pain. *Anatomy & cell biology* 2021;54(1):1-9. doi: 10.5115/acb.20.258 [published Online First: 2020/12/03]
19. Powers CM. Rehabilitation of patellofemoral joint disorders: a critical review. *The Journal of orthopaedic and sports physical therapy* 1998;28(5):345-54. doi: 10.2519/jospt.1998.28.5.345 [published Online First: 1998/11/11]
20. Ashnagar Z, Hadian MR, Sajjadi E, et al. Quadriceps architecture in individuals with patellofemoral pain: A systematic review. *Journal of bodywork and movement therapies* 2021;25:248-54. doi: 10.1016/j.jbmt.2020.08.007 [published Online First: 2021/03/15]
21. Jan MH, Lin DH, Lin JJ, et al. Differences in sonographic characteristics of the vastus medialis obliquus between patients with patellofemoral pain syndrome and healthy adults. *The American journal of sports medicine* 2009;37(9):1743-9. doi: 10.1177/0363546509333483 [published Online First: 2009/06/13]
22. Pattyn E, Verdonk P, Steyaert A, et al. Vastus medialis obliquus atrophy: does it exist in patellofemoral pain syndrome? *The American journal of sports medicine* 2011;39(7):1450-5. doi:

10.1177/0363546511401183 [published Online First: 2011/04/14]

23. Dong C, Li M, Hao K, et al. Dose atrophy of vastus medialis obliquus and vastus lateralis exist in patients with patellofemoral pain syndrome. *J Orthop Surg Res* 2021;16(1):128. doi: 10.1186/s13018-021-02251-6 [published Online First: 2021/02/12]
24. Pierrepont JW, Marel E, Baré JV, et al. Variation in femoral anteversion in patients requiring total hip replacement. *Hip international : the journal of clinical and experimental research on hip pathology and therapy* 2020;30(3):281-87. doi: 10.1177/1120700019848088 [published Online First: 2019/05/16]
25. Scorcelletti M, Reeves ND, Rittweger J, et al. Femoral anteversion: significance and measurement. *Journal of anatomy* 2020;237(5):811-26. doi: 10.1111/joa.13249 [published Online First: 2020/06/25]
26. Nelitz M. Femoral Derotational Osteotomies. *Current reviews in musculoskeletal medicine* 2018;11(2):272-79. doi: 10.1007/s12178-018-9483-2 [published Online First: 2018/04/27]
27. Tian G, Yang G, Zuo L, et al. Femoral derotation osteotomy for recurrent patellar dislocation. *Arch Orthop Trauma Surg* 2020;140(12):2077-84. doi: 10.1007/s00402-020-03598-x [published Online First: 2020/09/20]
28. Dall'Oca C, Maluta T, Micheloni GM, et al. Femoroacetabular impingement: biomechanical and dynamic considerations. *Acta bio-medica : Atenei Parmensis* 2014;85 Suppl 2:46-51. [published Online First: 2014/11/21]
29. Kaiser P, Attal R, Kammerer M, et al. Significant differences in femoral torsion values depending on the CT measurement technique. *Arch Orthop Trauma Surg* 2016;136(9):1259-64. doi: 10.1007/s00402-016-2536-3 [published Online First: 2016/08/10]
30. Stambough JB, Davis L, Szymanski DA, et al. Knee Pain and Activity Outcomes After Femoral Derotation Osteotomy for Excessive Femoral Anteversion. *Journal of pediatric orthopedics* 2018;38(10):503-09. doi: 10.1097/bpo.0000000000000874 [published Online First: 2016/09/17]

Figures

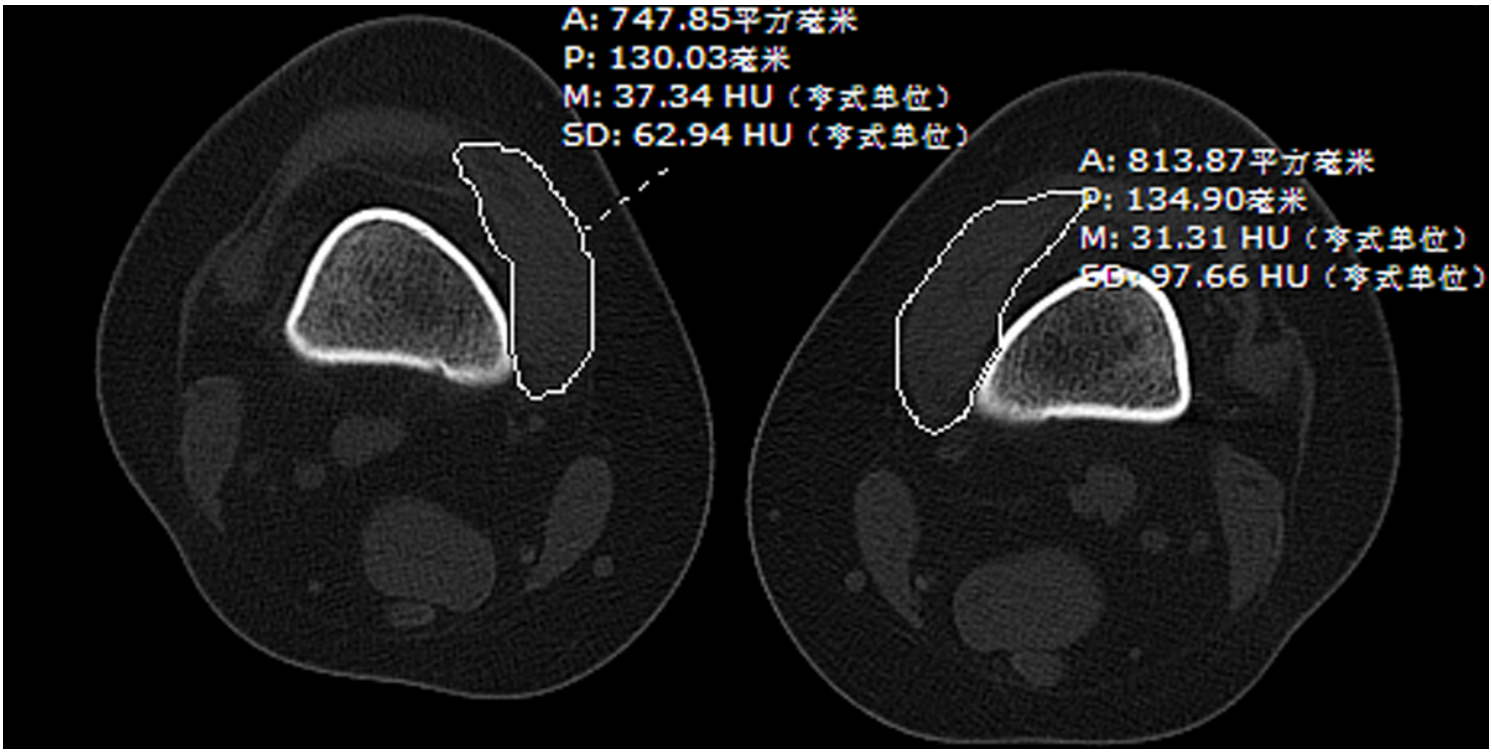

Figure 1

Measurement of the cross-sectional area of VMO and VML

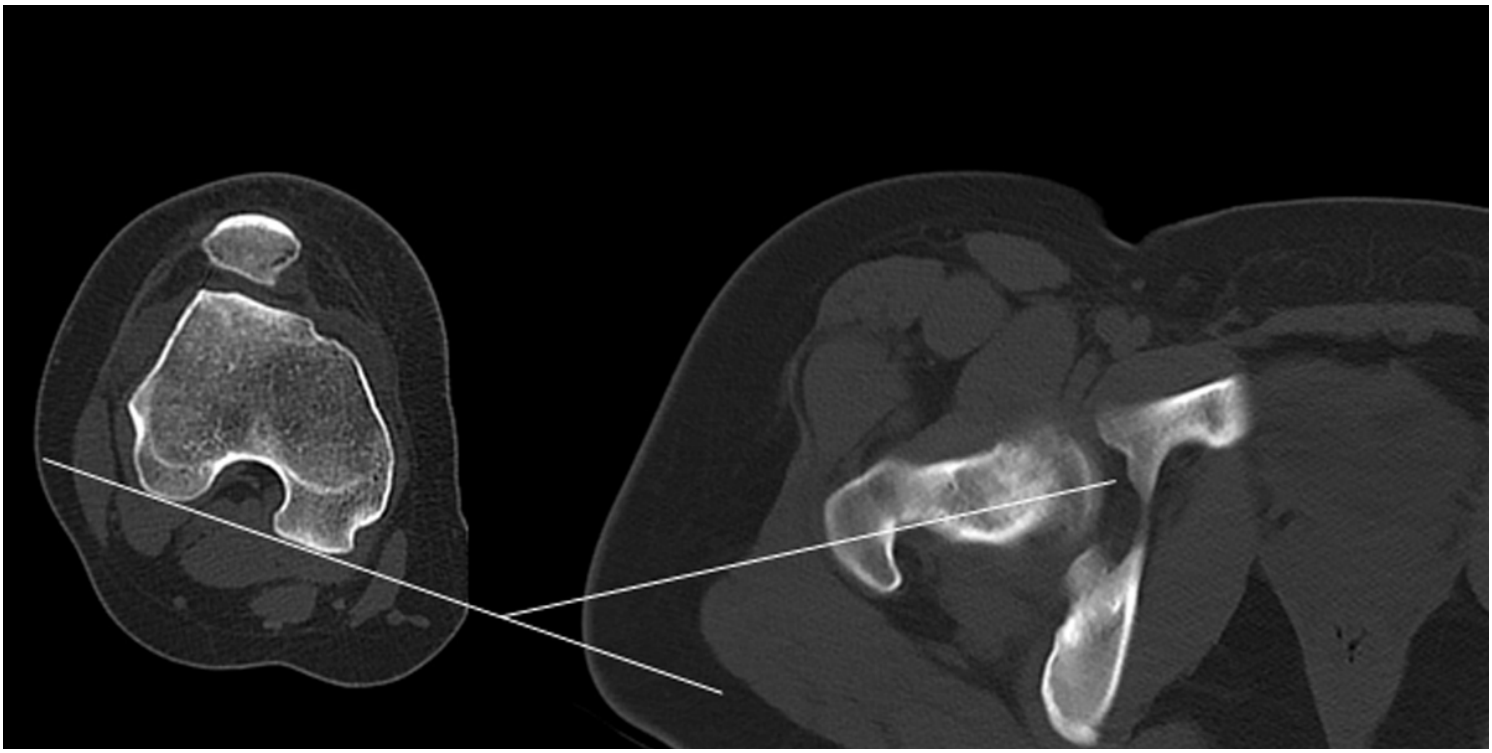

Figure 2

Measurement of FAA