Analysis of Related Influencing Factors of Hysterectomy in Patients With Placenta Accreta Spectrum Disorders After Uterine Artery Embolization

Duzhou Zheng
Third Affiliated Hospital of Guangzhou Medical College
Huawei Shen
Third Affiliated Hospital of Guangzhou Medical College
Mingxing Liu
Third Affiliated Hospital of Guangzhou Medical College
Shikuan Huang
Third Affiliated Hospital of Guangzhou Medical College
Weifeng Liu
Third Affiliated Hospital of Guangzhou Medical College
Mimi Zhou
Third Affiliated Hospital of Guangzhou Medical College
Mingjin Cai (mingjincai@163.com)
Third Affiliated Hospital of Guangzhou Medical College https://orcid.org/0000-0003-2915-7784

Research article

Keywords: Placenta accreta spectrum, Uterine artery embolization, Hysterectomy, Ovarian artery embolization, Placenta previa

Posted Date: November 9th, 2020

DOI: https://doi.org/10.21203/rs.3.rs-103137/v1

Abstract

Objective: To estimate the related factors of hysterectomy in patients with Placenta accreta spectrum (PAS) after uterine artery embolization (UAE), and try to evaluate the effectiveness and safety of UAE in patients with PAS.

Methods: From January 2012 to July 2020, a retrospective analysis was performed in 85 patients undergoing TAE for PAS. Information regarding clinical data, angiography as well as embolization details, and clinical outcomes was obtained. Univariate and multivariate analyses were performed to determine the factors related to hysterectomy.

Results: Bleeding greater than or equal to 500ml during the delivery(p = 0.037), the placenta type by MR or US(placenta increta vs placenta percreta, P = 0.01) and the type of ovarian artery(No vs Bilateral, P = 0.005; Unilateral vs Bilateral, P = 0.01) were independent risk factors of hysterectomy in PAS patients treated with UAE. The area under the curve (AUC) of the predictive model that incorporated the independent risk factors was 0.844. Abnormal collateral vessels communicating with uterine artery were observed on angiography in 24 patients (28.2%) with 31 abnormal collateral vessels. The major abnormal collateral vessel was the abnormal branches of the internal iliac artery(n = 13), followed by the inferior vesical artery (n = 11), internal pudendal artery(n = 3), obturator artery (n = 2), vaginal artery(n = 1) and the abnormal branches of the external iliac artery(n = 1).

Conclusions: TAE is safe and effective for patients with PAS. Bleeding greater than or equal to 500ml during the delivery, the placenta type by MR or US and the type of ovarian artery were related to the hysterectomy. For patients with hypertrophic ovarian-uterine artery anastomosis and no fertility requirements, Ovarian artery embolization(OAE) could be a feasible choice.

Introduction

The placenta accreta spectrum (PAS) had not been specifically defined in the past, it was generally called morbid placental adherence, and firstly defined as failure of separation of the placenta from the uterine wall following delivery of the human fetus by Irving et al. in 1937[1]. In order to better define lesions and guide clinical work, the latest guidelines suggested that the PAS should be subdivided into placenta accreta(where the villi attach directly to the surface of the myometrium without invading it), placenta increta(where the villi penetrate deeply into the myometrium up to the external layer) and placenta percreta(where the invasive villous tissue reaches and penetrates through the uterine serosa)[2, 3].

The incidence of PAS has increased substantially with the increase in the global caesarean section rate[4, 5]. Prior cesarean section and placenta previa were the two most important risk factors for PA, and the risk of encountering PAS increased with placenta previa and the number of previous caesarean sections, which could even surge to 67 percent in women who had five or more cesarean sections[6–9]. There were still other factors related to PAS, such as other forms of uterine surgery, abnormal endometrial histologic architecture, advanced maternal age, increasing parity and so on[10].

Regarding the diagnosis of placenta accreta, the sensitivity of prenatal ultrasound for the diagnosis of placental hyperplasia is 55% ~ 90%, and the specificity is nearly 88% ~ 98% according to previous reports [11, 12]. Although the sensitivity of ultrasound diagnosis of PAS had relatively large fluctuations, it had enhanced the prenatal diagnosis rate of PAS to a certain extent. The diagnostic efficacy of prenatal ultrasound for PAS was affected by many factors, such as the pregnancy stages, location of the accreta, ultrasonographic quality, ultrasonographer skill, and clinician experience, etc.[10].

As for MRI, another important diagnostic tool for prenatal diagnosis, the latest systematic review and meta-analysis of MRI in identifying invasive placentation showed a sensitivity of 94.4%, a specificity of 84.0%, a positive likelihood ratio of 5.91, and a negative likelihood ratio of 0.07[13]. Therefore, MRI can predict depth of invasion and topography of invasion in PAS with high accuracy through specific signs on the T2-weighted image, such as uterine bulging, heterogeneous signal intensity, focal interruption of the myometrium, bladder tenting, and dark intraplacental bands[13, 14]. However, compared MRI to ultrasonography, the review found no difference in sensitivity or specificity in identifying PAS[13]. In short, ultrasound and MRI had high prenatal diagnostic value for PAS, which could make interventions in advance and improve the prognosis to some extent[15].

The chief surgical treatment for PAS is total hysterectomy or subtotal hysterectomy. The main complications of surgery are the risk of massive bleeding, blood transfusion, and the possibility of urinary tract injury. For complicated PAS, planned delayed hysterectomy can reduce the occurrence of complications to some extent[16]. For the conservative treatment of PAS, leaving the placenta in situ approach, some additional procedures can assist it, such as gentle attempted removal of the placenta, methotrexate adjuvant treatment and preventive surgical or radiological uterine devascularization[17]. Selvan Pather and Loïc Sentilhes et al. revealed that the overall success rate of uterine preservation was 60% and 78%, respectively[18, 19]. Regarding the effect of UAE on the treatment of placental implants, several studies had shown that UAE could reduce bleeding and transfusion[20–22].

In patients with PAS, despite tending to conservative treatment and undergoing UAE treatment, the rate of hysterectomy is still very high. Therefore, our study is mainly to explore the related factors of hysterectomy in patients with PAS after UAE.

Materials And Methods

Patient selection

This study was approved by our institutional review board. There were 91 consecutive patients who had PAS and performed the UAE during treatment at our tertiary care obstetric center (The Third Affiliated Hospital of Guangzhou Medical University) from January 2012 to July 2020. The patients with PAS and placental residues, who were discharged from a hospital for improvement of conservative treatment and re-hospitalized with bleeding symptoms one month later since the delivery, were excluded(N = 6). The remaining 85 patients who had postpartum hemorrhage in one months since the delivery were enrolled in

our study for analysis. Relative patient data, obstetrical history, blood loss, blood transfusions, diagnostic imaging, and characteristics of TAE are summarized in Table 1.

Table 1
Comparison of general clinical data between the two groups

Characteristics	Overall	hysterectomy(-)	hysterectomy(+)	p value
	85	N = 70	N = 15	
ages(years)				0.781
30	31	26	5	
=30	54	44	10	
The pregnancy stages				0.876
early pregnancy	3	3	0	
mid-term pregnancy	53	44	9	
late pregnancy	29	23	6	
The number of pregnancy				0.313
History of cesarean section				0.642
yes	61	49	12	
no	24	21	3	
Type of delivery				0.546
cesarean delivery	45	36	9	
vaginal delivery	40	34	6	
Bleeding during the delivery				0.020[a]
500 ml	51	46	5	
=500 ml	34	24	10	
Blood transfusions(RBC)				0.015[a]
4u	62	56	6	
=4u	23	15	8	
Timing of intervention				0.638
UAE before delivery	67	54	13	
UAE after delivety	18	16	2	
The placenta type by MRI or US				0.009[a]

PAS, placenta accreta spectrum; RBC, red blood cell; UAE, uterine artery embolizaton; MRI,magnetic resonance imaging; US, ultrasound; GSP: gelatin sponge particles; a—statistical significance.

Characteristics	Overall	hysterectomy(-)	hysterectomy(+)	p value
placenta accreta	7	7	0	
placenta increta	66	57	9	
placenta percreta	12	6	6	
Placenta previa				0.013a
yes	56	42	14	
no	29	28	1	
Collateral vessels				0.867
yes	24	19	5	
no	61	51	10	
Type of ovarian artery				0.006[a]
No	45	40	5	
Unilateral	29	25	4	
Bilateral	11	5	6	
Embolic agents				1.000
GSP alone	75	62	13	
GSP + microcoils	10	8	2	

PAS, placenta accreta spectrum; RBC, red blood cell; UAE, uterine artery embolizaton; MRI,magnetic resonance imaging; US, ultrasound; GSP: gelatin sponge particles; a—statistical significance.

Diagnosis and treatment

The prenatal diagnosis of PAS in this study was mainly through US or MRI. When ultrasound indicated suspected PAS, further MRI would be routinely performed to determine the depth and scope of invasion(as shown in the Fig. 1), unless the patient was in emergency situations such as massive blood loss and hemodynamic instability. Both US and MR diagnosis of PAS were performed by two physicians at the deputy director level or above.

For patients with PAS diagnosed by US or MRI before surgery, obstetrical history, diagnostic imaging and clinical symptoms were used to determine whether to deliver by caesarean section or vaginal delivery. Patients with a history of cesarean section tended to choose cesarean section to terminate the pregnancy, except in the early pregnancy and the fetus was small enough, they would try vaginal delivery firstly and the cesarean section would be performed immediately to terminate the pregnancy after the failure of vaginal delivery. For patients with no previous history of cesarean section, tried vaginal delivery first, and performed cesarean section if vaginal delivery failed.

Regarding the placenta, after the fetus was delivered, had a try to remove the placenta manually. If the placenta was difficult to remove the placenta, leave the placenta in the situ and take other conservative measures.

Hysterectomy depended on the intraoperative evaluation of the depth and scope of placental invasion, intraoperative blood loss, and basic vital signs of the patient at cesarean section. And hysterectomy was also performed in patients after the failure of the conservative treatment.

The decision and the time to perform UAE were made after a discussion between the obstetricians and interventional radiologists. Without retaining fetus, UAE was routinely performed in patients with prenatal diagnosis of placental implantation or penetration, high-risk factors with PAS, and stable basic vital signs before the delivery. If the fetus needed to be retained, UAE was performed after the delivery of the fetus. In addition, UAE was also used as a means of hemostasis for patients who had prenatal diagnosis of placental accreta but with bleeding after delivery and patients with PAS had a symptom of bleeding after emergency cesarean section.

Angiography and embolization technique

Emergency digital subtraction angiography and TAE were performed by two interventional radiologists with more than 25 years of clinical experience. A 5-F vascular sheath was inserted into the right common femoral artery.

Firstly, the initial aortography was performed at the level of renal arteries with a 5-Fr pigtail catheter (Terumo Corp., Tokyo, Japan) to identify the uterine artery and/or other potential bleeding sites. A 5-Fr Yashiro catheter (Terumo Corp., Tokyo, Japan) was introduced over a 0.035-inch guidewire (Terumo Corp., Tokyo, Japan) to assess the internal iliac arteries and its branches such as uterine arteries.

Basically, bilateral uterine arteries were selected with a 5-Fr Yashiro catheter or a microcatheter (Terumo Corp), and the abnormal collaterals found were superselected with microcatheter as much as possible.

Bilateral uterine arteries and abnormal collaterals found are generally embolized with gelatin sponge (1000–1400 μm or 1400–2000 μm in size; Alicon, Hangzhou, China), meanwhile, microcoils (Cook, Bloomington, IN, USA) were used for laceration or malformation of blood vessels and proximal occlusion of thickened blood vessels with abundant blood supply to enhance and supplement the embolization.

The endpoint of embolization was the disappearance of placental staining, significantly decreased blood flow in bilateral uterine arteries and abnormal collateral vessels, and no signs of active bleeding during angiography.

A final angiogram was performed in confirm the occlusion of the target vessel and to identify any other potential abnormal collateral or bleeding arteries.

In principle, OAE was not performed since OAE was a procedure with unknown effects on fertility and might affect ovarian function, and we judged that bilateral uterine arteries and existing abnormal

collaterals were fully embolized based on uterine angiography. In the case of continuous active vaginal bleeding, an additional UAE or hysterectomy was considered.

According to the initial aortography, the type of ovarian artery was divided into three types; the Type No is without widened ovarian artery communicating with the uterine artery of a pregnant uterus, the Type Unilateral is with only unilateral hypertrophic ovarian artery communicating with the uterine artery of pregnant uterus and the Type Bilateral is with bilateral hypertrophic ovarian artery communicating with the uterine artery of a pregnant uterus, which was displayed in the Fig. 2.

Statistical analysis

All statistical analyses were performed using SPSS version 26.0 for Windows (IBM, Armonk, NY, USA statistical software). Continuous data were expressed as means ± SD. Categorical data are expressed as n (%). Categorical variables were compared using the Chi-square or Fisher's exact test. Factors for hysterectomy were evaluated through univariate and multivariate logistic regression analyses. Variables found significant by univariate logistic regression analysis were considered candidate variables for multivariate analysis. A two-sided p-value < 0.05 was considered statistically significant.

Results

Patient characteristics

Data from 85 patients (age 20 to 45 years; mean age ± sd, 31 ± 5.9 years) with PAS who met the inclusion criteria were included in the analyses. The medical records of patients were retrospectively reviewed. Each subgroup was classified according to the outcome, with 17.6% (*N* = 15) of cases assigned to the hysterectomy group and 82.4% (*N* = 70) of cases assigned to the non-hysterectomy group. Clinical parameters included age, the pregnancy stages, the number of pregnancy, history of cesarean section, the type of delivery, bleeding during the delivery, timing of intervention, blood transfusions(RBC), the placenta type by MR or US, placenta previa, collateral vessels, type of ovarian artery and embolic agents are summarized in Table 1. Patients were more likely to be performed the hysterectomy surgery with bleeding during the delivery(more than 500 ml, p = 0.02), blood transfusions(RBC, more than 4 units, p = 0.015), placenta percreta(p = 0.009) and the type of ovarian artery(the Type Bilateral, p = 0.006).

Logistic regression analysis of factors affecting the rate of hysterectomy

Univariate analyses the related factors of hysterectomy identified the bleeding during the delivery [odds ratio (OR), (95% confidence interval, CI) = 3.83 (1.18–12.49), p = 0.026], the blood transfusions(RBC) [odds ratio (OR), (95% confidence interval, CI) = 4.19 (1.31–13.42), p = 0.016], the placenta type by MR or US(placenta increta vs placenta percreta)[odds ratio (OR), (95% confidence interval, CI) = 0.16 (0.04–0.60), p = 0.007], placenta previa[odds ratio (OR), (95% confidence interval, CI) = 9.33(1.16-75.0), p = 0.036]

and the type of ovarian artery(Unilateral vs Bilateral)[OR (95% CI) = 0.13 (0.03–0.65), p = 0.013] as significantly associated with the performance of the hysterectomy(Table 2).

Table 2
Results of logistic analysis of hysterectomy related factors in pregnancy patients with PAS after UAE

Variables	Logistic univariate regression		Logistic multivariate regression	
	RR	P value	RR(95%CI)	P value
Bleeding during the delivery	3.83(1.18–12.49)	0.026[a]	4.48(1.10-18.31)	0.037[a]
500 ml				
=500 ml				
Blood transfusions(RBC)	4.19(1.31–13.42)	0.016[a]	—	—
4u				
=4u				
The placenta type by MR or US				
placenta accreta	0	0.999	—	0.999
placenta increta	0.16(0.04–0.60)	0.007[a]	0.13(0.03–0.61)	0.010[a]
placenta percreta	reference	0.025[a]	reference	0.035[a]
Placenta previa	9.33(1.16-75.0)	0.036[a]	—	—
yes				
no				
Type of ovarian artery				
No	0.10(0.02–0.47)	0.003[a]	0.075(0.012–0.458)	0.005[a]
Unilateral	0.13(0.03–0.65)	0.013[a]	0.083(0.013–0.551)	0.010[a]
Bilateral	reference	0.009[a]	reference	0.012[a]

Logistic multivariate regression with forward likelihood selection; PAS, placenta accreta spectrum; UAE, uterine artery embolizaton;RR—relative risk;CI—confidence interval; RBC, red blood cell; MRI,magnetic resonance imaging; US, Ultrasound; [a]—statistical significance.

In multivariate logistic regression models as shown in Table 2, bleeding greater than or equal to 500 ml during the delivery was associated with the higher rate of hysterectomy, with an odds ratio [OR; 95% confidence interval (CI)] of 4.48 (1.10–18.31, p = 0.037). Additionally, the placenta type by MR or US(placenta increta vs placenta percreta) was the clear predictor of hysterectomy with ORs of 0.13(0.03–

0.61, P = 0.01). Finally the type of ovarian artery(No vs Bilateral, Unilateral vs Bilateral) was significantly correlated with the rate of the hysterectomy with ORs of 0.075(0.012–0.458, P = 0.005) and 0.083(0.013–0.551, P = 0.01) respectively, while the blood transfusions and placenta previa were not.

The predictors identified in the multivariate logistic regression analysis were used to construct the prediction model based on data, and the predictive value of the model was subsequently evaluated. ROC curves were generated to validate the ability of the logistic model to predict the possibility of hysterectomy (Fig. 3). The AUC index for the indicators was 0.844.

Characteristics and outcome of TAE

According to the initial aortography, the type of ovarian artery was divided into three types(Table 1); the Type No was shown in 52.94% patients, the Type Unilateral was shown in 34.12% patients and the Type Bilateral was shown in 12.94% patients, with a respective hysterectomy rate of 11.1%, 13.8% and 54.5%.

Abnormal collateral vessels communicating with uterine artery were observed on angiography in 24 patients (28.2%) that a patient could have more than one collateral vessel. The abnormal branches of the internal iliac artery were the most frequent abnormal collateral vessels (n = 13), followed by the inferior vesical artery (n = 11), internal pudendal artery(n = 3), obturator artery (n = 2), vaginal artery(n = 1) and the abnormal branches of the external iliac artery(n = 1), which was shown in Table 3.

Table 3
Frequency of the abnormal branches supplying to the uterus in the patients with PAS

Arteries	N
Inferior vesical artery	11
Obturator artery	2
Internal pudendal artery	3
vaginal artery	1
Abnormal branches of the internal iliac artery	13
Abnormal branches of the external iliac artery	1
Total	31
PAS, placenta accreta spectrum; N,number;	

Although the TAE was technically successfully performed in the pregnant patients with the PAS, 17.6% of the patients (15 of 85) had performed a hysterectomy to stop bleeding. Three of the 85 patients underwent repeat UAE, two of the three successfully stopped bleeding and retained the uterus, and one had to performed hysterectomy to stop bleeding. 12 patients among the 85 patients developed low-grade fever 1–2 days after UAE without other serious complications such as infection, severe fever and

pulmonary embolism. All patients in the non-hysterectomy group recovered their normal menstrual cycle within 2–3 months after UAE.

Discussion

Our research mainly focused on pregnant patients with PAS. The purpose of the research was to analyze the relevant clinical factors that affect hysterectomy. Through univariate and multivariate logistic regression analysis, we found that the rate of hysterectomy was related to the bleeding during the delivery, the placenta type by MR or US and the type of ovarian artery.

In our research, the rate of hysterectomy in the group with a bleeding volume greater than or equal to 500 ml was 29.4%, while that in the group with a bleeding volume less than 500 ml was 9.8%. There is no doubt that bleeding is related to hysterectomy for the reason that failure to stop bleeding in time will result in unstable hemodynamics and even hemorrhagic shock that endangers the patient's life. Currently, there is no direct study on the relationship between hysterectomy rate and bleeding in patients with PAS after the UAE. Previous study had shown that the average bleeding volume of patients with PAS after successfully retaining the uterus with preoperative UAE was about 400ml[20]. Based on this, it was speculated that a larger bleeding volume may lead to a bad outcome and a higher hysterectomy rate.

In addition, in our study, we found that the hysterectomy rate of patients with PAS was related to the type of placenta diagnosed by prenatal MR or ultrasound. We used the MR and US imaging features of PAS and combined the depth of implantation to divide them into placenta accreta, placenta increta and placenta percreta. The hysterectomy rate of penetrating placenta accreta was 50%, which was higher than the hysterectomy rate of placenta increta and placental accreta, which were 15.8%% and 0% respectively. Some scholars revealed that the depth of placenta implantation was associated with the severity of outcomes; A large-scale retrospective analysis in China found that the hysterectomy rate for penetrating placenta accreta was 43.3%, and the hysterectomy rate for placental accreta was 11.2%, which were statistically significant and similar to our research[23]. Another study also showed the rate of hysterectomy during cesareans and the total hysterectomy rate were significantly higher in the percreta than the accreta group (52.9% vs 20.9%, 84.3%vs 23.8%). Compared to our research, the rate of hysterectomy during cesareans was similar to our study, while the total hysterectomy rate in the percreta group was quite higher than our results(50%)[24]. It was speculated that this was related to the fact that the patients included in our study were diagnosed with PAS by US or MR before surgery and trended to make adequate preparations to prevent severe bleeding, such as UAE, which could reduce the rate of hysterectomy, to some extent[25]. Moreover, for patients with stable hemodynamics and no life-threatening bleeding, we preferred to leave the placenta in situ when the implanted placenta could not be separated from the uterine wall, which could reduce the occurrence of major bleeding that might cause emergency hysterectomy to a certain extent[26, 27].

In last, our research demonstrated that the ovarian artery flow defined by initial aortography as having three types was predictive of failure of UAE and the need of hysterectomy. In contrast to the type Bilateral,

the type No and the type Unilateral had the lower rate of hysterectomy(11.1%vs 54.5%, 13.8%vs 54.5%), which was statistically significant. At present, no studies have been reported on the blood supply of the ovaries in patients with placental implants. However, the study of Makoto Aoki et al. revealed that the ovarian artery flow might lead to the failure of UAE and the subsequent hysterectomy in patients with primary postpartum hemorrhage[28]. Similarly, several scholars shown that OAE to be an effective and safe adjunct to UAE when hypertrophic ovarian artery(ies) require intervention among the patients with the uterine fibroids[29, 30]; Hyun S Kim et al. found that Uteroovarian anastomoses in young patients are associated with higher rates of repeat intervention after UAE[31]. Several researches above had shown to a certain extent that the failure of UAE was related to uterine-ovarian anastomosis, especially the ovarian artery could be greatly dilated during pregnancy to accommodate the increased blood flow[32]. Based on this, it was speculated that the bilateral hypertrophic ovarian-uterine anastomosis perhaps had a larger blood supply to the uterus that was temporarily ischemic due to UAE at early stages, which led to the failure of UAE and had to perform repeated UAE or hysterectomy to stop bleeding.

Although some patients' initial aorta angiography showed hypertrophic ovarian-uterine artery anastomoses, all ovarian arteries were not superselected and embolized for the uncertainty of the supplementary embolization effect of OAE to UAE and the impact on fertility potential.

In spite of some studies had shown that UAE did not affect the pregnancy rate of patients[33], there were also some studies that had shown that UAE could increase the rate of PAS, miscarriage in patients and other Pregnancy complications[34–36]. Especially in pregnant patients who had the hypertrophic ovarian-uterine artery anastomoses, the embolic material might reach the ovary through the anastomoses so that ovarian function and fertility might be affected somehow[37, 38].

As for the abnormal branches, although it was not associated with the rate of hysterectomy, 28.2% (24/85) of patients with PAS in our study had the abnormal branches that supply to the uterus. However, abnormal branches were present in 39.3% (24/61) of patients with a history of cesarean section, not in patients without a history of cesarean Sect. 45.83% (11/24) of patients with PAS had more than one abnormal branch in our study.

The abnormal branch of the internal iliac artery was the most commonly involved artery, accounting for 42% of all abnormal blood branch vessels in our study. The second most common collateral vessel was the inferior vesical artery, which accounts for 35.5% of all abnormal blood vessels, and the internal pudendal artery, the obturator artery, the vaginal artery as well as the abnormal branches of the external iliac artery together accounted for the remaining 22.5%. Cesarean section surgery easily led to adhesion of the surgical incision and surrounding pelvic tissues. It was speculated that the incision of cesarean section was related to the abnormal connection of small branches of internal iliac artery. Therefore, Careful attention should be paid to the collateral vessels when performing UAE for the reason that patients with a history of cesarean section are more likely to have complicated collateral vessels supplying the uterus.

In our study, ten patients used gelatin sponge and microcoils to supplement and strengthen the embolization effect. One was because of uterine arteriovenous malformations, and the rest was because of the abundant blood supply to the placenta from uterine arteries.

Regarding the complications of UAE, there were no serious complications such as uterine necrosis, perforation, and pulmonary embolism in this study. Only 14.1%(12/85)of patients had symptoms of low fever after UAE.

Our study had several limitations, one of which was its retrospective design. In addition, hematologic parameters and time interval between delivery and embolization were not included in the analysis. Furthermore, our study did not have long-term follow-up to evaluate the impact of UAE on fertility and ovarian function. Nevertheless, one of the strengths of our study was the first study to study hysterectomy-related factors in patients with PAS after the treatment of UAE, this study also revealed the frequency of abnormal collaterals after cesarean section and included the factors of uterine-ovarian artery anastomosis to analysis.

Conclusions

In conclusion, among the patients with PAS, even though with UAE, those had the high risk of hysterectomy with bleeding not less than 500 ml during the delivery, placenta percreta and hypertrophic ovarian-uterine artery anastomoses. In the patients with the hypertrophic ovarian-uterine artery anastomoses in the initial abdominal aortography, ovarian artery embolism may be a viable option for those without re-pregnancy requirements.

Abbreviations

PAS Placenta accreta spectrum; UAE Uterine artery embolization; US Ultrasound; MR Magnetic resonance imaging; OAE Ovarian artery embolization

Declarations

Ethics approval and consent to participate

This study was approved by Third Affiliated Hospital of Guangzhou Medical University ethics committee and the need for informed consent was waived. All participants recruited in this study provided informed written consent.

Consent for publication

Not applicable.

Availability of data and materials

The datasets analysed during the current study are available from the corresponding author on reasonable request.

Competing interests

The authors declare that they have no conflict of interest.

Funding

This study was not supported by any funding.

Authors'contributions

DZZ and MJC designed the study. MJC was the principal investigator of the study. DZZ was the lead contributor in writing the manuscript. HWS and MMZ helped analyse the data and contributed to writing the manuscript. MXL is co-investigator of the study. SKH and WFL did the collecting data and interpreted the data. All authors read and approved the final manuscript.

Acknowledgments

We thank the patients for participating in this study.

References

1. Henske WC: **A study of placenta accreta**. *Am J Obstet Gynecol* 1939, **38**(6).
2. Jauniaux E, Chantraine F, Silver RM, Langhoff-Roos J: **FIGO consensus guidelines on placenta accreta spectrum disorders: Epidemiology**. *Int J Gynaecol Obstet* 2018, **140**(3):265-273.
3. Jauniaux E, Jurkovic D: **Placenta accreta: pathogenesis of a 20th century iatrogenic uterine disease**. *Placenta* 2012, **33**(4):244-251.
4. Higgins MF, Monteith C, Foley M, O'Herlihy C: **Real increasing incidence of hysterectomy for placenta accreta following previous caesarean section**. *Eur J Obstet Gynecol Reprod Biol* 2013, **171**(1):54-56.
5. Solheim KN, Esakoff TF, Little SE, Cheng YW, Sparks TN, Caughey AB: **The effect of cesarean delivery rates on the future incidence of placenta previa, placenta accreta, and maternal mortality**. *J Matern Fetal Neona* 2011, **24**(11):1341-1346.
6. Jauniaux E, Alfirevic Z, Bhide AG, Belfort MA, Burton GJ, Collins SL, Dornan S, Jurkovic D, Kayem G, Kingdom J *et al*: **Placenta Praevia and Placenta Accreta: Diagnosis and Management: Green-top Guideline No. 27a**. *BJOG* 2019, **126**(1).
7. Silver RM, Landon MB, Rouse DJ, Leveno KJ, Spong CY, Thom EA, Moawad AH, Caritis SN, Harper M, Wapner RJ *et al*: **Maternal morbidity associated with multiple repeat cesarean deliveries**. *Obstet Gynecol* 2006, **107**(6):1226-1232.
8. Usta IM, Hobeika EM, Musa AAA, Gabriel GE, Nassar AH: **Placenta previa-accreta: risk factors and complications**. *Am J Obstet Gynecol* 2005, **193**(3 Pt 2):1045-1049.

9. Hung TH, Shau WY, Hsieh CC, Chiu TH, Hsu JJ, Hsieh TT: **Risk factors for placenta accreta**. *Obstet Gynecol* 1999, **93**(4):545-550.
10. Silver RM, Barbour KD: **Placenta accreta spectrum: accreta, increta, and percreta**. *Obstet Gynecol Clin North Am* 2015, **42**(2):381-402.
11. Japaraj RP, Mimin TS, Mukudan K: **Antenatal diagnosis of placenta previa accreta in patients with previous cesarean scar**. *The journal of obstetrics and gynaecology research* 2007, **33**(4):431-437.
12. Bowman ZS, Eller AG, Kennedy AM, Richards DS, Winter TC, Woodward PJ, Silver RM: **Accuracy of ultrasound for the prediction of placenta accreta**. *Am J Obstet Gynecol* 2014, **211**(2):177.e171-177.e177.
13. D'Antonio F, Iacovella C, Palacios-Jaraquemada J, Bruno CH, Manzoli L, Bhide A: **Prenatal identification of invasive placentation using magnetic resonance imaging: systematic review and meta-analysis**. *Ultrasound Obstet Gynecol* 2014, **44**(1).
14. Sun H, Qu H, Chen L, Wang W, Liao Y, Zou L, Zhou Z, Wang X, Zhou S: **Identification of suspicious invasive placentation based on clinical MRI data using textural features and automated machine learning**. *European radiology* 2019, **29**(11):6152-6162.
15. Warshak CR, Ramos GA, Eskander R, Benirschke K, Saenz CC, Kelly TF, Moore TR, Resnik R: **Effect of predelivery diagnosis in 99 consecutive cases of placenta accreta**. *Obstet Gynecol* 2010, **115**(1):65-69.
16. Allen L, Jauniaux E, Hobson S, Papillon-Smith J, Belfort MA: **FIGO consensus guidelines on placenta accreta spectrum disorders: Nonconservative surgical management**. *Int J Gynaecol Obstet* 2018, **140**(3):281-290.
17. Sentilhes L, Kayem G, Chandraharan E, Palacios-Jaraquemada J, Jauniaux E: **FIGO consensus guidelines on placenta accreta spectrum disorders: Conservative management**. *Int J Gynaecol Obstet* 2018, **140**(3):291-298.
18. Pather S, Strockyj S, Richards A, Campbell N, de Vries B, Ogle R: **Maternal outcome after conservative management of placenta percreta at caesarean section: a report of three cases and a review of the literature**. *Aust N Z J Obstet Gynaecol* 2014, **54**(1):84-87.
19. Sentilhes L, Ambroselli C, Kayem G, Provansal M, Fernandez H, Perrotin F, Winer N, Pierre F, Benachi A, Dreyfus M *et al*: **Maternal outcome after conservative treatment of placenta accreta**. *Obstet Gynecol* 2010, **115**(3):526-534.
20. Xie L, Wang Y, Man YC, Luo FY: **Preliminary experience in uterine artery embolization for second trimester pregnancy induced labor with complete placenta previa, placenta implantation, and pernicious placenta previa**. *Clin Exp Obstet Gynecol* 2017, **44**(1):81-84.
21. Niola R, Giurazza F, Nazzaro G, Silvestre M, Nasti G, Di Pasquale MA, Albano G, Valentino L, Sirimarco F, Maglione F: **Uterine Artery Embolization before Delivery to Prevent Postpartum Hemorrhage**. *Journal of vascular and interventional radiology : JVIR* 2016, **27**(3):376-382.
22. D'Antonio F, Iacovelli A, Liberati M, Leombroni M, Murgano D, Cali G, Khalil A, Flacco ME, Scutiero G, Iannone P *et al*: **Role of interventional radiology in pregnancy complicated by placenta accreta**

spectrum disorder: systematic review and meta-analysis. *Ultrasound Obstet Gynecol* 2019, **53**(6):743-751.

23. Zhang H, Dou R, Yang H, Zhao X, Chen D, Ding Y, Ding H, Cui S, Zhang W, Xin H *et al*: **Maternal and neonatal outcomes of placenta increta and percreta from a multicenter study in China**. *J Matern Fetal Neona* 2019, **32**(16):2622-2627.
24. Marcellin L, Delorme P, Bonnet MP, Grange G, Kayem G, Tsatsaris V, Goffinet F: **Placenta percreta is associated with more frequent severe maternal morbidity than placenta accreta**. *Am J Obstet Gynecol* 2018, **219**(2):193.e191-193.e199.
25. Wang J, Shi X, Li Y, Li Z, Chen Y, Zhou J: **Prophylactic intraoperative uterine or internal iliac artery embolization in planned cesarean for pernicious placenta previa in the third trimester of pregnancy: An observational Study (STROBE compliant)**. *Medicine (Baltimore)* 2019, **98**(44):e17767.
26. O'Brien JM, Barton JR, Donaldson ES: **The management of placenta percreta: conservative and operative strategies**. *Am J Obstet Gynecol* 1996, **175**(6):1632-1638.
27. Cui R, Li M, Lu J, Bai H, Zhang Z: **Management strategies for patients with placenta accreta spectrum disorders who underwent pregnancy termination in the second trimester: a retrospective study**. *BMC Pregnancy Childbirth* 2018, **18**(1):298.
28. Aoki M, Tokue H, Miyazaki M, Shibuya K, Hirasawa S, Oshima K: **Primary postpartum hemorrhage: outcome of uterine artery embolization**. *Br J Radiol* 2018, **91**(1087):20180132.
29. Pelage JP, Walker WJ, Le Dref O, Rymer R: **Ovarian artery: angiographic appearance, embolization and relevance to uterine fibroid embolization**. *Cardiovascular and interventional radiology* 2003, **26**(3):227-233.
30. Campbell J, Rajan DK, Kachura JR, Jaskolka J, Beecroft JR, Sniderman KW, Simons ME, Tan KT: **Efficacy of Ovarian Artery Embolization for Uterine Fibroids: Clinical and Magnetic Resonance Imaging Evaluations**. *Can Assoc Radiol J* 2015, **66**(2):164-170.
31. Kim HS, Paxton BE, Lee JM: **Long-term efficacy and safety of uterine artery embolization in young patients with and without uteroovarian anastomoses**. *Journal of vascular and interventional radiology : JVIR* 2008, **19**(2 Pt 1):195-200.
32. Wang MQ, Liu FY, Duan F, Wang ZJ, Song P, Song L: **Ovarian artery embolization supplementing hypogastric-uterine artery embolization for control of severe postpartum hemorrhage: report of eight cases**. *Journal of vascular and interventional radiology : JVIR* 2009, **20**(7):971-976.
33. Keung JJ, Spies JB, Caridi TM: **Uterine artery embolization: A review of current concepts**. *Best practice & research Clinical obstetrics & gynaecology* 2018, **46**:66-73.
34. David M, Kröncke T: **Uterine Fibroid Embolisation - Potential Impact on Fertility and Pregnancy Outcome**. *Geburtshilfe Frauenheilkd* 2013, **73**(3):247-255.
35. El-Miligy M, Gordon A, Houston G: **Focal myometrial defect and partial placenta accreta in a pregnancy following bilateral uterine artery embolization**. *Journal of vascular and interventional radiology : JVIR* 2007, **18**(6):789-791.

36. Goldberg J, Pereira L, Berghella V: **Pregnancy after uterine artery embolization**. *Obstet Gynecol* 2002, **100**(5 Pt 1):869-872.
37. Kim HS, Thonse VR, Judson K, Vang R: **Utero-ovarian anastomosis: histopathologic correlation after uterine artery embolization with or without ovarian artery embolization**. *Journal of vascular and interventional radiology : JVIR* 2007, **18**(1 Pt 1):31-39.
38. Sheikh GT, Najafi A, Cunier M, Hess TH, Binkert CA: **Angiographic Detection of Utero-Ovarian Anastomosis and Influence on Ovarian Function After Uterine Artery Embolization**. *Cardiovascular and interventional radiology* 2020, **43**(2):231-237.

Figures

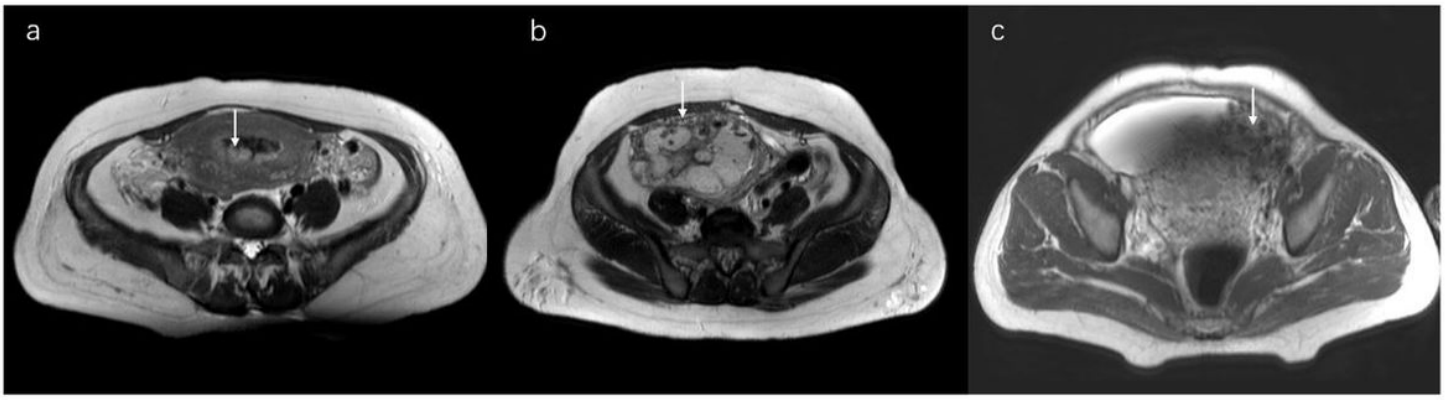

Figure 1

The abnormal MRI manifestation of placenta accreta, placenta increta and placenta percreta. Figure a: In the Axial T2-weighted MR image , equal length T2 signals could be seen in the uterine cavity(arrowhead), and the internal signals were heterogeneous, attached to the right and posterior wall of the uterus, and the boundary with the local muscle layer was unclear and jagged. Figures b: T2-weighted MR image displayed the main body of the placenta was attached to the inferior wall-posterior wall of the uterus, and the internal signal was heterogeneous, with sheet-like low signal in it. The attachment surface between the lower part of the placenta and the anterior inferior wall of the uterus was not smooth, and the local blood vessel flow signal was slightly rich. The muscle layer of the lower part of the uterus becomes thin and the boundary with the placenta was not clear(arrowhead); Figure c : T2-weighted MR image showed that the placenta was located in the front and rear lower walls of the uterus, and the signals in the placenta are uneven, with multiple tortuous dilated blood vessels and banded low signal shadows. The low signal combined band before the anterior inferior wall of the placenta was interrupted, and the placental tissue was seen extending into the top wall of the bladder.

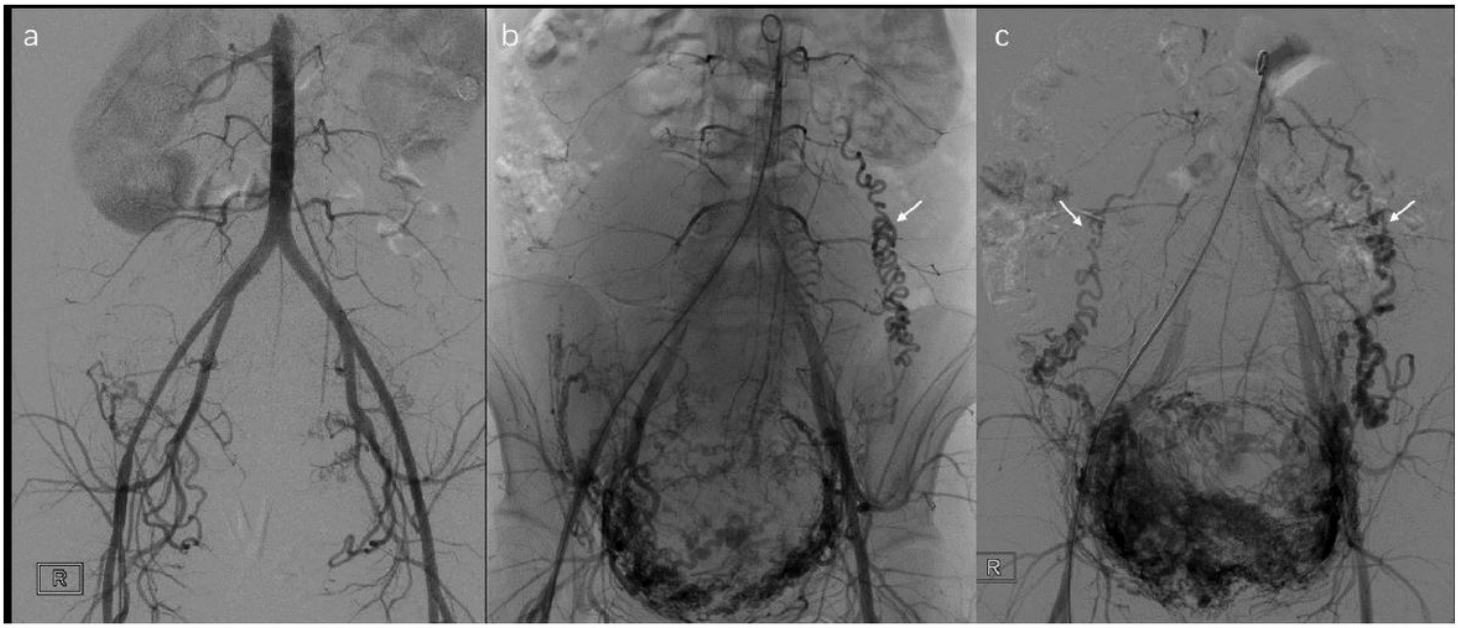

Figure 2

Different types of communication between ovarian artery and uterine artery. Figure a: Type No: uterine arteriography showed that there is no hypertrophic ovarian artery communicate with the uterine artery; Figure b: Type Unilateral: uterine arteriography shows that there is a unilateral hypertrophic ovarian artery communicating with the uterine artery; Figure c: Type Bilateral: uterine arteriography shows that there are bilateral hypertrophic ovarian arteries communicating with the uterine artery.

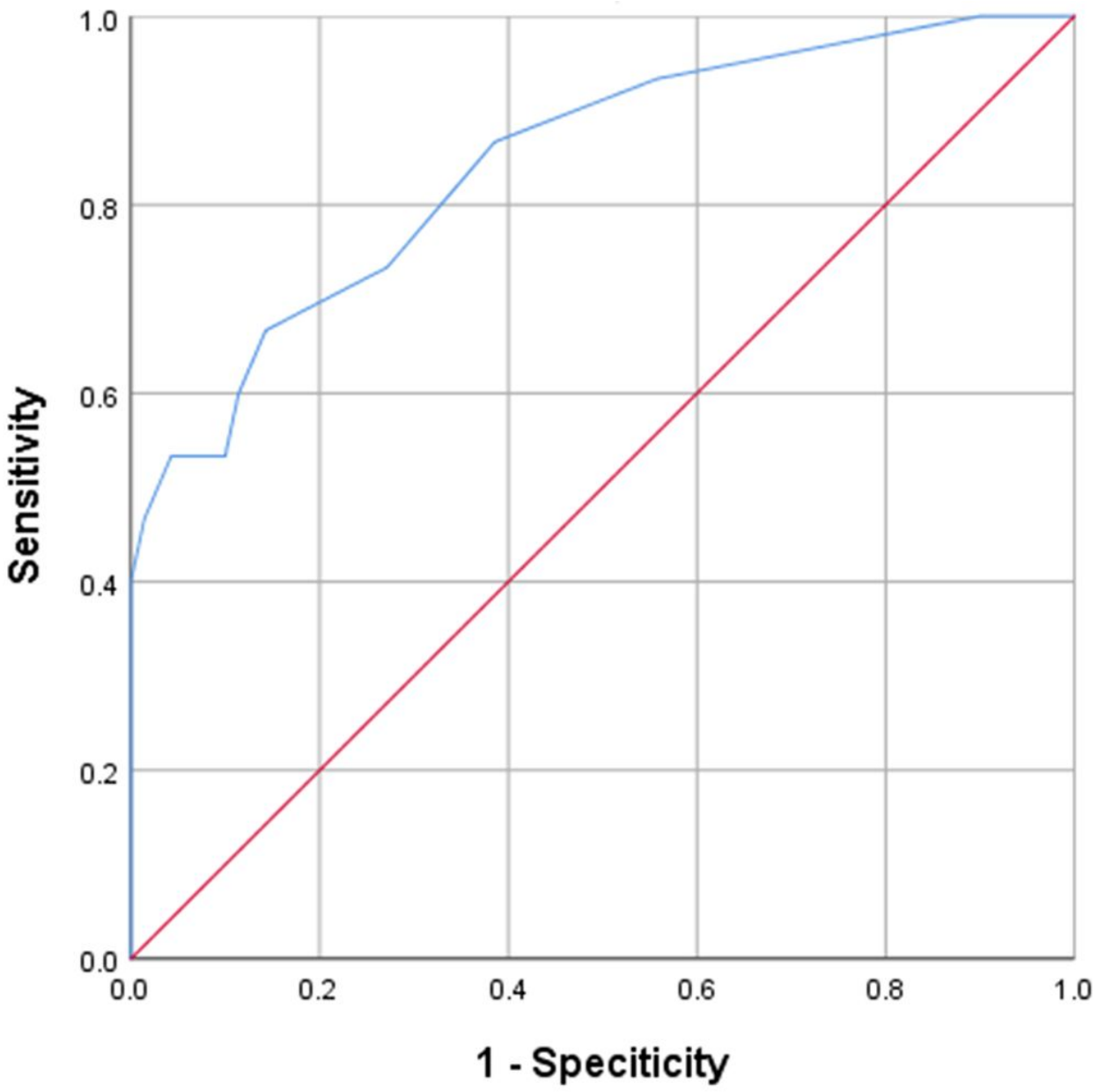

Figure 3

Predictive ROC curve of hysterectomy based on logic model. ROC curve were performed to predict whether the hysterectomy will occur based on the logit models. The AUC index was 0.844.