Research Square

Preprints are preliminary reports that have not undergone peer review. They should not be considered conclusive, used to inform clinical practice, or referenced by the media as validated information.

What Are the Results of Limb Salvage Surgery for Primary Malignant Bone Tumor in the Forearm?

Weifeng Liu (liuweifengjst@126.com)

Jishuitan Hospital and Fourth Medical College of Peking University: Beijing Jishuitan Hospital https://orcid.org/0000-0001-6935-3064

Yongkun Yang

Beijng Jishuitan Hospital

Tao Jin

Beijing Jishuitan Hospital

Yang Sun

Beijing Jishuitan Hospital

Yuan Li

Beijing Jishuitan Hospital

Lin Hao

Beijing Jishuitan Hospital

Qing Zhang

Beijing Jishuitan Hospital

Xiaohui Niu

Beijing Jishuitan Hospital

Research article

Keywords: forearm, sarcoma, limb salvage, recurrence, metastasis, prognosis

Posted Date: November 12th, 2020

DOI: https://doi.org/10.21203/rs.3.rs-103567/v1

License: This work is licensed under a Creative Commons Attribution 4.0 International License. Read Full License

Abstract

Background The forearm primary malignant bone tumor is rare and limb salvage is difficult. The purpose of this study was to analyze epidemiological characteristics of forearm primary malignant bone tumors and to explore oncological and functional results of limb salvage surgery in forearm.

Methods 369 patients with primary forearm malignant bone tumors were retrospectively analyzed from 2000 to 2017. There were 266 patients with radius tumor and 46 (17.3%) of them were malignancy, while 103 patients with ulna lesion and 22 (21.4%) of them were malignant tumor. The oncological results, prognostic factors and functional results after limb salvage surgery of forearm malignancy were analyzed.

Results A total of 60 patients received limb salvage surgery. Fifty-six patients followed more than 12 months or progressions within 12 months were included in final evaluation. Radius resection was performed in 38 patients and distal radius (25 patients) was most frequent. Ulna resection was performed in 18 patients and proximal ulna (13 patients) was most frequent. The surgical margin contained intracapsular resection in 3 patients, marginal resection in 8 patients and wide resection in 45 patients. The follow-up averaged 72.1 (7-192, median 62.5) months. Local recurrence occurred in 11 patients (19.6%) and distant metastasis occurred in 14 patients (25%). The 5-year recurrence free survival rates was 79.8%. Univariate analysis showed history of unplanned resection, tumor located in ulna, tumor located in proximal forearm and inadequate surgical margin were associated with recurrence. The overall 5-year and 10-year survival rates were 83.5% and 71.7%, respectively. Univariate analysis showed inadequate surgical margin, local recurrence and distant metastasis were associated with death. Forty-two patients were evaluated by MSTS score with an average of (93.0 ± 5.1) %.

Conclusions The incidence of radius malignant tumor is higher than that of ulna. The distal radius and proximal ulna are most frequency involved sites. Unplanned resection, tumor located in ulna, tumor located in proximal forearm and inadequate surgical margin are risk factors for local recurrence; local recurrence and distant metastasis are independent prognostic factors of death. The oncology control and function result of limb salvage surgery was satisfactory.

Background

Primary bone tumors of arising from ulna and radius are rare [1]. Benign tumors accounted for the majority of forearm tumors. Due to small size of muscles, there is often lack of enough space for tumor progression. There are many tendons in forearm responsible for fine movement of the hand and tumors often involve important structures in this narrow space. As a result, the hand function will be greatly damaged after wide resection of tumor. Amputation was considered to be the main surgical method for forearm malignant bone tumors. Muramatsu [2] suggested the key for local control of forearm tumor was safe surgical margin. The surgical margin of 5 cm in other sites is easy to be achieved, but it is difficult in the forearm. The reconstruction after tumor resection is also controversial and there are three problems: (1) some sarcomas are difficult to remove safely; (2) the defects and methods of reconstruction are various; (3) there are many reconstruction materials and fixation methods, which need individual design, the oncological evaluation and functional assessment need long-term follow up.

In this study, we included forearm primary malignant bone tumors for analysis, in order to clarify (1) the epidemiological characteristics; (2) the oncological results and related factors; (3) reconstruction methods and functional results after tumor resection.

Methods

1. Inclusion and Exclusion criteria

With institutional review board (IRB) approval, all patients in this study underwent limb salvage surgery for primary sarcoma of forearm. Inclusion criteria: (1) primary malignant tumor of radius/ulna; (2) limb salvage surgery with en bloc resection of tumor; (3) complete imaging and clinical data; (4) oncology results and complications can be evaluated; (5) follow-up time was more than 12 months, or oncological events (local recurrence, distant metastasis or death) occurred within 12 months. Exclusion criteria: (1) bone defect and reconstruction was not involved; (2) amputation; (3) no surgical treatment or rejection of treatment; (4) incomplete imaging and follow-up data.

2. General characteristics

A total of 369 patients with primary bone tumors of forearm treated in our hospital were analyzed retrospectively. There were 266 radius tumors and 48 patients (18.0%) were malignancy. There were 103 ulna tumors and 26 patients (25. 2%) were malignancy.

Local evaluation included X-ray, CT and MRI in forearm. Staging evaluation included chest CT and bone scan. Preoperative biopsy was performed for tumor with malignancy suspected. The surgical plan of tumor resection was based on preoperative imaging. Preoperative chemotherapy was recommended for patients younger than 50ys with high-grade sarcoma.

The collected data included: (1) surgical procedure: margin (intracapsular, marginal and wide), location of the lesion in long bone, proportion of resection in the whole bone and the reconstructive method; (2) oncological concerns: local relapse and recurrence free interval, distant metastasis or death; (3) functional parameters: complications and MSTS scores[3].

3. Statistical methods

Follow-up time was calculated from the date of operation to the last follow-up or death date. Comparison between subgroups was done by chi-square and t-tests where appropriate. Wilcoxon method was used for correlation comparison of abnormal distribution grade data, and Mann-Whitney for independent samples. Local recurrence free survival (LRFS), distant metastasis free survival (DMFS), and overall survival (OS) were calculated using the Kaplan-Meier method. Univariate analysis for clinical prognostic factors was performed using the log-rank test. Multivariate analysis of factors predicting outcome were performed using Cox regression. A *P* value of 0.05 or less for two sided was considered statistically significant. All analysis was carried out using SPSS21.0 software (IBM, USA).

Results

1. Patients and tumor characteristics

There were 46 patients with radial malignant tumor which accounting for 17.3% of 266 patients with radial tumor, 22 patients with ulna malignant tumor which accounting for 21.4% of 103 patients with ulna tumor. The number of malignant tumor in ulna was less than that in radius.

In 46 patients with primary malignant bone tumor of radius, limb salvage surgery was performed in 40 patients and amputation in 6 patients. In 22 patients with malignancy of ulna, limb salvage surgery was executed in 20 patients and amputation in 2 patients. A total of 60 patients were carried out limb salvage surgery. Fifty-six patients followed more than 12 months or progressions within 12 months were included in final evaluation (Table 1). There were 34 males (60.7%) and 22 females (39.3%) with mean age of 27.8 (5–73, median 20.0) years. The follow-up averaged 72.1 (7-192, median 62.5) months.

Table 1
Patients, Tumor Characteristics and Outcomes in 56 Patients

Characteristics	N (%)	Local recurrence	Metastasis	Death
Gender				
Male	34(61)	8	11	9
Female	22(39)	3	3	3
Age				
< 50	48(86)	10	12	10
≥ 50	8(14)	1	2	2
Major histologic type				
Osteosarcoma	17(30)	3	6	5
Ewing sarcoma	10(18)	2	3	3
Pleomorphic undifferentiated sarcoma	7(13)	1	2	2
chondrosarcoma	6(11)	1	0	0
Other than above	16(28)	4	3	2
Status at presentation				
Virgin	41(73)	5	9	8
Unplanned resection	15(27)	6	5	4
Grade				
Low	17(30)	4	2	2
High	39(70)	7	12	10
Involved bone				
Radius	38(68)	4	10	9
Ulna	18(32)	7	4	3
Anatomic location				
Proximal 1/3	19(34)	7	7	6
Middle 1/3	10(18)	2	1	1
Distal 1/3	27(48)	2	6	5
Bone Resection				
defect < 1/3	18(32)	3	5	4
1/3 ≤ defect < 2/3	24(43)	6	6	5
2/3 ≤ defect	14(25)	2	3	3
Margin				
Intracapsular	3(5)	2	1	1

Characteristics	N (%)	Local recurrence	Metastasis	Death
Marginal	8(14)	5	5	4
Wide	45(81)	4	8	7
Chemotherapy				
Neoadjuvant	28(50)	5	9	8
Adjuvant	33(59)	7	10	8
No chemo	23(41)	4	4	4

Thirty-eight (38/56, 67.9%) patients underwent radius resection. Location was at proximal radius in 6 patients, shaft in 7 patients, and distal radius in 25 patients. Eighteen (18/56, 32.1%) patients underwent ulna resection. Location was at proximal ulna in 13 patients, shaft in 3 patients, and distal ulna in 2 patients. In general, there were 19 cases (33.9%) in proximal 1/3, 10 cases (17.9%) in middle 1/3, and 27 cases (48.2%) in distal 1/3 of the forearm.

Based on pathological diagnosis, osteosarcoma was in 17 patients (30.4%), Ewing's sarcoma in 10 patients (17.9%), undifferentiated pleomorphic sarcoma in 7 patients (12.5%), low-grade central osteosarcoma in 6 patients (10.7%), chondrosarcoma in 6 patients (10.7%), bone angiosarcoma in 2 patients (3.6%), epithelioid sarcoma in 2 patients (3.6%), parosteal osteosarcoma, low-grade mixed tumor, low grade myofibroblastic sarcoma, malignant giant cell tumor of bone, spindle cell sarcoma and clear cell sarcoma in 1 patient (1.8%), respectively. There were 17 cases (30.4%) of low-grade sarcoma and 39 cases (69.6%) of high-grade sarcoma based on histology [4, 5]. Forty-one patients (73.2%) received initial operation in our hospital and 15 patients (26.8%) were referral to other hospitals after unplanned resection. The length diameter of recurrent lesion in 15 patients with unplanned resection was significantly larger than that of virgin tumor (P = 0.001). Twenty-eight high-grade bone tumors which contained osteosarcoma (16/17), Ewing's sarcoma (10/10) and undifferentiated pleomorphic sarcoma (2/5) received preoperative chemotherapy. Thirty-three of 39 cases of high-grade sarcoma were administered by postoperative chemotherapy.

The surgical margin contained intracapsular resection in 3 cases (5.3%), marginal resection in 8 cases (14.3%) and wide resection in 45 cases (80.4%). Reconstructions were performed in 48 patients (85.7%). Postoperative radiotherapy was not performed in each patient. The bone defect contained 1/3 defect in 18 patients (32.1%), 2/3 in 24 patients (42.9%) and more than 2/3 in 14 patients (25%). The reconstruction methods of radius defect included: autogenous iliac bone graft and wrist joint fusion, autogenous fibula transplantation, ulna centralization and wrist joint fusion, ulna osteotomy and replacement of radial defect. The reconstruction methods of ulna defect included: elbow prosthesis replacement, vascularized fibula transplantation, elbow arthroplasty with humerus and radius, inactivated replantation. Among the 48 patients underwent reconstruction, rotation function of forearm was preserved in 26 patients and lost in 22 patients. The wrist joint fusion was performed in 19 patients and elbow arthroplasty was performed in 6 patients.

2. Tumor local control

Local recurrence occurred in 11 patients (19.6%) (Table 2). The recurrence rate of reoperation in patients who underwent unplanned resection was 40% (6/15), which was higher than virgin tumor (12.2%, 5/41) (P = 0.02) (Fig. 1). The median recurrence free time of 11 recurrent cases was 12 (2–38) months and 90% of the recurrences occurred within 3 years (10/11). Amputation was performed in 4 cases (36.4%). The local resection was performed in 7 cases (63.6%) and 1 case had a second recurrence. The 3-year and 5-year recurrence free survival rates were 81.9% and 79.8% respectively. The recurrence rate with inadequate margin was significantly higher than that adequate resection. Univariate analysis (Table 3)

showed history of unplanned resection (P = 0.015), ulna tumor (P = 0.016), tumor located in proximal forearm (P = 0.021), and inadequate surgical margin (P < 0.001) were associated with recurrence (Fig. 2).

Table 2
Local Recurrences by Tumor Type, Grade, Location, Margins

No	Histology	Post-op interval	Grade	Bone	Location	Status	Margin	Outcome	Follow-up months
1	Osteosarcoma	2	High	Radius	Distal 1/3	Unplanned excision	Inadequate	Death	7
2	Osteosarcoma	38	High	Radius	Distal 1/3	Virgin	Inadequate	NED	123
3	Spindle cell sarcoma	11	Low	Radius	Distal 1/3	Unplanned excision	Inadequate	Death	19
4	Ewing sarcoma	12	High	Ulna	Proximal 1/3	Virgin	Adequate	Death	24
5	Ewing sarcoma	28	High	Ulna	Proximal 1/3	Unplanned excision	Adequate	Death	40
6	Osteosarcoma	5	High	Ulna	Middle 1/3	Virgin	Inadequate	Death	92
7	Chondrosarcoma	24	Low	Ulna	Proximal 1/3	Virgin	Inadequate	NED	48
8	Low grade central osteosarcoma	27	Low	Ulna	Proximal 1/3	Virgin	Adequate	NED	42
9	Clear cell sarcoma	5	Low	Radius	Proximal 1/3	Unplanned excision	Inadequate	Death	11
10	Pleomorphic undifferentiated sarcoma	16	High	Ulna	Proximal 1/3	Unplanned excision	Adequate	NED	43
11	Epithelioid sarcoma	11	High	Ulna	Proximal 1/3	Unplanned excision	Inadequate	SWT	30

Inadequate: Intracapsular and Marginal; Adequate: Wide; NED: No evidence of disease; SWT: Survival with tumor

Table 3
Outcomes in Univariate Analysis of Prognostic Factors (n = 56)

Variable		Local recurrence-free survival (%)	Distant metastasis-free survival (%)	Disease specific overall survival (%)
Gender				
	Male	76.1	64.6	65.6
	Female	85.6	86.4	86.4
	P value	0.377	0.152	0.392
Age				
	< 50	78.8	74.1	74.2
	≥ 50	85.7	65.6	43.8
	P value	0.620	0.986	0.609
Grade				
	Low	76.5	88.2	88.2
	High	81.4	67.0	67.7
	P value	0.651	0.178	0.427
Bone Site				
	Radius	88.9	71.0	71.8
	Ulna	66.1	77.8	66.1
	P value	0.016	0.762	0.662
Anatomic location				
	Proximal 1/3	62.3	51.3	48.1
	Middle & Distal 2/3	88.3	80.1	79.5
	P value	0.021	0.119	0.065
Status				
	Virgin	87.0	74.3	72.2
	Unplanned resection	60.0	66.7	72.7
	P value	0.015	0.419	0.409
Margin				
	Adequate	90.8	80.4	80.9
	Inadequate	36.4	43.6	48.5
	P value	0.000	0.008	0.048
Chemotherapy				

Variable		Local recurrence-free survival (%)	Distant metastasis-free survival (%)	Disease specific overall survival (%)
	Neoadjuvant & Adjuvant	78.2	79.1	70.8
	No chemo	82.2	68.7	72.5
	P value	0.741	0.321	0.833
Local recurrence				
	Yes	NA	36.4	26.5
	No	NA	82.2	81.8
	P value	NA	0.000	0.000
Metastasis				
	Yes	NA	NA	0
	No	NA	NA	100
	P value	NA	NA	0.000

3. Distant metastasis and overall survival

Distant metastasis was observed in 14 patients (14/56, 25%) and 12 (12/14, 85.7%) of them were with high-grade malignant tumor. The median time to the development of distant metastasis was 15 (2–64) months with 8 (57.1%) metastasis occurring within 1.5 years after surgery and 12 cases (85.7%) within 2 years. The median time to death after development of distant metastasis was 11 (1–84) months. Eleven cases (78.6%) involved only lung metastasis, 3 cases (21.4%) involved multiple sites of lung and bone metastases (1 scapula, 1 thoracic vertebra and 1 femoral shaft). The 2-year and 5-year metastasis free survival rates were 78.6% and 76.0% respectively. The metastasis free survival rates with different surgical margins were 80.4% and 43.6%, respectively (P = 0.008) (Fig. 3). The 5-year survival rates of high-grade and low-grade tumors were 81.7% and 88.2%, respectively (P = 0.427). At the last follow-up, 42 patients survived without tumor, 2 patients survived with tumor and 12 patients died. The median survival time of dead patients was 29 (7–92) months. The overall 5-year and 10-year survival rates were 83.5% and 71.7%, respectively (Fig. 4). Univariate analysis showed inadequate surgical margin (P = 0.048), local recurrence (P < 0.001) and distant metastasis (P < 0.001) were associated with death. Multivariate analysis of risk ratio model showed recurrence and distant metastasis were independent significant predictor of overall survival.

4. Postoperative complications and functional evaluation

Ten patients (17.8%) developed postoperative complications: internal fixation failure in 5 patients, limb short deformity, wrist silver fork deformity, prosthetic aseptic loosening, inactivated bone graft joint subluxation and bone graft nonunion in 1 patient respectively. Seven patients (70%) underwent revision: 5 patients with fixation failure received re-fixation, 1 patient with nonunion received iliac graft again, and 1 patient with short limb deformity received limb extension by external fixator. The other 3 patients carried out routine observation without revision.

The bone defect after radial tumor resection were divided into proximal 1/3, distal 1/3 and middle 2/3 defect. The proximal 1/3 defect didn’t receive reconstruction (Fig. 5-A). The distal 1/3 defect receive autogenous iliac bone graft and wrist joint fusion with internal fixation (Fig. 5-B). The middle 2/3 defect received following methods: (1) ulna osteotomy and fixation

with the end of radius (Fig. 5-C), (2) ulna centralization and wrist joint fusion with internal fixation (Fig. 5-D), (3) long segment fibula autograft and fixation (Fig. 5-E), (4) ipsilateral ulnar osteotomy to replace the radial defect (Fig. 5-F)

After resection of ulna tumor, the proximal 1/3 defect was treated with (1) elbow prosthesis replacement, (2) inactivated replantation. More than 2/3 defect of middle segment was treated with (1) elbow prosthesis combined with free vascularized fibula grafting (Fig. 5-G), (2) brachioradial elbow arthroplasty (Fig. 5-H). The distal 1/3 defect didn't receive reconstruction (Fig. 5-I). Twenty-two patients with ulna centralization lost rotation function, but flexion/extension and other fine movements were not significantly limited. At the last follow-up, 42 patients were evaluated by MSTS score with an average of 93.0 ± 5.1%. The function of patients with limb salvage was satisfactory and the final limb salvage rate was 92.9% (52/56).

Discussion

The incidence of primary malignant bone tumors of forearm is low. There is little literature describing large case series of bone tumors in the forearm while most of them are soft tissue tumors [6]. The complex anatomy in the narrow space of forearm lead to the difficulty of limb salvage and poor function after limb salvage in bone sarcoma. In the past 18 years, we found more benign bone tumors than malignancy with soft tissue sarcomas predominate [1]. There were many reports on soft tissue sarcoma in forearm [7], but bone sarcoma was much more common on case reports [8, 9]. The incidence of primary malignant tumors in forearm is only 18.4% (68/369) of all primary bone tumors in this series. Although the incidence of malignant tumors in radius is higher than that in ulna, but the proportion of malignant tumors in all ulna tumors is more frequent than that in radius. This result suggests that it's more likely to be malignant once tumor occurs in ulna, although the number of malignant tumor of radius is dominant. This distribution characteristic has not been clearly described [10, 11].

Twenty-five cases (65.8%) of radial malignant tumors were located in distal 1/3 of the radius, while 13 cases (72.2%) of malignancy were located in proximal 1/3 of the ulna. This characteristic of distribution has not been reported before. Since the very low incidence rate of forearm, Daecke [12] summarized 33 cases of osteosarcoma through multicenter study of Cooperative Osteosarcoma Study Group (COSS), which found 60.6% of the tumors in distal radius and only one tumor in proximal ulna. The common tumors of forearm bone are osteosarcoma, Ewing's sarcoma, undifferentiated pleomorphic sarcoma and chondrosarcoma, which are consistent with that osteosarcoma was the most common tumor in upper limb reported by Landau [13]. But Ewing's sarcoma and chondrosarcoma were usually sporadic and individual cases [8, 14–16].

In this series, 15 recurrent cases (26.8%) after unplanned resection were referred to our hospital. The size of lesion was significantly increased compared with the original imaging. Popov et al. [17] found the risk of limb salvage after unplanned resection was considerable, and the probability of skin flap coverage and radiotherapy intervention was significantly increased. Because of the dominant of primary bone tumor in our study, only 3 recurrent cases underwent skin flap transfer to cover the wound.

In current study, 8 patients with initial amputation were excluded. Limb salvage procedure was unavailable with the neurovascular bundle involved by neoplasm. Eleven cases (19.6%) had local recurrence in the final follow-up. Six of the 15 patients (40%) underwent unplanned tumor resection developed recurrence, improper surgical approach, contamination of surgical field and destruction of compartment barrier resulted in the spread of tumor. The biological behavior of recurrent tumor was more aggressive [18]. We found a significant advantage in recurrence free survival for virgin tumors in univariate analysis and their imaging findings were "milder" than those of recurrent tumors. Because of the high risk of recurrent tumor, radical resection and even amputation should be considered.

Tumors located in ulna and proximal forearm showed significantly higher risk of local recurrence in univariate analysis, which was not found in previous studies [7, 12, 13]. It is considered that soft tissue sarcoma of forearm has been reported

in majority before, so tumor size was more concerned and was associated with recurrence [19]. In the literature of primary malignant bone tumor, Bosma et al. [20] analyzed the difference of recurrence risk of Ewing's sarcoma in different sites. Pradhan et al. [2] compared forearm sarcoma with that of other sites. But the difference of recurrence rate between different sites of forearm did not be further analyzed due to the small series of patient. With less soft tissues attachment, the coverage is more difficult for limb salvage in ulna. The anatomical structure of proximal is complex than distal forearm, the radial nerve, brachial artery, attachment of muscles at proximal forearm and juxtaposition of elbow joint may lead to inadequate resection margin due to the preservation of important structures. The influence of surgical margin on local recurrence has been suggested [7]. Most researchers define adequate surgical margin as wide resection or extra-compartmental resection. Muramatsu et al [21] used 2 cm margin for high-grade sarcoma and 1 cm margin for low-grade sarcoma, the satisfied local recurrence rate of 11% was achieved. In our study, inadequate surgical margin increased the recurrence rate significantly; the recurrence rate of adequate margin was 8.9% (4/45), while in intracapsular and marginal resection was 63% (7/11). It suggested limb salvage surgery need to be re-evaluated if it is difficult to achieve safe margin.

Although the risk of metastasis exits in all malignancies especial high-grade malignancies, there seems to be various results in forearm sarcomas. Pradhan et al. [2] reported the incidence of distant metastasis was 42% and low-grade was significantly lower than that of high-grade sarcoma. The survival rate also displayed the low-grade superiority. The 5-year survival rate of high-grade osteosarcoma was 60% [2]. However, daecke et al. [12] reported the metastasis rate of forearm high-grade osteosarcoma was 24% and the 5-year survival rate was 86.2%, which was higher than that in other sites. Current study showed 14 patients (25%) had metastasis and 5-year survival rate of high-grade sarcoma was 81.7% ,which was slightly lower than that of low-grade sarcoma without statistically significant. We considered lower tumor load in forearm lead to lower risk of metastasis than that in lower limb and axial bone. Preoperative and postoperative chemotherapy were performed in most high-grade sarcomas, which played positive role in the control of distant metastasis.

Different opinions about whether surgical margin and recurrence affect metastasis and survival [22, 23]. Some studies suggested safe surgical margin only affects recurrence, and recurrence didn’t increase metastasis and reduce survival [24–26]. However, more studies suggested the risk of local recurrence was leading to metastasis and reducing survival [6, 27, 28]. Our study showed surgical margin and recurrence were significant associated with metastasis and survival in univariate analysis, recurrence and metastasis were independent risk factors of death in multivariate analysis. We consider that recurrence causes repeated operations and prolongs tumor bearing time, which leads to the change of tumor biological behavior and increases the risk of metastasis. It was further proved the important therapeutic concept of safe surgical margin – local control - reduction of metastasis - improvement of survival.

Function is highly concerned on the premise of oncological safety. The particularity of two bones in forearm has great influence on rotation and hand function. Since there is no weight-bearing, it is important to ensure flexibility of forearm and hand. The defects of distal ulna and proximal radius have little effect on function and reconstruction is unnecessary. The most difficult problems are 2/3 or more defects in middle and distal radius and 2/3 or more defects in middle and proximal ulna. For the treatment strategy of distal radius, we choose iliac bone transplantation and wrist joint fusion for the defect within 7 cm, which achieved good results [29]. For the defect over 7 cm, ulna is directly displaced to centralization. This method is simple and practical, but the loss of rotation is no negligible. In order to keep rotation, segment autogenous fibula transplantation or ipsilateral ulnar osteotomy and fixation with the end of radius were adopted. This relatively complex method showed better function of forearm. We prefer wrist fusion to obtain a stable joint and the function is satisfactory [29]. The prosthesis replacement is a routine and applicable method for proximal ulna. Some new methods for forearm reconstruction are proposed with different advantages and disadvantages [8, 9, 15]. We designed the brachioradial elbow arthroplasty between proximal radius and humeral condyle with satisfactory function. It is difficult to cover skin defect due to large resection in recurrent cases, microsurgery and flap technology is desiderated to be executed

[13, 30]. In our study, 3 cases received flap coverage and two patients underwent free vascularized fibula grafting with satisfied postoperative results.

This study has some limitations. Firstly, this is a retrospective analysis spanning 18 years. There were homogeneous differences in the choice of chemotherapy schemes and surgical techniques. Secondly, this is a single institution report which lacks multiple center coordination to correct the bias in patients' enrollment and treatment methods. Finally, this study only included limb salvage cases which did not compare with the outcomes of amputation. Thus the selection bias of tumor load and site may exist, so the survival rate of patients with forearm malignancy may be overestimated.

Conclusions

This study is the largest single institution case analysis of limb salvage treatment for primary malignant bone tumor of forearm. The incidence of radial malignant tumor is higher than that of ulna. The distal radius and proximal ulna are most frequency involved sites. Unplanned resection history, tumor located in ulna, tumor located in proximal forearm, and inadequate surgical margin are important factors leading to local recurrence. Recurrence and metastasis are independent prognostic factors of survival. Limb salvage surgery for malignant bone tumors of forearm showed high overall survival rate and relative satisfactory function.

List Of Abbreviations

CT: Computed Tomography. MRI: Magnetic Resonance Imaging. MSTS: Musculoskeletal Tumor Society

Declarations

Ethics approval and consent to participate

Our study was approved by the Ethics Committee of the Beijing Jishuitan hospital. All patients who participate in the study provided written informed consent. A copy of the consent form is available for review.

Consent for publication

All patients gave written informed consent for the publication of their details in the manuscript. A copy of the written informed consent is available for review by the editor.

Availability of data and materials

The datasets generated during and/or analyzed during the current study are not publicly available due they are paper document in Chinese language store in our hospital archives but are available from the corresponding author on reasonable request.

Competing interests

No benefits in any form have been received or will be received from a commercial party related directly or indirectly to the subject of this research.

Funding

This research was supported by Chinese Society of Clinical Oncology (CSCO) Research Foundation (Y-2019GCTB-002, Y-young2019-070), National Natural Science Foundation of China (51973021), Beijing JST Research Funding (ZR-201902, YGQ-201925).

Authors' contributions

WFL and XHN conceived and designed the study. WFL, YKY, TJ, YS, YL, LH and QZ performed the study. WFL and YKY analyzed and interpreted the clinical data. WFL drafted the manuscript. WFL, YKY and XHN reviewed and edited the manuscript. All authors read and approved the final manuscript.

Acknowledgments

The authors thank Chung Ming Chan MBBS, G.Douglas Letson M.D who reviewed the manuscript, Tao Wang MD, Fajun Yang MD, Feng Yu MD, Hairong Xu MD, for their contribution to the data collection of this series.

References

1. Niu X, Xu H, Inwards CY, Li Y, Ding Y, Letson GD, Bui MM. Primary Bone Tumors: Epidemiologic Comparison of 9200 Patients Treated at Beijing Ji Shui Tan Hospital, Beijing, China, With 10 165 Patients at Mayo Clinic, Rochester, Minnesota. Arch Pathol Lab Med. 2015; 139(9):1149-55.
2. Pradhan A, Reddy KI, Grimer RJ, Abudu A, Tillman RM, Carter SR, Jeys L. Osteosarcomas in the upper distal extremities: are their oncological outcomes similar to other sites? Eur J Surg Oncol. 2015; 41(3):407-12.
3. Enneking WF, Dunham W, Gebhardt MC, Malawar M, Pritchard DJ. A system for the functional evaluation of reconstructive procedures after surgical treatment of tumors of the musculoskeletal system. Clin Orthop Relat Res. 1993; (286): 241-6.
4. Coindre JM. Grading of soft tissue sarcomas: review and update. Arch Pathol Lab Med. 2006; 130(10):1448-53.
5. Christopher DM, Fletcher JAB, Pancras CW, Hogendoorn, et al. WHO Classification of Tumours of Soft Tissue and Bone. Lyon: International Agency for Research on Cancer; 2013.
6. Stojadinovic A, Leung DH, Hoos A, Jaques DP, Lewis JJ, Brennan MF. Analysis of the prognostic significance of microscopic margins in 2,084 localized primary adult soft tissue sarcomas. Ann Surg. 2002; 235(3):424-34.
7. Baroudi MR, Ferguson PC, Wunder JS, Isler MH, Mottard S, Werier JA, Turcotte RE. Forearm soft tissue sarcoma: tumors characteristics and oncologic outcomes following limb salvage surgery. J Surg Oncol. 2014; 110(6):676-81.
8. Puri A, Gulia A, Byregowda S, Ramanujan V. Reconstruction of the elbow and forearm for Ewing sarcoma of ulna: A new biological technique. Int J Shoulder Surg. 2016; 10(2):85-8.
9. Cahayadi SD, Antoro A, Swandika B. A giant cell rich osteosarcoma of the proximal ulnar bone treated by elbow arthroplasty: A case report. Int J Surg Case Rep. 2019; 58:157-61.
10. KK. U. Dahlin's bone tumors-general aspects and data on 11,087 cases., 5th edition edn. Philadelphia: Lippincott-Raven Publishers; 1996.
11. Rosenberg AE. WHO Classification of Soft Tissue and Bone, fourth edition: summary and commentary. Curr Opin Oncol. 2013; 25(5):571-3.
12. Daecke W, Bielack S, Martini AK, Ewerbeck V, Jurgens H, Kotz R, Winkelmann W, Kabisch H, Kevric M, Bernd L. Osteosarcoma of the hand and forearm: experience of the Cooperative Osteosarcoma Study Group. Ann Surg Oncol. 2005; 12(4):322-31.
13. Landau MJ, Badash I, Yin C, Alluri RK, Patel KM. Free vascularized fibula grafting in the operative treatment of malignant bone tumors of the upper extremity: A systematic review of outcomes and complications. J Surg Oncol. 2018; 117(7):1432-9.
14. Bansal K, Prasad A, Shahi P, Sehgal A, Kamal S. Extraosseus Ewing's Sarcoma of the Forearm. Cureus. 2020; 12(7):e9051.

15. Yang Z, Niu N, Tang J, Wu L, He J, Shi J. Reconstruction of forearm support with ulnar translocation after resection of chondrosarcoma in the proximal radius. Orthopade. 2020.
16. Guzik G. The Use of a Custom-made Prosthesis in the Treatment of Chondrosarcoma of Distal Radius. Ortop Traumatol Rehabil. 2016; 18(1):65-72.
17. Popov P, Tukiainen E, Asko-Seljavaara S, Huuhtanen R, Virolainen M, Virkkunen P, Blomqvist C. Soft-tissue sarcomas of the upper extremity: surgical treatment and outcome. Plast Reconstr Surg. 2004; 113(1):222-230; discussion 231-22.
18. Bilgeri A, Klein A, Lindner LH, Nachbichler S, Knosel T, Birkenmaier C, Jansson V, Baur-Melnyk A, Durr HR. The Effect of Resection Margin on Local Recurrence and Survival in High Grade Soft Tissue Sarcoma of the Extremities: How Far Is Far Enough? Cancers (Basel). 2020; 12(9).
19. England P, Hong Z, Rhea L, Hirbe A, McDonald D, Cipriano C. Does Advanced Imaging Have a Role in Detecting Local Recurrence of Soft-tissue Sarcoma? Clin Orthop Relat Res. 2020.
20. Bosma SE, Rueten-Budde AJ, Lancia C, Ranft A, Dirksen U, Krol AD, Gelderblom H, van de Sande MAJ, Dijkstra PDS, Fiocco M. Individual risk evaluation for local recurrence and distant metastasis in Ewing sarcoma: A multistate model: A multistate model for Ewing sarcoma. Pediatr Blood Cancer. 2019; 66(11):e27943.
21. Muramatsu K, Ihara K, Yoshida K, Tominaga Y, Hashimoto T, Taguchi T. Musculoskeletal sarcomas in the forearm and hand: standard treatment and microsurgical reconstruction for limb salvage. Anticancer Res. 2013; 33(10):4175-82.
22. Pisters PW, Leung DH, Woodruff J, Shi W, Brennan MF. Analysis of prognostic factors in 1,041 patients with localized soft tissue sarcomas of the extremities. J Clin Oncol. 1996; 14(5):1679-89.
23. Yang JC, Chang AE, Baker AR, Sindelar WF, Danforth DN, Topalian SL, DeLaney T, Glatstein E, Steinberg SM, Merino MJ, et al. Randomized prospective study of the benefit of adjuvant radiation therapy in the treatment of soft tissue sarcomas of the extremity. J Clin Oncol. 1998; 16(1):197-203.
24. Tanabe KK, Pollock RE, Ellis LM, Murphy A, Sherman N, Romsdahl MM. Influence of surgical margins on outcome in patients with preoperatively irradiated extremity soft tissue sarcomas. Cancer. 1994; 73(6):1652-9.
25. Heinemann M, Ranft A, Langer T, Jurgens H, Kreyer J, Vieth V, Schafers M, Weckesser M, Simon T, Hassenpflug W, et al. Recurrence of Ewing sarcoma: Is detection by imaging follow-up protocol associated with survival advantage? Pediatr Blood Cancer. 2018; 65(7):e27011.
26. Spraker-Perlman HL, Barkauskas DA, Krailo MD, Meyers PA, Schwartz CL, Doski J, Gorlick R, Janeway KA, Isakoff MS. Factors influencing survival after recurrence in osteosarcoma: A report from the Children's Oncology Group. Pediatr Blood Cancer. 2019; 66(1):e27444.
27. Zhao R, Yu X, Feng Y, Yang Z, Chen X, Wand J, Ma S, Zhang Z, Guo X. Local recurrence is correlated with decreased overall survival in patients with intermediate high-grade localized primary soft tissue sarcoma of extremity and abdominothoracic wall. Asia Pac J Clin Oncol. 2018; 14(2):e109-15.
28. Dickinson IC, Whitwell DJ, Battistuta D, Thompson B, Strobel N, Duggal A, Steadman P. Surgical margin and its influence on survival in soft tissue sarcoma. ANZ J Surg. 2006; 76(3):104-9.
29. Wang T, Chan CM, Yu F, Li Y, Niu X. Does Wrist Arthrodesis With Structural Iliac Crest Bone Graft After Wide Resection of Distal Radius Giant Cell Tumor Result in Satisfactory Function and Local Control? Clin Orthop Relat Res. 2017; 475(3):767-75.
30. Muramatsu K, Ihara K, Doi K, Hashimoto T, Taguchi T. Sarcoma in the forearm and hand: clinical outcomes and microsurgical reconstruction for limb salvage. Ann Plast Surg. 2009; 62(1):28-33.

Figures

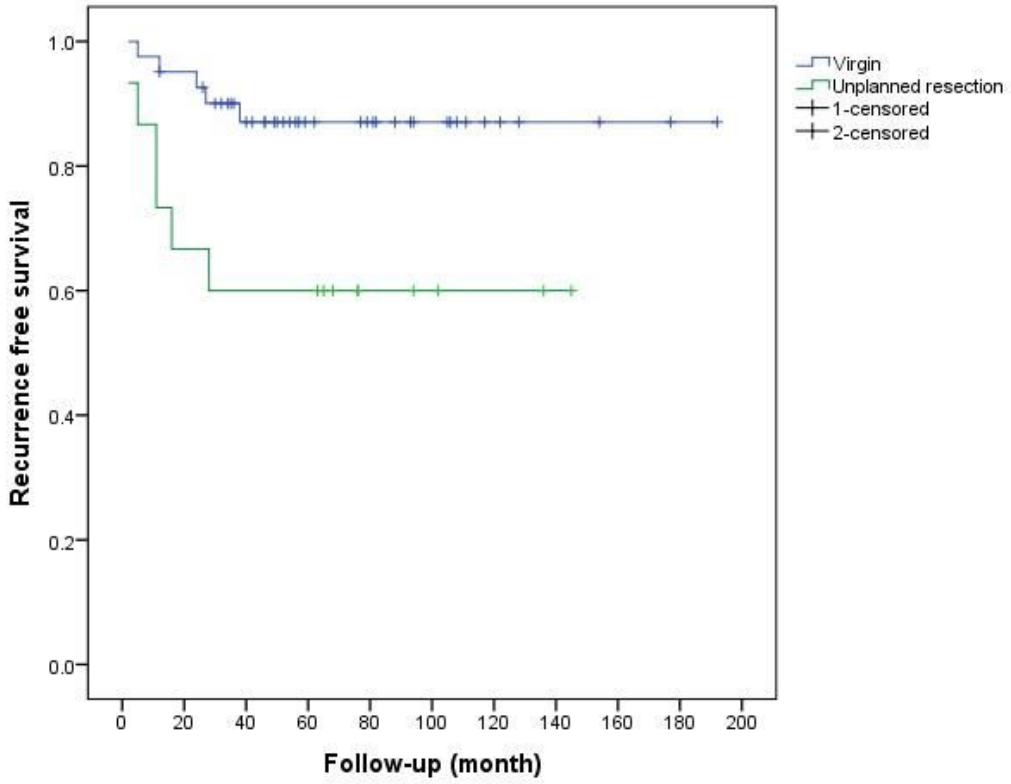

Figure 1

Comparison of recurrence free survival between patients with recurrence after unplanned resection and those with initial treatment (P = 0.015).

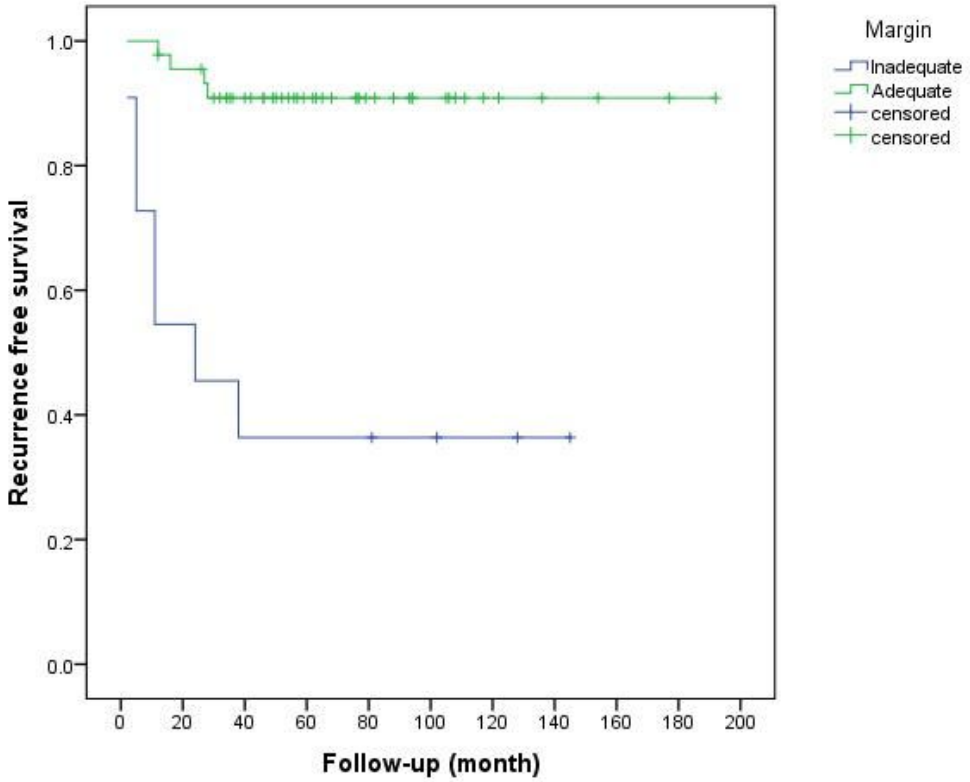

Figure 2

Comparison of recurrence free survival between inadequate and adequate surgical margin (P < 0.001).

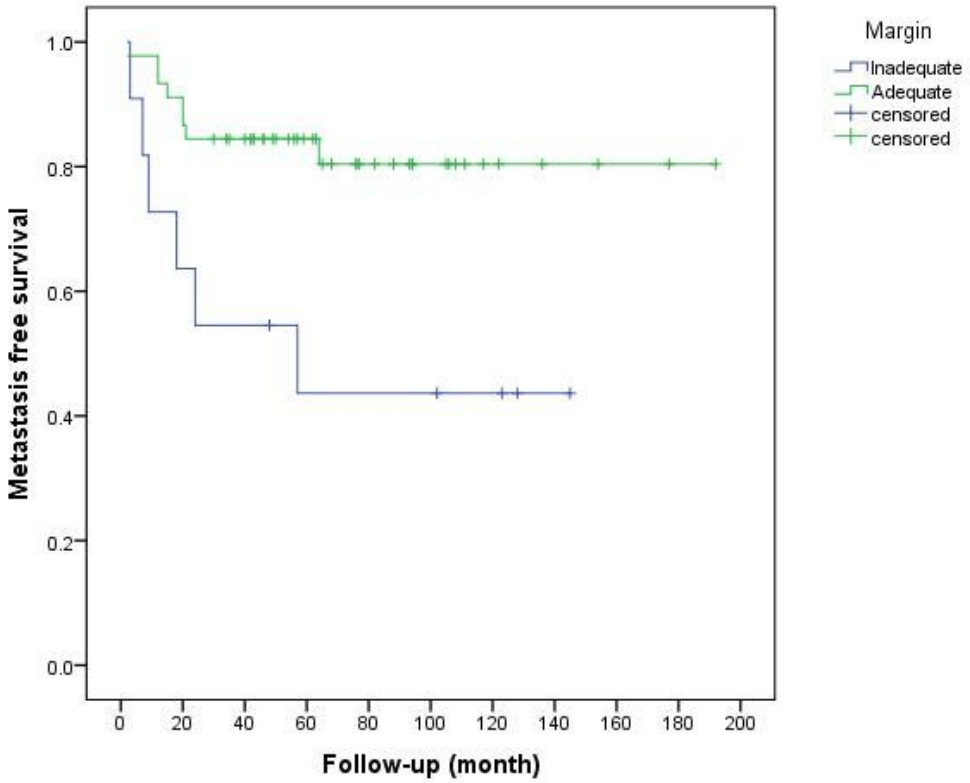

Figure 3

Comparison of metastasis free survival between inadequate and adequate surgical margin (P = 0.008).

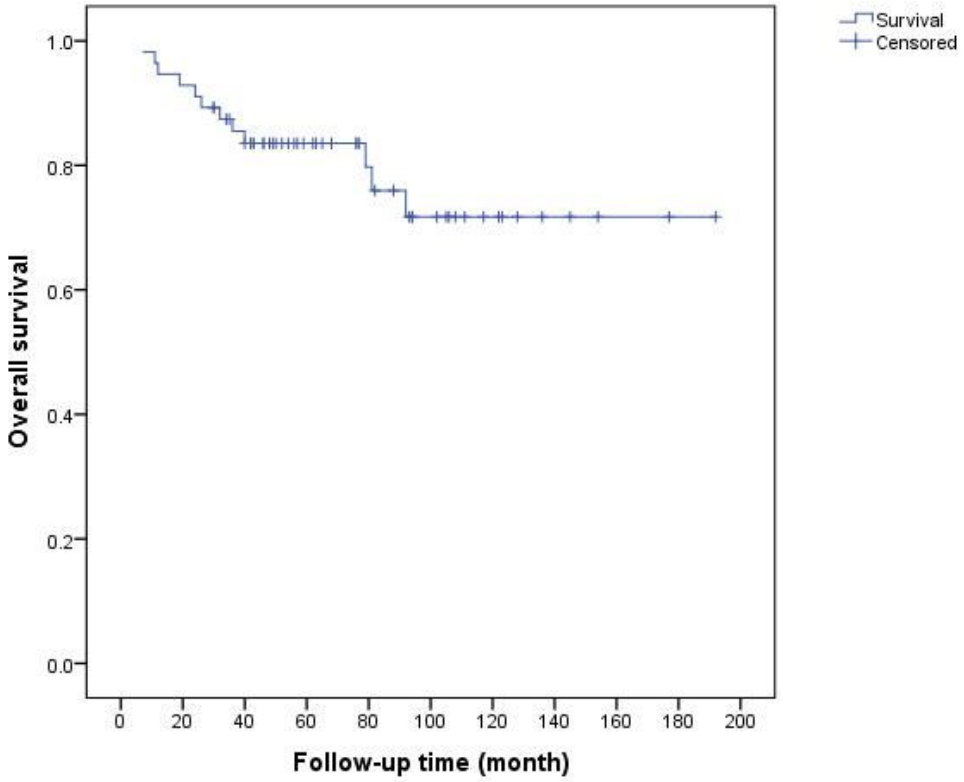

Figure 4

Overall 5-year and 10-year survival rate of 56 patients were 83.5% and 71.7%, respectively.

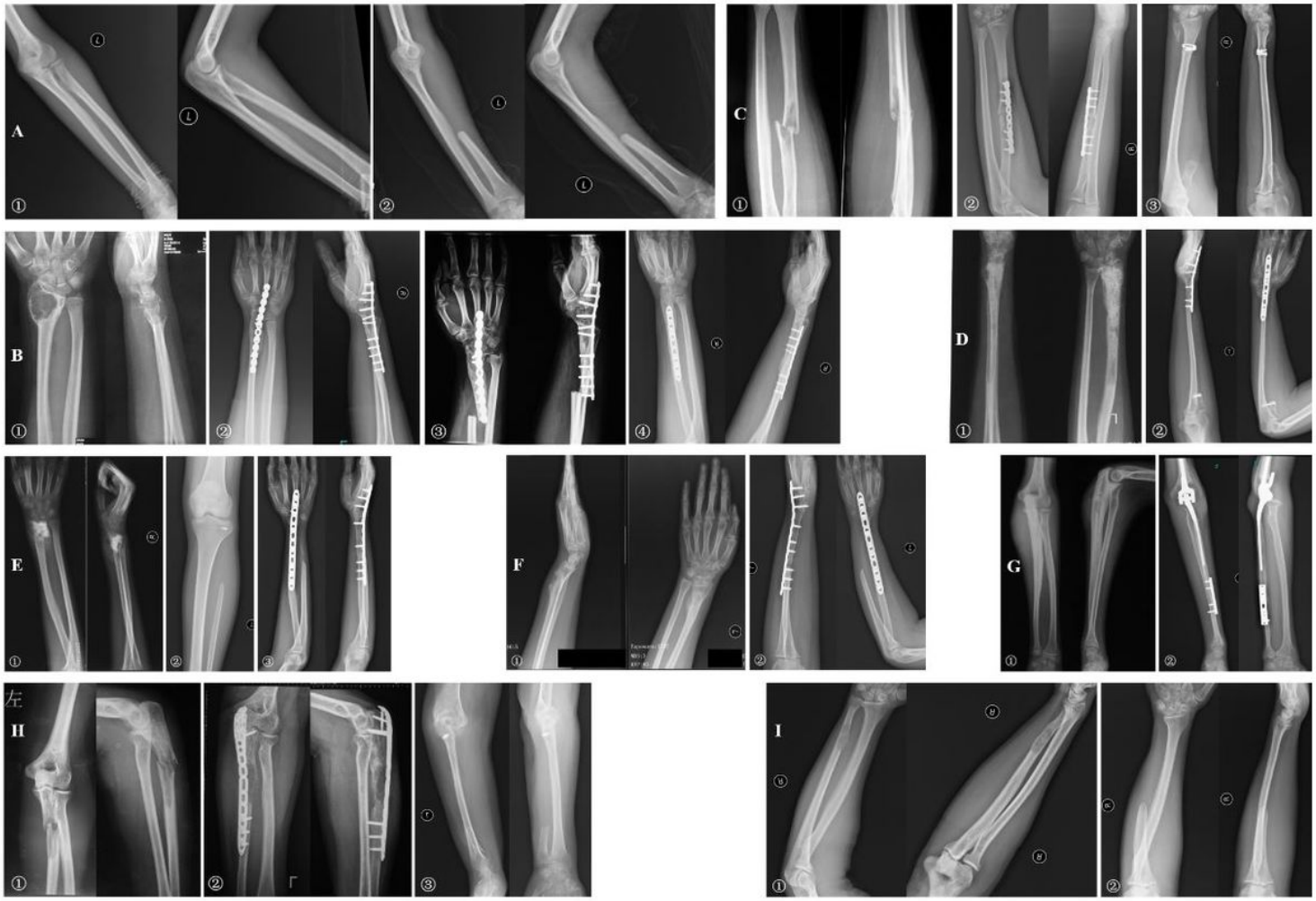

Figure 5

Figure 5A □ The Preoperative radiographs of 28 yrs male with Ewing's sarcoma. □ He received proximal radius resection without reconstruction and was followed for 56 months. Figure 5-B □ The Preoperative radiographs of 29 yrs male with chondrosarcoma. □ He received distal radius resection and autogenous iliac bone graft with wrist joint fusion. □ Fracture was caused by trauma 8 years after surgery and internal fixation was performed again. □ Rotation function of forearm was shown 192 months postoperatively. Figure 5-C □ The Preoperative radiographs of 14 yrs male with Ewing’s sarcoma of radius. □ He underwent unplanned tumor curettage and internal fixation. □ The distal ulna was osteotomized and fixed with the distal end of radius; satisfactory bone healing but loss of forearm rotation was shown 123 months postoperatively. Figure 5-D □ A 29 yrs female with low-grade central osteosarcoma of middle and distal radius underwent unplanned curettage and tumor recurrence. □ Radius resection and ulna centralization with wrist joint fusion was performed; satisfactory bone healing but loss of forearm rotation was shown 65 months postoperatively. Figure 5-E □ The Preoperative radiographs of 17 yrs female with osteosarcoma of distal radius adjacent to ulna; she underwent resection of distal radius and ulna; autologous fibula graft for wrist arthrodesis was performed.□ Proximal fibula was excised for bone graft. □ Satisfactory bone healing and rotation function of forearm was shown 54 months postoperatively. Figure 5-F □ The Preoperative radiographs of 19 yrs female with low-grade central osteosarcoma of distal radius. □ She underwent distal radius resection; ipsilateral ulnar osteotomy to replace the radial defect, wrist joint fusion was performed; satisfactory bone healing and rotation function of forearm was shown 50 months postoperatively. Figure 5-G □ A 16 yrs male with Ewing's sarcoma of proximal ulna underwent unplanned curettage and tumor recurrence. □ The middle and proximal ulna was excised, elbow joint replacement and vascularized fibula transplantation were performed; rotation function of forearm was shown 40 months postoperatively. Figure 5-H □ The Preoperative radiographs of 51 yrs female with osteosarcoma of

proximal ulna. ▯ She underwent unplanned curettage and tumor recurrence. ▯ Radius head was displaced and inserted into the intercondylar of humerus after proximal ulna resection; rotation function of forearm was shown 76 months postoperatively. Figure 5-I ▯ The Preoperative radiographs of 39 yrs male with osteosarcoma of distal ulna. ▯ He underwent distal ulna resection and rotation function of forearm was shown 106 months postoperatively.