Efficacy and safety of single-use flexible ureteroscope（ZebraScope™）for the treatment of upper urinary tract calculi ≤ 2 cm

Shun Wang
Guizhou provincial people's hospital
Kehua Jiang
Guizhou provincial people's hospital
Xiaolong Chen
Guizhou provincial people's hospital
Qing Wang
Guizhou provincial people's hospital
Xiangyi Liang
Guizhou provincial people's hospital
Yuan Tian
Affiliated hospital of Guizhou medical university
Kun Chen
Guizhou provincial people's hospital
Fa Sun（sfgmc@sina.com）
Guizhou provincial people's hospital

Research Article

Keywords: Flexible ureteroscope, single-use ureteroscope, Efficacy and safety

Posted Date: November 22nd, 2021

DOI: https://doi.org/10.21203/rs.3.rs-1039755/v1

Abstract

Purpose

To evaluate the clinical efficacy and safety of a Chinese single-use flexible ureteroscope (ZebraScope^{TM}) for the treatment of upper urinary tract calculi ≤2 cm based on a retrospective database.

Methods

Overall, 84 patients with upper urinary tract calculi who underwent FURS at our hospital from July, 2020 to January, 2021 were enrolled and reviewed. Demographic characteristics and perioperative data were evaluated and analyzed.

Results

We identified 84 patients: 51 male and 33 female. The mean age of the patients was(49.63±12.23)years, and the mean body mass index was 24.44±3.62 Kg/m^2. The degree of hydronephrosis was absent, mild, moderate and severe in 24, 35, 21 and 4 patients, respectively. The average operation time was 74.57±42.51 min, and the average blood loss was 5.28±4.99 ml. The catheter retention time was 1.71±0.99 day and the double-J tube retention time was 32.89±13.23 day. The length of hospital stay was 4.29±3.28 day. The stone-free rate was 77.78% after 1-month, and the cost of hospitalization was ¥ 34619±8719.16 . The overall complication rate was 4.76%. There were significant increase in leukocyte, neutrophils, and decrease in urea nitrogen, albumin and globulin after surgery (P 0.05), while no significant difference were observed in hemoglobin and creatinine (P 0.05).

Conclusion

The Chinese single-use ureteral flexible ureteroscope (ZebraScope^{TM})can be considered effective and safe for the treatment of upper urinary tract calculi ≤ 2 cm.

Background

The upper urinary tract stone was the most common diseases in urology [1]. Extracorporeal shock wave lithotripsy (ESWL), percutaneous nephrolithotomy (PCNL), rigid ureteroscope (RURS) and flexible ureteroscope (FURS) lithotripsy have become standard therapeutic options for urinary stones [2]. PCNL is more invasive and has higher complication rate compared to ureteroscope lithotripsy [3], and the ESWL has low SFR and higher retreatment rate [4, 5]. Comparing with FURS, the RURS has more deficiencies for renal and proximal ureteral calculi in select patients [6, 7]. Nowadays, flexible ureteroscopy has been the first-line treatment for upper urinary tract calculi ≤ 2 cm [8].

The role of flexible ureteroscopy has rapidly expanded owing to improvements in endoscopes and instrumentation, technique refinement, and growing operator experience, however, the original purchasing costs, reprocessing cost, repair fees and the problem of durability of reusable ureteroscopes serve as the chief factors that hinder FURS being embraced [9–11]. Finally, an important concern for the use of reusable flexible ureteroscopes is sterility [11, 12]. Over the past years, several single-use FURS devices have been introduced [13, 14]. Chinese single-use flexible ureteroscope(ZebraScope™), each component is single-use, so, it can avoid cross infections, reprocessing costs and repair fees, which greatly improves its benefit-cost ratio and safety. The purpose of this study is to evaluate the efficacy and safety of ZebraScope™ single-use flexible ureteroscope for the treatment of upper urinary tract calculi ≤ 2 cm.

Methods

Study population

We collected the clinical information of patients who underwent FURS at our hospital from July, 2020 to January, 2021, overall, 84 patients were retrospectively reviewed. The demographic characters, including age, gender and BMI (body mass index, BMI), preoperative parameters, including stone size, stone location, calculi laterality, and hydronephrosis severity, routine blood examinations, urinalysis and culture, serum biochemistry, surgical parameters, postoperative complications and parameters, length of hospital stay, hospitalization costs were evaluated and analyzed. All methods were carried out in accordance with relevant guidelines and regulations.

The inclusion criteria were: patients with upper urinary tract calculi ≤ 2 cm (as diagnosed by CT, abdominal DR or ultrasound); cognitive ability was normal and the ureteral access sheathes were placed successfully at one time. The exclusion criteria were: patients with malignant tumors, uncontrolled urinary tract infection, severe urethral or ureteral stricture, severe hemorrhagic diseases and cardiopulmonary insufficiency. All methods were carried out in accordance with relevant guidelines and regulations.

ZebraScope™

ZebraScope™ single-use ureteral flexible ureteroscope (Figure 1), which weighs 0.185 kg, is easy to hold, and the operating handle has an automatic locking system. The outer diameter of tip is 2.47mm, and the largest outer diameter is 2.87 mm, which can pass through the F11 / 13 expansion sheath smoothly. The operating channel is 3.6Fr, which allow the simultaneous operation of pressure perfusion and 200μm fiber work at the same time. The working length of the flexible ureteroscope is 670mm, and the total length of ureteroscope is 905mm. The maximum deflection in tip deflection is 275°, the lens is 1.6×10^5 pixels, and the depth of field is 2 to 50 mm (Figure 1).

Statistical analysis

Statistical analysis was performed using SPSS (version 22.0, IBM, USA). Categorical variables were presented as numerical values, and continuous data were presented as mean ± standard deviation. All test results were considered significant at $P < 0.05$.

Results

Demographic characteristics and preoperative data were summarized in Table 1. The mean BMI was(24.44±3.62)Kg/m^2, and the average age was 49.63±12.23 year. 25 patients got the left side stones, 29 patients affected by right stones and another 30 patients suffered from bilateral stones. The degree of hydronephrosis was absent, mild, moderate and severe in 24, 35, 21 and 4 patients respectively (Table 1).

Table 1
Demographic characteristics and preoperative data

Items	Value (n=84)
Gender (male/female)	51/33
BMI (Kg/m^2)	24.44±3.62
Age (years)	49.63±12.23
Hypertension, n (%)	19(22.62%)
Diabetes, n (%)	7(8.33%)
Cardiopathy, n (%)	7(8.33%)
Ureteral stricture, n (%)	18(21.43%)
Affected side, n (%)	25(29.76%)
Left	29(34.52%)
Right	
Bilateral	30(34.52%)
Stone characteristics, n (%)	
Single stone	28(33.33%)
Multiple stones	56(66.67%)
Stone size, n (%)	
< 10 mm	28(33.33%)
10–20 mm	56(66.66%)
CT HU	853.20±304.47
Hydronephrosis, n (%)	
Absent	24(28.57%)
Mild	35(41.67%)
Moderate	21(25.00%)
Severe	4 (4.76%)
Stone location, n (%)	
Kidney	40(47.62%)
Ureter	14(16.67%)

Items	Value (n=84)
Both kidney and ureter	30(35.71%)
Surgical history, n (%)	36(32.86%)
Preoperative urine culture n (%)	71(84.52%)
Negative	13(15.48%)
Positive	
Urine WBC	124.10±250.74
BMI: body mass index; WBC: white blood cell.	

The operative and postoperative data were shown in Table 2. All patients' ureteral access sheathes were placed successfully at one time. The operation time was (74.57±42.51)min and the blood loss was 5.28±4.99ml. The double-J tube retention time was32.89±13.23 day and the catheter retention time was 1.71±0.99 day. The length of hospital stay was 4.29±3.28day. The 1-month SFR (stone-free rate, SFR) was 77.78% and the cost of hospitalization ¥34619±8719.16. The overall complication rate was 4.76%. Only 1 patient had the double J tube position adjusted under cystoscopy. Other complications include fever, septic shock and abdominal pain, all can be cured by conservative treatments (Table 2).

Table 2
Operative and postoperative data statistics

Items	Value (n=84)
Operation time (min)	74.57±42.51
Blood loss (ml)	5.28±4.99
Hospital stay (day)	4.29±3.28
Complications, n (%)	
Grade I	1(1.19%)
Fever	1
Grade II	2(2.38%)
Septic shock	1
Lumbar and abdominal colic (Conservative cure)	1
Grade III	1(1.19%)
Lumbar and dorsum colic (Operative cure)	1
Indwelling time of double J tube (day)	32.89±13.23
Indwelling time of catheter (days)	1.71±0.99
Stone-free rate, n (%)	50(59.52%)
24 hours	64(76.19%)
1 month	
Cost	34619.87±8719.16
The complication grade based on Clavien-Dindo: Grade I：Any deviation from the normal postoperative course without the need for pharmacologic treatment or surgical, endoscopic, and radiologic interventions. Allowed therapeutic regimens are drugs as antiemetics, antipyretics, analgetics, and diuretics, and electrolytes and physiotherapy. This grade also includes wound infections opened at the bedside. Grade II：Requiring pharmacologic treatment with drugs other than such allowed for grade I complications. Blood transfusions and total parenteral nutrition are also included. Grade III： Requiring surgical, endoscopic, or radiologic intervention. Grade IV： Life-threatening complication (including CNS complications) requiring IC/ICU management. Grade V：Death as a result of complications.	

The comparison of preoperative and postoperative blood test were recorded in Table 3. There were significant increase in leukocyte, neutrophils, and decrease in urea nitrogen, albumin and globulin after surgery (P<0.05), while no significant difference were observed in hemoglobin and creatinine (P>0.05) (Table 3).

Table 3
The comparison of Preoperative and Postoperative blood test

Parameters	Preoperative	Postoperative	*P*
Leukocyte(10^9•L^{-1})	6.43±1.65	10.37±3.36	0.000
Neutrophils(10^9•L^{-1})	3.98±1.62	8.66±3.42	0.000
Hemoglobin(g•L^{-1})	136.90±23.83	134.29±15.41	0.339
Creatinine(μmol•L^{-1})	90.92±47.01	92.30±42.24	0.436
Urea nitrogen(mmol•L^{-1})	5.31±2.54	4.27±2.37	0.000
Albumin(g•L^{-1})	44.71±3.98	38.23±3.77	0.000
Globulin(g•L^{-1})	31.37±5.59	25.34±6.54	0.000

Discussion

The European Association of Urology (EAU) guidelines (Version 2019) has a strong recommendation for FURS to treat upper urinary tract calculi ≤ 2 cm [15]. Zhu Zewu conclude the SFR between PCNL and FURS for the management of intermediate-size renal stones (2-3cm) was comparable, however, the hospitalization time and rate of intraoperative complications were higher in group PCNL [16]. Compare with FURS, ESWL showed significantly lower SFR for previously untreated kidney stones 5-20 mm, ESWL (71%) versus URS (84%), in study of Christian D Fankhauser [17]. The 1-month SFR for upper urinary tract calculi ≤ 2 cm was 76.19% in our study, which was similar to study of Jiaqiao Zhang (71.00%) for renal stone [18]. For some special patients, such as abnormal kidney(anatomy or location), obesity and urinary malformations, FURS performs better than ESWL and PCNL [19–21].

Since the single-use FURS been introduced, they have gained widespread popularity with their efficacy becoming closer to reusable scopes [22, 23]. Yongchao Li find single-use FURS had a higher SFR in comparison with reusable FURS, and the perioperative complication rate were comparable [24]. Furthermore, there was an outbreak of urinary tract cross infection as incomplete decontamination of reusable flexible ureteroscope has been reported [25].

The most frequent complications after flexible ureteroscopy were fever, sepsis, steinstrasse or ureteral injury, ureteral avulsion, ureteral strictures, kidney damage and severe bleeding [26, 27]. Giusti published a retrospective analysis based on patients who underwent FURS with an overall complication rate of 29.1%, which the Clavien I and II rate was 26.9%, while the Clavien III and IV were 1.9% and 0.3% [28]. However, N F Davis reported the overall complication rate of Single-use flexible ureteropyeloscopy for the treatment of renal calculi was 9.3% [29]. The overall complication rate in our study was 4.76%, the Clavien I and II

rate was 3.57%, while the Clavien III was 1.19%. The most probable explanation could be our sample size was not sufficient and the stone size was larger in their study.

However, the elimination of stone fragments after FURS is also affected by many factors, including anatomy of ureter and kidney, holmium laser parameter, stone factors (including size, number, location, composition), operator experience, etc. [30, 31]. There were certain limitations in our study: this is a retrospective study, and the sample size is not sufficient enough. More multicenter and large-sample studies are needed to verify our findings in the future.

Conclusions

Chinese single-use ureteral flexible ureteroscope (ZebraScope^{TM}) can be considered effective and safe for the treatment of upper urinary tract calculi ≤ 2 cm .

Abbreviations

EAU: European Association of Urology; BMI: Body mass index; SFR: Stone-free rate; ESWL: Extracorporeal shock wave lithotripsy; PCNL: Percutaneous nephron lithotomy; RURS: Rigid ureteroscope; FURS: Flexible ureteroscope; CT: Computed tomography; DR: Digital radiography; WBC: White blood cell count.

Declarations

Ethical approval and consent to participate

The study was approved by the Ethics Committee of Guizhou Provincial People's Hospital. Informed consent was obtained from all patients, if patients are under 16, from a parent and/or legal guardian.

Consent for publication

Not applicable.

Availability of data and material

Records and data pertaining to this study are in the patient's medical records in Guizhou Provincial People's Hospital and are available from the corresponding author on reasonable request.

Competing interests

The authors declare that they have no competing interests.

Funding

This study was funded by National Natural Science Foundation of China (Number: 82060136), The Science and Technology Foundation of Guizhou Province (Number: [2020]1Y303), Science and

Technology Plan project of Guizhou Province (Number: [2019]5405), Foundation of Health and Family Planning Commission of Guizhou Province (Number: gzwjkj2019-1-127) and the Doctoral Foundation of Guizhou Provincial People's Hospital (GZSYBS[2018]02). The funding agencies and donors had no role in any aspect of this study.

Authors' contributions

WS, LXY, CXL and WQ wrote the manuscript and collected the data, JKH, CK and TY collected the data and analysis, SF and JKH study design, study supervision and edited the manuscript, all authors reviewed the manuscript.

Acknowledgements

Not applicable.

References

1. Chen, Y., et al., *Percutaneous nephrolithotomy versus flexible ureteroscopic lithotripsy in the treatment of upper urinary tract stones: a meta-analysis comparing clinical efficacy and safety*. BMC Urology, 2020. **20**(1): p. 109.
2. He, Q., et al., *Which is the best treatment of pediatric upper urinary tract stones among extracorporeal shockwave lithotripsy, percutaneous nephrolithotomy and retrograde intrarenal surgery: a systematic review*. BMC Urol, 2019. **19**(1): p. 98.
3. Turk, C., et al., *EAU Guidelines on Diagnosis and Conservative Management of Urolithiasis*. Eur Urol, 2016. **69**(3): p. 468–74.
4. Raman, J.D. and M.S. Pearle, *Management options for lower pole renal calculi*. Curr Opin Urol, 2008. **18**(2): p. 214–9.
5. Soliman, T., et al., *Miniperc vs Shockwave Lithotripsy for Average-Sized, Radiopaque Lower Pole Calculi: A Prospective Randomized Study*. J Endourol, 2016.
6. Cone, E.B., et al., *Cost-effectiveness comparison of ureteral calculi treated with ureteroscopic laser lithotripsy versus shockwave lithotripsy*. World J Urol, 2017. **35**(1): p. 161–166.
7. Assimos, D.G., *Re: Modular Flexible Ureteroscopy and Holmium Laser Lithotripsy for the Treatment of Renal and Proximal Ureteral Calculi: A Single-Surgeon Experience of 382 Cases*. J Urol, 2016. **195**(5): p. 1492–1493.
8. Fais, P.O., T. Albert and S. Gaillet, [*Flexible ureteroscopy with laser for upper urinary tract stone]*. Prog Urol, 2011. **21**(11): p. 811–5.
9. Kramolowsky, E., et al., *Cost Analysis of Flexible Ureteroscope Repairs: Evaluation of 655 Procedures in a Community-Based Practice*. J Endourol, 2016. **30**(3): p. 254–6.
10. Landman, J., et al., *Evaluation of overall costs of currently available small flexible ureteroscopes*. Urology, 2003. **62**(2): p. 218–22.

11. Scotland, K.B., J. Chan and B.H. Chew, *Single-Use Flexible Ureteroscopes: How Do They Compare with Reusable Ureteroscopes?* J Endourol, 2019. **33**(2): p. 71–78.
12. Ofstead, C.L., et al., *The effectiveness of sterilization for flexible ureteroscopes: A real-world study*. Am J Infect Control, 2017. **45**(8): p. 888–895.
13. Boylu, U., et al., *In Vitro Comparison of a Disposable Flexible Ureteroscope and Conventional Flexible Ureteroscopes*. Journal of Urology, 2009. **182**(5): p. 2347–2351.
14. Emiliani, E. and O. Traxer, *Single use and disposable flexible ureteroscopes*. Current Opinion in Urology, 2017. **27**(2): p. 176–181.
15. C. Türk, A.S.V.A., *EAU Guidelines on Urolithiasis.* 2019: p. 996-1084.
16. Zewu, Z., et al., *Comparison of retrograde flexible ureteroscopy and percutaneous nephrolithotomy in treating intermediatesize renal stones (2-3cm): a meta-analysis and systematic review*. Int Braz J Urol, 2019. **45**(1): p. 10–22.
17. Fankhauser, C.D., et al., *Extracorporeal shock wave lithotripsy versus flexible ureterorenoscopy in the treatment of untreated renal calculi*. Clin Kidney J, 2018. **11**(3): p. 364–369.
18. Zhang, J., et al., *Flexible ureteroscopy for renal stone without preoperative ureteral stenting shows good prognosis*. PeerJ, 2016. **4**: p. e2728.
19. Nerli, R.B., et al., *Flexible ureteroscopy for upper ureteral calculi in children*. J Endourol, 2011. **25**(4): p. 579–82.
20. Turna, B., et al., *Safety and efficacy of flexible ureterorenoscopy and holmium:YAG lithotripsy for intrarenal stones in anticoagulated cases*. J Urol, 2008. **179**(4): p. 1415–9.
21. Weizer, A.Z., et al., *Ureteroscopic management of renal calculi in anomalous kidneys*. Urology, 2005. **65**(2): p. 265–9.
22. Ventimiglia, E., et al., *Cost comparison of single-use versus reusable flexible ureteroscope: A systematic review*. Turk J Urol, 2020. **46**(Supp. 1): p. S40-S45.
23. Kam, J., et al., *Single use versus reusable digital flexible ureteroscopes: A prospective comparative study*. Int J Urol, 2019. **26**(10): p. 999–1005.
24. Li, Y., et al., *Comparison of single-use and reusable flexible ureteroscope for renal stone management: a pooled analysis of 772 patients*. Transl Androl Urol, 2021. **10**(1): p. 483–493.
25. Kumarage, J., et al., *Transmission of multi-drug resistant Pseudomonas aeruginosa between two flexible ureteroscopes and an outbreak of urinary tract infection: the fragility of endoscope decontamination*. J Hosp Infect, 2019. **102**(1): p. 89–94.
26. Perez, C.E., et al., *Differences in ureteroscopic stone treatment and outcomes for distal, mid-, proximal, or multiple ureteral locations: the Clinical Research Office of the Endourological Society ureteroscopy global study*. Eur Urol, 2014. **66**(1): p. 102–9.
27. Zeng, L., et al., *[MODIFIED Politano-Leadbetter REIMPLANTATION FOR TREATMENT OF CONGENITAL MALFORMATION OF VESICOURETERAL JUNCTION IN CHILDREN]*. Zhongguo Xiu Fu Chong Jian Wai Ke Za Zhi, 2015. **29**(10): p. 1279–83.

28. Giusti, G., et al., *Current Standard Technique for Modern Flexible Ureteroscopy: Tips and Tricks*. Eur Urol, 2016. **70**(1): p. 188–194.
29. Davis, N.F., et al., *Single-use flexible ureteropyeloscopy: a systematic review*. World J Urol, 2018. **36**(4): p. 529–536.
30. Iremashvili, V., et al., *Role of Residual Fragments on the Risk of Repeat Surgery after Flexible Ureteroscopy and Laser Lithotripsy: Single Center Study*. J Urol, 2019. **201**(2): p. 358–363.
31. Wang, F., et al., *The application of a single-use fiberoptic flexible ureteroscope for the management of upper urinary calculi*. Int Urol Nephrol, 2018. **50**(7): p. 1235–1241.

Figures

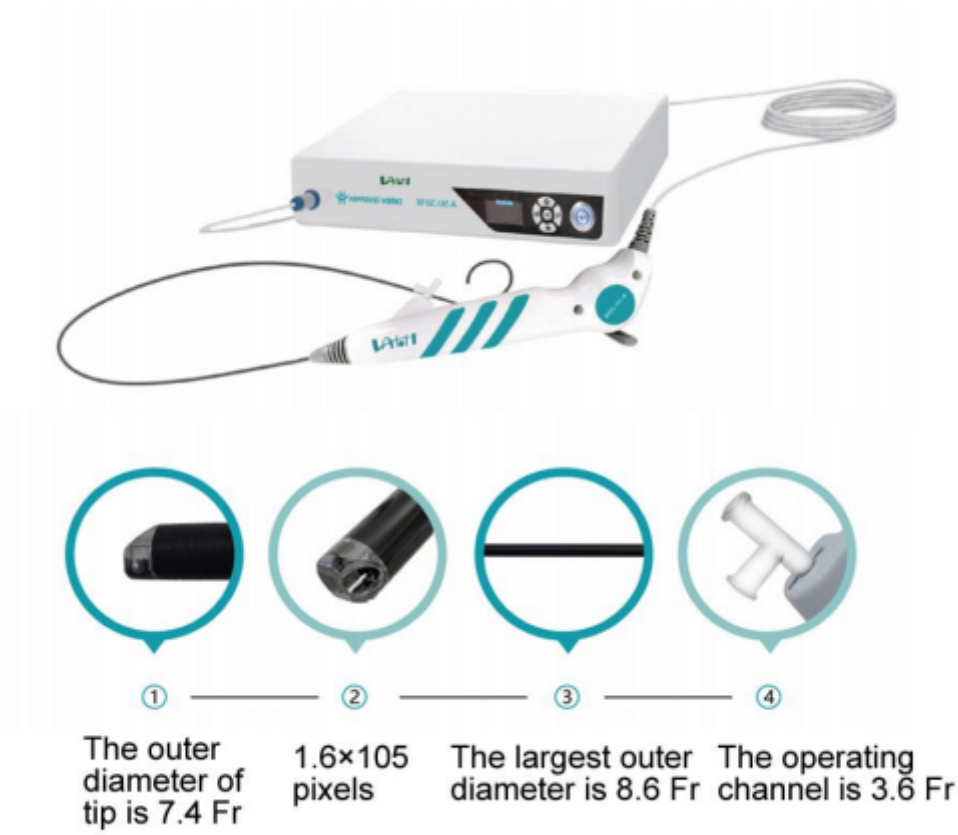

Figure 1

The ZebraScopeTM single-use ureteral flexible ureteroscope.