A Giant Gastrointestinal Stromal Tumor of Duodenal Origin with Spontaneous Rupture Bleeding: A Case Report

Zheqi Han
Shaoxing University Medical College
Baochun Lu
Shaoxing University Affiliated First Hospital: Shaoxing People's Hospital
Jianhua Yu
Shaoxing University Affiliated First Hospital: Shaoxing People's Hospital
Zhiyang Zhu (zhuzhy@usx.edu.cn)
Shaoxing University Affiliated First Hospital: Shaoxing People's Hospital https://orcid.org/0000-0001-9076-7288

Case report

Keywords: Gastrointestinal stromal tumors, Pancreaticoduodenectomy, Spontaneous rupture bleeding.

Posted Date: November 8th, 2021

DOI: https://doi.org/10.21203/rs.3.rs-1039804/v1

Abstract

Background

The duodenum is a rare site of gastrointestinal stromal tumors (GISTs). The unique anatomical characteristics and rich blood supply of the duodenum make it difficult to treat duodenal GISTs in patients with bleeding.

Case presentation

Here we report a case of a 76-year-old female was hospitalized with a large GIST that originated in the duodenum. Imaging assessment suggested that the tumor could not be radically resected. However, the tumor was rupturing and bleeding, and therefore pancreaticoduodenectomy had to be performed. After receiving imatinib postoperatively, the patient has recovered during the 1 year after the operation.

Conclusion

The results of this case suggest that pancreaticoduodenectomy may be a better choice for duodenal GISTs with rupture and bleeding.

Background

Gastrointestinal stromal tumors (GISTs) are the most common mesenchymal tumors of the gastrointestinal tract. While GISTs most commonly occur in the stomach, these tumors rarely originate in the duodenum. Here, we present a rare case of a large GIST originating in the descending duodenum that showed spontaneous rupture and hemorrhage. The treatment of this case presented a challenge and is discussed here.

Case Presentation

A 76-year-old woman was hospitalized with a large space mass in her abdominal cavity. Except for a slight pain in the stomach, there were no other gastrointestinal symptoms. Contrast-enhanced computed tomography (CECT) showed a mass of slightly low-density shadow in the pancreaticoduodenal area with obvious annular moderately heterogeneous enhancement. A duodenal origin of the mass was considered. The other organs in the abdominal cavity were normal without metastasis (Fig. 1A). CECT showed that the tumor was widely adhered to the inferior vena cava, right ureter, and posterior peritoneum, and the right renal vein were compressed (Fig. 1B). After multi-disciplinary team discussion, we considered that operation would be difficult; large intraoperative blood vessel injury might lead to massive intraoperative bleeding, and R0 resection could not be achieved. The tumor was diagnosed as a stromal tumor. Imatinib treatment was recommended first, as imatinib as a high objective response rate, and surgical treatment was planned after tumor shrinkage.

Three days after admission, the patient experienced sudden subxiphoid pain and pallor. Emergency ultrasound examination revealed a large amount of abdominal effusion. After discussion, we concluded that the tumor spontaneously ruptured with bleeding. The patient received conservative treatment, such as hemostasis and red blood cell transfusion, but the response was not sufficient. In addition, the patient's heart rate increased (from 65 beats/min before bleeding to 95 beats/min), and blood routine showed a continuous decrease in hemoglobin. Without emergency surgery, the patient was expected to undergo hemorrhagic shock and die. However, an operation would be too risky. After full communication with the patient and her family, we decided to perform emergency surgery.

We found a large amount of blood in the patient's abdominal cavity (approximately 2000 ml). After clearing the hemorrhage, we observed that the tumor was located in the pancreatic-duodenal region. The tumor showed spontaneous rupture and bleeding. In the separation of the tumor, we found that the tumor was widely adhered to the inferior vena cava, right renal vein, right ureter, and posterior peritoneum, which made the operation very difficult. After 10 h of surgery, we performed a successful pancreaticoduodenectomy (PD): the adhesions between the tumor and the inferior vena cava, right renal vein, right ureter, and retroperitoneum were successfully separated and the tumor was removed. The amount of bleeding was 1200 ml.

The tumor measured 11.8×9.5×4.5 cm (Fig. 2). Pathology of the tumor revealed CD117- and CD34-positive cells, which is consistent with GISTs. The patient recovered well during the 1 year after operation, and CECT review showed no tumor recurrence (Fig. 1C). Compression of the right renal vein was improved (Fig. 1D).

Discussion And Conclusions

GISTs account for only 1% of gastrointestinal malignancies and originate mainly in the stomach (60%), followed by the small intestine (35%). GISTs of duodenal origin are rare, representing less than 5% of all GISTs.[1] Duodenal GISTs with a diameter of 11.8 cm are rarely reported.

Bleeding is a common manifestation of GISTs. The submucosa of the duodenum is rich in blood vessels and has a high bleeding rate. A previous report indicated that tumor bleeding was higher among duodenal GISTs than gastric GISTs (28.2% vs. 6.6%), and the rate of bleeding after endoscopic hemostasis was significantly higher in the duodenal GIST group (41.2%) than in the gastric GIST group (13.3%); the authors suggested this difference in bleeding rate may be related to p53 expression.[2] The duodenum is long and narrow, and it is difficult to locate the duodenum under endoscopy. Therefore, in cases with duodenal stromal tumors, if the patient shows bleeding, direct surgical resection is a good choice.

At present, the radical treatment for duodenal GISTs is operation, but the optimal surgical method is not clear. Lee et al. reported that limited resection has fewer late complications and postoperative diabetic

complications than PD.[3] However, if the tumor involves the pancreas, we believe PD is better at completely removing the tumor and reducing the risk of tumor recurrence.

In the current case, the patient's condition continued to deteriorate under conservative care. After full communication with the patient and her family members, we selected surgical treatment. We successfully performed PD and completely removed the tumor, which saved the patient's life. Because of the large size of the tumor and its extensive adhesion to the surrounding tissues, there may be a small amount of residual tumor tissue left after tumor resection, and R0 resection may not be achieved. However, the patient received oral imatinib maintenance treatment after surgery, and the abdominal CECT reexamination one year later showed no significant recurrence or metastasis.

Previous studies showed that duodenal GISTs larger than 5 cm show good prognosis compared with bowel cancer, with a 3-year overall survival rate of 86.1%.[4] For patients with giant duodenal GISTs, we should adopt surgical treatment and add imatinib maintenance therapy after surgery, so that patients can benefit from surgery and other comprehensive treatments.

Abbreviations

GISTs, gastrointestinal stromal tumors; CECT, contrast-enhanced computed tomography; PD, pancreaticoduodenectomy.

Declarations

Acknowledgements

We thank Gabrielle White Wolf, PhD, from Liwen Bianji (Edanz) (www.liwenbianji.cn/) for editing the English text of a draft of this manuscript.

Conflicts of Interest and Source of Funding

The authors declare that they have no known competing financial interests or personal relationships that could have influenced the work reported in this paper. This work was sponsored by Zhejiang Provincial Natural Science Foundation of China under Grant No. LY19H160016 and LQ14H160001, National Natural Science Foundation of China (NSFC) No. 81602044, and Research Foundation of Health Bureau of Zhejiang Province under Grant No. 2020RC127, 2019ZD057 and 2018KY836.

Availability of data and materials

The data that support the findings of this study are available from the corresponding author upon reasonable request.

Author information

Contributions

Zheqi Han: Manuscript writing, literature research. Jianhua Yu and Baochun Lu: Management of the case, editing the manuscript. Zhiyang Zhu: Manuscript writing, management of case and final approval of manuscript. All authors have read and approved the manuscript.

Corresponding author

Correspondence to Zhiyang Zhu.

Ethics declarations

Ethics approval and consent to participate

Ethics approval by committee was not required for this case report.

Consent for publication

Written informed consent was obtained from the patient for publication of this case report and any accompanying images. A copy of the written consent is available for review by the Editor-in-Chief of this journal.

References

1. Beham A, Schaefer IM, Cameron S, et al. Duodenal GIST: a single center experience. *Int. J. Colorectal Dis.* 2013;28(4):581–590.
2. Pih GY, Ahn JY, Choi JY, et al. Clinical outcomes of tumor bleeding in duodenal gastrointestinal stromal tumors: a 20-year single-center experience. *Surg Endosc.* 2021;35(3):1190–1201.
3. Lee SJ, Song KB, Lee YJ, et al. Clinicopathologic Characteristics and Optimal Surgical Treatment of Duodenal Gastrointestinal Stromal Tumor. *Journal of gastrointestinal surgery: official journal of the Society for Surgery of the Alimentary Tract.* 2019;23(2):270–279.
4. Huang Y, Chen G, Lin L, et al. Resection of GIST in the duodenum and proximal jejunum: A retrospective analysis of outcomes. *Eur. J. Surg. Oncol.* 2019;45(10):1950–1956.

Figures

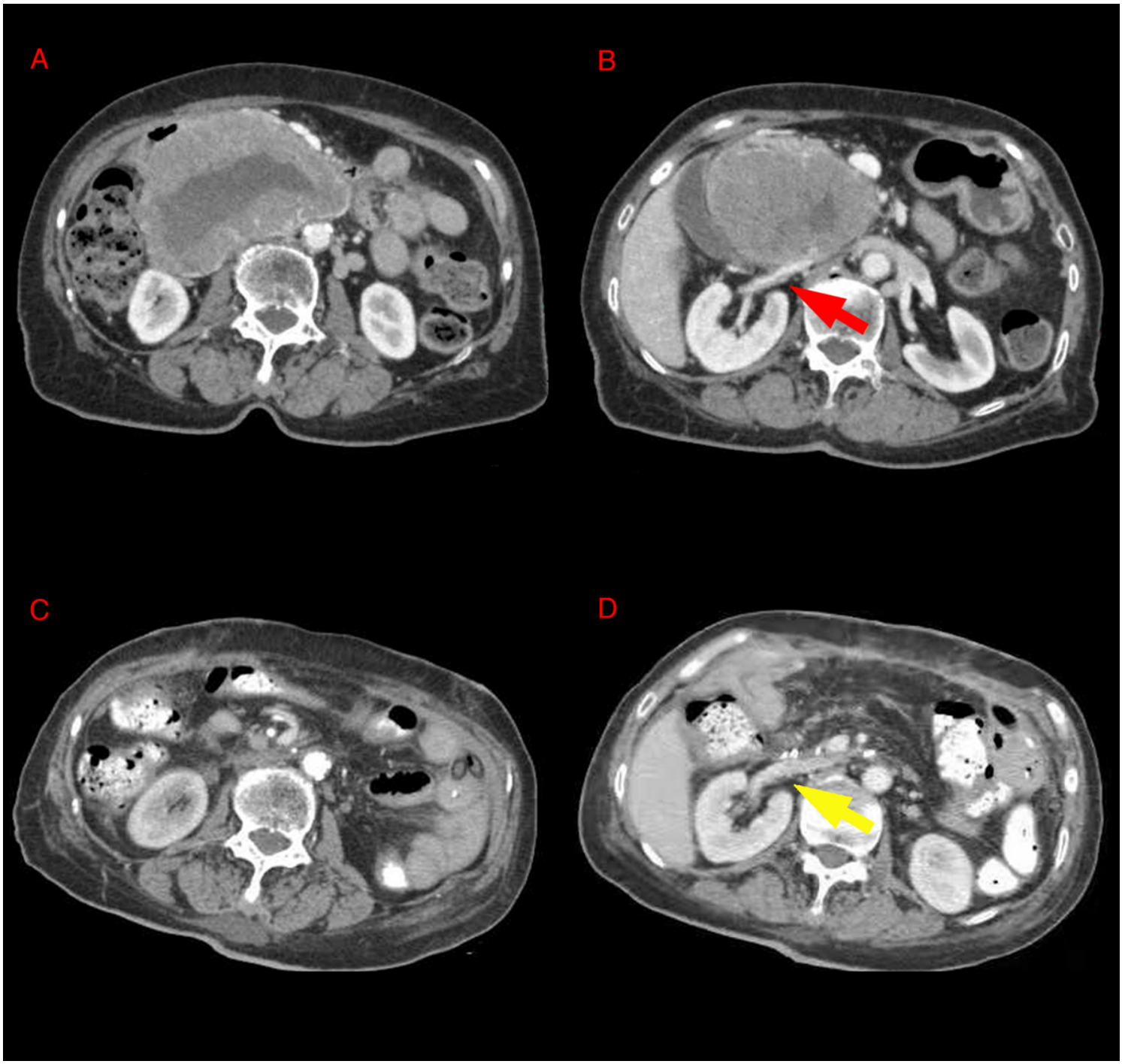

Figure 1

(A) CECT scan before surgery revealed a mass of slightly low-density shadow in the pancreaticoduodenal area. (B) Red arrows indicate the compressed the right renal veins. (C) CECT showed no tumor recurrence one year after surgery. (D) Yellow arrow shows that the compression of the right renal vein was improved. CECT, contrast-enhanced computed tomography.

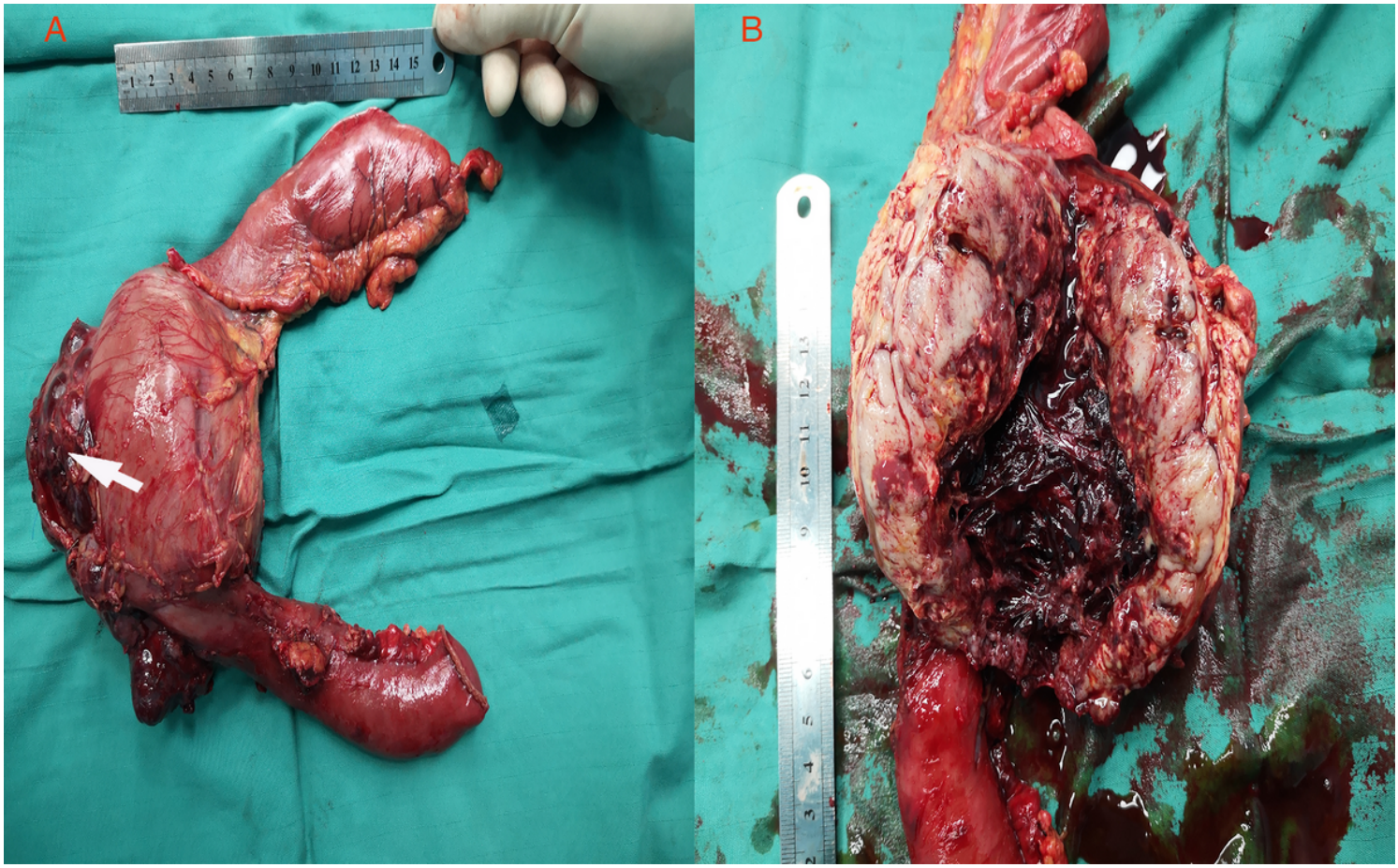

Figure 2

Postoperative specimen. (A) The huge duodenal GIST with a diameter of 11.8 cm. White arrow indicates the tumor rupture site. (B) In the dissected specimen, necrosis is seen in the center of the tumor.