Trauma and sinusitis induce orbital cellulitis in an 11-year-old boy

Cong Liang
Sun Yat-sen University First Affiliated Hospital
Ru-Jiang Zheng
Sun Yat-sen University First Affiliated Hospital
Su-Ping Li
Sun Yat-sen University First Affiliated Hospital
Yi-Juan Li
Sun Yat-sen University First Affiliated Hospital
Ling-Ling Xu (xulingl2@mail.sysu.edu.cn)
Sun Yat-sen University First Affiliated Hospital https://orcid.org/0000-0001-9074-6145

Case report

Keywords: orbital cellulitis, peripheral abscess, sinusitis, trauma, children

Posted Date: November 8th, 2021

DOI: https://doi.org/10.21203/rs.3.rs-1041329/v1

Abstract

Background

We conducted a literature review and found that the most common causes of orbital cellulitis susceptibility in children are infections in adjacent areas (such as sinusitis, dental disease, upper respiratory tract infections, and facial skin infections), recent trauma/surgery, foreign bodies, and insect bites. This article aims to discuss the differential diagnosis and treatment of orbital cellulitis in children.

Case presentation:

Here we present a report of a case of orbital cellulitis with intra-frame abscess induced by trauma and sinusitis, and a review of the relevant literature. An 11-year-old boy with a history of orbital trauma one year earlier had had fever, pain in the right eye, periorbital swelling, restricted extraocular movement, protruding eyes, and decreased vision for six days before admission. The initial treatment with intravenous Rocephin and linezolid was unsuccessful. MRI showed sinusitis and orbital abscess. Endoscopic sinus surgery was then performed to clean up the purulent secretions in the orbit, which relieved his orbital symptoms.

Conclusions

Here, we report a case of sinusitis and trauma-induced orbital cellulitis in an 11-year-old boy. The use of intravenous antibiotics and further treatment with orbital incision and decompression led to clinical improvement. Children with orbital complications of acute sinusitis have complex clinical manifestations and rapid disease progression. Our literature review findings suggest that broad-spectrum antibiotics are the main empirical treatment, and abscesses are not an absolute indication for immediate surgery. Therefore, dynamic evaluation, multidisciplinary consultations, and surgical treatment (if necessary) should be performed in cases of orbital cellulitis.

Background

Orbital cellulitis in children can be secondary to inflammation of the periorbital structure (such as sinusitis, respiratory tract infection, or local eye infection), or blood or trauma-induced infections, eye manifestations of systemic diseases, and secondary to periorbital structure surgery. Notably, intraorbital complications have a rapid onset and rapid progress. Hence, if not timely treated, they can cause optic neuritis, cavernous sinus thrombophlebitis, and even intracranial infection, endangering life [1–3]. In the present article, we introduce a case of orbital cellulitis and intra-frame abscess induced by trauma and sinusitis. Additionally, we have performed a literature review and have discussed the clinical features, diagnosis, treatment options, and prognosis of orbital cellulitis in children.

Case Presentation

An 11-year-old boy with a history of orbital trauma one year previously had developed a low-grade fever without obvious cause six days earlier. Tmax was 37.6°C, accompanied by pain, redness, and swelling of the right eye, as well as headache, and blurred vision. Ceftriaxone was administered intravenously for two days with no significant effect. Then, he visited us and underwent a vision test with the following results obtained: VOD 0.2, VOS 0.3. The CT examination findings were as follows: cellulitis of the right orbit and inflammation of the ethmoid, sphenoid, and maxillary sinuses (Figure 1).

The symptoms of the child did not improve significantly despite the change in the antibiotic therapy to meropenem and linezolid, and the continued administration of eye drops and symptomatic treatment of sinusitis. Three days later, head CT re-examination showed cellulitis of the right orbit and increased inflammation of the ethmoid, sphenoid, and maxillary sinuses. We added voriconazole since fungal infections were not ruled out. Due to the Spring Festival Holiday, MRI was not performed until the 5th day of conservative treatment. During this period, the appointed Ophthalmology Clinic personnel conducted dynamic evaluations every day maintaining close contact with the Otolaryngology Department staff. MRI revealed cellulitis of the right orbit with local abscess and inflammation of the ethmoid, sphenoid, and maxillary sinuses (Figure 1).

Due to the lack of significant improvement after the implementation of conservative treatment and the MRI findings of abscess formation, on the 5th day of the conservative therapy, we performed surgery of the right maxillary, ethmoid, sphenoid, and frontal sinuses by nasal endoscopy + orbital lesion resection + orbital incision decompression. Endoscopy showed obvious deviation of the nasal septum to the right side. Nasal stenosis and abundant purulent secretions were found in the middle nasal passage. Next, we opened the right maxillary sinus and observed excessive purulent secretion in the right maxillary sinus. We further collected a sample of the purulent secretion for culture by excision of a small part the orbital fascia. And we cleaned up the purulent secretions in the orbit thoroughly. Next, a large amount of normal saline was flushed through the operation cavity. Intensive anti-inflammatory and anti-swelling treatments were administered postoperatively. The patient recovered well, and the pain in the right eye disappeared. The following physical examination results were obtained: VOD 0.3, VOS 0.3; the swelling of the right eyelid had disappeared, the protrusion of the right eye was eliminated, and the conjunctiva showed no obvious congestion. Our treatment achieved complete resolution of the orbital inflammation, and his extraocular motility returned to normal (Figures 1 and 2).

Discussion And Conclusions

Orbital cellulitis in this child might have been induced by trauma and sinusitis. However, this case was characterized by certain specific features: the child had no history of sinusitis, whereas a history of orbital trauma one year earlier was present. This condition is not consistent with previous reports indicating that trauma-induced orbital cellulitis usually occurs within a few days post-trauma [4]. We, therefore, speculated that the damage of the local orbital structures caused by the trauma could easily induce orbital cellulitis in a later period of life. Moreover, no orbital abscess was detected by the repeated CT examinations in this patient, which is consistent with the existing literature evidence. Notably, MRI can improve the diagnosis rate of patients with orbital abscess [5]. In this patient, broad-spectrum antibiotics were first used as empirical treatment after suspected orbital cellulitis. Additionally, close contact was maintained with ophthalmology and otolaryngology departments. During the conservative treatment, the visual acuity and imaging conditions were dynamically evaluated. Due to the absence of considerable improvement, surgical treatment was considered and applied, followed by hormone anti-inflammatory agent administration until the child was finally cured.

In this study, we also conducted a literature review on PubMed using the terms "orbital cellulitis" and collected data associated with children reported in the past five years. We then analyzed and summarized its clinical features, treatment, and differential diagnosis. Interestingly, we found that most of the studied children had unilateral eye disease. The most common predisposing etiologies were infection of the adjacent area (such as sinusitis, dental disease, upper respiratory tract infection, and facial skin infection), recent trauma/surgery, foreign body, and insect bites. *Staphylococcus aureus* and non-hemolytic streptococci were the major pathogens [6]. Fungal infections should be considered as part of the initial workup in each patient diagnosed with preseptal/septal cellulitis unresponsive to empirical broad-spectrum antibiotic therapy, high CRP levels, and severe proptosis [7]. A high index of suspicion for

fungal infection should also be taken into consideration after surgical intervention with insertion of prosthetic materials [5]. In our case, the child was diagnosed with sinusitis and trauma-induced orbital cellulitis (Table S1).

Acute sinusitis is infectious or non-infectious inflammation of the nasal cavity and sinus mucosa. However, due to the thinner sinus bone walls and weaker immune system in children than those in adults, this disease leads to a higher incidence of nasal orbital complications and more extensive progression of the disease into the adjacent tissues. Acute sinusitis complications can be divided into peripheral soft tissue infections, osteitis, and intraorbital and intracranial complications. Intraorbital complications are most common, accounting for approximately 80% of all complications. Importantly, these complications have a rapid onset and progression, and, if not timely treated, they can cause optic neuritis, cavernous sinus thrombophlebitis, and can even lead to life-endangering intracranial infection [1, 2].

The clinical manifestations of the orbital complications of acute sinusitis include acute sinusitis, fever, headache, red and swollen eyelids, bulging eyeballs, restricted movement, eyeball tenderness, bulbar conjunctival edema, ptosis (in severe cases), and even loss of vision. The blood test in our case showed an increase in the white blood cell count (mainly that of neutrophils). Our patient initially had a fever, headache, eyelid swelling, but then gradually developed bulging eyes, restricted movement, and vision decline. It is noteworthy that in the literature review we performed, the main symptoms reported were eyelid redness and swelling.

CT examination is of considerable value in the diagnosis and treatment of orbital cellulitis. It can not only facilitate the diagnosis, but can also clarify the extent of the lesion, the involvement of adjacent bone walls and extraocular muscles, the degree of sinusitis and its relationship with orbital infection, showing the formation of abscesses and their locations. Therefore, timely incision and drainage should be implemented. MRI should be routinely applied for examinations in patients with suspected intracranial complications. Additionally, DWI (diffusion-weighted imaging) can improve the diagnosis rate in almost all patients with orbital abscess by the concurrent use of enhanced scan images [22]. In the present case, the orbital abscess was found only through MRI. Most patients with orbital cellulitis are cured by active treatment. However, acute periorbital swelling in some children can be misdiagnosed as orbital cellulitis. Hence, disease diagnosis is to be performed based on the assessment of infection indicators, clinical presentation, imaging features, the feedback on the effect of antibiotic treatment, and even of histopathology results. A history of sinusitis, high temperature, leukocytosis, and a normal pupil and fundus are usually present in children with true orbital cellulitis [20]. Importantly, timely diagnosis and treatment are essential for the prevention of potential irreversible visual loss [9], which highlights the importance of differential diagnosis of acute periorbital swelling in children. Nevertheless, most cases in which correct treatment has been implemented will be resolved without adverse residual effects (Table 1).

Table 1
List of diseases that are easily misdiagnosed as orbital cellulitis.

Patient Information	Ocular Symptoms	Risk Factors	Diagnosis	CT or MRI	Treatment	Reference
7 years, female	painful, swelling and ptosis	upper respiratory tract infection	Idiopathic Orbital Inflammation	MRI	corticosteroid	[8]
7 years, male	periorbital swelling and arm pain	no	Acute Sickle Cell Orbitopathy	CT	antibiotics	[9]
3 years, No mention of gender	swelling, purulent discharge	no	retinoblastoma	CT	Enucleation and chemotherapy	[10]
9 years, female	swelling	no	Langerhans cell histiocytosis	CT and MRI	chemotherapy	[11]
14 years, male	proptosis, eyelid edema and low vision	no	Sickle Cell Disease	MRI	ampicilin-sulbactam and methylprednisolone	[12]
10 years, female	swelling	no	Langerhans cell histiocytosis	CT	surgically debulked and corticosteroids	[13]
10 days, male	swelling, mucopurulent discharge and an incomplete fistulous tract	live in poor hygiene area	External ophthalmomyiasis	no	remove the larval with forceps and antibiotics	[14]
5 years, male	swelling and restriction of movements of right eye	no	Intra-ocular medulloepithelioma	MRI	Enucleation and chemotherapy	[15]
1 years, No mention of gender	swelling	no	Langerhans cell histiocytosis	MRI	chemotherapy	[16]
12 years, female	Reduced vision, diplopia, and swollen	insect bites	ophthalmomyiasis	no	Nd:YAG laser photodisruption and corticosteroids	[17]
9 years, male	swelling	no	leukemia	MRI	radiotherapy	[18]
12 years, male	swelling and ptosis	global developmental delay	Granulomatosis with polyangiitis	MRI	steroid and methotrexate	[19]
Mean age: 8 months female (80%)	swelling	retinoblastoma family history (40%)	Retinoblastoma	MRI	Enucleation and chemotherapy	[20]

Patient Information	Ocular Symptoms	Risk Factors	Diagnosis	CT or MRI	Treatment	Reference
8 years, male	swelling	no	venous lymphatic malformation	CT and MRI	surgery	[21]

No consensus guideline for the treatment of children with orbital cellulitis exists. The main empirical treatment for periorbital infection is the application of broad-spectrum antibiotics. Early diagnosis and appropriate antibiotic treatment are essential for the prevention of life-threatening complications. An empirical treatment is generally recommended that is directed against at least 90% of the possible pathogen microorganisms. It is critical that all patients should be treated against *Streptococcus pneumoniae, Streptococcus pyogenes, Streptococcus viridans, Staphylococcus aureus, Haemophilus* representatives, and anaerobes. In areas with a low incidence of MRSA, the administration of ampicillin/sulbactam, followed by amoxicillin/clavulanic acid, is the best monotherapy. In case of concerns regarding cerebrospinal fluid penetration or suspected or confirmed allergy to penicillin, ceftriaxone can be considered as part of an empirical treatment plan. However, the therapy in patients with severe illness is usually combined with the implementation of metronidazole and vancomycin. Additionally, in patients with mild illness or in areas with high rates of clindamycin susceptibility, it can be considered for use. signs of clinical and laboratory improvement are present, a transition from initial intravenous treatment to oral treatment can be considered. The total treatment duration of these infections has decreased considerably in recent years to approximately two weeks, even in cases of orbital or subperiosteal infections [23–26]. After CT examination for diagnosis confirmation, children with orbital honeycomb inflammation combined with sinusitis are usually treated with systemic antibiotics, nasal glucocorticoids, nasal cavity washing, agents promoting mucosal dissolution, negative pressure to attract nasal secretions, etc. After the exclusion of tumors and systemic immune system diseases, 3–5-day corticosteroid therapy can be applied systemically, with a dexamethasone dosage of 0.1–0.2 mg/kg. This treatment is to be terminated after the symptoms have significantly improved. The use of systemic steroids as an adjunct to the systemic antibiotic treatment of orbital cellulitis can reduce orbital inflammation while diminishing the risk of infection aggravation [27, 28]. Due to the present lack of guidelines for corticosteroid dosage in children with orbital cellulitis, CRP levels can be used as an effective indicator for determination of the need for corticosteroid application in orbital cellulitis [29]. In an earlier study, IV dexamethasone was administered on admission concurrently with broad spectrum IV antibiotics. The dosing regimen selected was based on the standard pediatric IV dosing of dexamethasone for the treatment of inflammation (0.3 mg/kg/d divided every 6 hours) [30]. Antibiotics with high sensitivity can be replaced depending on the specific drug sensitivity results. Importantly, surgical incision and pus drainage are to be performed in cases of incorrect or missed orbital cellulitis diagnosis, as well as when the applied antibiotics therapy has been ineffective, the imaging has shown abscess formation, or after vision loss + persistent high fever despite intravenous antibiotics administration for 24–48 hours and worsening clinical symptoms. The rates of surgery in most studies are within the range of 0–11% [31]. Importantly, subperiosteal abscess is not an absolute indication for immediate surgery (Figure 3) [32].

Here, we present our analysis and summary of the initial treatment process features in a case of an orbital mass detected in children. The following information was collected: a history of trauma or eye surgery, presence of eyelid edema, extraocular movement, abnormal changes in visual acuity, exophthalmos, diplopia, fever, headache, and other clinical manifestations. Routine blood test + CRP + blood culture + CT examination results were also required. CT scans were necessary for the following conditions in patients with orbital cellulitis: inability to perform a complete eye evaluation, exophthalmos, ophthalmoplegia, and pain in external eye movements, decreased vision, or central symptoms (seizures, focal neurological deficits, or a change in the mental state). In clinical cases of intracranial

complications or cavernous sinus thrombosis or such suspected on the basis of CT findings, such as changes in the mental status, persistent fever after appropriate treatment, or CT findings suggesting intracranial expansion, MRI should be considered [25, 31]. When the clinical manifestations support orbital cellulitis, but the CT examination results are normal, MRI examination is recommended to be performed to facilitate the diagnosis [33]. In case of intracranial symptoms, MRI examination is to be performed. If orbital cellulitis is diagnosed, conservative treatment can be initially administered, including the application of topical quinolone-containing eye drops on the eyelids, levofloxacin eye drops, and gatifloxacin eye ointment in combination with systemic broad-spectrum antibiotic therapy (Figure 3).

Briefly, in cases of orbital swelling, we recommend that multidisciplinary consultation should be performed, considering all infectious and non-infectious causative factors. Ineffective three-day conservative treatment should be followed by CT/MRI examination for diagnosis and treatment facilitation. However, surgery is to be considered in cases of persistent or progressive symptoms.

Declarations

Acknowledgements

Not applicable.

Authors' contributions

Cong Liang: drafted the manuscript; Ru-Jiang Zheng: collected the patient data; Su-Ping Li: reviewed the literature; Yi-Juan Li and Ling-Ling Xu contributed to the final version of the manuscript. All authors read and approved the final manuscript.

Funding

There is no funding to declare.

Availability of data and materials

Data sharing is not applicable to this article as no datasets were generated during the current study. All data analyzed during this study are included in this published article. Clinical data are available in the patient's clinical records at the first affiliated hospital of Sun Yat-sen University.

Ethics approval and consent to participate

Not applicable.

Consent for publication

Written informed consent for publication of clinical details was obtained from the parents of the patient. A copy of the consent form is available for review by the Editor of this journal.

Competing interests

The authors declare that there is no conflict of interest.

References

1. Sow, A.J., et al., *Sphenoethmoid sinusitis in a child resulting in a disastrous intracranial sequela*. Ear Nose Throat J, 2012. **91**(11): p. E20-2.
2. Ketenci, I., et al., *Approaches to subperiosteal orbital abscesses*. Eur Arch Otorhinolaryngol, 2013. **270**(4): p. 1317–27.
3. Wan, Y., G. Shi, and H. Wang, *Treatment of Orbital Complications Following Acute Rhinosinusitis in Children*. Balkan Med J, 2016. **33**(4): p. 401–6.
4. Laycock, J., et al., *Facial trauma aggravating paediatric orbital cellulitis*. BMJ Case Rep, 2020. **13**(4).
5. Habroosh, F.A., H. Eatamadi, and R.M. Mohamed, *Concomitant orbital aspergillosis and mucormycosis in a 17 months old immunocompetent child*. Saudi J Ophthalmol, 2017. **31**(3): p. 193–195.
6. Mohd-Ilham, I., et al., *Clinical characteristics and outcomes of paediatric orbital cellulitis in Hospital Universiti Sains Malaysia: a five-year review*. Singapore Med J, 2020. **61**(6): p. 312–319.
7. Amanati, A., et al., *Orbital mucormycosis in immunocompetent children; review of risk factors, diagnosis, and treatment approach*. BMC Infect Dis, 2020. **20**(1): p. 770.
8. Alqaseer, B. and I. Almutawa, *A Case of Idiopathic Orbital Inflammation in a Seven-Year-Old Child*. Cureus, 2021. **13**(3): p. e13924.
9. Stewart, C.M., et al., *Acute Sickle Cell Orbitopathy Masquerading as Orbital Cellulitis*. J Pediatr Hematol Oncol, 2018. **40**(1): p. 79–80.
10. Pinto, A., et al., *Aseptic pediatric orbital cellulitis: retinoblastoma until otherwise proven*. Ophthalmic Genet, 2019. **40**(5): p. 488–492.
11. Richards, N.Q., et al., *Atypical presentation of isolated orbital Langerhans cell histiocytosis*. Sarcoidosis Vasc Diffuse Lung Dis, 2019. **36**(2): p. 167–171.
12. Sundu, C., et al., *Bilateral Subperiosteal Hematoma and Orbital Compression Syndrome in Sickle Cell Disease*. J Craniofac Surg, 2017. **28**(8): p. e775-e776.
13. Albert-Fort, M. and M. González-Candial, *A case report of orbital Langerhans cell histiocytosis presenting as a orbital cellulitis*. Arch Soc Esp Oftalmol (Engl Ed), 2018. **93**(10): p. 503–506.
14. Sen, P., et al., *External ophthalmomyiasis in a neonate masquerading as an orbital cellulitis*. Indian J Ophthalmol, 2020. **68**(5): p. 900–901.
15. Pushker, N., et al., *Intra-ocular medulloepithelioma as a masquerade for PHPV and Panophthalmitis: a Diagnostic Dilemma*. Saudi J Ophthalmol, 2017. **31**(2): p. 109–111.
16. Ali-Ridha, A., et al., *Langerhans cell histiocytosis in an 18-month-old child presenting as periorbital cellulitis*. Saudi J Ophthalmol, 2018. **32**(1): p. 52–55.
17. Fung, S.S., S.J. West, and A.T. Moore, *Ophthalmomyiasis interna masquerading as orbital cellulitis*. J aapos, 2016. **20**(6): p. 546-548.e2.
18. Essa, M.F. and A. Alsultan, *Orbital extramedullary leukemia relapse in a pediatric patient post-CART cell therapy-Case report*. Pediatr Transplant, 2021. **25**(5): p. e13852.
19. Drobysheva, A., et al., *Orbital Granulomatosis With Polyangiitis Mimicking IgG4-Related Disease in a 12-Year-Old Male*. Int J Surg Pathol, 2018. **26**(5): p. 453–458.
20. Martino, F., et al., *Orbital Pseudocellulitis: A Retinoblastoma-Associated Masquerade Syndrome*. Ocul Oncol Pathol, 2020. **6**(6): p. 430–437.
21. Galindo-Ferreiro, A., et al., *Recurrent Orbital Inflammation Mimicking Orbital Cellulitis Associated With Orbitopalpebral Venous Lymphatic Malformation*. Ophthalmic Plast Reconstr Surg, 2017. **33**(5): p. e112-e114.

22. Sepahdari, A.R., et al., *MRI of orbital cellulitis and orbital abscess: the role of diffusion-weighted imaging*. AJR Am J Roentgenol, 2009. **193**(3): p. W244-50.
23. McMaster, D., S. Patel, and C. Marsh, *Variation in UK guidelines for the first-line antimicrobial management of paediatric orbital cellulitis-time for national recommendations*. Eye (Lond), 2021. **35**(4): p. 1061–1065.
24. Coudert, A., et al., *Microbiology and antibiotic therapy of subperiosteal orbital abscess in children with acute ethmoiditis*. Int J Pediatr Otorhinolaryngol, 2018. **106**: p. 91–95.
25. Adamson, J. and T. Waterfield, *Fifteen-minute consultation: Preseptal and orbital cellulitis*. Arch Dis Child Educ Pract Ed, 2019. **104**(2): p. 79–83.
26. Stimes, G.T. and J.E. Girotto, *Applying Pharmacodynamics and Antimicrobial Stewardship to Pediatric Preseptal and Orbital Cellulitis*. Paediatr Drugs, 2019. **21**(6): p. 427–438.
27. Kim, B.Y. and J.H. Bae, *Role of systemic corticosteroids in orbital cellulitis: a meta-analysis and literature review*. Braz J Otorhinolaryngol, 2021.
28. Mahalingam, S., et al., *The role of adjuvant systemic steroids in the management of periorbital cellulitis secondary to sinusitis: a systematic review and meta-analysis*. Eur Arch Otorhinolaryngol, 2021. **278**(7): p. 2193–2201.
29. Davies, B.W., et al., *C-Reactive Protein As a Marker for Initiating Steroid Treatment in Children With Orbital Cellulitis*. Ophthalmic Plast Reconstr Surg, 2015. **31**(5): p. 364–8.
30. Chen, L., et al., *Intravenous Steroids With Antibiotics on Admission for Children With Orbital Cellulitis*. Ophthalmic Plast Reconstr Surg, 2018. **34**(3): p. 205–208.
31. Wong, S.J. and J. Levi, *Management of pediatric orbital cellulitis: A systematic review*. Int J Pediatr Otorhinolaryngol, 2018. **110**: p. 123–129.
32. Cohen, N., et al., *Clinicians need to consider surgery when presented with some markers for severe paediatric orbital cellulitis*. Acta Paediatr, 2020. **109**(6): p. 1269–1270.
33. Basily, A., et al., *Orbital Cellulitis-When Computed Tomography Imaging Is Falsely Reassuring*. Pediatr Emerg Care, 2021. **37**(1): p. e48-e50.

Figures

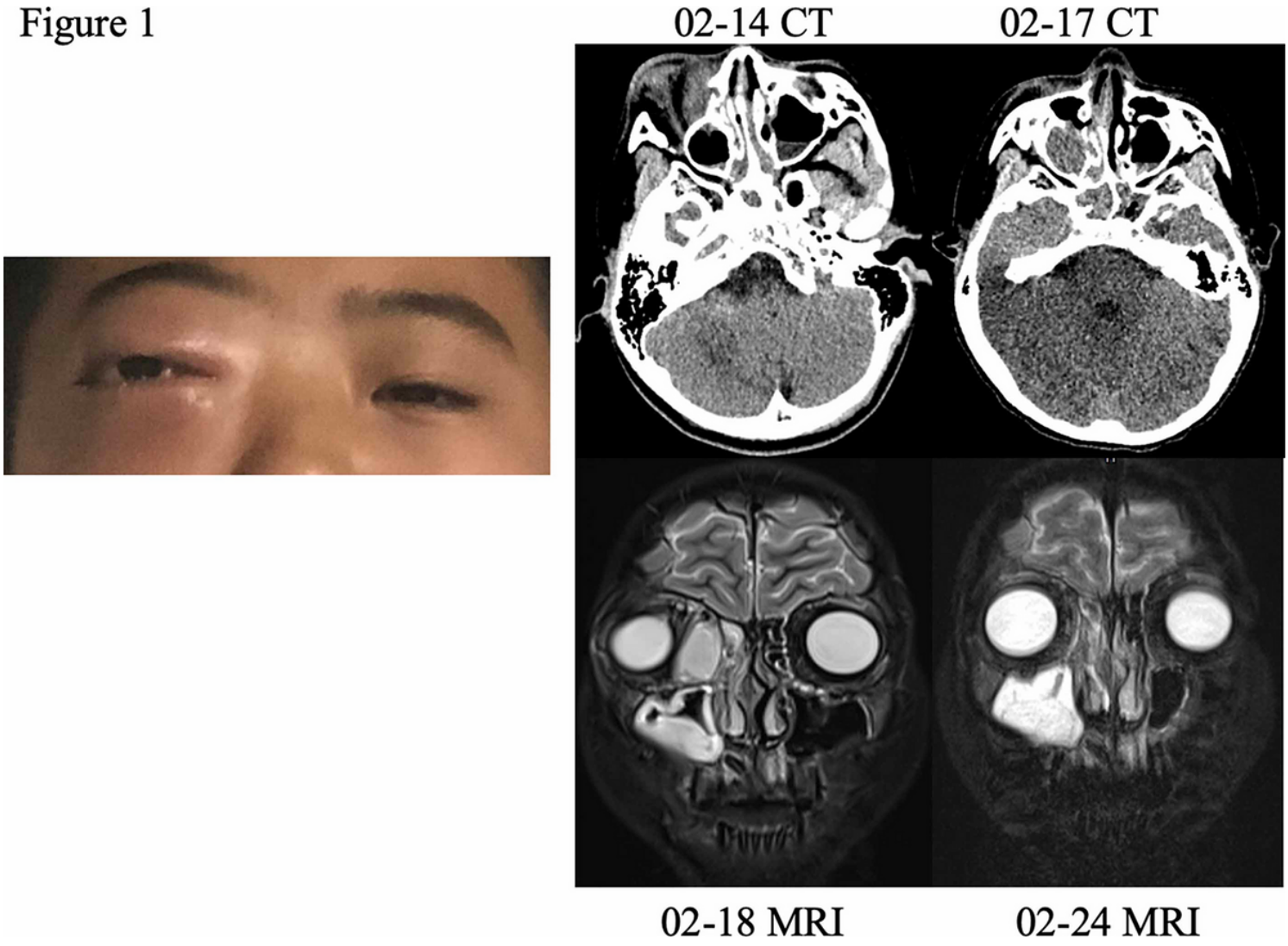

Figure 1

Swelling of the right eye before treatment and image scan within hospitalization 02-14、02-17CT and 02-18MRI performed prior to surgery showing a significant right eye proptosis, cellulitis and sinusitis. Postoperative MRI (02-24) showed no cellulitis of the right orbit.

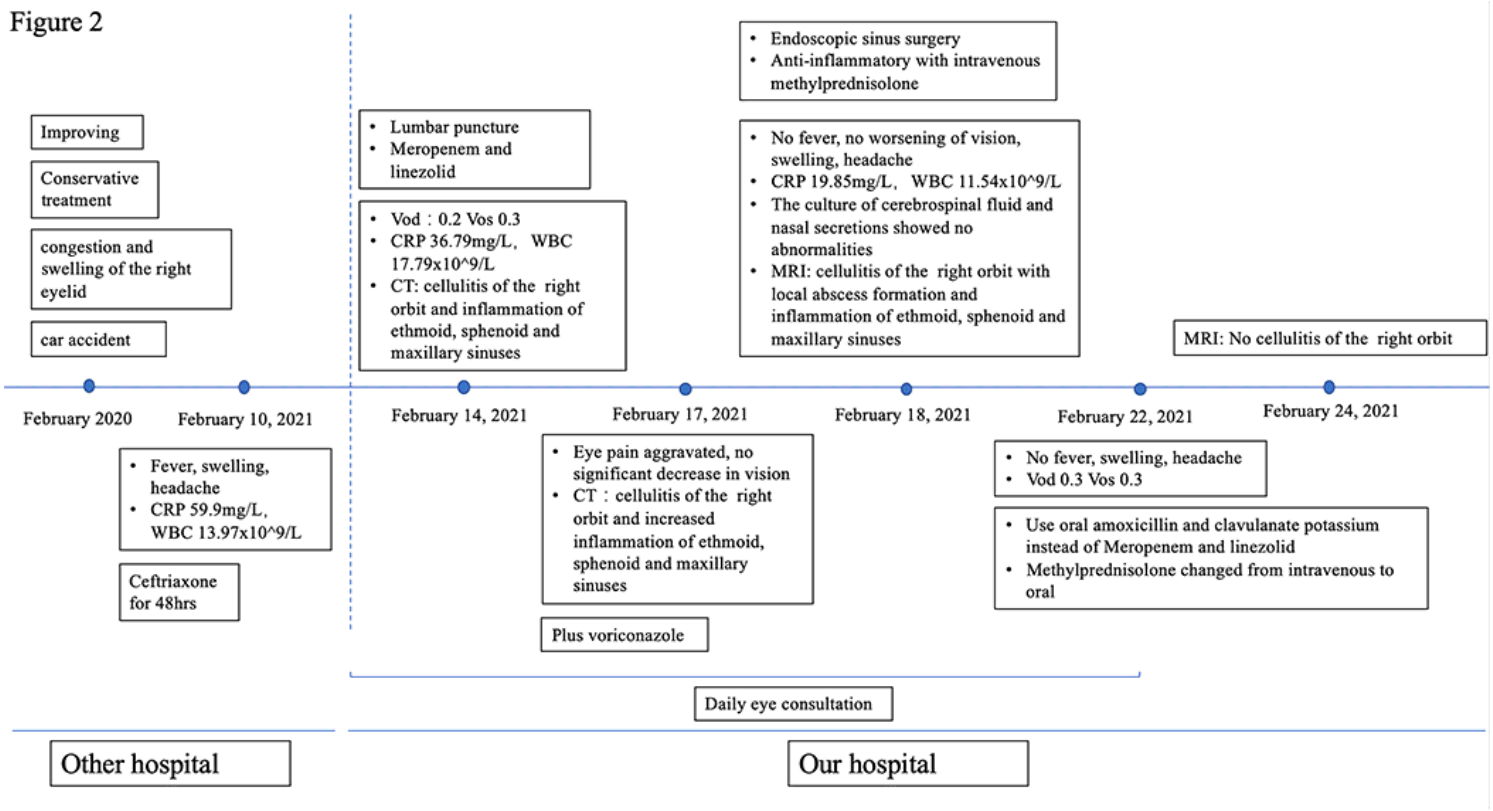

Figure 2

Treatment line Timeline of disease progression and treatment events in our patient

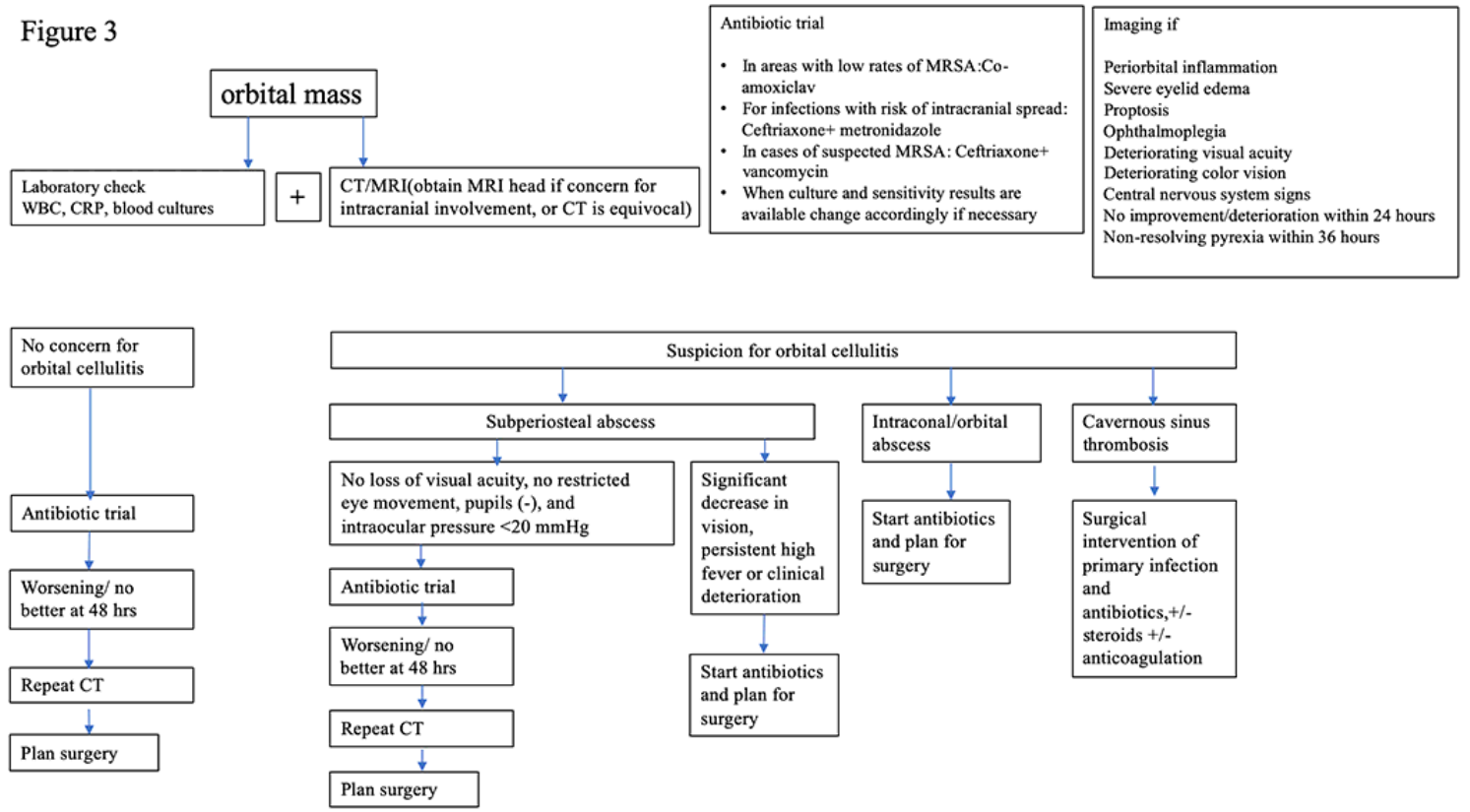

Figure 3

Algorithm for the diagnosis and management of periorbital abscess.

Supplementary Files

This is a list of supplementary files associated with this preprint. Click to download.

- TableS1.docx