VATS right upper posterior segmentectomy with anomalous bronchiand pulmonary vessels: a case report and literature review

Jianbin Zhang (fishing11@163.com)

HuZhou Central Hospital, Affiliated Central Hospital of Huzhou University https://orcid.org/0000-0001-6007-1247

Yilv Zhu

Affiliated Hospital of Huzhou Normal University: Huzhou Central Hospital

Hongwei Li

Affiliated Hospital of Huzhou Normal University: Huzhou Central Hospital

Caihua Yu

Affiliated Hospital of Huzhou Normal University: Huzhou Central Hospital

Weiwei Min

Affiliated Hospital of Huzhou Normal University: Huzhou Central Hospital

Case report

Keywords: Video-assisted thoracoscopic surgery (VATS), three-dimensional computed tomography bronchography and angiography (3D-CTBA), segmentectomy, case report

Posted Date: November 13th, 2020

DOI: https://doi.org/10.21203/rs.3.rs-104612/v1

Version of Record: A version of this preprint was published at Journal of Cardiothoracic Surgery on March 29th, 2021. See the published version at https://doi.org/10.1186/s13019-021-01420-2.

Abstract

Background

Anatomic variation may increase the difficulty and risk for anatomic segmentectomy. The preoperative three-dimensional computed tomography bronchography and angiography(3D-CTBA) can provide a detailed model of the segmental structure, and contribute to precise and safe segmentectomy.

Case presentation

We report a case with anomalous bronchi and pulmonary vessels in the right upper posterior segment (RS^2), under the guidance of 3D-CTBA, anatomic RS^2segmentoctomywas performed accurately and safely, the postoperative condition was uneventful.

Conclusions

This rare case highlights the importance of 3D-CTBA to guild accurate segmentectomy with anatomic variation.

Introduction

With the popularization of chest computed tomography (CT), the discovery of small pulmonary nodules is increasingly common, and it promotes the progress of segmentectomy as well[1, 2]. The anatomic structure of the pulmonary segment is sometimes variable, as reported in the previous cases[3–5]. The public's attention is now shifting to how to achieve an accurate anatomic segmentectomy. In terms of the successful resection, the development and application of various 3D imaging softwares have given strong technical supports[6]. Preoperative reconstruction of the segment can clearly show the anatomic structure and judge whether there are variations, so as to make an accurate surgical plan. In this case, we reported a 34-year-old female patient who experienced a ground-glass nodule (GGN) at the right upper posterior segment (RS^2). The preoperative three-dimensional computed tomography bronchography and angiography (3D-CTBA) displayed multiple anatomic variations. Through the detailed planning of the operation, video-assisted thoracoscopic surgery (VATS) RS^2 segmentectomy was carried out successfully.

Case Presentation

A 34-year-old female was admitted to us with a GGN in RS^2, discovered by chest CT during health checkup one year ago. A review of CT showed the subpleural GGN was slightly larger than before, with the diameter of 7 mm, and the CT value was − 400HU (Fig. 1). She had no positive signs, no history of smoking, no history of malignant tumors, and no family history of lung cancer. Preoperative 3D-CTBA displayed multiple variations in the right upper lobe: (1) The apical subsegmental bronchi(B^1a and B^1b)originated from the posterior segmental bronchus (B^2) and the anterior segmental bronchus (B^3)

respectively; (2) The right upper pulmonary arteries shared trunk without posterior ascending artery (Asc.A^2); (3) The right upper lobe had no central vein, with only one posterior intrasegmental vein (V^2t), the other two veins pointed to intersegmental plane respectively without another posterior intrasegmental vein (V^2b) (Fig. 2). With the guidance of 3D-CTBA, VATS anatomic RS^2 segmentectomy and lymph node sampling were conducted accurately (video 1), all anatomic variations were successfully detected during the operation (Fig. 3). The fast-frozen pathology was minimally invasive adenocarcinoma (MIA). The chest radiograph illustrated that the right lung was completely re-dilated, and the incisal margin of the segment displayed no obvious exudation on the 2nd postoperative day (Fig. 4). The drainage tube was removed on the 2nd postoperative day, and the patient was discharged on the 3rd postoperative day. The postoperative pathology revealed MIA with negative surrounding lymph nodes.

Video Description

Intravenous general anesthesia combined with double-lumen endotracheal intubation and contralateral one-lung ventilation were performed. The observation port was made in the 7th intercostal space of the posterior axillary line, and the operation port in the 4th intercostal space of the anterior axillary line. The surgical procedure was as follows: (1) Thoracoscopic exploration revealed a subpleural nodule at the RS^2; (2) The parietal pleura was sectioned by harmonic, then the Nos.11 lymph nodes were removed; (3) The V^2t was dissociated and pulled by silk, the Nos.12 and 13 lymph nodes around the bronchus were completely removed; (4) After ligating the V^2t, the B^2 was dissected out and transected with a thick tissular (blue cartridge) 45 mm long endostapler (EC45A, JJMC, USA); (5) According to the preoperative 3D-CTBA, the other two veins were judged as the intersegmental veins, so they were all preserved; (6) Due to the posterior segmental artery was very difficult to ligate, we reventilated the right lung with pure oxygen, when the intersegmental plane was clear after about 15 minutes, the segmental hilum was released sufficiently to expose the posterior segmental artery, then the artery was ligated safely;(7) The intersegmental plane was divided along the inflation-deflation line using the endostaplers, thus the posterior segment was removed successfully. A sterile glove was made to collect the specimen. No bleeding and air leakage were discovered after the pleural injection of inflation. No. 24 chest drainage tube was placed in the observation port. After the right lung was completely dilated, the incision was sutured. The operative time was about 70 min, and intraoperative blood loss was about 50 ml.

Conclusion

Anatomic segmentectomy for early lung cancer is one of the biggest hotspots in thoracic surgery in recent years. It can not only completely resect the tumor, but also preserve the normal lung tissue to the maximum extent[7]. The distribution of bronchus, artery and vein in pulmonary segment exists variations in some patients. The key to the implementation of this operation is to accurately grasp the anatomical structure of the target segment. The 3D-CTBA can provide a precise anatomical structure, identify the intrasegmental and intersegmental veins from different views[8]. Some complicated pulmonary segmentectomy should be performed under the guidance of 3D-CTBA[9, 10].

The efficacy of 3D reconstruction for thoracic surgery has been previously described[11], Kimihiroet al.[12] first reported the application of 3D-CTBA in VATS segmentectomy. At present, the main softwares for 3D reconstruction of segment include IQQA, DeepInsight, etc[13, 14]. All the reconstructive softwares can offer precise anatomical structure of pulmonary segments, but sometimes, it is difficult for surgeons to skillfully use them. In our institution, with the assistance of the radiologists, we adopt the computed tomography pulmonary angiography (CTPA)-based technology to reconstruct the anatomic structure for each patient who undergoing segmentectomy. It shows the precise structure of bronchi, arteries and veins in a natural surgical field view, and the results are also satisfactory.

RS^2 segmentectomy is a common procedure in all kinds of segmental resection, but the anatomic variations may increase the difficulty and risk[15]. Xinfeng et al.[16] reported a tracheal bronchus and a variable central vein entering the left atrium dorsal to the right pulmonary artery trunk in a patient underwent VATS RS^2 segmentectomy. Tadashi et al. [17] reported a patient with anatomic variations in bronchi and pulmonary vessels during thoracoscopic RS^2 segmentectomy. However, to the best of our knowledge, bronchial variation associated with variant pulmonary vessels has rarely been reported. The normal anatomic structure of RS^2 consists of B^2, $Asc.A^2$, the recurrent artery ($Rec.A^2$), intrasegmental veins (V^2tand V^2b) and intersegmental veins (V^2aand V^2c), but in this case, the 3D-CTBA revealed multiple variations: (1) The bronchopulmonary trees of the right upper lobe were divided into (B^2 + B^1a)and (B^3 + B^1b), the (B^2 + B^1a) variation might have been mistaken for B^2 without the guidance of3D-CTBA; (2)There was only one intrasegmental vein (V^2t) without another rintrasegmental vein (V^2b), intersegmental veins might have been transected as intrasegmental veins without the preoperative 3D-CTBA; (3) The posterior segmental arteries originated from the superior trunk without $Asc.A^2$, they were very difficult to expose, so we released the hilum of segment first to expose the arteries sufficiently, then the artery was ligated safely, this novel strategy has rarely been reported. In conclusion, we present a successful strategy for VATS RS^2 segmentectomy with multiple anatomic variations.

Abbreviations

3D-CTBA: three-dimensional computed tomography bronchography and angiography; RS^2 right upper posterior segment; VATS: Video-assisted thoracoscopic surgery; CT: computed tomography; GGN: ground-glass nodule; MIA: minimally invasive adenocarcinoma; B^1: apical segmental bronchus; B^2: posterior segmental bronchus; B^3: anterior segmental bronchus; $Asc.A^2$: ascending artery; $Rec.A^2$: recurrent artery;

Declarations

Data availability statement

The data used to support the findings of this study are included within the article.

Authors' contributions

JZ was the main surgeon and drafted the manuscript. YZ performed the 3D-CTBA. CY and WM helped care for the patient and draft the manuscript. HL reviewed and modified the manuscript. All authors read and approved the final manuscript.

Acknowledgements

Not applicable.

Funding

Not applicable.

Ethics approval and consent to participate

The article was reviewed and approved by the by the research ethics committee of Huzhou Central Hospital, Affiliated Central Hospital of Huzhou University. Written informed consent was signed by all participants.

Consent for publication

Not applicable.

Competing interests

The authors declare that they have no competing interests.

References

1. Nakazawa S, Shimizu K, Mogi A, Kuwano H: **VATS segmentectomy: past, present, and future**. *Gen Thorac Cardiovasc Surg* 2018, **66**(2):81-90.
2. Sato Y, Fujimoto D, Morimoto T, Uehara K, Nagata K, Sakanoue I, Hamakawa H, Takahashi Y, Imai Y, Tomii K: **Natural history and clinical characteristics of multiple pulmonary nodules with ground glass opacity**. *Respirology* 2017, **22**(8):1615-1621.
3. Aragaki M, Iimura Y, Yoshida Y, Hasegawa N: **Anomalous V(2) of the left pulmonary vein detected using three-dimensional computed tomography in a patient with lung cancer: A case report**. *Int J Surg Case Rep* 2017, **37**:208-210.
4. Ohtaka K, Iwashiro N, Watanabe K, Mizota T, Takahashi R, Suzuoki M, Komuro K, Ohara M, Kaga K, Matsui Y: **A left lung abscess with a displaced subsegmental bronchus and anomalous pulmonary artery and vein: a case report**. *Surg Case Rep* 2019, **5**(1):66.
5. Qi W, Yang F, Liu H, Sun Y: **Thoracoscopic right apical segmentectomy for lung cancer with tracheal bronchus and variable pulmonary vein: a case report and literature review**. *J Int Med Res* 2020, **48**(8):300060520947935.

6. Chang SS, Okamoto T, Tokunaga Y, Nakano T: **Intraoperative Computed Tomography Navigation During Thoracoscopic Segmentectomy for Small-sized Lung Tumors**. *Semin Thorac Cardiovasc Surg* 2018, **30**(1):96-101.
7. Tane S, Nishio W, Nishioka Y, Tanaka H, Ogawa H, Kitamura Y, Takenaka D, Yoshimura M: **Evaluation of the Residual Lung Function After Thoracoscopic Segmentectomy Compared With Lobectomy**. *Ann Thorac Surg* 2019, **108**(5):1543-1550.
8. Wu WB, Xu XF, Wen W, Xu J, Zhu Q, Chen L: **Thoracoscopic Pulmonary Sub-Subsegmentectomy Based on Three-Dimensional Images**. *Ann Thorac Surg* 2016, **102**(5):e389-e391.
9. Sato M, Murayama T, Nakajima J: **Thoracoscopic stapler-based "bidirectional" segmentectomy for posterior basal segment (S10) and its variants**. *J Thorac Dis* 2018, **10**(Suppl 10):S1179-S1186.
10. Shimizu K, Nagashima T, Yajima T, Ohtaki Y, Obayashi K, Nakazawa S, Kosaka T, Mogi A, Kuwano H: **Thoracoscopic Medial-Basal Segment Segmentectomy**. *Ann Thorac Surg* 2017, **104**(5):e403-e406.
11. Fukuhara K, Akashi A, Nakane S, Tomita E: **Preoperative assessment of the pulmonary artery by three-dimensional computed tomography before video-assisted thoracic surgery lobectomy**. *Eur J Cardiothorac Surg* 2008, **34**(4):875-877.
12. Shimizu K, Nakano T, Kamiyoshihara M, Takeyoshi I: **Segmentectomy guided by three-dimensional computed tomography angiography and bronchography**. *Interact Cardiovasc Thorac Surg* 2012, **15**(2):194-196.
13. Wu WB, Xu XF, Wen W, Xu J, Zhu Q, Pan XL, Xia Y, Chen L: **Three-dimensional computed tomography bronchography and angiography in the preoperative evaluation of thoracoscopic segmentectomy and subsegmentectomy**. *J Thorac Dis* 2016, **8**(Suppl 9):S710-S715.
14. Xu G, Chen C, Zheng W, Zhu Y, Zheng B, Chen H: **IQQA-3D imaging interpretation and analysis system-guided single-port video-assisted thoracic surgery for anatomical sub-segmentectomy (LS(1+2)a+b)**. *J Thorac Dis* 2018, **10**(9):5515-5521.
15. Polaczek M, Szaro P, Jakubowska L, Zych J, Religioni J, Orlowski TM: **Pulmonary veins variations with potential impact in thoracic surgery: a computed-tomography-based atlas**. *J Thorac Dis* 2020, **12**(3):383-393.
16. Xu XF, Chen L, Wu WB, Zhu Q: **Thoracoscopic right posterior segmentectomy of a patient with anomalous bronchus and pulmonary vein**. *Ann Thorac Surg* 2014, **98**(6):e127-129.
17. Akiba T, Morikawa T, Marushima H, Nakada T, Inagaki T, Ohki T: **Computed tomography guided thoracoscopic segmentectomy for lung cancer with variant bronchus**. *Ann Thorac Cardiovasc Surg* 2014, **20**(5):407-409.

Figures

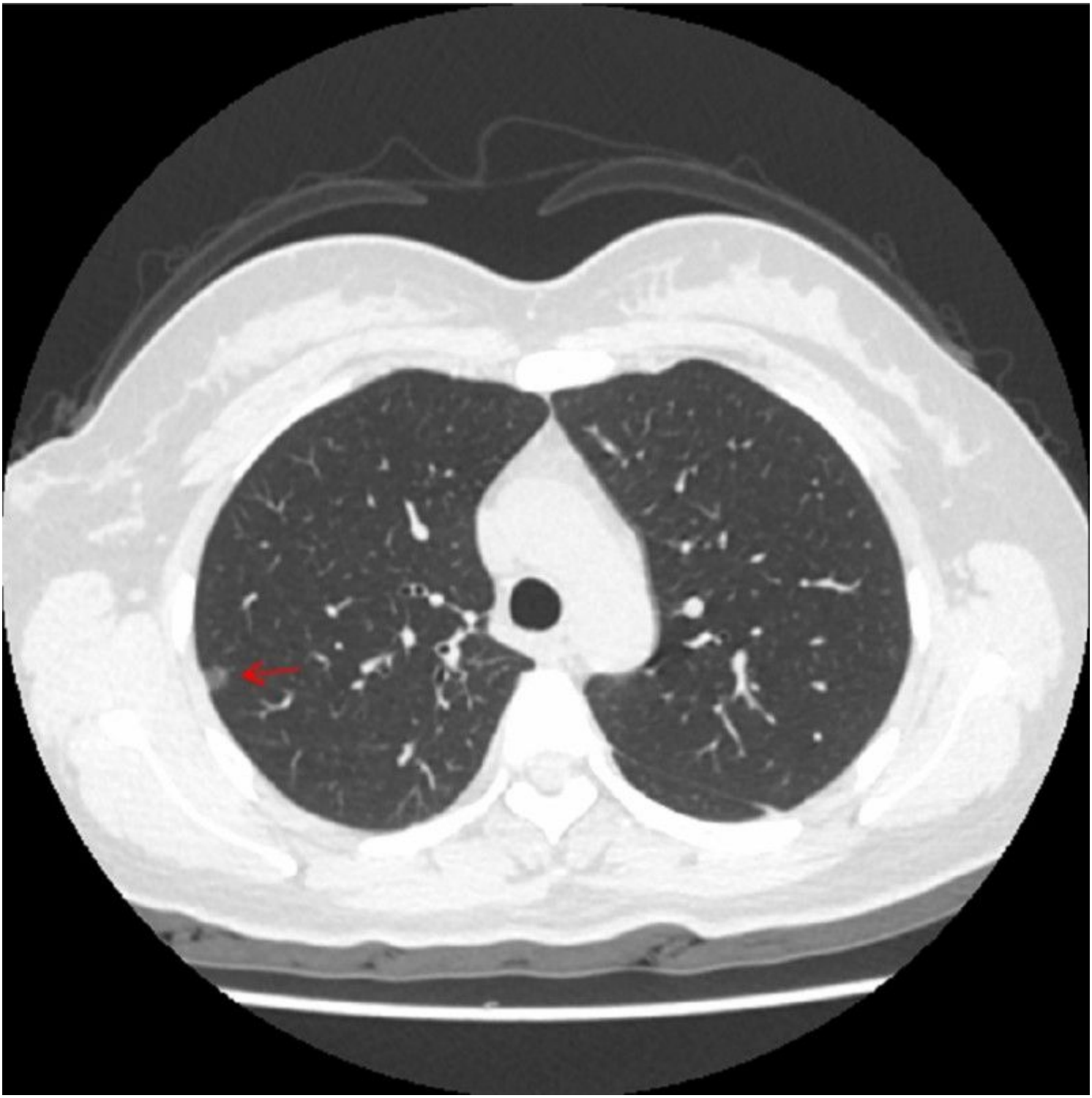

Figure 1

The preoperative computed tomography scanning. A 7-mm ground-glass nodule was identified at the posterior segment of the right upper lobe (arrow) , the CT value was -400HU.

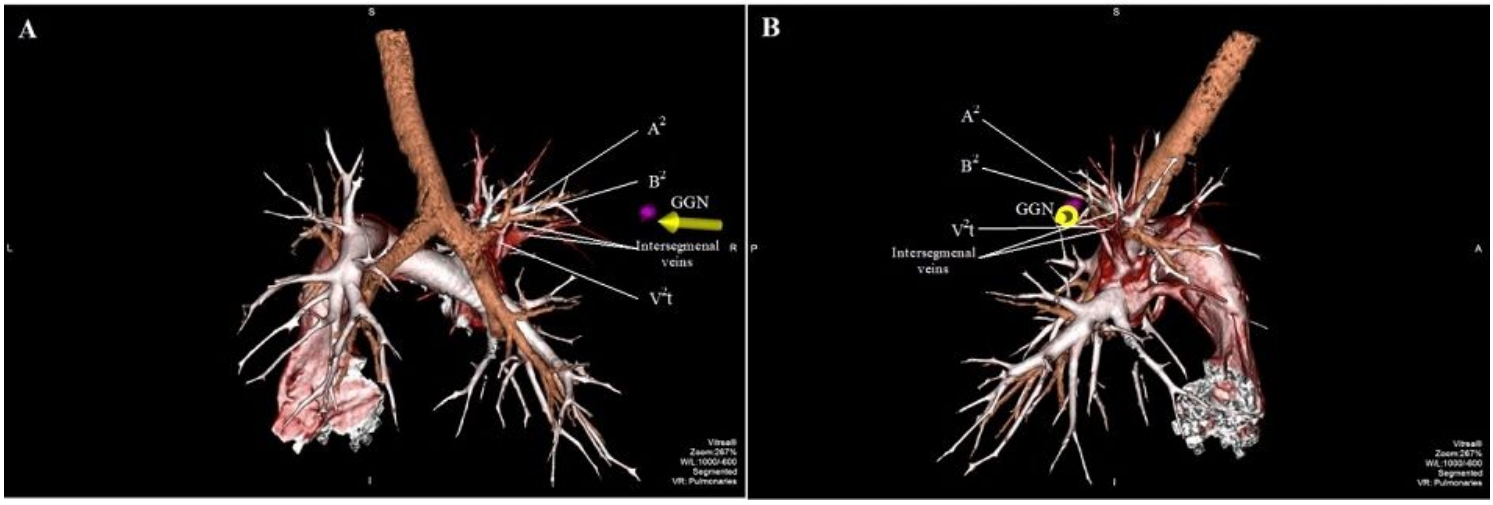

Figure 2

The three-dimensional computed tomography bronchography and angiography.The apical subsegmental bronchi B1a and B1b originated from the posterior segmentalbronchus (B2) and the anterior segmental bronchus (B3) respectively; The right upper pulmonary artery shared trunk without posterior ascending artery(Asc.A2); The right upper pulmonary vein had no central vein, with only one posterior intrasegmental vein(V2t), the other two veins pointed to the intersegmental plane respectively. (A) Posterior view; (B) Lateral view.

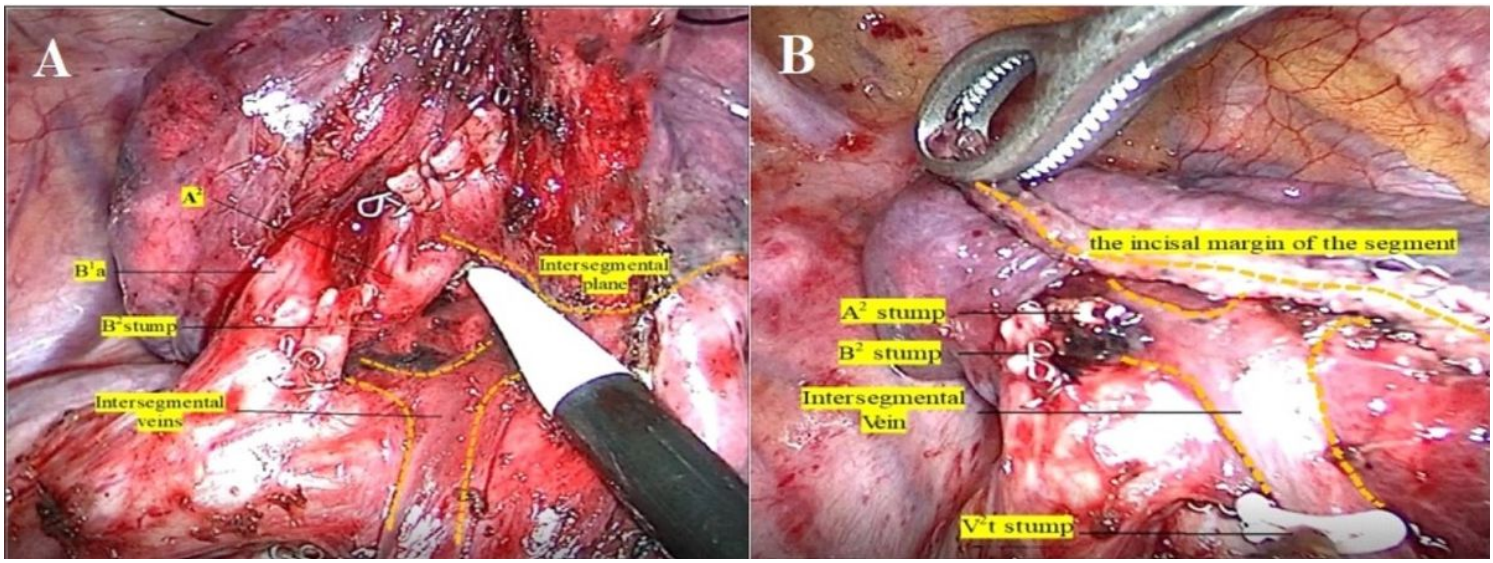

Figure 3

The intraoperative view of the posterior segment of the right upper lobe.(A)Exposed the posterior segmental artery after releasing the segmental hilum sufficiently;(B) The structure of lung segmental hilum after resection.

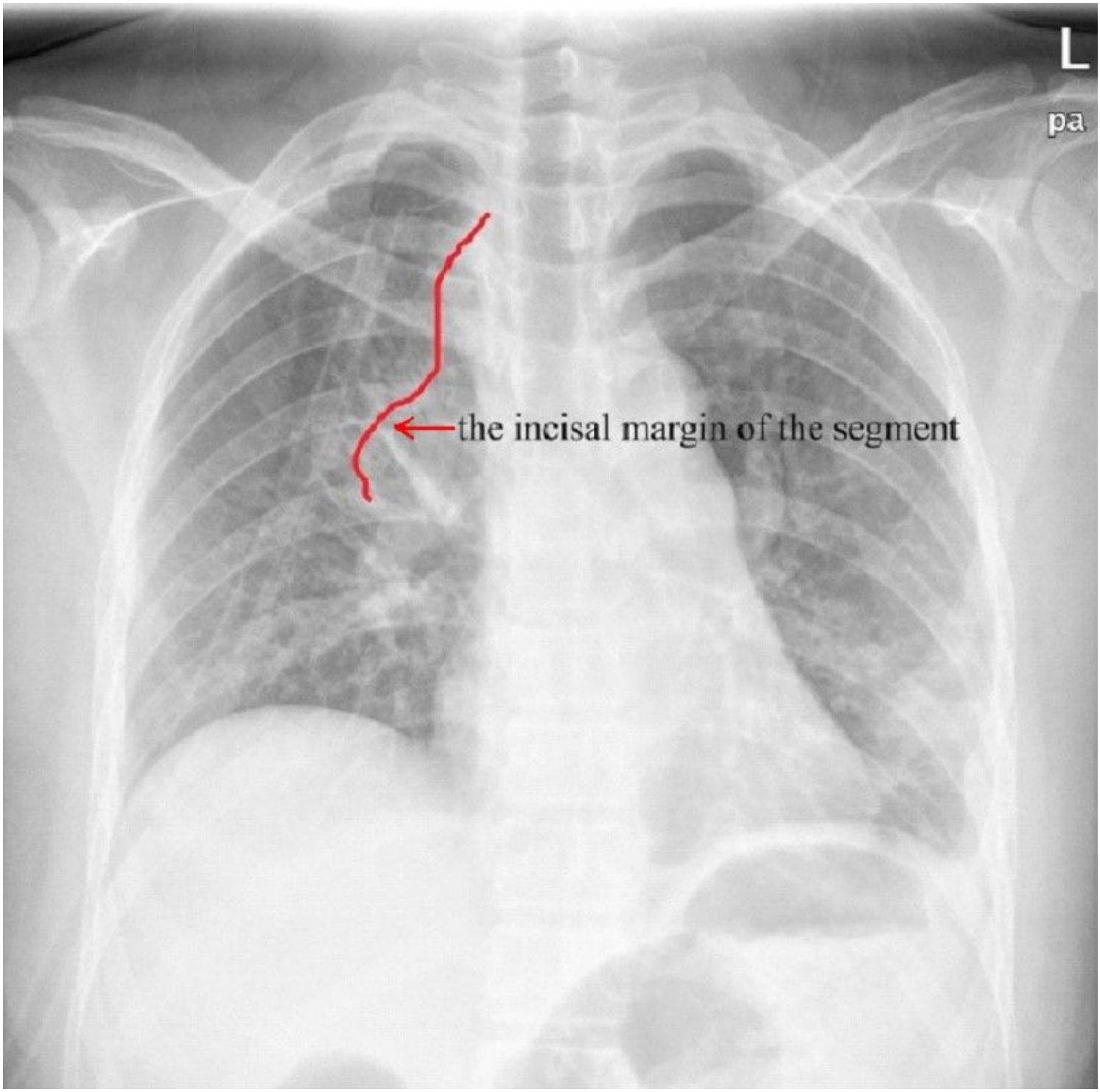

Figure 4

The chest radiograph on the 2nd postoperative day. Theincisal margin of the segment displayed no obvious exudation(arrow).

Supplementary Files

This is a list of supplementary files associated with this preprint. Click to download.

- CARChecklistEnglish2013.pdf