Comparison of marsupialization under nasal endoscopy versus Lacrimal probing for treatment of congenital dacryocystoceles: a report of 40 cases

Yanhui Cui
Beijing Children's Hospital, National Centre for Children's Health, China
Peng Sun
Beijing New Century Women's and Children's Hospital
Lixing Tang
Beijing Children's Hospital, National Centre for Children's Health, China
Chengyue Zhang
Beijing Children's Hospital, National Centre for Children's Health, China
Qian Wu
Beijing Children's Hospital, National Centre for Children's Health, China
Gang Yu
Beijing Children's Hospital, National Centre for Children's Health, China
Li Li
Beijing Children's Hospital, National Centre for Children's Health, China
Wen Bin Wei (weiwenbintr@163.com)
Beijing Tongren Hospital

Research article

Keywords: Nasal endoscopy; Marsupialization; Lacrimal probing; Congenital dacryocystocele

Posted Date: May 27th, 2019

DOI: https://doi.org/10.21203/rs.2.9860/v1

Abstract

Introduction This study was performed to compare the efficacy of marsupialization under nasal endoscopy versus Lacrimal probing in the treatment of congenital dacryocystocele. Methods Forty neonates (43 eyes) diagnosed with congenital dacryocystoceles were divided into Group A (nasal endoscopic marsupialization) and Group B (Lacrimal probing). The patients were followed up for 1 year after surgery. The efficacy, incidence of complications, and reoperation rate were compared between the two groups. Results The male:female ratio was 25:15 patients (27:16 eyes). In Group A, the success rate was 100%, the incidence of complications was 5%, and the reoperation rate was 0%. In Group B, the success rate was 90%, the incidence of complications was 20%, and the reoperation rate was 30%. Conclusion Compared with Lacrimal probing, marsupialization under nasal endoscopy provides greater efficacy and safety for congenital dacryocystoceles.

Introduction

A congenital dacryocystocele, also known as a dacryocyst mucocele, is a rare congenital lacrimal disease. The most common causes are congenital membranous atresia of Hasner's valve at the distal end of the nasolacrimal duct and functional atresia of the valve of Rosenmuller at the proximal end of the dacryocyst [1]. The typical clinical manifestation is a hard, dark blue mass at the inner canthus within 1 week to 1 month after delivery [2,3]. This mass may be accompanied by various degrees of nasal congestion and lacrimation, and dyspnea and suffocation during breastfeeding may occur if the masses are bilateral. Traditionally, conservative observation or Lacrimal probing has been performed in patients with ongenital dacryocystoceles. However, with the development of pediatric surgical techniques involving the nose and eyes, marsupialization under nasal endoscopy has recently been used to treat congenital dacryocystoceles in clinical practice with favorable efficacy and safety [4]. Since 2012, nasal endoscopy has been conducted in our ophthalmology department to treat pediatric lacrimal duct disorders. We herein share our clinical experience with treating congenital dacryocystoceles by marsupialization under nasal endoscopy.

Methods

Basic demographics

We retrospective assessed 40 children (43 eyes) with complete data who were treated in our hospital for a hard, dark blue mass at the inner canthus after birth from March 2012 to January 2016. All patients had a cystic space-occupying lesion in the affected inferior nasal meatus that was further diagnosed as a congenital dacryocystocele by computed tomography (CT) scanning at a low dosage (tube current of <50 mA) or electronic nasopharyngoscope. There are 20 cases (23 eyes) were grouped in Group A these patients underwent marsupialization by nasal endoscopy under general anesthesia at a median age of

18 days (8-27 days). 15 patients with dacryocystitis were treated by antibiotics before the operation. Other 20cases (20 eyes) were grouped in Group B, these patients underwent Lacrimal probing at a median age of 19 days (9-27 days). 13 patients with dacryocystitis were treated by antibiotics before the operation.

Methods

Surgical methods

All neonatal patients in Group A were treated by surgery under general anesthesia. Cotton soaked with 1:10,000 adrenaline was used for vessel contraction on the affected side. A semitransparent pink cystic mass was observed in the inferior nasal meatus using a 0° hard nasal endoscope (diameter, 2.7 mm; Karl Storz, Tuttlingen, Germany) (Fig. 1). In most patients, the mass was large and pushed the ipsilateral inferior turbinate to a horizontal position, which blocked the beginning of the meatus nasi communis and middle nasal meatus. At the beginning of the operation, most of the mass was removed using an electric cut-off drill with a diameter of 2 mm (Medtronic, Minneapolis, MN, USA) under nasal endoscopy (Fig. 2). The upper lacrimal punctum was then enlarged and the probe was inserted. Under nasal endoscopic vision, the probe tip was exposed through the inferior nasal meatus, the probe was withdrawn, and the lacrimal passage was washed using normal saline. After cleaning any viscous or purulent secretions from the lacrimal passage and nasal cavity, the nasal endoscope was adjusted to a diameter of 3 mm and 70º to observe the opening of the nasolacrimal duct at the fornix of the inferior meatus. Finally, the prolapsed mucosa around the opening of the nasolacrimal duct was trimmed and smoothed with an electric cutoff and suction drill (Fig. 3). The nasal cavity packing is not performed upon completion of the surgery. The efficacy of the procedure was observed during re-examinations, which involved lacrimal passage washing under nasal endoscopy at 1 week, 1 month, 6 months, and 1 year postoperatively.

In Group B, the neonate's head was fixed with the help of an assistant. The mucosal surface was anesthetized at the conjunctival sac using 0.3% oxybuprocaine. We connected the lacrimal probe size #7 to the syringe and advanced it into the upper lacrimal punctum (the inferior punctum was chosen in one patient because of punctum loss). When the probe tip touched the wall of hard bone in parallel with the gingival margin, the tail was rotated 90° and the tip was pushed in the direction of the lacrimal sac. Syringing under pressure allowed observation of viscous secretions flowing back from the punctum, confirming that the tip was located in the lacrimal sac. Advancement of the tip then continued in the direction of the inferior nasal meatus until a feeling of breakthrough was encountered. The success of probing was verified by an overflow of secretions from the front nostril or obvious swallowing during syringing. After surgery, the patients were treated with topical antibiotic eye drops. The efficacy of the procedure was assessed by re-examination involving lacrimal passage syringing at 1 week, 1 month, 6 months, and 1 year postoperatively.

Efficacy assessment criteria

Cure was defined as disappearance of the mass from the inner canthus, no nasal congestion, and no reflux during lacrimal passage syringing. Lack of cure was defined as failure to remove the mass from the inner canthus, nasal congestion, epiphora, a cyst in the inferior nasal passage, or persistence of reflux during lacrimal passage syringing.

Results

Patients had an median age was 18.5 days, and the male:female ratio was 25:15 patients (27:16 eyes). All 20 patients in Group A had achieved a cure at the 1-year follow-up (success rate of 100%). 15 infants had dacryocystitis and two had acute dacryocystitis before surgery, which was controlled with antibiotic medication (Table 1). The symptoms of a mass in the inner canthus and epiphora disappeared immediately after surgery. Nasal congestion usually disappeared 1 week after surgery because of mucosal swelling of the adjacent inferior turbinate during nasal surgery; the congestion resolved without special treatment. During the postoperative follow-up visits, mucosal adhesion between the left inferior turbinate and nasal septum was detected by nasal endoscopy in one patient. The adhesion was separated under local anesthesia, and absorbable hemostatic gauze was used for local bleeding control. The patient was clinically normal at the 1-year follow-up. No other complications occurred in the remaining neonatal patients; the incidence of complications was therefore 5%. No reoperations were required.

Eighteen patients in Group B had achieved a cure at the 1-year follow-up (success rate of 90%). All patients had unilateral cysts and 13 patients with dacryocystitis were treated by antibiotics before the operation before surgery (Table 2). Four patients developed postoperative complications. Two of them presented with nasal bleeding immediately after surgery, which was stopped after compression with ephedrine-soaked cotton. The other two patients developed edema of the inner canthus during syringing; this was considered to have been caused by false passage formation, and probing was discontinued. These two patients were treated with both antibiotic eye drops and oral antibiotics. Probing was conducted again 1 week later. The incidence of complications was 20%. Reoperation was performed in six patients. Four of them were cured during the second probing. One neonate with formation of a false lacrimal passage was cured during the third probing. The remaining patient exhibited recurrence of the mass in the inner canthus accompanied by nasal congestion at the 1-month follow-up, and reflux during lacrimal duct syringing was obvious; therefore, a second probing was performed. At the 6-month follow-up, however, synechiae had appeared in the small perforation of the transnasal cyst because of redundancy of the cyst wall, and marsupialization under nasal endoscopy was finally performed. The reoperation rate was 30%.

Discussion

A congenital dacryocystocele is a rare congenital disorder leading to obstruction of the nasolacrimal duct and acts as one of the reasons for congenital lacrimal duct obstruction. The nasolacrimal duct is derived from the ectoderm, located between the maxillary process in the middle of the face and the lateral nasofrontal process. It is formed in the first 3 months of gestation and extends to the head and tail to form a tubular structure at 6 months of gestation [5]. About 30% of newborns develop partial obstruction of the nasolacrimal duct [6]; however, 85% to 95% of lacrimal duct obstructions will reopen spontaneously at around 1 year without treatment [1]. When a congenital dacryocystocele forms, spontaneous regression of >50% of the congenital dacryocystocele occurs within 3 months, >80% in 6 months, and 95% at 1 year [7]. Approximately 76% of children can reportedly be cured after nonsurgical treatment, including lacrimal sac massage, lacrimal duct irrigation, and other conservative treatment [8,9]. However, the disease is easily complicated by dacryocystitis or periorbital cellulitis; thus, early intervention is required. In this study, a total of 28/40(70 %) patients had dacryocystitis, including 15/20(75%) patients in group A and 13/20(65%) patients in group B. We utilized an endoscopic technique in our pediatric otolaryngology department and combined it with CT, lacrimal lipiodol angiography, and nasal endoscopy, and the diagnosis rate of congenital dacryocystocele in our outpatient clinic reached 100%. Some previous studies, such as the work of Roy [10] and Paysse[11], had also emphasized the role of nasal endoscopy combined with CT scanning. The combination of CT and lacrimal lipiodol angiography (Fig. 4) takes the safety of the examination into consideration and can accurately display the three main pathological and imaging features of the disease [12]: various degrees of unilateral or bilateral nasolacrimal duct expansion, a cyst in the inner canthus, and an inner cyst in the inferior nasal meatus [13]. If the clinical findings cannot be confirmed, CT can be used to achieve a diagnosis of lacrimal cysts by excluding brain encephalocele, sweat gland cysts, dermoid cysts, and other lacrimal system abnormalities [14-16]. If CT suggests meningeal encephalocele, further confirmation by magnetic resonance imaging is required. Pink cystic masses can be directly observed by nasal endoscopy. The lower turbinate is usually pushed horizontally; if secondary infection occurs, it can rapidly develop into acute dacryocystitis and periorbital cellulitis [17]. Previous reports have described confirmation of the diagnosis by ultrasound [18] or magnetic resonance imaging [19]. Prenatal ultrasound can detect this disease early [20].

The marsupialization under nasal endoscopy is performed under endoscopic vision, placement of the syringing device under nasal endoscopic vision eliminates the risk of formation of the false lacrimal passage that usually occurs during blind probing and reduces the incidence of postoperative infection.

Due to complete removal of the cyst from the inferior nasal passage, a wide nasolacrimal duct opening is formed on the affected side; this greatly reduces the probability of surgical failure caused by postoperative synechiae. The opening of the lacrimal duct reduces the pressure in the lacrimal duct system, the occluded valve of Rosenmuller opens naturally, the lacrimal sac decompresses, the cyst in the inner canthus regresses spontaneously, and key physiological functions are preserved. Therefore, this procedure can be considered a functional operation of great clinical significance. Postoperative mucosal

hemorrhage can be treated under nasal endoscopy. The cyst itself does not usually have a rich blood supply, and precise cutting with the electric cutting-off drill does not damage adjacent structures; thus, little intraoperative bleeding occurs. Avoidance of nasal filling after surgery is beneficial to the postoperative care of newborns and small infants and meets the postoperative care requirements for nasal surgery in children. In the present study, no postoperative complications of nasal bleeding occurred in Group A. In contrast, when Lacrimal probing is performed blindly, it depends on the operator's personal experience and skills. The technique causes great damage to the lacrimal system mucosa, causes a new scar to form after surgery, and results in local stenosis, which will lead to secondary lacrimal stenosis. These problems are why multiple probing procedures are performed to cure congenital dacryocystoceles. During the follow-up in Group B, we found that the probing failure that had occurred in one patient was caused by a decrease in the diameter of the probe opening during the second probing, even resulting in atresia after surgery. The possible reason for this is that due to the high pressure in the lacrimal system preoperatively, the membranous nasolacrimal duct prolapses to form a large cyst in the inferior nasal passage. After penetration, the pressure in the lacrimal duct is reduced, but the small penetrated opening does not allow for adequate drainage. If the cysts are not removed, stimulation by inflammatory secretions and the inflammatory response of the postoperative mucosa eventually lead to re-atresia of the opening. Although no definite conclusion has been reached regarding the size of the cyst opening compared with the narrow opening after penetration, the spacious drainage opening after marsupialization under nasal endoscopy has obvious advantages with respect to preventing postoperative re-occlusion. Collaboration between rhinologists and ophthalmologists is indispensable when performing marsupialization under nasal endoscopy to ensure efficacy and reduce complications.

Conclusions

In present study, the efficacy and safety of marsupialization under nasal endoscopy was significantly better than those of traditional Lacrimal probing. This procedure has great advantages over blind probing including a small area of injury, the need for few lacrimal duct flushes, and avoidance of unnecessary damage caused by probing and syringing of the mucosa of the entire lacrimal system.On the other hand, because this study is limited by the sample size, a more accurate conclusion needs to be demonstrated by a large sample of multi-center research.

Abbreviations

CT computed tomography

Declarations

Ethics approval and consent to participate

This retrospective case series was approved by the ethics committee at Beijing Children's Hospital and conducted in accordance with the principles of the Helsinki Declaration, and informed consent was

obtained from all parents of the patients before surgical treatment.

Consent for publication

Not applicable

Availability of data and material

The datasets used and/or analyzed during the current study are available from the corresponding author on reasonable request.

Competing interests

The authors declare that there is no conflict of interest.

Funding

This research was supported by the National Natural Science Foundation of China (No. 81570891), the National Natural Science Foundation of China (No. 81272981), the Beijing Natural Science Foundation (No. 7151003), and the Advanced Health Care Professionals Development Project of Beijing Municipal Health Bureau (No. 2014-2-003).

Authors' contributions

Dr. Cui carried out part of the marsupialization under nasal endoscopy and Lacrimal probing surgery and drafted this manuscript. Dr. Sun and Dr. Tang carried out part of the marsupialization under nasal endoscopy surgery. Dr. Zhang participated in the design of the study and performed the data analysis. Dr. Wu carried out part of Lacrimal probing surgery and revised the manuscript. Dr. Yu and Dr. Li participated in experimental design and coordination and helped to draft the manuscript. Dr. Wei designed this study and guided the surgery and data collection. All authors read and approved the final manuscript for submission.

Acknowledgements

Not applicable

References

[1] Shashy RG,Durairaj VD,Holmes JM,et al. Congenital dacryocystocele associated with intranasal cysts: diagnosis and management[J].Laryngoscope,2003,113(1) : 37-40.

[2] Becker BB. The treatment of congenital dacryocystocele[J]. Am J Ophthalmol,2006,142(5) : 835-838.

[3] Mansour AM,Cheng KP,Mumma JV,et al. Congenital dacryocele:

a collaborative review [J]. Ophthalmology, 1991, 98 (11) :1744-1751.

[4] Dogan E,Yüksel NG,Ecevit MC,et al. Microdebrider assisted

endoscopic marsupialization of congenital intranasal nasolacrimal duct cysts. Int J Pediatr Otorhinolaryngol, 2012, 76(4) : 488-491.

[5] Shashy RG, Durairaj V, Holmes JM, et al. Congenital dacryocystocele associated with intranasal cysts: Diagnosis and management. *Laryngoscope*. 2003; 113:37–40 .

[6]Yohendran J,Wignall AC,Beckenham EJ. Bilateral congenital

dacryocystocoeles with concurrent intranasal mucocoeles causing respiratory distress in a neonate[J]. Asian J Surg,2006,29 (2) :109-111.

[7] Kakizaki H, Takahashi Y, Kinoshita S, et al.The rate of symptomatic improvement of congenital nasolacrimal duct obstruction in Japanese infants treated with conservative management during the 1st year of age. Clin Ophthalmol .2008;2(2):291–294

[8] Lueder GT. The association of neonatal dacryocystoceles and infantile dacryocystitis with nasolacrimal duct cysts (An american ophthalmological society thesis). *Trans Am Ophthalmol Soc.* 2012; 110: 74–93

[9]Davies R, Watkins WJ, Kotecha S, Watts P. The presentation, clinical features, complications, and treatment of congenital dacryocystocele. *Eye (Lond).* 2018 Mar;32(3):522-526.

[10]Roy et al. Endoscopic marsupialization of congenital duct cyst with dacryocoele. *Clin Otolaryngol Allied Sci.* 2002 Jun;27(3):167-70

[11]Paysse EA. Management and complications of congenital dacryocele with concurrent intranasal mucocele. J AAPOS. 2000 Feb;4(1):46-53

[12]CY Zhang,YU Gang,WU Qian. Computed tomography dacryocystography of congenital nasolacrimal duct obstruction and preliminary study of nasolacrimal canal measurement. Ophthalmology in China. 2011, 20(5) : 307-310.

[13]Rand PK,Ball WS Jr,Kulwin DR. Congenital nasolacrimal mucoceles: CT evaluation[J]. Radiology. 1989,173(3) : 691-694.

[14] Rosen WJ, Li Y. Sudoriferous cyst of the orbit. *Ophthal Plast Reconstr Surg.*

2001;17(1):73–75.

[15] Robertson DM, Henderson JW. Unilateral proptosis secondary to orbital mucocele in infancy. *Am J Ophthalmol.* 1969;68(5):845–847.

[16] Hurwitz JJ, Rodgers J, Doucet TW. Dermoid tumor involving the lacrimal drainage pathway: a case report.. *Ophthalmic Surg.* 1982;13(5):377–379.

[17]Yi Zhang,Yu Fan,Jinlu Fan,et al. Selection of surgical intervention for congenital dacryocystocele [J]. European Journal of Ophthalmology. 2018,00(0) : 1-7.

[18] Cavazza S,Laffi GL,Lodi L,et al. Congenital dacryocystocele: diagnosis and treatment[J]. Acta Otorhinolaryngol Ital,2008,28(6) : 298-301.

[19] Leonard DS,O'Keefe M,Rowley H,et al. Neonatal respiratory distress secondary to bilateral intranasal dacryocystocoeles[J]. Int JPediatr Otorhinolaryngol. 2008, 72(12) : 1873-1877.

[20] RK Wong,DK Vanderveen. Presentation and Management of Congenital Dacryocystocele. Pediatrics 2008;122: e1108–e1112

Tables

Table 1. Data of marsupialization under nasal endoscopy in Group A

Patient ID	Unilateral/Bilateral	Complication	Reoperation
1	U	N	N
2	B	mucosal adhesion between the left inferior turbinate and nasal septum	N
3	U	N	N
4	U	N	N
5	U	N	N
6	U	N	N
7	B	N	N
8	U	N	N
9	U	N	N
10	U	N	N
11	U	N	N
12	B	N	N
13	U	N	N
14	U	N	N
15	U	N	N
16	U	N	N
17	U	N	N
18	U	N	N
19	U	N	N
20	U	N	N

Table 2. Data of lacrimal passage probing in Group B

Patient ID	Unilateral/Bilateral	Complication	Reoperation
1	U	N	N
2	U	nasal bleeding	second probing
3	U	N	N
4	U	N	N
5	U	N	N
6	U	N	N
7	U	N	N
8	U	nasal bleeding	second probing
9	U	N	marsupialization under nasal endoscopy
10	U	N	N
11	U	N	second probing
12	U	N	N
13	U	false passage formation	third probing
14	U	N	N
15	U	N	N
16	U	false passage formation	second probing
17	U	N	N
18	U	N	N
19	U	N	N
20	U	N	N

Figures

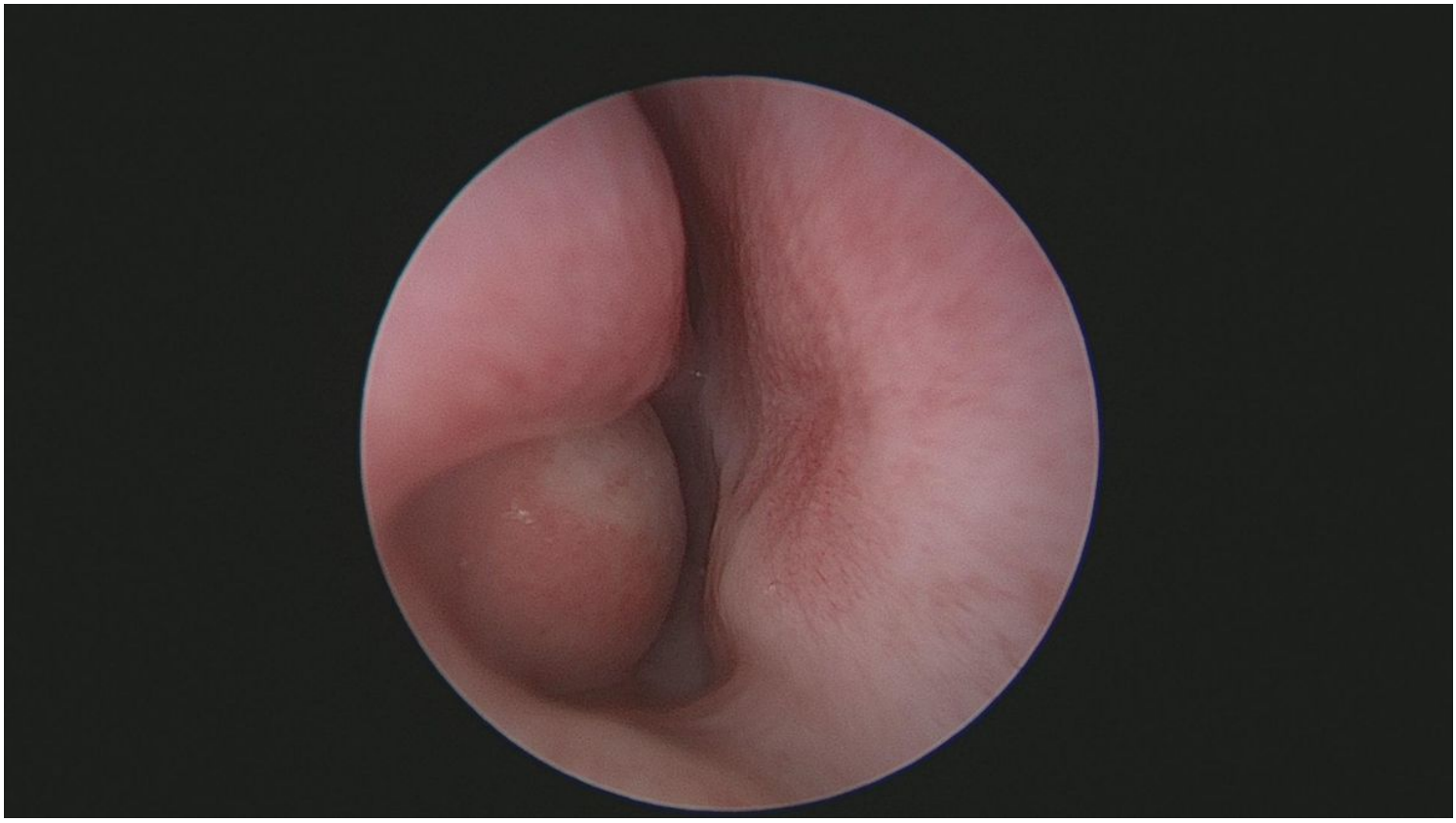

Figure 1

Cysts in the inferior nasal passages. IT: inferior turbinate; SP: nasal septum; Cys: cysts that prolapsed into the inferior nasal passages.

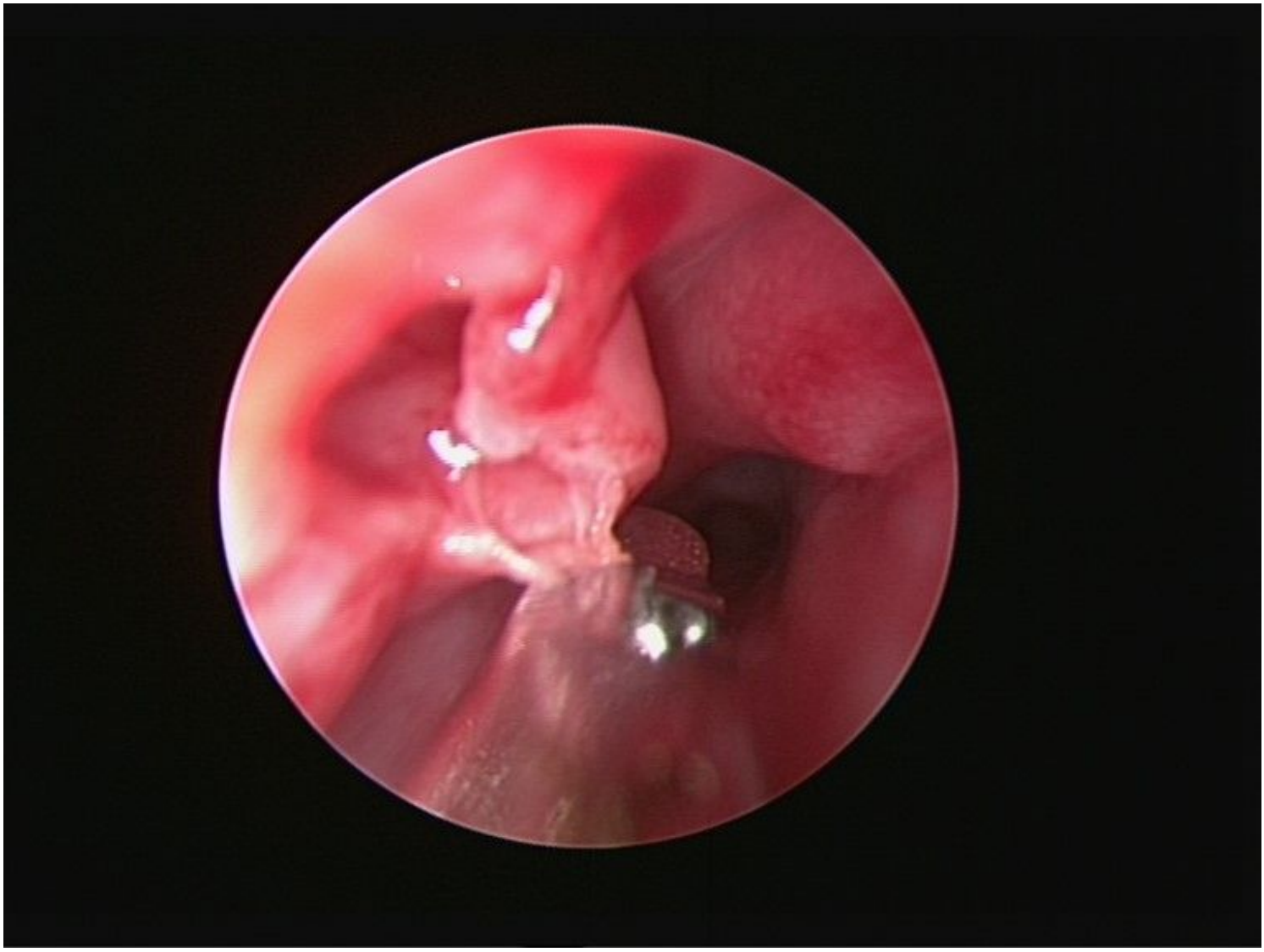

Figure 2

Cyst removal using the electric cut-off drill. IT: inferior turbinate; SP: nasal septum.

Figure 3

Opening of the nasolacrimal duct after cystectomy under a 70° endoscope.

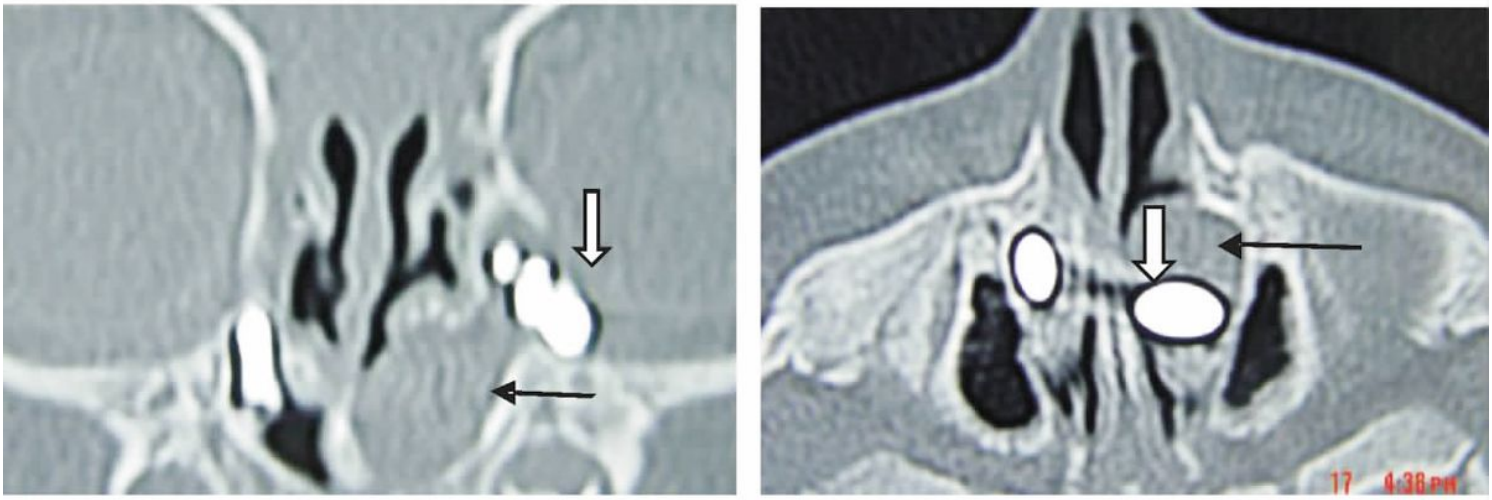

Figure 4

Lacrimal lipiodol angiography clearly shows that iodized oil remains in the upper segment of the dilated nasolacrimal duct (down arrow), and the lower nasal cyst is compressing the affected inferior turbinate (→) in the coronal and axial positions