Venogenic Erectile Dysfunction: Diagnosis on Computed Tomography Cavernosography and Endovascular Treatment Using An Anterograde Access via Deep Dorsal Penile Vein

Hanno Hoppe (hanno.hoppe@gmail.com)
University of Bern: Universitat Bern https://orcid.org/0000-0001-5673-0035

Nicolas Diehm
University of Bern: Universitat Bern

Research Article

Keywords: Erectile dysfunction, impotence, venous leak, embolization

Posted Date: November 16th, 2021

DOI: https://doi.org/10.21203/rs.3.rs-1048273/v1

Version of Record: A version of this preprint was published at CVIR Endovascular on February 3rd, 2022. See the published version at https://doi.org/10.1186/s42155-022-00283-5.

Abstract

Background

The underlying etiologies of erectile dysfunction may be manifold. Among them, vasculogenic etiologies are of increasing relevance and are not strictly limited to the elderly population. According to recent study, venogenic erectile dysfunction appears to be even more relevant than arteriogenic erectile dysfunction. Venogenic erectile dysfunction due to venous leakage causes insufficient penile blood retention. Proper diagnosis of venous leakage should include both color Doppler flow analysis and computed tomography cavernosography for adequate patient selection and treatment planning. Besides surgical ligation of penile draining veins, endovascular treatment methods may demonstrate more promising results. Especially endovascular embolization of venous leakage using an anterograde access via deep dorsal penile veins appears to be more beneficial for patients' clinical outcome and awareness of this technique should be raised among endovascular interventionalists.

Case presentation

A 47-year-old man was diagnosed with venogenic erectile dysfunction due to venous leakage on color Doppler flow analysis and computed tomography cavernosography. He did not respond to PDE-5-inhibitors. This patient demonstrated major venous leakage of paired deep dorsal penile veins via periprostatic veins and internal pudendal veins draining into both iliohypogastric veins. This patient's venous leak was treated with endovascular embolization using an anterograde access via deep dorsal penile veins.

Conclusion

In patients with erectile dysfunction due to venous leakage embolization using an anterograde access via deep dorsal penile veins is a safe non-invasive endovascular treatment option. A wider use of this technique may contribute not only to improved patient health but also to homogenization of future study results.

Background

Definition of erectile dysfunction is the recurring inability to achieve and maintain an erection for satisfactory sexual intercourse, which may result in relevant life impairment. Erectile dysfunction may be caused by various etiologies such as vasculogenic, endocrinologic, neurogenic, iatrogenic, psychogenic or rarely structural components. Not only in the elderly population, especially vasculogenic etiologies are increasingly relevant. Among them the incidence seems to be even higher for venogenic causes than for arteriogenic causes (1). Venogenic erectile dysfunction is due to insufficient penile blood retention during erection caused by venous leakage. For treatment of venous leakage surgical ligation of deep dorsal

veins including potential collateral veins has been performed. However, surgical treatment is rather invasive and usually takes place in an operation room under general anesthesia. Not very encouraging, long-term success rates of surgical ligation are reported to be merely 25% (2). Endovascular therapies with embolization of leaking veins have been reported including both retrograde and anterograde approaches with and without previous surgical exposure of deep dorsal penile veins. However, the authors are confident that an anterograde approach with ultrasound-guided puncture of a deep dorsal penile vein is more beneficial for the patient in terms of clinical outcome. Therefore, we aim to describe and illustrate this technique to encourage other interventionalists to adapt to this technique. Furthermore, we intend to emphasize the need for pre-interventional work-up, especially computed tomography cavernosography, for adequate patient selection and treatment planning.

Case Presentation

Diagnosis

A 47-year-old man was diagnosed with erectile dysfunction due to venous leakage following an urological intervention not further specified 20 years ago. Patient especially complains about insufficient penile rigidity and early penile relaxation during sexual activity. Furthermore, he is a non-responder to PDE-5-inhibitors. Patient was assessed with an International Index of Erectile Function Questionnaire (IIEF-15) score of 43 indicating moderate erectile dysfunction.

Color Doppler Flow Analysis

For patient work-up, venous color Doppler flow analysis was performed using direct pharmacological stimulation with an intra-cavernosal injection of 10 µg prostaglandin E1 resulting in penile tumescence grade E3 (considered not sufficient for sexual intercourse). At 15 minutes post injection (rigid phase), a high systolic flow rate of 50 cm/s (peak systolic velocity; normal <25 cm/s) and a persistent end-diastolic velocity of 11 cm/s (normal <5 cm/s) was found compatible with venous leakage. Arterial color Doppler flow analysis was without pathological findings.

Computed Tomography Cavernosography

For confirmation of diagnosis and anatomical depiction of venous leaks computed tomography cavernosography was performed post intra-cavernosal injection of 10 µg prostaglandin E1 resulting in penile tumescence grade E3. Fifteen minutes post injection a 23-G needle was inserted at the dorso-lateral side of the corpora cavernosum. Graduated injection of normal saline into corpora cavernosum at increasing flow rates up to a flow rate of 0.6 ml/s resulted in penile tumescence grade E4. Subsequently injection of 30 ml 50% saline-diluted non-ionic iodinated contrast medium (300 mg ml^{-1}) with an infusion velocity of 0.6. ml/s was performed. Computed tomography parameters were as follows: 64 × 0.625 mm collimation, gantry rotation time 0.75 s, time resolution 30 ms, pitch factor 0.984. Continuous scanning was performed under real time monitoring of contrast distribution up to the iliohypogastric veins extending from the upper brim of the true pelvis to the most distant level of the penis. The data

constructive section thickness was 1 mm with a reconstruction increment of 1 mm for post-processing. For post-processing, multiplanar reformation using maximum intensity projection and volume rendering was applied. This patient demonstrated major venous leakage of paired deep dorsal penile veins via periprostatic veins and internal pudendal veins draining into both iliohypogastric veins (**Figure 1**). Furthermore, a more peripheral minor venous leak was found with drainage to superficial inferior epigastric veins (**Figure 2**).

Endovascular Treatment

The treatment strategy for this patient was embolization of major penile venous leakage. The procedure was performed in an angiosuite. The patient was prepared and draped in the supine position. Following local subcutaneous administration of lidocaine 2%, an ultrasound-guide puncture of a penile deep dorsal vein was performed using a stiff 20-G micropuncture set with a 0.018-inch guide wire and 4-French introducer (Cook Inc., Bloomington, Indiana, U.S.A.). The stiff set appears to be advantageous compared to a regular floppier micropuncture set. The introducer was carefully advanced and positioned in close proximity to the radix penis and a diagnostic venogram was acquired confirming venous leakage via periprostatic veins and bilateral internal pudendal veins draining into both iliohypogastric veins (**Figure 3**). Subsequently, all materials were flushed using 5% glucose solution to preserve catheter patency and prevent its inadvertent adhesion to the vessel wall. Afterwards venous embolization was performed with a slow but steady injection using N-butyl-2-cyanoacrylate (Histoacryl, Braun, Melsungen, Germany) and ethiodized oil (Lipiodol by Guerbet, Zurich, Switzerland) mixed in a 1:3 ratio under Valsalva maneuver and continuous fluoroscopic monitoring (**Figure 4**). The injection was terminated in time prior to inadvertent distribution of embolization material to the iliohypogastric veins. The total amount of N-butyl cyanoacrylate used in this case was 3 ml. Periinterventional sedation, antiphlogistic and pain medication were administered. The more peripheral minor venous leak draining into superficial inferior epigastric veins was not treated at the time. Whenever necessary, these veins would rather qualify for percutaneous venous sclerotherapy than for embolization since reflux of embolization material into deep dorsal penile veins should be avoided since it may cause phlebitis.

Clinical Outcome

On 4-week follow-up this patient’s erectile dysfunction had resolved and his erectile function was back to normal without additional need for supportive vasoactive medications. Long-term follow-up is pending.

Discussion And Conclusion

In patients with erectile dysfunction due to venous leakage embolization is a safe non-invasive endovascular treatment option. Technical success rates are reported to be as high as 97% and complications rates are low (5%), including mainly minor complications whereas major complications such as pulmonary embolism are very rare (<1%) (1). As reported in the literature, the average overall clinical success rate is 60% (range 22-100%) including various techniques and both partial and full responses (1, 3–6). For full response, meaning sufficient erection to perform intercourse without

additional need for supportive vasoactive medications, success rates rather tend to be within the lower range of the spectrum so far (7, 8). However, small patient collectives on the one hand as well as inhomogeneous study protocols and various embolization techniques on the other hand may impede study reproducibility. Furthermore, long-term results are still pending. In conclusion, increasing future use of computed tomography cavernosography for adequate patient selection and anterograde embolization techniques among endovascular interventionalists may contribute to ameliorated study results and improved patient health.

List Of Abbreviations

PDE - Phosphodiesterase

IIEF - International Index of Erectile Function

Declarations

Acknowledgements

The authors acknowledge Dr. Heinz Schönhofen from Radiology Center Baden in Switzerland for excellent implementation of computed tomography cavernosography with high-quality diagnostic images.

Funding

None.

Author information

Affiliations

Hanno Hoppe[1,2], Nicolas Diehm[2,3]

1 - SwissIntervention Microtherapy Center, Bern, Switzerland

2 - University of Bern, Switzerland

3 - Vascular Institute Central Switzerland, Aarau, Switzerland

Contributions

HH: Concept of manuscript, outline of topics, and scientific writing

ND: Outline of topics, manuscript drafting

Corresponding author

Prof. Dr. med. Hanno Hoppe, SwissIntervention Microtherapy Center, Kornhausstrasse 8, 3013 Bern, Switzerland (hanno.hoppe@gmail.com)

Ethics declarations

Ethics approval and patient consent are available.

Competing interests

The authors declare that they have no competing interests.

References

1. Doppalapudi SK, Wajswol E, Shukla PA, Kolber MK, Singh MK, Kumar A et al (2019) Endovascular Therapy for Vasculogenic Erectile Dysfunction: A Systematic Review and Meta-Analysis of Arterial and Venous Therapies. J Vasc Interv Radiol 30(8):1251–8e2
2. Katzenwadel A, Popken G, Wetterauer U (1993) Penile venous surgery for cavernosal venous leakage: long-term results and retrospective studies. Urol Int 50(2):71–76
3. Fernandez Arjona M, Oteros R, Zarca M, Diaz Fernandez J, Cortes I (2001) Percutaneous embolization for erectile dysfunction due to venous leakage: prognostic factors for a good therapeutic result. Eur Urol 39(1):15–19
4. Rebonato A, Auci A, Sanguinetti F, Maiettini D, Rossi M, Brunese L et al (2014) Embolization of the periprostatic venous plexus for erectile dysfunction resulting from venous leakage. J Vasc Interv Radiol 25(6):866–872
5. Peskircioglu L, Tekin I, Boyvat F, Karabulut A, Ozkardes H (2000) Embolization of the deep dorsal vein for the treatment of erectile impotence due to veno-occlusive dysfunction. J Urol 163(2):472–5
6. Schild HH, Müller SC, Mildenberger P, Strunk H, Kaltenborn H, Kersjes W et al (1993) Percutaneous penile venoablation for treatment of impotence. Cardiovasc Interv Radiol 16(5):280–6
7. Bookstein JJ, Lurie AL (1988) Transluminal penile venoablation for impotence: a progress report. Cardiovasc Intervent Radiol 11(4):253–260
8. Kutlu R, Soylu A (2009) Deep dorsal vein embolization with N-butyl-2-cyanoacrylate and lipiodol mixture in venogenic erectile dysfunction: Early and late results. Radiol Oncol 43(1):17–25

Figures

Figure 1

Computed tomography cavernosography (axial maximum intensity projection) in a 47-year-old man with erectile dysfunction. Color Doppler flow analysis demonstrated a high systolic flow rate of 50 cm/s and a persistent end-diastolic velocity of 11 cm/s (quod vide complementary movie file). Contrast enhanced computed tomography cavernosography demonstrating major venous leakage from deep dorsal penile veins via bilateral periprostatic veins (arrows) draining into internal pudendal veins and bilateral

iliohypogastric veins. Of interest, paired deep dorsal penile veins were found (arrowheads). Besides there is minor venous leakage originating more peripherally via inferior epigastric veins.

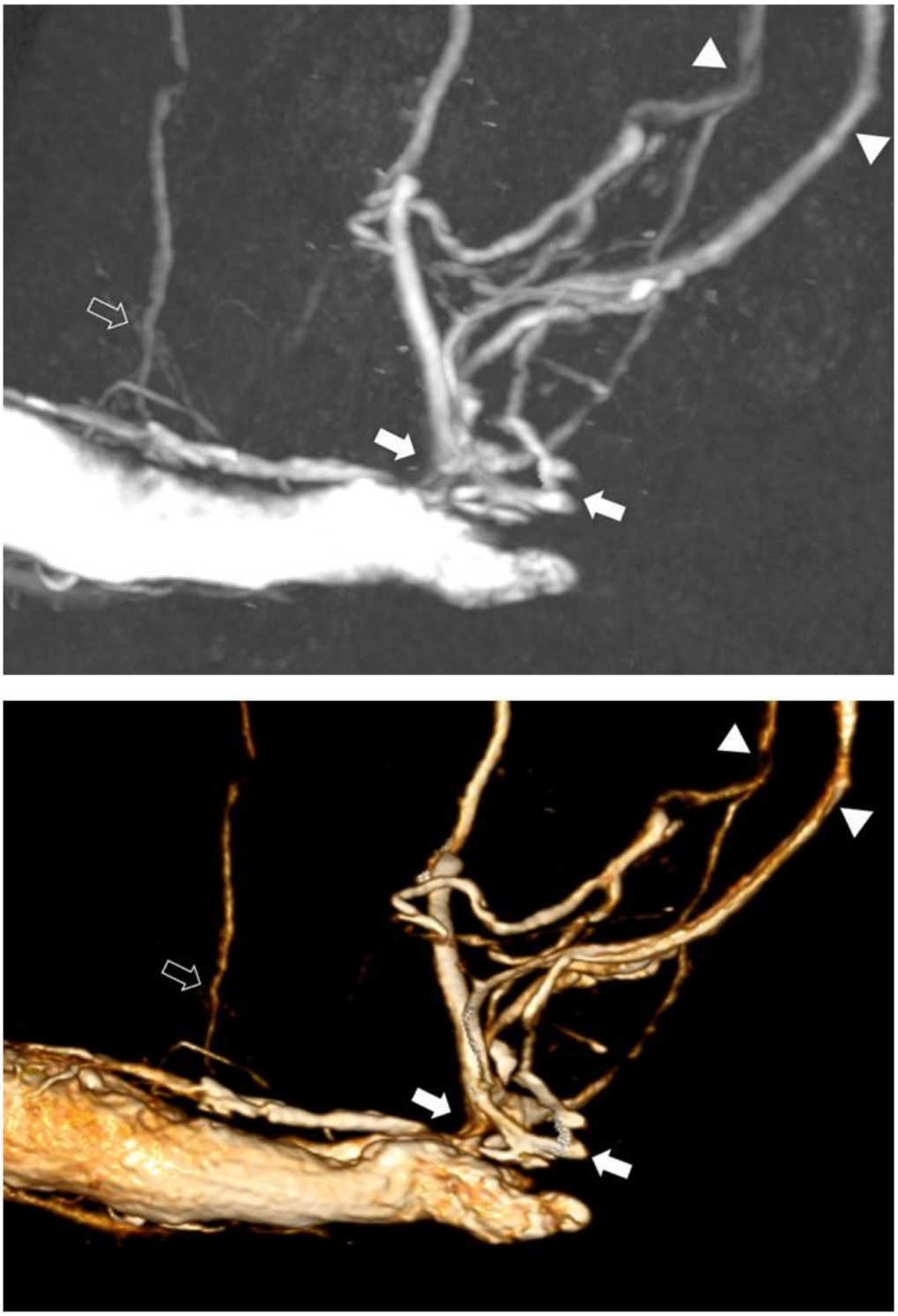

Figure 2

Computed tomography cavernosography on a) three-dimensional maximum intensity projection and b) three-dimensional volume rendering in a 47-year-old man with erectile dysfunction (quod vide complementary movie files). Contrast enhanced computed tomography cavernosography demonstrating

major venous leakage from deep dorsal penile veins via periprostatic veins (arrows) draining into internal pudendal veins and bilateral iliohypogastric veins (arrowheads). Besides there is minor venous leakage originating more peripherally via superficial inferior epigastric veins (open arrow).

Figure 3

Venogram (digital subtraction angiography) in a 47-year-old man with venogenic erectile dysfunction confirming the diagnosis of venous leakage as previously suspected on color Doppler flow analysis and depicted in computed tomography cavernosography (quod vide complementary movie file). Venogram post anterograde access via deep dorsal penile vein confirming venous leakage via bilateral periprostatic veins (arrows) and internal pudendal veins draining into iliohypogastric veins (arrowheads).

Figure 4

Embolization of venous leak in a 47-year-old man with venogenic erectile dysfunction (quod vide complementary movie file). Radiographic image post venous leakage embolization using N-butyl-2-cyanoacrylate and ethiodized oil mixed in a 1:3 ratio. Note radiopaque embolization material within periprostatic veins (arrows) and internal pudendal vein (open arrow). There is residual contrast staining of both iliohypogastric veins post venogram (asterisk), not to be mistaken for embolization material.

Complementary movie file demonstrating venous embolization performed with a slow but steady injection of embolization material under Valsalva maneuver and continuous fluoroscopic monitoring.

Supplementary Files

This is a list of supplementary files associated with this preprint. Click to download.

- Figure1mov.mp4
- Figure2amov.mp4
- Figure2bmov.mp4
- Figure3mov.mp4
- Figure4mov.mp4