Assessment of anterior chamber configuration changes after phacoemulsification with swept-source optical coherence tomography

Man Hu
Wenzhou Medical University School of Optometry and Ophthalmology
Qian Zheng
Wenzhou Medical University School of Optometry and Ophthalmology
Zhangliang Li
Wenzhou Medical University School of Optometry and Ophthalmology
Pingjun Chang
Wenzhou Medical University School of Optometry and Ophthalmology
Yun-e Zhao (zyehzeye@126.com)
Wenzhou Medical University School of Optometry and Ophthalmology https://orcid.org/0000-0002-4535-318X

Research article

Keywords: anterior chamber parameters, phacoemulsification, shallow anterior chamber, normal anterior chamber, anterior segment swept-source optical coherence tomography

Posted Date: January 8th, 2020

DOI: https://doi.org/10.21203/rs.2.9863/v2

Abstract

Background: To assess the changes of anterior chamber angle in patients with shallow anterior chamber and normal anterior chamber after phacoemulsification and intraocular lens implantation (IOL) using anterior segment swept-source optical coherence tomography (AS-SS-OCT). Methods: This was a prospective case control study; 60 eyes of 60 patients who scheduled for cataract surgery with normal intraocular pressure (IOP). Based on anterior chamber depth (ACD) and gonioscopy findings, the eyes were classified into two groups: shallow anterior chamber group with narrow angle (SAC group, 30 eyes) and normal anterior chamber group with wide angle (NAC group, 30 eyes). Measurements of ACD, anterior chamber volume (ACV), Iris volume (IV), lens vault (LV) , angle opening distance (AOD), angle recess area (ARA), trabecular iris space area (TISA), and trabecular iris angle (TIA) were conducted in each group before and 3 months after surgery. Differences between the two groups were compared. Results: There was no significant difference in age, axial length (AL), corneal curvature, corneal diameter, IOP and IV between the SAC group and the NAC group before operation, except for the LV ($p = 0.000$). All angle parameters including ACD, ACV, AOD, ARA, TISA and TIA in both groups at 3 months post-surgery were significantly different from the preoperative values ($p<0.01$). In addition, there were significant differences in all angle parameters between two groups before and after operation (All $P< 0.05$). Besides, the TISA750 in superior quadrant, ACD and ACV were significantly smaller in the group of SAC than those in the group of NAC 3 months after operation ($P = 0.041$, 0.001 and 0.002, respectively). Conclusions: Cataract surgery can deepen anterior chamber and increase the width of anterior chamber angle in Chinese subjects, but the ACD and ACV in patients with shallow anterior chamber and narrow angle have not reached the normal level, presumably because the iris root of SAC group inserted more anteriorly than that of NAC group. Phacoemulsification may not completely eliminate the risk of glaucoma in NAC group of people after surgery.

Introduction

In 2016, a multicenter randomized controlled trial by Azuara et al. found that the eyes after clear-lens extraction had higher mean health status score and lower intraocular pressure than eyes after laser peripheral iridotomy (LPI), with a difference of 0.052 and 1.18 mmHg, repsetively. Clear-lens extraction showed greater efficacy and was more cost-effective than LPI, and should be considered as an option for first-line treatment of the primary angle-closure glaucoma [1]. Previous studies confirmed that cataract surgery with intraocular lens implantation (IOL) can deepen the anterior chamber and widen the anterior chamber angles [2-7]. The effect of cataract surgery on intraocular pressure (IOP) in glaucoma patients has been described in numerous studies in different subtypes of glaucoma. Husain et al. reported that there were significantly more failures of IOP control at 2 years in the LPI group (7/18 [38.9%]) compared with the phaco/IOL group (2/19 [10.5%]) [8]. Lam et al. found that prevalence of IOP rise for the LPI group (46.7%) was significantly higher than phacoemulsification group for the follow-up at 18 months. Mean IOP for phacoemulsification group (12.6±1.9mmHg) was consistently lower than that of the LPI group (15.0±3.4mmHg) [8, 9]. Cataract surgery may have improved anterior chamber angle parameters and

decreased IOP in normal-tension glaucoma patients [10]. Lens extraction may be an option for a subset of patients with primary angle closure disease [2, 8,9,11].

Although the anterior chamber did deepen and the anterior chamber angle was widen after cataract surgery, whether the anterior chamber angle opening and anterior chamber depth (ACD), anterior chamber volume (ACV) in patients with shallow anterior chamber and narrow angle after surgery can reach the normal level remains to be studied.

Chinese individuals are at a high risk for angle closure. The 10-year cumulative incidence of any forms of primary angle closure（PAC）was 20.5% in an urban Chinese population aged 50 years and older. Small ocular dimensions and hyperopia at baseline were associated with the development of angle closure [12].

The purpose of the current study was to evaluate the effects of cataract surgery on anterior segment structure and angle parameters in Chinese subjects by using anterior segment swept-source optical coherence tomography (AS-SS-OCT) technique. By comparing the anterior chamber angle parameters of shallow anterior chamber narrow angle with normal anterior chamber wide angle before and 3 months after operation, to investigate the changes of anterior chamber depth and angle-related parameters after surgery. We hope to obtain more strong evidence from AS-SS-OCT to confirm whether there are any other factors affecting the anterior chamber angle structure other than lens.

Methods

In this prospective study, we enrolled consecutive patients who were scheduled for cataract surgery at a tertiary referral center in Southeast China from September, 2013 to May, 2014. The study was approved by the institutional review board and complied with the tenets of the Declaration of Helsinki. Informed consent was obtained from each patient.

Each patient received a comprehensive eye examination, including visual acuity, manifest refraction, slit-lamp evaluation, noncontact tonometry (TX-F; Cannon, Tokyo, Japan), gonioscopy, fundus examination, and AS-SS-OCT scanning. Shallow anterior chamber was defined as: ACD≤2.68 measured by the AS-SS-OCT [13] and angle≤Shaffer 2 in four quadrants under gonioscope [14].

Inclusion criteria were age-related cataract patients with normal IOP who were scheduled for elective phacoemulsification and intraocular lens implantationincluding patients of shallow anterior chamber with narrow angle and wide anterior chamber with wide angle. In the patients who received surgery in both eyes, only the data of the right eyes were analyzed. Images with good quality from preoperative and 3-month postoperatively examinations were analyzed.

Exclusion criteria included diagnosed primary angle closure with evidence of previous acute episode, established peripheral anterior synechias, established primary angle-closure glaucoma with glaucomatous damage of the optic nerve and visual field defects, ocular comorbidity other than cataract (e g, primary open angle glaucoma, normal tension glaucoma, uveitis, history of ocular surgery or injury),

pterygium influencing AS-SS-OCT scanning and intraoperative or postoperative complications (e g, posterior capsule tear, zonular dialysis, IOL tilting, subluxation or dislocation, post-operative elevated IOP, prolonged postoperative inflammation).

Based on the ACD and gonioscopy findings, patients were divided into two groups: Normal anterior chamber with wide angle group (NAC group) and shallow anterior chamber with narrow angle group (SAC group), including patients with close angle but normal IOP.

Anterior Chamber Measurement

AS-SS-OCT (SS-1000 CASIA; Tomey CO. Ltd, Nagoya, Japan) was performed preoperatively and 3 months postoperatively. For each patient each time, 3 consecutive examinations were done by a same skilled professional inspector without pupil dilation. The preoperative and postoperative examinations were performed under the same lighting conditions (300lux). To avoid lid artifact, participants were instructed to pull down the lower lid against the lower orbital rim to expose the lower limbus while the technician elevated the upper lid against the upper orbital rim to expose the upper limbus [15]. Two researchers confirmed that the images with the best exposure were analyzed.

ACD, anterior chamber volume (ACV) and angle opening distance 750[μm] (AOD750), anterior recess area at 750[μm^2] (ARA750), trabecular iris space area 750[μm^2] (TISA750), trabecular iris angle 750 [deg] (TIA750), iris volume (IV) and lens vault (LV) were measured and compared between the two groups. .

AOD750 was defined as the perpendicular distance measured from the trabecular meshwork at 750μm anterior to the scleral spur to the anterior iris surface [16]. ARA750 was the area bordered by the anterior surface of the iris, corneal endothelium and a line perpendicular to the corneal endothelium drawn from a point 750μm anterior to scleral spur to the iris surface [17]. TISA750 was an area bounded anteriorly by the AOD, posteriorly by a line drawn from the scleral spur perpendicular to the plane of the inner scleral wall to the opposing iris, superiorly by the inner corneoscleral wall, and inferiorly by the iris surface [16].TIA 750 was calculated as an angle measured with the apex in the iris recess and the arms of the angle passing through a point on the trabecular meshwork 750μm from the scleral spur and the point on the iris perpendicularly opposite [18]. LV was the anterior pole of the cataractous lens or IOL to the center of the line joining the two iridocorneal angles. IV and ACV were computed and calculated automatically, after the instrument software detected the anterior and posterior boundaries of the iris and cornea in the individual B-scans[15] (Figure 1).

Statistical Analysis

Statistical analysis was performed using SPSS version 21.0 (SPSS Inc, Chicago, Illinois, USA). Kolmogorov-Smirnov test was used to check the normal distribution of variables, which indicated several parameters of non-normal distributions and recommended non-parametric statistical analysis. Values were expressed as mean±SD or median (quartile range). One-way ANOVA test or Mann-Whitney U test was employed to compare parameters between two groups, depending on the normality of variables The

sample size was calculated using PASS software (version 11.0, NCSS, LLC) and determined to be 30 eyes (a = 0.05; power = 0.90). A P value less than 0.05 was considered statistically significant.

Results

A total of 60 eyes of 60 patients were recruited in our study. Table 1 showed the demographic characteristics. There were no significant differences of age, axial length (AL), corneal curvature, cornea diameter, IOP and IV between groups of SAC and NAC (P>0.05). Only lens vault (LV) of the two groups has significant different (p=0.000).

Table 1. Demographic characteristics.

	SAC	NAC	P
N. of eyes	30	30	
N. of patients	30	30	
Gender (Male/Female)	15/15	6/24	
Age (y)	63.6±10.8	68.4±8.4	0.107
AL (mm)	23.28±0.70	22.87±0.89	0.080
Corneal curvature (D)	7.35±0.03	7.33±0.03	0.076
Cornea diameter（mm）	11.62±0.05	11.60±0.06	0.501
IOP (mmHg)	10.2(8.7, 14.3)	11.9(9.5,14.6)	0.158
IV(mm^3)	35.51±4.31	36.41±4.81	0.393
LV(mm)	0.91±0.24	0.50±0.29	0.000

SAC = Shallow Anterior Chamber, NAC = Normal Anterior Chamber;

Preoperative Anterior Segment Comparison

All the anterior segment parameters, including AOD750, ARA750, TISA750, TIA, ACD, and ACV, showed significant differences between groups of SAC and NAC before surgery(All P<0.005)(Figure 2 & Figure 3). ACV in groups of SAC and NAC before surgery were 91.24(84.23, 109.57) and 145.11(115.62, 159.06)

(Figure 3). However, LV of SAC group was significantly larger than NAC group (0.91±0.24mm and 0.50±0.29mm, p=0.000) .There was no significant difference in IV between SAC group and NAC group.

Postoperative Anterior Segment Comparison

We found significant differences of ACD, ACV, AOD750, ARA750, TISA750, and TIA in nasal and inferior quadrants, and TISA750 in superior quadrant between groups of SAC and NAC (All P< 0.05). Besides, ACD was significantly smaller in the group of SAC than that in the group of NAC 3 months after operation (3.74±0.67 and 3.91±0.26, p=0.002). ACV was significantly smaller in the group of SAC than that in the group of NAC 3 months after operation (161.37±19.47 and 178.26±20.30, p=0.002) (Figure3, Figure 4).

Discussion

As in previous cross-sectional studies confirmed, greater lens thickness, shallower ACD, narrower angle width and more hyperopic spherical equivalent at baseline were predictors for the development of angle closure [19]. Cataract surgery can deepen the anterior chamber and increase the width of anterior chamber angle [18, 20-23]. Hoy et al. study showed phacoemulsification led to anterior chamber deepening and lower IOP in eyes with occludable angles compares to eyes with open angles, which suggests it is an option for preventing acute angle–closure attacks [24]. Kasai's team also confirmed that cataract surgery increases ACD and all angle parameters early after the surgery. However, the degree of angle widening in narrow-angle eyes was not as much as that in open-angle eyes, suggesting that factors other than the lens influence the angle closure [25]. But there were several limitations and defects in the gonioscopy, ultrasound biomicroscopy (UBM) and even AS-OCT which they used to examine the anterior chamber. To the best of our knowledge, there is no comparative study on the fine structure of anterior chamber angle using anterior segment swept-source optical coherence tomography (AS-SS-OCT) before and after cataract surgery in Chinese subjects.

Further studies have been carried out to explore the changes of the angle structure of the anterior chamber after phacoemulsification by AS-OCT [1-12].It has the advantage of allowing faster cross-sectional imaging of the anterior chamber than UBM and does not require contact with the globe. However, AS-OCT can only detect the horizontal angle information, and cannot fully represent the 360-degree anterior chamber angle and the changes of the three-dimensional space of the anterior chamber. AS-SS-OCT was verified to be suitable for assessment of angle and angle-related parameters by some authors [15, 26-28]. With a substantial improvement in scan speed (30,000 A-scans per second), the anterior chamber angles can be imaged in 128 cross-sections (each with 512 A-scans) 360° around the anterior segment in 2.4 seconds [26]. Therefore, through the AS-SS-OCT examination, we can understand the anterior chamber and anterior chamber angles more comprehensively than previous studies.

In our study, cataract patients were divided into two groups by ACD and anterior chamber angle: shallow anterior chamber with narrow angle and normal anterior chamber with wide angle. The results obtained are basically consistent with previous studies. What is different from other studies is that our analysis

showed that there were differences in ACD、ACV and angle openness between the two groups postoperatively, especially the angle structure of some quadrants and the postoperative ACV in the shallow anterior chamber group were still relatively small 3 months after surgery. In recent years, only one research report has obtained similar results, but its application is the AS-OCT technology, and it only evaluates the anterior chamber angle parameters one day after operation. There is no long-term observation after operation [25].

Our results showed that there was no significant difference in the preoperative axial length, corneal curvature and corneal diameter between the two groups. It is speculated that the reason why ACD and ACV in the shallow anterior chamber narrow angle group could not recover to the NAC group after operation may be related to the anterior insertion point of the iris. The position of the iris anterior insertion point may not reach the same state as the normal group after operation be due to involve embryologic and anatomic factors. Meanwhile, whether there is ciliary body abnormalities remains to be further investigated.

There are some limitations in this study. Firstly, as AS-SS-OCT could not measure the ciliary body as UBM or gonioscopy does, the data of ciliary body structure could not be obtained. Secondly, this study did not take into account the factor of intraocular pressure, and whithout pupil diameter measurement. In addition, we didn't confirm whether the anterior insertion point of the iris was different between two groups via gonioscopy. Future investigation of these factors will be necessary.

Conclusions

In this study, AS-SS-OCT was used to quantitatively evaluate the changes of anterior chamber morphology before and after cataract surgery in SAC and NAC groups. We proved that cataract surgery can deepen anterior chamber and increase the width of anterior chamber angle in Chinese subjects, but the ACD and ACV in patients with shallow anterior chamber and narrow angle have not reached the normal level, presumably because the iris root of SAC group inserted more anteriorly than that of NAC group. This needs to be proved by further study. Therefore, cataract surgery may not completely eliminate the risk of glaucoma in this group of people after surgery, it still needs close observation.

List Of Abbreviations

IOL: intraocular lens implantation; **AS-SS-OCT**: anterior segment swept-source optical coherence tomography; **ACD**: anterior chamber depth; **AOD**: angle opening distance; **ARA**: angle recess area; **TISA**: trabecular iris space area; **TIA**: trabecular iris angle; **IOP**: intraocular pressure; **PACG**: primary angle-closure glaucoma; **UBM**: ultrasound biomicroscopy; **AS-OCT**: anterior segment optical coherence tomography; **AOD500**: angle opening distance at 500[μm]; **TISA500**: trabecular-iris space at 500μm; **PAC**: primary angle closure; **ACV**: anterior chamber volume; **AOD750**: angle opening distance at 750[μm]; **ARA750**: anterior recess area at 750[μm^2] ; **TISA750**: trabecular iris space area 750[μm^2]; **TIA750**: trabecular iris angle 750 [deg]; **IV**: iris volume ; **LV**: lens vault; **SAC**: shallow anterior chamber; **NAC**: normal anterior chamber

Declarations

Ethics approval and consent to participate: This study has been performed in accordance with the Declaration of Helsinki and was approved by the Ethics Committee of the Eye Hospital, Wen Zhou Medical University.

Consent for publication: Written informed consents were obtained from all subjects.

Availability of data and material: All data generated or analyzed during this study are included in this published article

Competing interests: The authors declare that they have no competing interests

Funding: This work was supported by Provincial construction project of Zhejiang (Grant No. 2016147538), The Innovation Discipline of Zhejiang Province (Lens disease in children).

Authors' contributions: QZ performed the AS-SS-OCT examination, CPJ and ZLL analyzed and interpreted the patient data. MH was a major contributor in writing the manuscript. YEZ made substantial contributions to the conception design of the work and reviewed the manuscript. All authors read and approved the final manuscript.

Acknowledgements: Not applicable.

References

[1] Azuara-Blanco A, Burr J, Ramsay C, et al. Effectiveness of early lens extraction for the treatment of primary angle-closure glaucoma (EAGLE): a randomised controlled trial. Lancet. 2016. 388(10052): 1389-1397.

[2] Friedman DS, He M. Anterior chamber angle assessment techniques. Surv Ophthalmol. 2008. 53(3): 250-73.

[3] Kim M, Park KH, Kim TW, Kim DM. Anterior chamber configuration changes after cataract surgery in eyes with glaucoma. Korean J Ophthalmol. 2012. 26(2): 97-103.

[4] Hayashi K, Hayashi H, Nakao F, Hayashi F. Changes in anterior chamber angle width and depth after intraocular lens implantation in eyes with glaucoma. Ophthalmology. 2000. 107(4): 698-703.

[5] Altan C, Bayraktar S, Altan T, Eren H, Yilmaz OF. Anterior chamber depth, iridocorneal angle width, and intraocular pressure changes after uneventful phacoemulsification in eyes without glucoma and with open iridocorneal angles. J Cataract Refract Surg. 2004. 30(4): 832-8.

[6] Nolan WP, See JL, Aung T, et al. Changes in angle configuration after phacoemulsification measured by anterior segment optical coherence tomography. J Glaucoma. 2008. 17(6): 455-9.

[7] Kucumen RB, Yenerel NM, Gorgun E, Kulacoglu DN, Dinc UA, Alimgil ML. Anterior segment optical coherence tomography measurement of anterior chamber depth and angle changes after phacoemulsification and intraocular lens implantation. J Cataract Refract Surg. 2008. 34(10): 1694-8.

[8] Lam DS, Leung DY, Tham CC, et al. Randomized trial of early phacoemulsification versus peripheral iridotomy to prevent intraocular pressure rise after acute primary angle closure. Ophthalmology. 2008. 115(7): 1134-40.

[9] Husain R, Gazzard G, Aung T, et al. Initial management of acute primary angle closure: a randomized trial comparing phacoemulsification with laser peripheral iridotomy. Ophthalmology. 2012. 119(11): 2274-81.

[10] Lee W Bae HW KCY, Seong GJ. The change of anterior segment parameters after cataract surgery in normal-tension glaucoma. Int J Ophthalmol. 2017. 10(8): 1239-1245.

[11] The Role of Phacoemulsification in Glaucoma Therapy A Systematic Review and Meta-analysis .

[12] Wang L, Huang W, Huang S, et al. Ten-year incidence of primary angle closure in elderly Chinese: the Liwan Eye Study. Br J Ophthalmol. 2018 .

[13] Nongpiur ME, Haaland BA, Friedman DS, et al. Classification algorithms based on anterior segment optical coherence tomography measurements for detection of angle closure. Ophthalmology. 2013. 120(1): 48-54.

[14] SHAFFER RN. Operating room gonioscopy in angle-closure glaucoma surgery. AMA Arch Ophthalmol. 1958. 59(4): 532-5.

[15] Mak H, Xu G, Leung CK. Imaging the iris with swept-source optical coherence tomography: relationship between iris volume and primary angle closure. Ophthalmology. 2013. 120(12): 2517-2524.

[16] Narayanaswamy A, Sakata LM, He MG, et al. Diagnostic performance of anterior chamber angle measurements for detecting eyes with narrow angles: an anterior segment OCT study. Arch Ophthalmol. 2010. 128(10): 1321-7.

[17] Esaki K, Ishikawa H, Liebmann JM, Greenfield DS, Uji Y, Ritch R. Angle recess area decreases with age in normal Japanese. Jpn J Ophthalmol. 2000. 44(1): 46-51.

[18] Pavlin CJ, Harasiewicz K, Foster FS. Ultrasound biomicroscopy of anterior segment structures in normal and glaucomatous eyes. Am J Ophthalmol. 1992. 113(4): 381-9.

[19] George R, Paul PG, Baskaran M, et al. Ocular biometry in occludable angles and angle closure glaucoma: a population based survey. Br J Ophthalmol. 2003. 87(4): 399-402.

[20] Nonaka A, Kondo T, Kikuchi M, et al. Angle widening and alteration of ciliary process configuration after cataract surgery for primary angle closure. Ophthalmology. 2006. 113(3): 437-41.

[21] Nonaka A, Kondo T, Kikuchi M, et al. Cataract surgery for residual angle closure after peripheral laser iridotomy. Ophthalmology. 2005. 112(6): 974-9.

[22] Memarzadeh F, Tang M, Li Y, Chopra V, Francis BA, Huang D. Optical coherence tomography assessment of angle anatomy changes after cataract surgery. Am J Ophthalmol. 2007. 144(3): 464-5.

[23] Pereira FA, Cronemberger S. Ultrasound biomicroscopic study of anterior segment changes after phacoemulsification and foldable intraocular lens implantation. Ophthalmology. 2003. 110(9): 1799-806.

[24] Shin HC, Subrayan V, Tajunisah I. Changes in anterior chamber depth and intraocular pressure after phacoemulsification in eyes with occludable angles. J Cataract Refract Surg. 2010. 36(8): 1289-95.

[25] Kasai K, Takahashi G, Kumegawa K, Dogru M. Measurement of early changes in anterior chamber morphology after cataract extraction measured by anterior segment optical coherence tomography. Graefes Arch Clin Exp Ophthalmol. 2015. 253(10): 1751-6.

[26] Liu S, Yu M, Ye C, Lam DS, Leung CK. Anterior chamber angle imaging with swept-source optical coherence tomography: an investigation on variability of angle measurement. Invest Ophthalmol Vis Sci. 2011. 52(12): 8598-603.

[27] Lai I, Mak H, Lai G, Yu M, Lam DS, Leung CK. Anterior chamber angle imaging with swept-source optical coherence tomography: measuring peripheral anterior synechia in glaucoma. Ophthalmology. 2013. 120(6): 1144-9.

[28] Assessment of Circumferential Angle-Closure by the IriseTrabecular Contact Index with Swept-Source Optical Coherence Tomography .

Figures

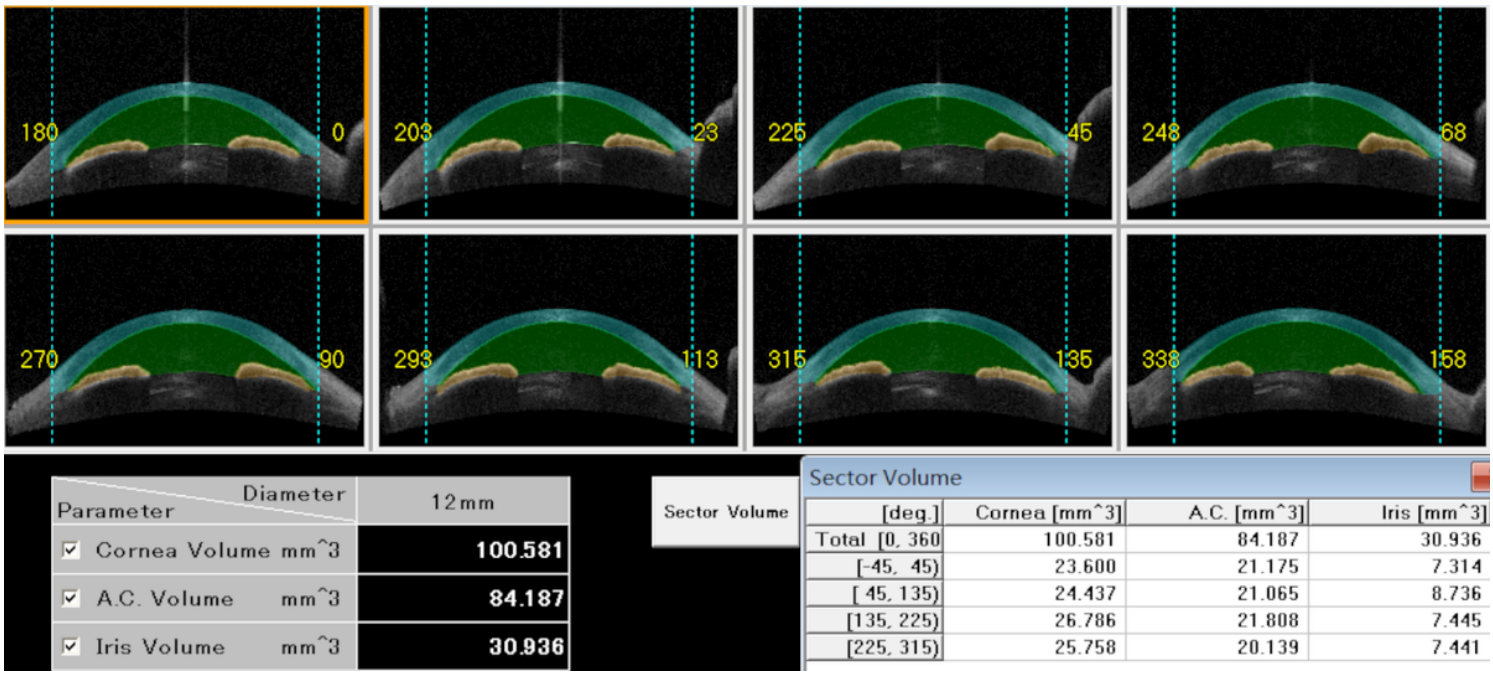

Figure 1

The images of angle meridians from 180° and 0° to 333° and 158° were shown. The cornea, iris and anterior chamber volume (denoted in light green, yellow and dark green respectively) of total (360-degree) and four quadrants were calculated.

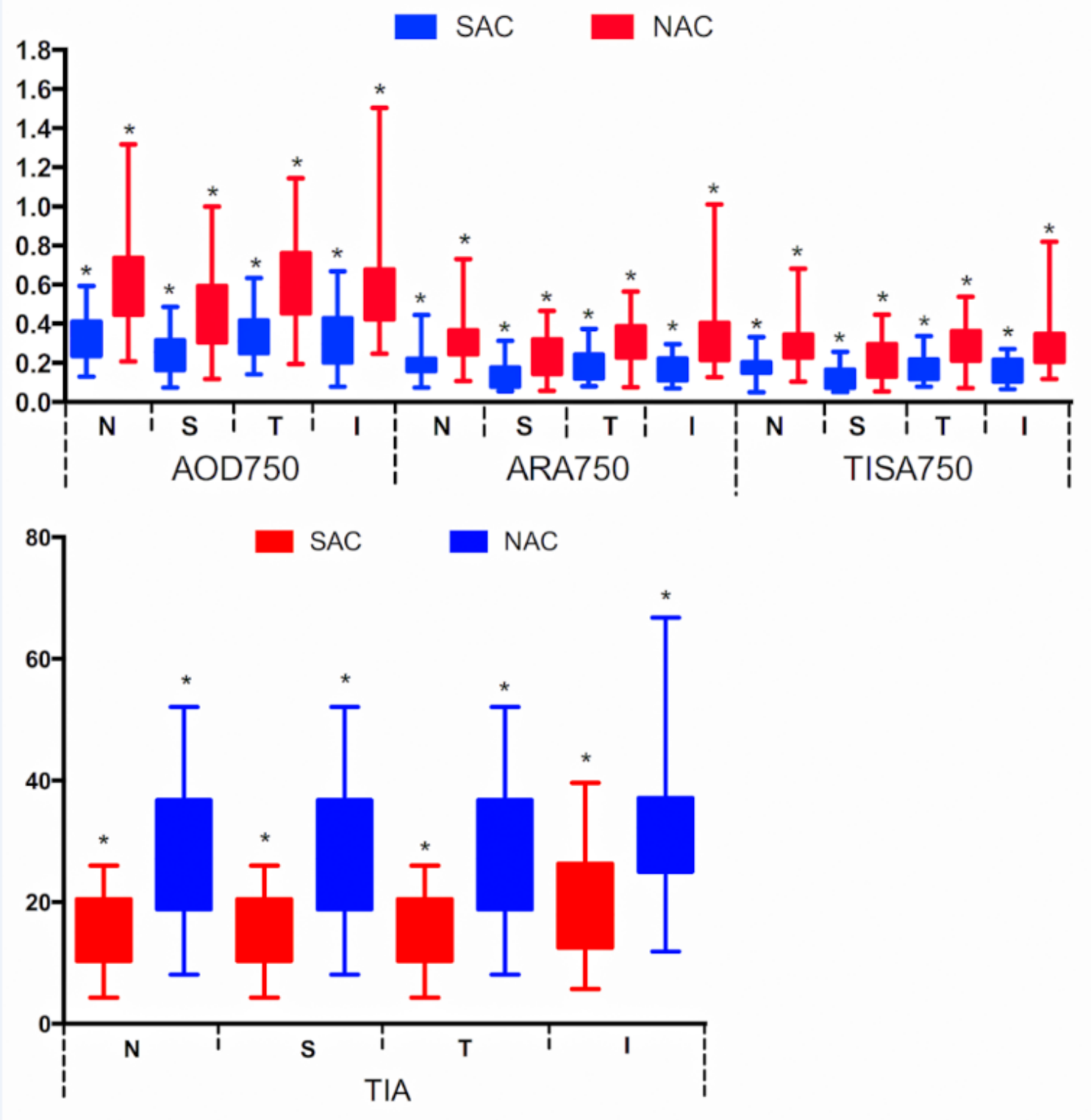

Figure 2

All the anterior segment parameters, including AOD750, ARA750, TISA750, TIA showed significant differences between groups of SAC and NAC before surgery(All P<0.005)

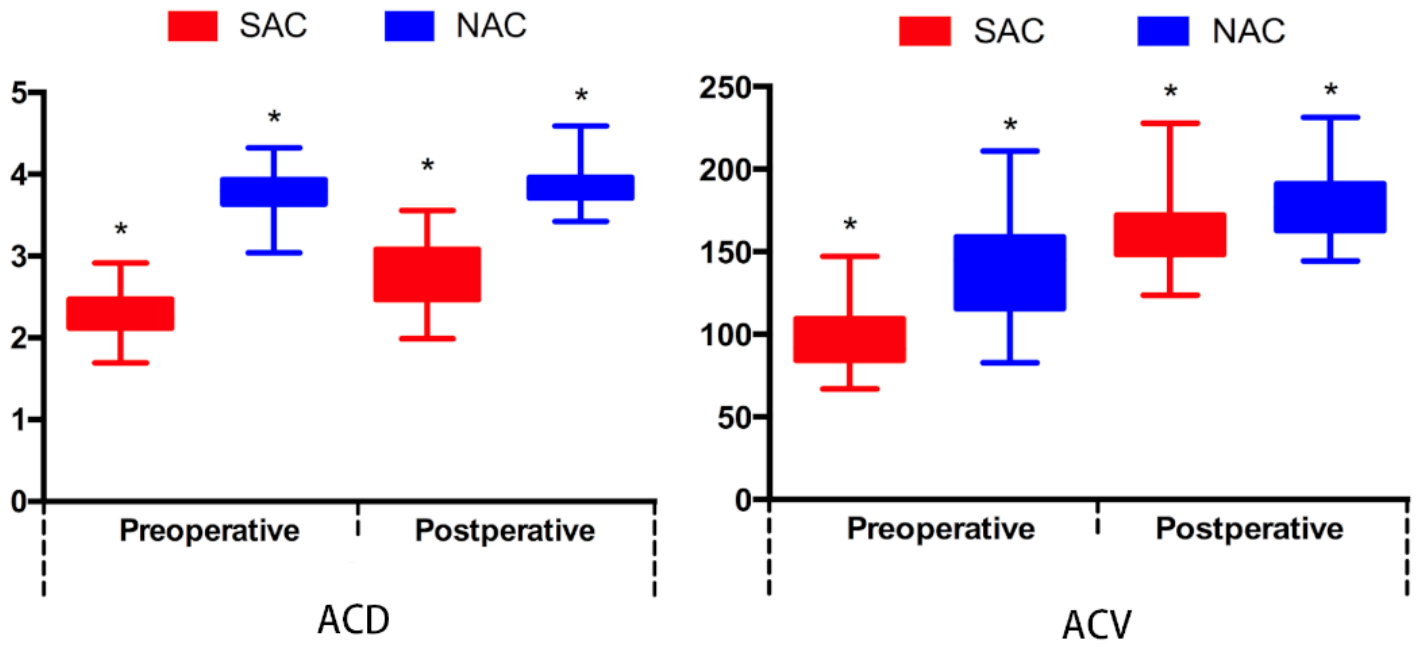

Figure 3

a. ACD of SAC and NAC groups before surgery were 2.25±0.28 and 2.88±0.42. At 3 months after operation, ACD of SAC and NAC groups were 3.74±0.67 and 3.91±0.26. ACD was significantly smaller in the group of SAC than in the NAC (p=0.001). b. ACV of SAC and NAC groups before surgery were 91.24(84.23,109.57) and 145.11(115.62,159.06)At 3 months after operation, ACV of SAC and NAC groups were 161.37±19.47 and 178.26±20.30. ACV was significantly smaller in the group of SAC than in the NAC (p=0.002).

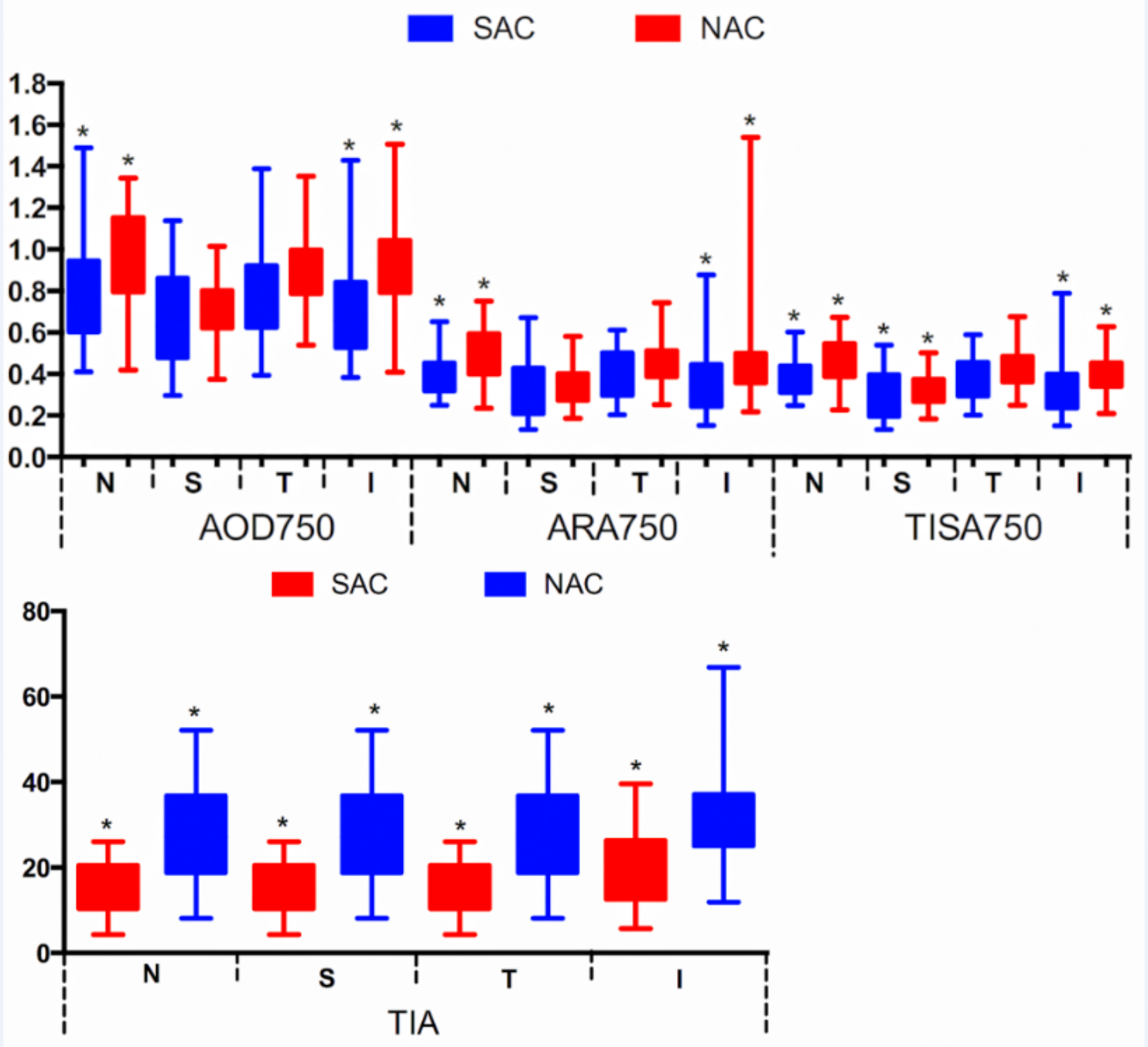

Figure 4

There were significant differences of AOD750, ARA750, TISA750, and TIA in nasal and inferior quadrants, between groups of SAC and NAC (All P< 0.05). Besides, the TISA750 in superior quadrant were significantly smaller in the group of SAC than those in the group of NAC (P = 0.041).