Is conservative treatment really the best option for all thoracolumbar injury patients with a thoracolumbar injury classification and severity scale score<4?

Yang Xu
Fujian Provincial Hospital

Zhiyuan Zeng
Quanzhou First Hospital

Fubiao Ye (yfb283@163.com)
Fujian Provincial Hospital

Feiyue Lin
Fujian Provincial Hospital

Chuncai Xu
Fujian Provincial Hospital

Jianghu Huang
Fujian Provincial

Xi Lin
Fujian Provincial Hospital

Research article

Keywords: thoracolumbar injury classification and severity scale, throacolumbar burst fractures, neurologically intact, spine kyphosis

Posted Date: January 3rd, 2020

DOI: https://doi.org/10.21203/rs.2.19920/v1

Abstract

Objectives: The conservative treatment recommendation for patients with thoracolumbar burst fractures with a TLICS score<4 has always been controversial. This retrospective review was conducted to investigate the reliability and validity of thoracolumbar injury classification and severity scale(TLICS) recommendations for thoracolumbar burst fracture patients with a score<4.

Methods: A retrospective analysis was conducted from Jan. 2010 through Jun. 2018 for patients with thoracolumbar fractures in a single local institute; patients with a TLICS score <4 were enrolled and grouped according to the therapeutic strategy (surgical or nonsurgical). Imaging and clinical data were collected and compared between the two groups before and after treatment.

Results: In total, 119 patients were enrolled (75 in the nonsurgical group and 44 in the surgical group). There was no significant difference between the two groups with regard to both the VAS and ODI values ($p = 0.91$ and 0.79, respectively) at the last follow-up. Importantly, despite no improvements in the local sagittal angle (LSA, α) of the spine($p = 0.09$),a worsened regional sagittal angle (RSA, β) ($p = 0.03$)was observed in the nonsurgical group, while significant improvements in the LSA and RAS were both observed in the surgical group($p < 0.01$).

Conclusions: There were no clinical quantifiable benefits (VAS pain and ODI scores) between nonsurgical and surgical patients with comminuted thoracolumbar fractures (TLICS score<4). However, this type of patient deserves a very careful preoperative evaluation if a nonoperative decision is made; a close follow-up is mandatory due to the high likelihood of long-term kyphotic deformities.

Background

Thoracolumbar burst fractures (T11-L2) account for approximately 17% of all spinal fractures;[1]the treatment of these types of fractures, especially in patients who are neurologically intact, has always been controversial.[2–4]Surgical treatment aims to restore the stability of the spine as well as decompression as early as possible; however, these patients face substantial problems following surgery, including operative trauma, blood loss, infection and high health care costs. On the other hand, some have suggested that nonsurgical treatment may be an acceptable alternative in properly selected patients. Ordinary scoring systems, such as the thoracolumbar injury classification and severity scale(TLICS),[5] the load-sharing classification[6] or the AO-Magerl classification,[7] have been used as a basis for making treatment decisions, while there is currently no consistent treatment guideline for this set of patients. As one of these classifications, the TLICS is becoming popular because of its practicability and feasibility. However, problems with its validity and reliability have been continuously noted after years of clinical practice.

The TLICS was proposed by Vaccaro et al. in 2005[5] as a special treatment guideline for thoracolumbar spinal fractures. The TLICS is based on three basic aspects of spinal injuries: injury morphology, the integrity of the posterior ligamentous complex (PLC), and neurological status. Accordingly, patients with a total score of ≤ 3 are considered candidates for conservative treatment, and those with a total score of ≥ 5 are considered candidates for surgical treatment. Patients with a total score of 4 may be treated with either operative or nonoperative methods. Despite a great deal of evidence provided by studies that have demonstrated that the

TLICS score largely matches the treatment selection, the limitations of the TLICS score have been gradually recognized and have remained under considerable debate.[8, 9] Particularly, for the conservative treatment recommendation in patients with a TLICS score < 4, a variety of problems, including progressive kyphosis and persistent pain, have been reported by researchers. Furthermore, some scholars have questioned the long-term effects of conservative treatment for these types of patients.[10, 11]

To further elucidate this problem, a retrospective review was conducted from Jan. 2010 through Jun. 2018 for patients with thoracolumbar burst fractures and a TLICS score < 4 in a local hospital. X-ray, CT, and MRI data at the time of injury and at the last follow-up were collected and extracted in all patients who met the inclusion criteria. After treatment, the improvement rate of spinal kyphosis, represented by the local sagittal angle (LSA, α) and regional sagittal angle (RSA, β) in both groups, was extracted for subsequent studies, such as the assessment of a pain relief index (the Visual Analogue Scale) and of improvements in functional disability (the Oswestry Disability Index).

Materials And Methods

Inclusion and exclusion criteria

Following approval by the institutional review board, a retrospective chart review of prospectively collected data was conducted. The inclusion criteria for this study were as follows: 1) T11-L2 single-level burst fracture; TLICS score <4 points; 2) adult patients (aged 18-65) without severe internal diseases, such as severe hypertension, diabetes and heart disease; and 3) no injury of other important organs. The exclusion criteria included a follow-up of less than 6months and incomplete or inadequate radiograph data unavailable for complete analysis.

Data extraction and measured parameters

Most of the initial treatment decisions for patients were made based on the AO classification, as it has been historically used at this institution by most of the treating surgeons. Demographic parameters obtained from patients' electronic medical records included patient age, sex, diagnosis, treatment, surgical procedure, and time of hospitalization. Digitally archived posterior-anterior (PA) and lateral radiographs were collected and analyzed from three time points: admission/preoperative and final follow-up appointments. Using available radiographic studies, injuries were classified by two reviewers (FBY, YX) according to the TLICS system. As described in the study by Knight et al.[12], sagittal plane kyphosis of the spine was measured. Specifically, local sagittal angles (LSAs, α) and regional sagittal angles (RSAs, β) were measured using lateral film as available in the local hospital. Kyphotic angulation was indicated with a minus sign and lordotic angulation with a plus sign. The LSA was the angle made by the upper and lower endplate of the fractured vertebra. The RSA was measured by the angle made by the upper endplate of the vertebra superior to the fractured vertebra and the lower endplate of the vertebra inferior to the fractured vertebra (Figure 1). Since this was a retrospective study, clinical evaluations regarding pain VAS scores and ODI values of patients were only obtained at the final follow-up appointment, which involved patients returning for visits as outpatients or telephone follow-ups.

Statistical analysis

The tests were performed using SPSS 19.0.1 for Windows (SPSS Inc., Chicago,IL). Statistical evaluation included the use of the Mann-Whitney, unpaired *t* test to compare the distributions in the two treatment groups with regard to kyphosis angle and correction as well as pain and functional outcomes. The level of significance was set at $p < 0.05$.

Results

A total of 439 patients were initially identified and evaluated; of these, 320 were excluded according to the exclusion criteria(Supplemental Table). A total of 119 patients were enrolled in the present study: 75 patients (41 males and 34 females) in the conservative group with an average age of 40.6±9.8 (range, 18~63) years old and 44 (25 males and 19 females) in the surgical group with an average age of 44.5±8.8 (range, 30 ~ 65) years old. Among them, 39 patients(33%) had high-fall injuries, 41 patients(34%) had traffic accidents, 15 patients(13%) had stumbles, and 24 patients(20%) had other injuries. The average TLICS score of the two groups at admission was 1.8±0.6 in the conservative group and 1.9±0.4 in the surgical group. As a result, there was no significant difference in either age (p=0.59) or TLICS score (p>0.5) between the two groups of patients. The mean hospitalization time was 9.8±4.5 days in the conservative group and 13.2±5.9 days in the surgical group (p>0.5). In addition, the mean follow-up period of the conservative group was 25.2±11.1 months, and it was 38±20.8 months in the surgical group (Table 1).

At the last follow-up, the VAS pain score was 2.6±1.8 in the conservative treatment group and 2.4±1.5 in the surgical group, and no significant difference was observed between the two groups of patients (p=0.91). The ODI value was 32.4±21.8 in the conservative group of patients and 32.9±19 in the surgical group of patients. Similarly, there was no significant difference between the two groups (p=0.79) (Table 2).

With regard to the improvement in kyphotic deformity, which was represented by the LSA and RSA, from the time of injury to the last follow-up, no significant improvement was observed in the conservative group of patients in terms of the LSA (p=0.09), while the kyphotic angulation of the RSA was deteriorated in these patients (p=-0.03). In the surgical group, both theLSA and RSA at the last follow-up were significantly improved compared with the preoperation values (p<0.01) (Table 3).

A typical patient who underwent nonsurgical treatment is shown in Figure 2. In a 62-year-old woman with an L1 burst fracture and without neurological damage who was treated nonoperatively, X-ray, CT and MRI scans of the lumbar spine demonstrated an L1burst fracture with approximately 20%height loss, and the posterior ligamentous complex could not be determined. By applying the TLICS classification, the patient was found to have a total score of 3, as follows: injury morphology/compression fracture (1 point) + PLC/indeterminate (2 point) + neurological status/intact (0 point). Following the recommendation of the TLICS, the patient was treated conservatively. However, at the 2-month follow-up, the repeated lateral X-ray and CT scans demonstrated that the height loss of L1 had increased to approximately 80% and that there was remarkable protrusion of the posterior bony fragment toward the spinal canal. Even worse, at this point, the patient presented with increased low back pain and mild intermittent claudication. Figure3 shows another typical patient with an L2 burst fracture and a total TLICS score of 2: injury morphology/burst fracture (2 point) + PLC/intact (0 point) + neurological status/intact (0 point), with the treatment of posterior three-level pedicle screw instrumentation. The height of L2 was restored, and the kyphotic deformity was remarkably reduced

after surgery. At 2 years postoperatively, the pain and dysfunction experienced by the patient had disappeared; the pedicle screw instrumentation was removed, and the alignment of the spine was optimally maintained.

Discussion

Thoracolumbar burst fractures without neurological symptoms are frequently seen in the clinic, and the ideal treatment of these fractures is still controversial, especially in patients with TLICS scores < 4.[10, 13]As an attempt to develop a grading system with prognostic significance that could also be used as an algorithm to guide the clinical decision of operative or nonoperative treatment, the TLICS system has been extensively investigated in terms of its reliability and validity since its introduction in 2005. The controversy of using it for guiding treatment decisions for thoracolumbar burst fractures has been reported previously and has been increasingly questioned, especially in terms of its recommendation of conservative treatment for patients with a score < 4. [4, 14, 15] A large retrospective analysis by Joaquimet al.[16] that included a total of 458 patients showed that the recommendation matching rate of the TLICS system in the conservative group was as high as 99%; however, only 46.6% of patients matched TLICS recommendations in the surgical group, especially in the population with burst fractures but without neurological injury (TLICS score = 2); the mismatched rate was 100%. These data seem to suggest that, in those patients who had received conservative treatment based on the TLICS recommendation but in accordance with the judgment of the surgeon, more than half of them should be treated with surgical intervention. Another retrospective study conducted by Shen [17] confirmed that after evaluating 129 patients who had TLICS scores less than 4, 25 patients (up to 19.4%) who were neurologically intact still failed nonoperative treatment and ultimately required surgery. Therefore, the author suggested that the TLICS system was too conservative and that inconsistencies remained in the treatment of thoracolumbar burst fractures. A meta-analysis conducted by Gnanenthiran et al.[18] indicated that, in patients with thoracolumbar burst fractures but without neurologic deficits, despite no between-group differences in pain relief or functional disorders found in operative versus nonoperative patients, there may have been a significant improvement in residual kyphosis in operative patients compared with nonoperative patients at the last follow-up(mean of 4 years). Taken together, these results show that the efficacy of conservative treatment has been questioned for this set of patients. Specifically, patients with a total TLICS score < 4 who did not receive surgery could experience further collapse of the vertebral body with marked local kyphosis, progressive loss of vertebral body height and deterioration in pain status after long-term follow-up[19]. For instance, Mattei et al. [20] presented a case of a patient with a total TLICS score of 2 who was managed conservatively; after 12 months, the patient presented with complaints of increased back pain and a major kyphotic deformity. Ultimately, the patient was submitted to a staged anterior-posterior procedure to assure definitive fixation and adequate reconstruction of spinal alignment. The author suggested that due to the high risk of late progressive deformities, patients displaying a TLICS score of less than 4 should be considered for upfront surgical stabilization.

Consistent with most previous studies, the results of the current study showed no significant difference in the VAS pain score and ODI value between the surgical group and conservative group at the last follow-up. However, we found that no improvement in the LSA ($p = 0.09$) and an even worse RSA ($p=-0.03$)were observed in the conservative group, while significant improvements in the LSA and RSA were observed in the surgical group($p < 0.01$). Thus, compared with surgical patients, patients who received conservative treatment seemed

to have similar pain relief and functional recovery, but in general, there was no improvement or even aggravation of segmental kyphosis during the follow-up.

As previously reported in the literature, compared with previous classifications, the TLICS system has deficiencies in terms of the evaluation of the morphology and stability of fractures. For example, Oxland et al.[21] suggested that a vertebral height loss > 50% and kyphotic angulation > 20° may be indicative of instability. There is a possibility of progressive kyphotic deformity or even subsequent neurological deficits in such patients. Schnake et al.[22] recommended that patients in this subgroup(TLICS score < 4)should be assessed in combination with the AO-Magerl classification, taking into account instability indicators such as the fracture level, degree of comminution (integrity of posterior vertebral wall, upper / lower endplate) and kyphotic angulation to determine the stability of the fracture. Thus, in cases that are considered to be "unstable" burst fractures, conservative treatment should be implemented with caution, especially in patients with osteoporosis. Nevertheless, none of these instability indicators described above are taken into account in the TLICS system. Therefore, it has been suggested that it is better to combine the TLICS system with the AO spine injury classification or the load-sharing score when making treatment decisions. In particular, the modified AO-Magerl system is a helpful supplement for the TLICS system to assess the deficiencies of anterior column fractures[23]. As our typical patient mentioned in Fig. 3, with a total TLICS score < 4, conservative treatment was recommended. However, taking into account the more than 50%vertebral height loss and 22° of kyphotic angulation or an AO-Magerl classification of A3, which indicated the instability of the fracture[13], the patient was ultimately treated with surgery, resulting in a satisfactory prognosis after 2 years of follow-up. Furthermore, it has been proven that this strategy is reliable in a previous study by Wood et al.,[2]who indicated that while using both the TLICS classification and AO systems as a practical algorithm to orient the clinical decision-making between conservative and surgical management in the treatment of thoracolumbar burst fractures, the patients in the conservative treatment group had less pain and better function than the patients in the surgery group after long-term (16 ~ 22 years) follow-up. In addition, it is also worth mentioning another retrospective cohort trial conducted by Shen et al.[17], who showed that the recommendation of nonoperative treatment for patients with a TLICS score < 4 has limitations in terms of patients having greater VAS scores or IPD (interpedicular distance). If conservative treatment is implemented, a close follow-up is necessary due to the high likelihood of long-term kyphotic deformities.

Conclusions

In summary, compared with surgical patients, patients who received conservative treatment seemed to have similar levels of pain relief and functional recoveries. However, the limitations of the TLICS classification in clinical practice should be fully understood. As in such a subpopulation, even if the TLICS score is less than 4, the appropriate treatment method should be based not only on the score classification but also on the general situation of the patient and the comprehensive consideration of the stability of the fracture.

Limitation

Nevertheless, there are several limitations that should be noted in our study. First, our study is limited by its retrospective nature, although there was no evidence indicating any significant difference between the conservative group and the operative group regarding the baseline indexes, including sex, age and fracture

score, among these eligible patients. However, due to the lack of specific scoring in terms of pain and disability at the time of admission, it is not clear whether the two groups of patients were consistent with each other in regards to this aspect, which may lead to a potential bias of analysis. Second, it is also noteworthy that the average follow-up time was not long enough in the present study, which may have affected the reliability of the results. After different periods of follow-up, the same set of patients may achieve different clinical outcomes.[2]

Abbreviations

TLICS: thoracolumbar injury classification and severity scale; LSA: local sagittal angle; RSA: regional sagittal angle; VAS: visual analogue scale; ODI: oswestry disability index; IPD: interpedicular distance.

Declarations

Acknowledgments

Not applicable

Authors' contributions

FBY, ZZY and YX carried out the studies, and drafted the manuscript, XL and XCC participated in collecting the data. FYL and JHH performed statistical analysis and participated in its design. All authors read and approved the final manuscript.

Funding

This work was supported by grants from the Department of Health of Fujian Province (CN) (Grant No: 2017-ZQN-8) and high-level hospital foster grants from Fujian Prvincial Hospital, Fujian province(Grant No: 2019HSJJ02).

Availability of data and materials

The datasets used and analyzed during the current study are available from the corresponding author on reasonable request.

Ethics approval and consent to participate

The study was approved by the research ethics committee of the Fujian Provincial Hospital. The need for informed consent was waived by the committee.

Consent for publication

Not applicable

Competing interests

The authors declare that they have no competing interests

References

1. Kraemer WJ, Schemitsch EH, Lever J, et al. Functional outcome of thoracolumbar burst fractures without neurological deficit. *J Orthop Trauma* 1996;10:541-544.
2. Wood KB, Buttermann GR, Phukan R, et al. Operative compared with nonoperative treatment of a thoracolumbar burst fracture without neurological deficit: a prospective randomized study with follow-up at sixteen to twenty-two years. *J Bone Joint Surg A*, 2015;97(1):3-9.
3. Abudou M, Chen X, Kong X, et al. Surgical versus non-surgical treatment for thoracolumbar burst fractures without neurological deficit. *Cochrane Db Syst R*; 2013:D5079.
4. Shen WJ, Liu TJ, Shen YS. Nonoperative treatment versus posterior fixation for thoracolumbar junction burst fractures without neurologic deficit. *Spine (Phila Pa 1976)*, 2001;26:1038-1045.
5. Vaccaro AR, Lehman RJ, Hurlbert RJ, et al. A new classification of thoracolumbar injuries: the importance of injury morphology, the integrity of the posterior ligamentous complex, and neurologic status. *Spine (Phila Pa 1976)*, 2005;30:2325-2333.
6. McCormack T, Karaikovic E, Gaines RW. The load sharing classification of spine fractures. *Spine (Phila Pa 1976)*, 1994;19:1741-1744.
7. Magerl F, Aebi M, Gertzbein SD, et al. A comprehensive classification of thoracic and lumbar injuries. *Euro Spine J*, 1994,3:184-201.
8. Pneumaticos SG, Karampinas PK, Triantafilopoulos G, et al. Evaluation of TLICS for thoracolumbar fractures. *Euro Spine J*; 2016,25:1123-1127.
9. Joaquim AF, Ghizoni E, Tedeschi H, et al. Clinical results of patients with thoracolumbar spine trauma treated according to the Thoracolumbar Injury Classification and Severity Score. *J Neurosurg Spine*, 2014;20:562-567.
10. Kaul R, Chhabra HS, Vaccaro AR, et al. Reliability assessment of AOSpine thoracolumbar spine injury classification system and Thoracolumbar Injury Classification and Severity Score (TLICS) for thoracolumbar spine injuries: results of a multicentre study. *Euro Spine J*, 2017;26:1470-1476.
11. Joaquim AF, Daubs MD, Lawrence BD, et al. Retrospective evaluation of the validity of the Thoracolumbar Injury Classification System in 458 consecutively treated patients. *Spine J*, 2013,13:1760-1765.
12. Knight RQ, Stornelli DP, Chan DP, et al. Comparison of operative versus nonoperative treatment of lumbar burst fractures. *Clin Orthop Relat Res*, 1993;(293):112-121.
13. Rajasekaran S. Thoracolumbar burst fractures without neurological deficit: the role for conservative treatment. *Euro Spine J,* 2010,19 Suppl 1:S40-S47.
14. Chow GH, Nelson BJ, Gebhard JS, et al. Functional outcome of thoracolumbar burst fractures managed with hyperextension casting or bracing and early mobilization. *Spine (Phila Pa 1976)*, 1996;21:2170-2175.
15. Shen WJ, Shen YS. Nonsurgical treatment of three-column thoracolumbar junction burst fractures without neurologic deficit. *Spine (Phila Pa 1976),* 1999;24:412-415.
16. Joaquim AF, Lawrence B, Daubs M, et al. Measuring the impact of the Thoracolumbar Injury Classification and Severity Score among 458 consecutively treated patients. *J Spinal Cord Med*, 2014;37:101-106.
17. Shen J, Xu L, Zhang B, et al. Risk Factors for the Failure of Spinal Burst Fractures Treated Conservatively According to the Thoracolumbar Injury Classification and Severity Score (TLICS): A Retrospective Cohort

Trial. *PLoS One*, 2015;10:e135735.

18. Gnanenthiran SR, Adie S, Harris IA. Nonoperative versus operative treatment for thoracolumbar burst fractures without neurologic deficit: a meta-analysis. *Clin Orthop Relat Res*, 2012;470:567-577.
19. Dai LY, Jiang LS, Jiang SD. Conservative treatment of thoracolumbar burst fractures: a long-term follow-up results with special reference to the load sharing classification. *Spine (Phila Pa 1976)*, 2008;33:2536-2544.
20. Mattei TA, Hanovnikian J, H DD. Progressive kyphotic deformity in comminuted burst fractures treated non-operatively: the Achilles tendon of the Thoracolumbar Injury Classification and Severity Score (TLICS). *Euro Spine J*, 2014;23:2255-2262.
21. Oxland TR, Panjabi MM, Southern EP, et al. An anatomic basis for spinal instability: a porcine trauma model. *J Orthop Res*, 1991;9:452-462.
22. Schnake KJ. Expert's comment concerning Grand Rounds case entitled "progressive kyphotic deformity in comminuted burst fractures treated non-operatively: the Achilles tendon of the Thoracolumbar Injury Classification and Severity Score (TLICS)" (T.A. Mattei, J. Hanovnikian, D. Dinh. *Euro Spine J*, 2014,23:2263-2264.
23. Reinhold M, Audige L, Schnake KJ, et al. AO spine injury classification system: a revision proposal for the thoracic and lumbar spine. *Euro Spine J*, 2013;22:2184-2201.

Tables

Table 1. Patient Demographic Data

	Nonsurgical	Surgical
No. of patients	75	44
Gender(male/female)	41/34	25/19
Median age at admission (Years)	40.6±9.8（18～63）	44.5±8.8（30～65）
TLICS score at admission	1.8±0.6	1.9±0.4
Level of fracture		
T11	9	5
T12	18	7
L1	28	20
L2	20	12
Hospital stay（Day）	9.8	13.2
Mean time of follow up（Months）	25(11-38)	38(13-55)
Complication associated with surgery	None	2 case of superficial infection

Table 2. Pain and functional outcome in nonsurgical and surgical group at last follow up

	nonsurgical	surgical	*p* value
VAS	2.6±1.8	2.4±1.5	0.91
ODI	32.4±21.8	32.9±19	0.79

Table 3. The improvement of kyphosis in nonsurgical and surgical group

	nonsurgical（n= 75）			*p* value	surgical（n=44）			*p* value
	Injury	Final follow up	improvement		Injury	Final follow up	improvement	
LSA(°)	17.6±4.5	15.2±6.2	2.3±4.6	0.09	16.8±4.2	9.5±4.2	7.3±5.2	<0.01
RSA(°)	13.6±3.4	16.5±6.5	-2.9±4.2	-0.03	10.5±4.6	6.4±5.3	4.1±2.7	<0.01

Figures

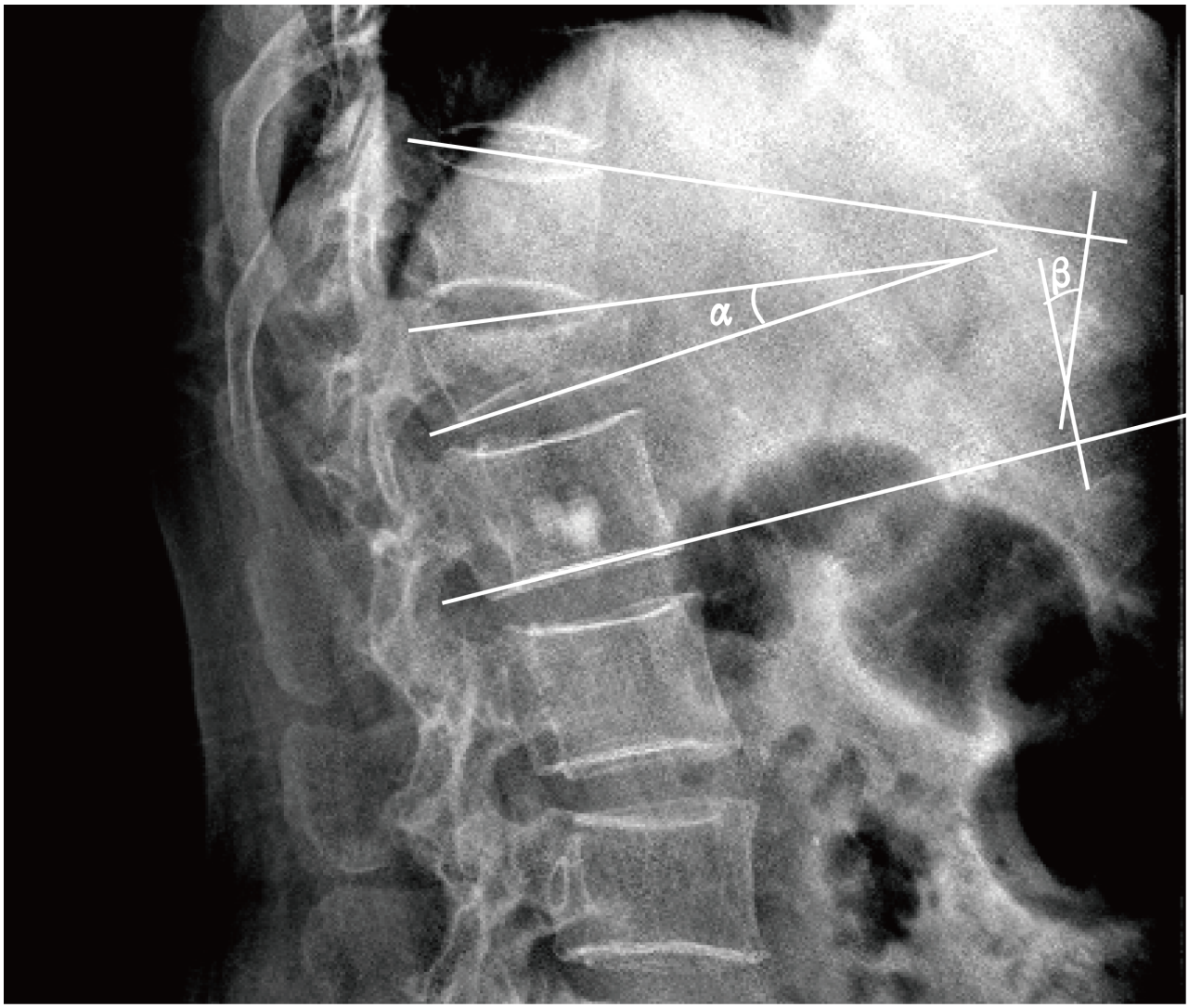

Figure 1

(A) Local sagittal angle (α). (B) Regional sagittal angle (β).

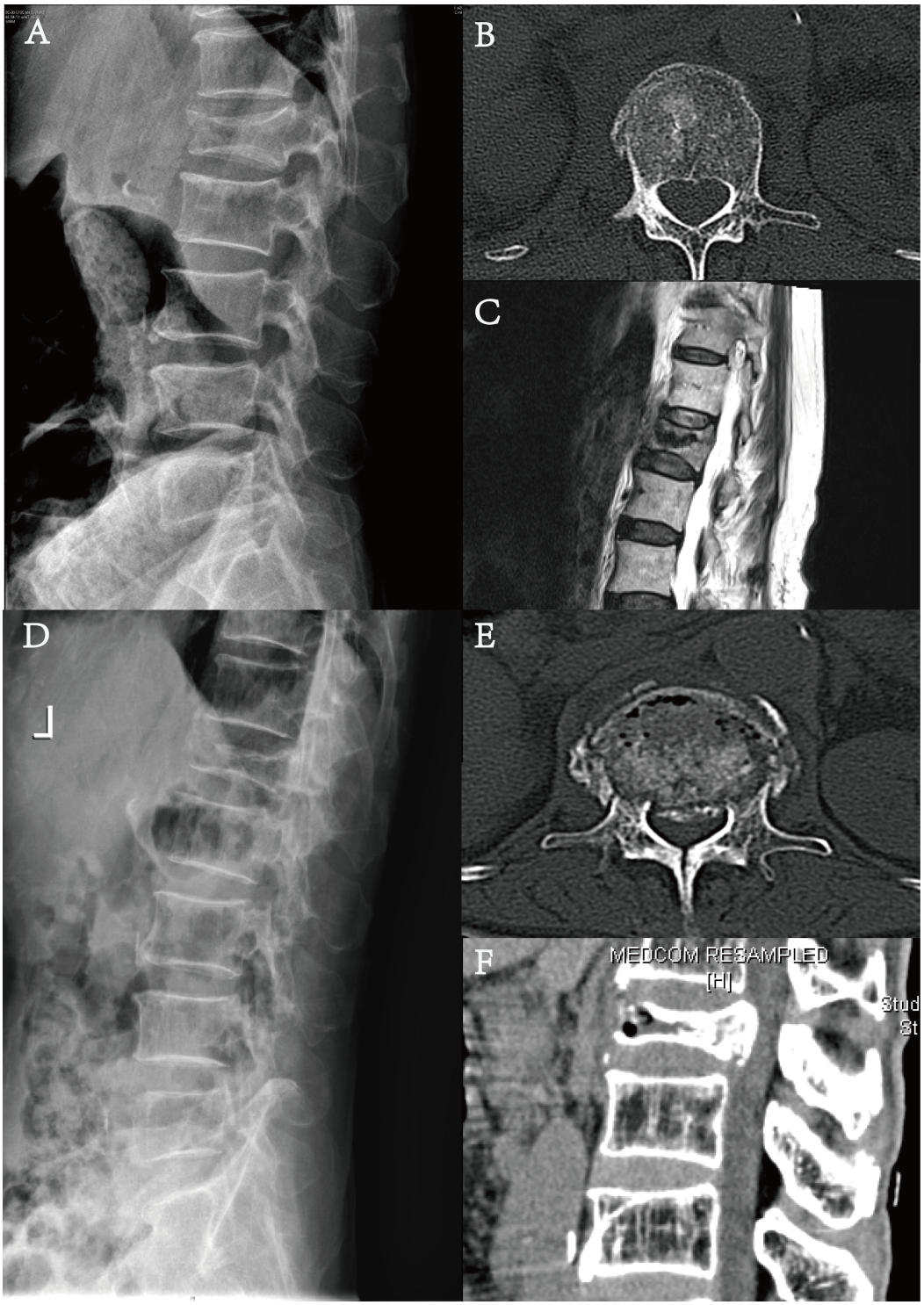

Figure 2

(A-C)A 62-year-old woman presented with L1 vertebral burst fracture showed by X Ray and CT scan, the patient presented no sign of neuropathy and had a total TLICS score of 3: injury morphology/compression fracture (1 point) + PLC/indeterminate (2 point) + neurological status/intact (0 point), and been treated with nonoperative. (D-F) Repeated X Ray and CT scan indicated obvious vertebra height loss and lumbar stenosis after 2 months follow-up, the patient complained of increased low back pain and claudication.

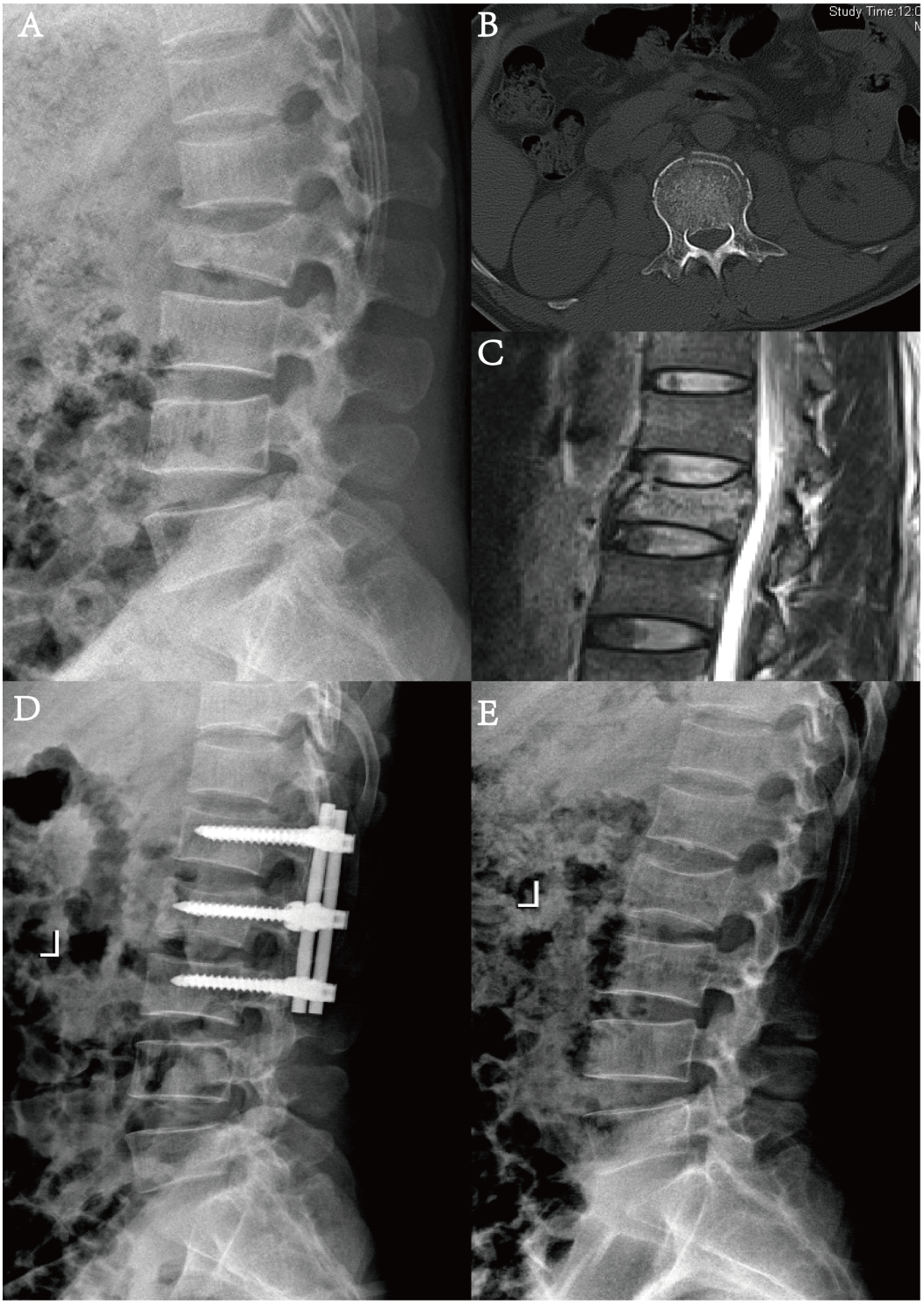

Figure 3

A-C Another 49-year-old man presented with L2 vertebral burst fracture without neuropathy because of high falling injury, X-ray, CT and MRI scan indicated he had a total TLICS score of 2: injury morphology/ burst fracture (2 point) + PLC/ intact(0 point) + neurological status/intact (0 point); (D) He underwent a posterior spinal fusion with instrumentation; (E) the instrumentation was removed at 2 years postoperatively, the pain and dysfunction experienced by the patient had disappeared; and the alignment of the spine was optimally maintained.

Supplementary Files

This is a list of supplementary files associated with this preprint. Click to download.

- SupplementalTable.docx