Should We Think More About Chronic Osteomyelitis After Trauma? A Case Report of Osteomyelitis of the Cuboid Bone

Guang-hui Zhang
Affiliated Hospital of Jining Medical University

Hong-jun Wang
Affiliated Hospital of Jining Medical University

Bing Song
Affiliated Hospital of Jining Medical University

Hong-bin Wang (wanghongbinsd1981@163.com)
Shool of Basci Medical Science,Key Lab of Cerebral Mircrocirculation,Shandong First Medical University&Shandong Academy of Medical Science

---

Research

Keywords: Osteomyelitis, diagnosis, treatment

Posted Date: November 18th, 2020

DOI: https://doi.org/10.21203/rs.3.rs-105419/v1

Abstract

Osteomyelitis is a refractory infectious disease in surgery, which takes a long time to be treated and the condition is easy to be repeated, which causes a heavy burden to individuals and families. Actively looking for the cause is the key to the treatment of osteomyelitis. In our work, we encountered a patient with cuboid osteomyelitis who had forgotten the history of injury and had received surgical treatment before seeing a doctor in our hospital, which caused great difficulties to our work. In the work of diagnosis and treatment, we constantly adjust the treatment plan and treatment ideas, and finally remove the branches from the infected focus, and obtain satisfactory treatment results.

1. Introduction

Osteomyelitis is a common clinical infectious disease that is frequently encountered by orthopedic surgeons. Chronic osteomyelitis describes infection and inflammation of bone accompanied by skin ulceration and pus outflow, and the sinus remains open for a long time without healing [1]. If it remains untreated, osteomyelitis can lead to tissue destruction and loss of function or even permanent disability [2,3]. In addition, it places heavy burdens on patients, families and society [4]. According to its etiology, osteomyelitis is divided into three types: blood-induced osteomyelitis, traumatic osteomyelitis, and osteomyelitis caused by infection of tissues adjacent to the bone. Traumatic osteomyelitis may be due to fractures caused by high-energy injury accompanied by severe skin and soft tissue damage. The damage may not be serious, but the contamination of the wound is serious [5]. Patients may focus on only the extent of injury and ignore wound contamination under various conditions because repair of tissue damage conceals wound contamination. Later, when osteomyelitis occurs, the patients may have forgotten the contamination of the wound and may even fail to remember the history of injuries. Based on only the clinical manifestations of the disease and auxiliary examinations, doctors may obtain confusing results.

2. Case Report

2.1 Clinical data

A 48-year-old patient who typically enjoyed good health underwent surgery (resection of a left foot cuboid bone cyst plus allograft bone grafting) for a cuboid bone cyst of the left foot at a local hospital. The surgeon found a cavity after opening the lateral side of the cuboid bone in surgery, and clear liquid flowed out. Allogeneic bone was used to fill the cavity after removing the hardened bone wall. Because no solid tissue specimen was obtained, no pathological examination was performed, and only bacterial culture examination was performed. The exudate from the wound after surgery was abundant, and no improvement was found after the stitches were removed. Bacterial culture showed no bacterial growth. The patient was transferred to our hospital to continue treatment to solve the continuing problem.

2.2 Preoperative preparation and first operation in our hospital

When he arrived at the hospital, the patient's left foot was slightly swollen, there was a sinus in the dorsolateral part of the foot near the cuboid bone, approximately 1 centimeter long, and a small amount of pus white liquid exuded from the sinus. The sensation and blood supply of the foot and ankle joint were normal (Fig. 1A). X-ray examination results show that the local density of the cuboid bone is reduced (Fig. 1B&C). CT and MRI showed a cuboid bone cyst and infection, which could indicate osteomyelitis (Fig. 1D&E). Importantly, the patient had mentioned that his left foot was punctured by a tree branch three years ago, but he could not provide more detailed information about the injury or the tree branch. After summarizing the opinions of all doctors in the treatment group, the following treatment plans were proposed. (1) Clean the infected area thoroughly and wash the cavity continuously. Perform bacterial culture of secretions and administer sensitive antibiotics systemically. (2) If the state of illness after the first step of treatment improves, implant bone cement particles in the cavity with sensitive antibiotics and close the wound. On 2018-11-29, with the aid of general anesthesia, we performed surgery (cleaned out the infected area plus vacuum sealing drainage) [6, 7]. In order not to destroy the integrity of the cuboid bone, we chose to enter the bone cavity along the original sinus orifice for thorough debridement. During the operation, thick pus was seen in the sinus, and a large amount of broken bone was found in the cuboid bone. We saved the necrotic tissue for pathological examination and the secretions for bacterial culture, removed necrotic tissue and pus, flushed the cavity three times with iodophor, hydrogen peroxide and saline, and then placed a vacuum sealing drainage device on the left foot.

2.2 Second operation

Three days later, bacterial culture and pathological examination revealed Enterobacter aerogenes infection and visible trabecular bone (Fig. 2A), with chronic inflammatory cell infiltration. Antibiotics and negative-pressure suction after 7 days improved the state of illness (Table 1). On 2018-12-07, under nerve block anesthesia, we performed a bone cement tamping operation [6]. During the operation, the condition of the sinus of the cuboid bone was improved. We used bone cement with sensitive antibiotics to fill the cavity (Fig. 2B). However, after 2 weeks, the wound still exuded and failed to heal, with moderate swelling.

Table 1
Bacterial culture and drug sensitivity test results.

Sequence	Antibiotic	Sensitive
1	Cefoperazone/sulbactam	Y
2	Piperacillin tazobactam	Y
3	Ceftazidime	Y
4	Ceftriaxone	Y
5	Cefepime	Y
6	Aztreonam	Y
7	Ertapenem	Y
8	Imipenem	Y
9	Amikacin	Y
10	Gentamicin	Y
11	Tobramycin	Y
12	Ciprofloxacin	Y
13	Levofloxacin	Y
Y, yes.		

2.3 Third operation

The doctors in the treatment group and the patient discussed possible countermeasures for the patient's condition together. Considering that the patient had forgotten the injury and the condition of wound contamination, with the consent of the patient, the operation was performed again for the purpose of detecting the infection, and the intraoperative situation determined the next step. On 2018-12-24, under nerve block anesthesia, we performed exploratory surgery on the infected site. In surgery, the surgeon discovered that there were many granulations in the cavity, and osteosclerosis of the cuboid bone was clear. An extended incision and enlargement of the opening of the sinus tract were performed, and a tree branch was found embedded in the dorsal wall of the cuboid bone (Fig. 3A). We found that removing the tree branch from a small opening was difficult (Fig. 3B). The wound was repeatedly flushed after removal of the branch, removal of the granulation and hardening of the bones. Considering that the cause of the infection had been removed, to reduce the patient's pain and the number of operations, we used bone cement with antibiotics to fill the cavity [8, 9].

3. Result

The wound healed smoothly after the third operation (Fig. 4C). The patient visited the doctor's office for review. The wound of the left foot had healed without redness, swelling, exudation, or local tenderness. X-ray examination results showed that bone cement supported the cuboid bone well and that bone healing had started (Fig. 4A&B). The patient had begun to work.

4. Discussion

The patient had undergone surgery at a local hospital before he came to our consultation room and was implanted with bone cement during the operation, which had an important impact on our diagnosis. No final conclusions could be drawn from the radiographs. The patient could not provide detailed wound or wound contamination information because the wound occurred 3 years prior. For the two previous operations at our hospital, we performed surgery only on existing wounds, with a restricted field of vision, and the patient failed to recover in the shortest time. We used the following osteomyelitis treatment principles: (1) Administer sensitive antibiotics; (2) Clear the lesion completely, remove dead bones and foreign matter, provide adequate drainage, and fill the cavity; (3) Improve blood circulation and promote healing [10, 11]. We summarized our lessons learned as follows: (1) Ask for a detailed medical history without missing any clues,the imaging data should be reviewed carefully before operation.; patients who do not remember something clearly are treated according to their presentation. For example, if a patient cannot remember whether the tree branch was incomplete, we should consider that the tree branch may have broken, leaving a small part in the wound. (2) Regardless of whether the patient has been treated previously, when coming to our clinic for the first time, we should not be influenced by others and simply continue previous treatment; we need to make our own diagnosis and develop a systematic treatment plan. (3) An auxiliary examination is necessary. We can also perform two to three types of examinations for different tissues, such as X-rays, CT, and MRI, when necessary. It is better to do more work on the examination than to subject the patient to repeated surgeries. (4) During the operation, the scope of the exploration should be completely exposed in the surgeon's field of vision, and we should not take this issue for granted. (5) Sitting with the patient and discussing the condition and the surgical treatment options is very meaningful.

After having these treatment experiences, we have successively removed foreign matter from patients' wounds, such as broken glass from the sole of the foot and wire and other materials from the wounds of patients who had limb trauma. We are also sharing relevant scientific knowledge with other practitioners through lectures.

Declarations

Ethics approval

All procedures performed involving human participants were in accordance with the ethical standards of the 1964 Helsinki Declaration and approved by the ethical committee of Affiliated Hospital of Jining Medical University.

Consent for publication

Not applicable.

Availability of data and materials

The datasets used during the current study are available from the corresponding author on reasonable request.

Competing interests

We declare no competing interests.

Funding

Not applicable.

Author's contributions

GZ designed the study, and collected the data. HW and BS provided the results of the auxiliary examination. GZ, HW, BS drafted the manuscript. All authors had input on the manuscript draft. HW made corresponding changes. All authors interpreted the results, revised the report and approved the final version.

Acknowledgments

Not applicable.

References

1. Hotchen AJ, McNally MA, Sendi P. The Classification of Long Bone Osteomyelitis: A Systemic Review of the Literature. J Bone Jt Infect. 2017;2(4):167–74.
2. Patel DB, Emmanuel NB, Stevanovic MV, Matcuk GR, Gottsegen CJ, Forrester DM, White EA. Hand infections: anatomy, types and spread of infection, imaging findings, and treatment options. Radiographics. 2014;34(7):1968–86.
3. McDonald LS, Bavaro MF, Hofmeister EP, Kroonen LT. Hand infections. J Hand Surg Am. 2011;36(8):1403–12.
4. Huang CC, Tsai KT, Weng SF, Lin HJ, Huang HS, Wang JJ, Guo HR, Hsu CC. Chronic osteomyelitis increases long-term mortality risk in the elderly: a nationwide population-based cohort study. BMC Geriatr. 2016;16:72.
5. Chan JKK, Ferguson JY, Scarborough M, McNally MA, Ramsden AJ. Management of Post-Traumatic Osteomyelitis in the Lower Limb: Current State of the Art. Indian J Plast Surg. 2019;52(1):62–72.

6. Huang HJ, Niu XH, Yang GL, Wang LY, Shi FC, Xu SJ, Xu LG, Li YL. [Clinical effects of application of antibiotic bone cement in wounds of diabetic foot ulcers]. Zhonghua Shao Shang Za Zhi. 2019;35(6):464–6.
7. Diefenbeck M, Mennenga U, Gückel P, Tiemann AH, Mückley T, Hofmann GO. Vacuum-assisted closure therapy for the treatment of acute postoperative osteomyelitis (in German). Z Orthop Unfall. 2011;149(3):336–41.
8. Balfour JA, Bryson HM, Brogden RN. Imipenem/cilastatin: an update of its antibacterial activity, pharmacokinetics and therapeutic efficacy in the treatment of serious infections. Drugs. 1996;51(1):99–136.
9. Diefenbeck M, Haustedt N, Schmidt HG. Surgical debridement to optimise wound conditions and healing. Int Wound J. 2013;10(Suppl 1):43–7.
10. Kutscha-Lissberg F, Hebler U, Kälicke T, Arens S. [Principles of surgical therapy concepts for postoperative and chronic osteomyelitis]. Orthopade. 2004;33(4):439–54.
11. Verhelle N, Van Zele D, Liboutton L, Heymans O. How to deal with bone exposure and osteomyelitis: an overview. Acta Orthop Belg. 2003;69(6):481–94.

Figures

Figure 1

Wounds and auxiliary examinations of patients on admission. (A) The skin around the wound is edema, exudation can be seen in the wound, the cuboid bone is exposed, and part of the bone is hardened. (B⊠C) X-ray examination results show that the local density of the cuboid bone is reduced. (C⊠D) CT (computed tomography)results showed that the internal bone of the cuboid bone was destroyed and the cavity formed.

Figure 1

Wounds and auxiliary examinations of patients on admission. (A) The skin around the wound is edema, exudation can be seen in the wound, the cuboid bone is exposed, and part of the bone is hardened. (B⊠C) X-ray examination results show that the local density of the cuboid bone is reduced. (C⊠D) CT (computed tomography)results showed that the internal bone of the cuboid bone was destroyed and the cavity formed.

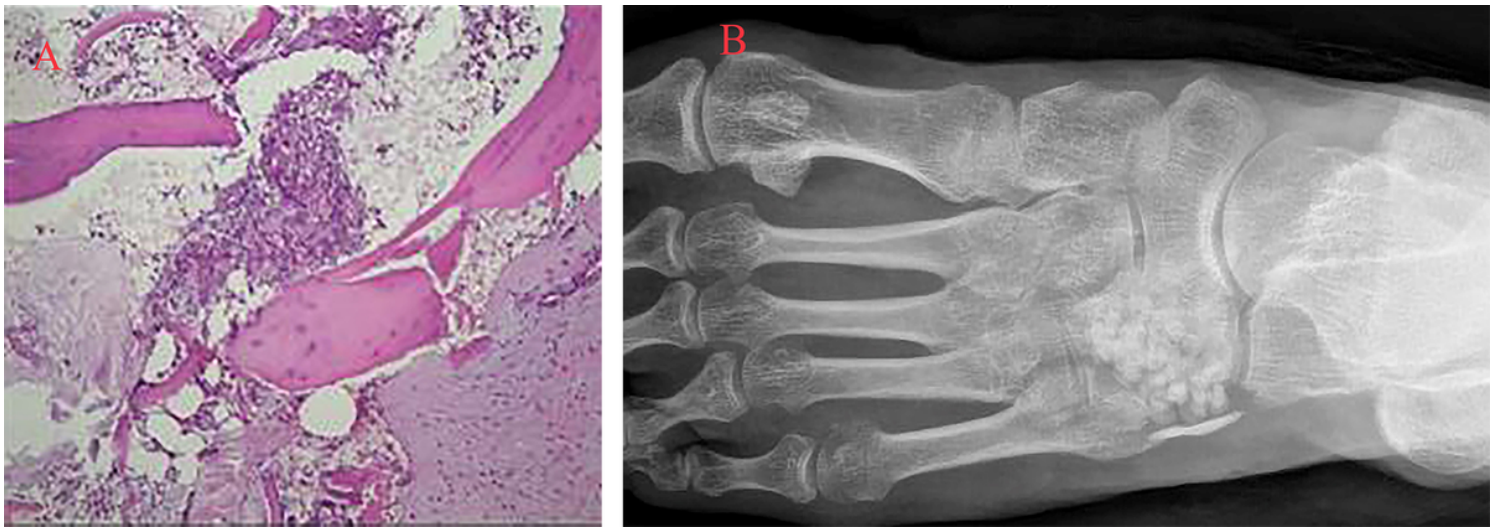

Figure 2

Pathological results and X-ray film after bone implanted. (A) Bone tissue and fibrous tissue were examined, and acute and chronic inflammatory cell infiltration between bone trabeculae could be seen. (B) The orthographic X-ray of the left foot showed that the amount of bone implanted was moderate and the bone filled the bone cavity.

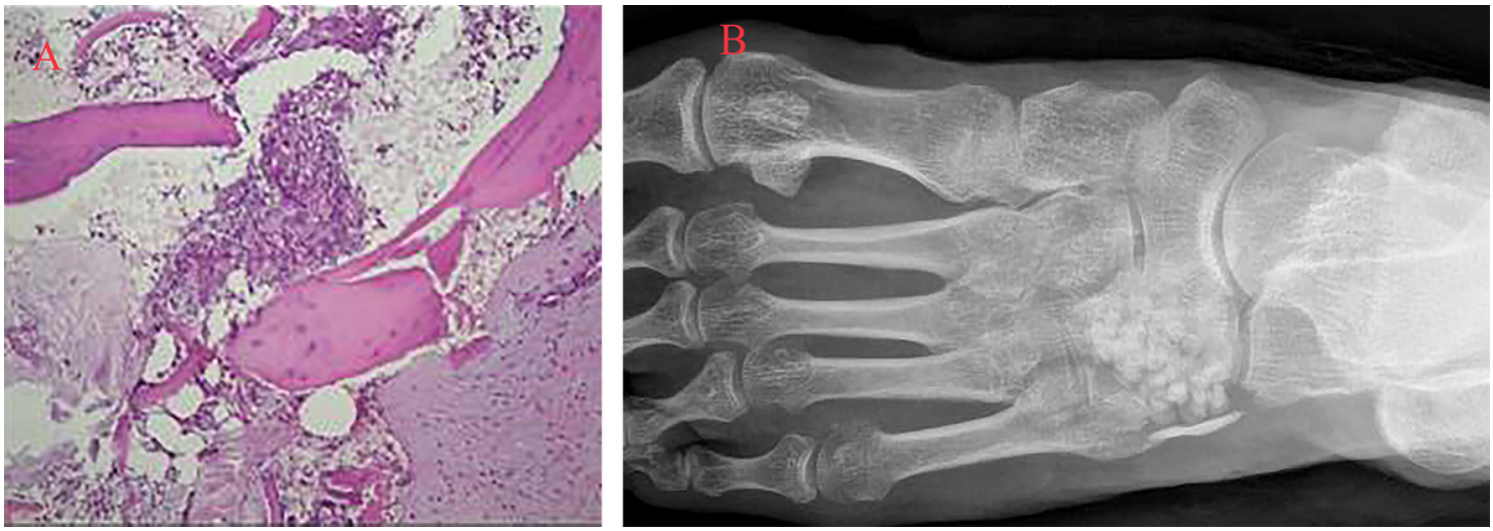

Figure 2

Pathological results and X-ray film after bone implanted. (A) Bone tissue and fibrous tissue were examined, and acute and chronic inflammatory cell infiltration between bone trabeculae could be seen. (B) The orthographic X-ray of the left foot showed that the amount of bone implanted was moderate and the bone filled the bone cavity.

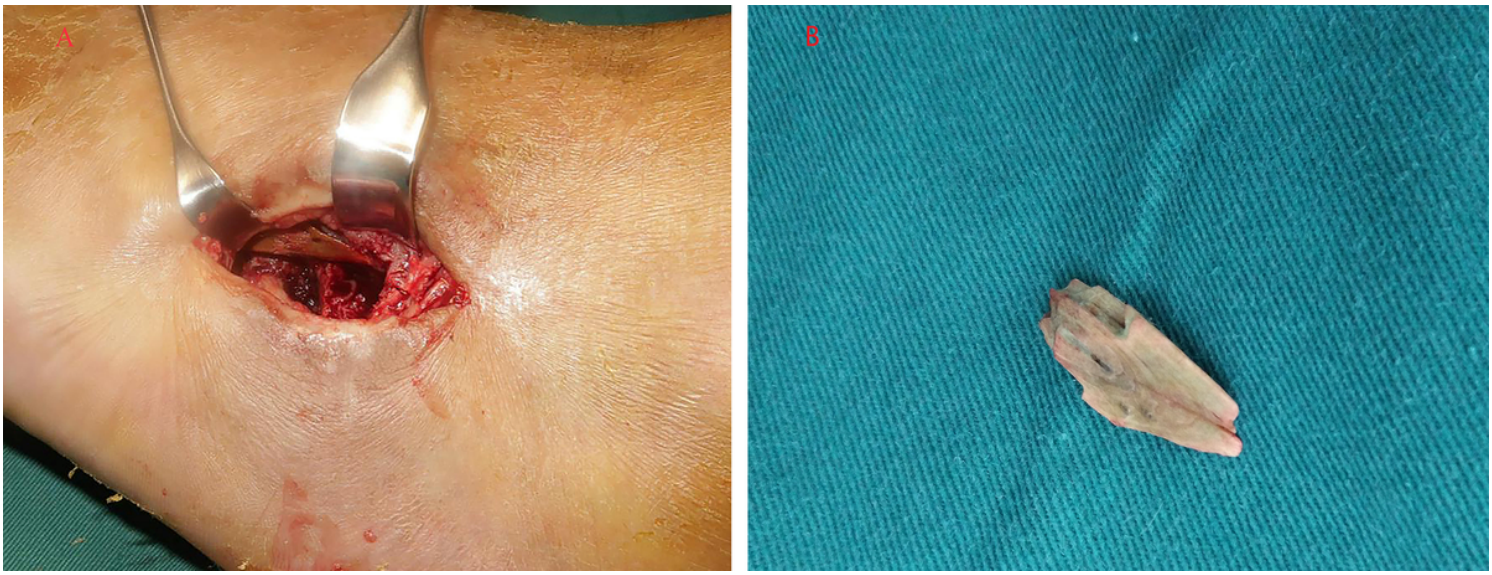

Figure 3

Expanded the window of the cuboid bone and removed the foreign body. (A) The sclerosing part of the cuboid was bitten and the bone wall wound was enlarged. After exploration, branches were embedded in the cavity. (B) The color and appearance of the removed branches.

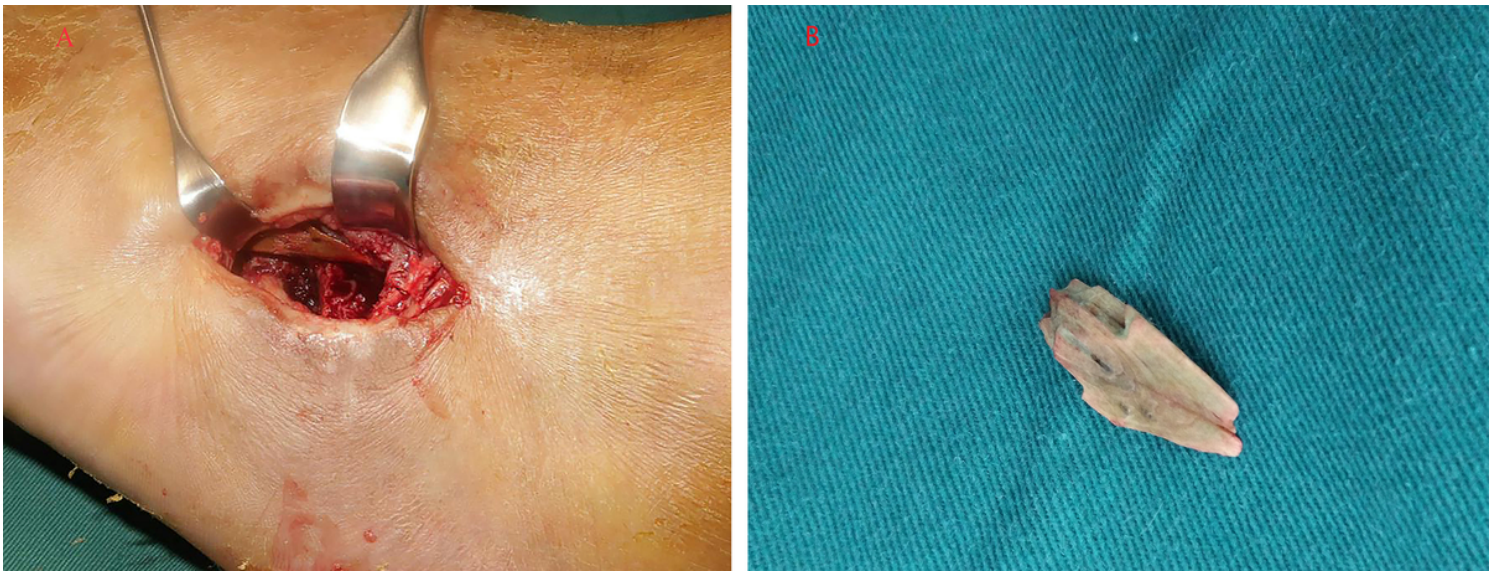

Figure 3

Expanded the window of the cuboid bone and removed the foreign body. (A) The sclerosing part of the cuboid was bitten and the bone wall wound was enlarged. After exploration, branches were embedded in the cavity. (B) The color and appearance of the removed branches.

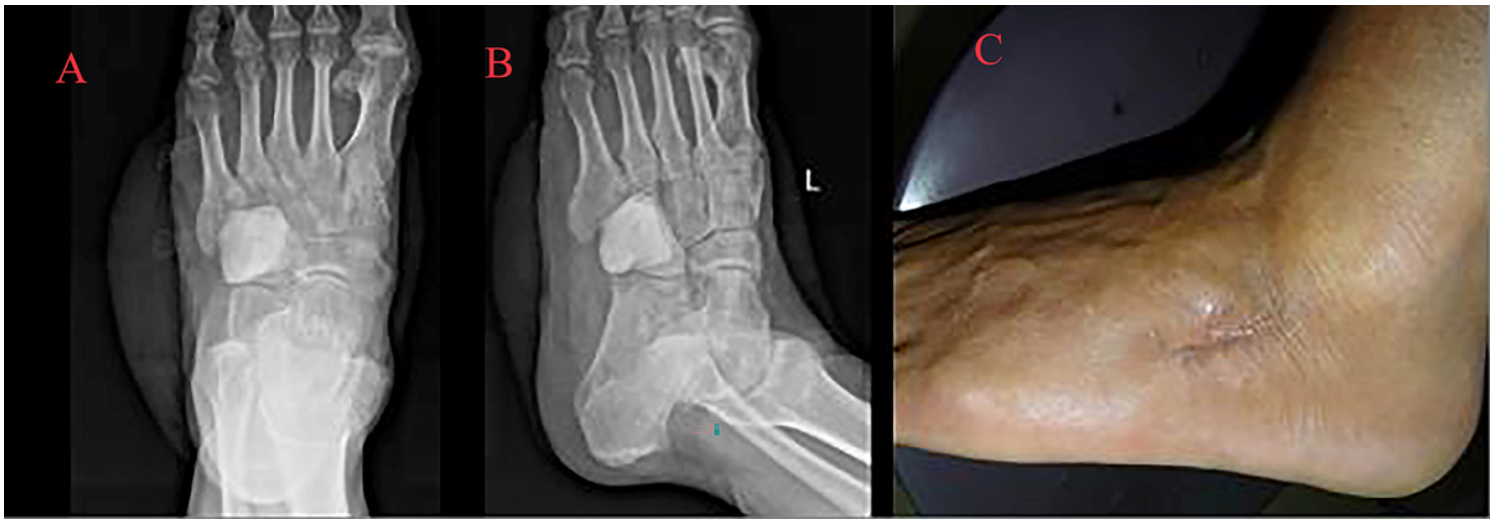

Figure 4

X-ray shows bone cement implantation and wound healing. (A⊠B) The bone cement fills the bone cavity, the cuboid bone is healed well, and there is no area of reduced density. (C) The wound is cicatricial, the scar is long, the skin around the wound is not obviously red and swollen.

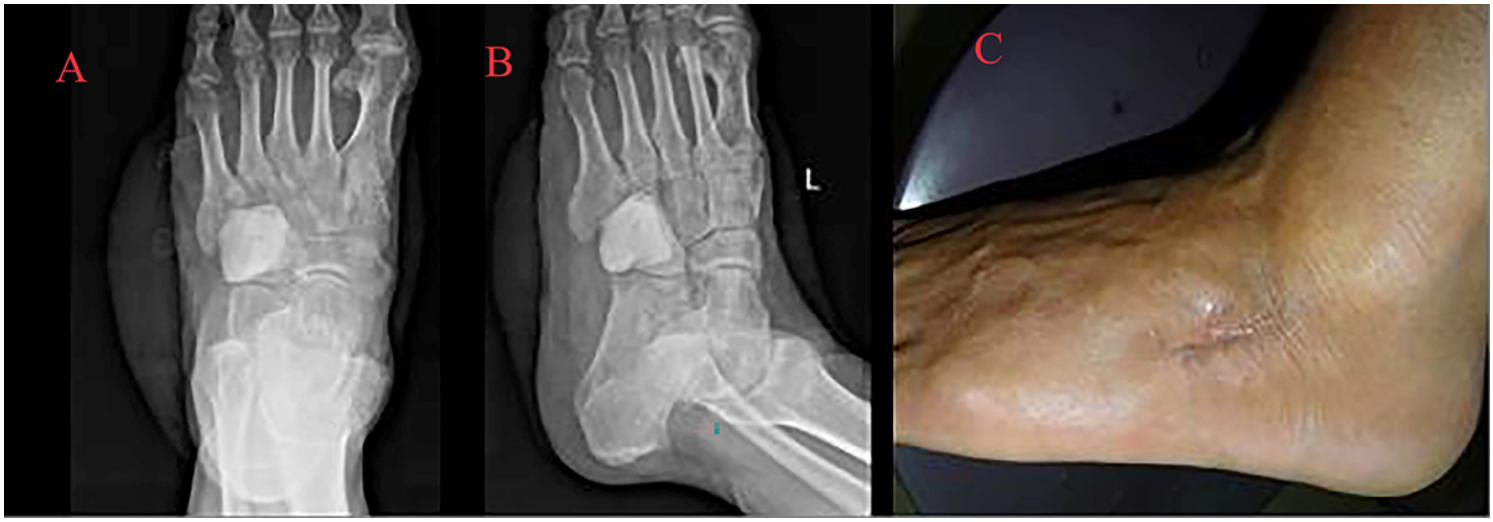

Figure 4

X-ray shows bone cement implantation and wound healing. (A⊠B) The bone cement fills the bone cavity, the cuboid bone is healed well, and there is no area of reduced density. (C) The wound is cicatricial, the scar is long, the skin around the wound is not obviously red and swollen.