Long-Term Outcome of Microwave Ablation for Benign Thyroid Nodules: A 48-Month Follow-up Study

Jia-Rui Du
China-Japan Union Hospital of Jilin University
Wen-Hui Li
China-Japan Union Hospital of Jilin University
Cheng-Hai Quan
Hospital of JiLin Bureau of Geologic Exploration and Mineral Development
Deng-Ke Teng
China-Japan Union Hospital of Jilin University
Hui Wang (whui66@jlu.edu.cn)
China-Japan Union Hospital of Jilin University https://orcid.org/0000-0001-6729-8292

Research Article

Keywords: Thyroid, Benign nodules, Thermal ablation, Ultrasound

Posted Date: November 18th, 2021

DOI: https://doi.org/10.21203/rs.3.rs-1070053/v1

Abstract

Purpose

The short-term effects of microwave ablation (MWA) in the treatment of benign thyroid nodules (BTNs) were satisfactory in previous studies. However, as a slowly progressing disease, the long-term efficacy of MWA for BTNs at present is not clear. Our study aim was to assess the long-term results of MWA for BTNs after a 48-month follow-up.

Methods

From June 2015 to September 2017, 148 patients had 148 BTNs lesions. All patients were from China-Japan Union Hospital of Jilin University. Careful ultrasound examinations were performed 1 day, 1 month, 3 months, 6 months, 12 months, and every 6 months after MWA. The volume, volume reduction rate (VRR) recurrence rate of the ablated area and thyroid function were recorded.

Results

The mean volume of the 148 nodules were 15.6±9.4 cm^3 (range: 1.3-48.9 cm^3) and 0.6±0.6 cm^3 (range: 0-3.5 cm^3) before and 48 months after MWA, respectively, for a nodule VRR of 96.9±2.5% (range: 90.4-100%). Two patients (1.35%) had recurrence after MWA. Compared with that before MWA, no significant variation in thyroid function was observed after MWA. Five patients experienced complications (3.38%): two patients (1.35%) had bleeding, two patients (1.35%) had ear pain and toothache during MWA, and one patient (0.68%) had hoarseness after MWA. No cases of oesophageal injury, tracheal injury, infection, skin burn, etc., were reported during or after MWA.

Conclusions

Over long-term follow-up, MWA is an effective method for treating BTNs and is expected to be a potential first-line treatment.

Introduction

In recent years, the detection rate of thyroid nodules has been as high as 65%, and more than 90% of nodules are benign [1, 2]. Only a few of these benign nodules require treatment. Although surgery is a widely used and effective treatment regimen, it is traumatic, results in a slow recovery, and affects the appearance of the patient. Moreover, some patients must be placed on long-term thyroid hormone replacement therapy after surgery [3-5]. Therefore, in recent years, a huge number of scholars have sought minimally invasive treatment methods to treat benign thyroid nodules (BTNs).

One such method is microwave ablation (MWA), which has demonstrated good results in the treatment of benign and malignant thyroid tumours in recent years [6-8]. The short-term effects of MWA in the treatment of BTNs have been verified by some scholars [9-12]. However, as a slowly progressing disease, the real efficacy of MWA treatment for BTNs should be demonstrated over long-term follow-up. Therefore, this study aimed to clarify the efficacy of MWA in the treatment of BTNs through at least 48 months of follow-up.

Materials And Methods

Study oversight

This retrospective study was approved by the Ethics Committee of the China-Japan Union Hospital of Jilin University, and all patients signed an informed consent form before undergoing MWA. All patients were confirmed to have BTNs by core-needle biopsy (CNB).

Patients

The inclusion criteria were as follows: (1) benign nodules with once clear pathological result by CNB (Bethesda category: class II, benign); (2) large nodules (>4 cm) causing compressive or structural symptoms or psychological anxiety or that affected the appearance of the patient; (3) only a single nodule of the thyroid gland; (4) refusal to undergo surgical treatment or intolerance for surgery; and (5) normal thyroid functionality.

The exclusion criteria were as follows: (1) no clear pathological diagnosis or inaccurate CNB results (Nondiagnostic or Unsatisfactory; Atypia of Undetermined Significance or Follicular Lesion of Undetermined Significance; Follicular Neoplasm or Suspicious for a Follicular Neoplasm or Specify if Hurthle cell type); (2) pregnancy or lactation; (3) severe abnormal blood coagulation; (4) severe abnormal heart or lung function causing inability to tolerate MWA; and (5) nodules accompanied by macrocalcifications (>1 cm).

From June 2015 to September 2017, 153 patients with 153 lesions at our hospital underwent ultrasound-guided MWA for the treatment of BTN. Five patients with 5 lesions were lost to follow-up, and the remaining 148 patients with 148 lesions were finally included in this study. Among them, there were 33 males and 115 females with an average age of 41.2 ±10.7 years (range: 25-72 years).

Equipment

A Siemens S2000 (Siemens Mountainview, USA) and MINDRAY® DC-8Exp (MINDRAY, Shenzhen, China) colour Doppler ultrasonic diagnostic instrument was employed for ultrasonic image acquisition and MWA guidance. The probe was a 4-9 MHz linear array probe for detecting the superficial organs. An ECO-100A1 microwave treatment instrument (YIGAO Microwave System Engineering Co., Ltd., Nanjing, Jiangsu Province, China) and ECO-100AI3 superficial organ ablation needle (16 G, total length: 10 cm, microwave transmitter away from the shaft tip: 3 mm) were used for MWA.

Pre-MWA procedures

Image collection included observing and recording the size, location, composition, echogenicity, margin, shape, echogenic foci, blood flow, etc., of the lesion. All images were collected by a senior doctor (with more than 10 years of experience in thyroid ultrasound examination). Contrast-enhanced ultrasonography (CEUS) was performed before MWA to obtain the scope and blood supply of the nodules and to design a corresponding MWA plan, which was designed by two experienced doctors (with over 5 years of experience in MWA). The volume of the lesion was calculated using $V = \pi abc/6$ (V: volume, a: maximum diameter, b and c: the other two perpendicular diameters). A thyroid function test was performed before MWA and 1 month, 6 months, 12 months, and every 12 months thereafter.

Symptom scores and cosmetic scores were evaluated before and after MWA. We used a visual analogue scale (with scores ranging from 0 to 10) to evaluate neck compression symptoms and dysphagia. The experienced physician evaluated the cosmetic appearance with a score from 1 to 4: 1: no palpable mass; 2: palpable but invisible mass; 3: cosmetic problems when swallowing; 4: cosmetic problems (6, 10).

MWA procedure

The patient was laid supine with the neck fully exposed, and local infiltration anaesthesia with 1% lidocaine was administered. For lesions close to the high-risk area, e.g., near the trachea, oesophagus, recurrent laryngeal nerve and neck vasculature, normal saline was used as an isolation fluid to separate the high-risk area from the lesion to prevent damage to the surrounding important organs or tissues.

Following the use of Teng's puncture method (13), the ablation antenna was implanted into the thyroid nodule. On the MWA instrument, ablation mode was initiated with 25 W-30 W power. Using moving-shot techniques (14) during MWA, according to the volume, location and blood supply of the nodule, ablation was performed layer by layer from the upper pole to the lower pole or from the lower pole to the upper pole of the thyroid, following the "from far to near" or "from deep to shallow" principle (14).
When the MWA process was performed near the recurrent laryngeal nerve, the operator verbally communicated intermittently with the patient to quickly detect any hoarseness. During the MWA process, the isolation fluid should be quickly replenished if it is absorbed.

A CEUS examination was performed immediately after MWA. If the ablation range was satisfactory, i.e., the "black hole" without contrast filling completely covered the tumour, the ablation was considered complete; if the ablation range was not satisfactory, i.e., CEUS showed contrast filling in nodules, supplemental ablation was performed.

Follow-up

Careful ultrasound examinations were performed 1 day, 1 month, 3 months, 6 months, 12 months, and every 6 months after MWA. The volume and volume reduction rate (VRR) of the MWA area were observed and recorded, the latter using the following formula: VRR (%) = ([initial volume−final volume] × 100%)/initial volume. Recurrence was defined as abnormal nodular echo found in the internal or marginal

ablation area, nodular echo gradually growing or abundant blood flow signals inside during follow-up, and then it was confirmed as a BTN by CNB.

Statistical analysis

SPSS 20.0 was used for statistical analysis. The size of the nodule and the age of the patient were described using the mean ± standard deviation (SD). The volume changes before and after MWA were measured by the paired samples *t*–test. $P < 0.05$ was considered to indicate statistical significance.

Result

Lesion characteristics

A total of 148 lesions were confirmed by CNB pathology to be BTNs. Among them, 81 were located in the right lobe, and 67 were located in the left lobe. The average maximum diameter of the nodules was 3.6±0.8 cm (range: 2.0-5.8 cm), and the mean volume was 15.6 ±9.4 cm^3 (range: 1.3-48.9 cm^3).

MWA procedure and complications

During MWA, all 148 patients tolerated the local anaesthesia well, and none required other analgesic drugs after MWA.

Five patients (3.38%) had complications in the peri-MWA period: major complications (0.68%) were observed in one patient (one with hoarseness), and minor complications (2.70%) were observed in four patients (two with bleeding and two with earache and toothache). No cases of oesophageal injury, tracheal injury, infection, skin burn, etc., were reported during or after MWA.

Of the two patients (1.35%) who had bleeding during MWA, 5 minutes of compression stopped the bleeding for one but not for the other, as confirmed by colour Doppler ultrasound at the bleeding site. For the other patient, the bleeding site was burned for 1 minute with an ablation power of 40 W, successfully stopping the bleeding. Neither of the patients who had bleeding required surgical haemostasis.

Two patients (1.35%) experienced earache or toothache on the same side as the lesion during MWA, and the pain was relieved within two hours after MWA.

One patient (0.68%) had hoarseness after MWA and recovered 3 months after MWA. The nodule of this patient was larger than that of the other patients, measuring 5.8 cm×3.5 cm×4.6 cm for a volume of 48.9 cm^3, and was located adjacent to the dorsal thyroid gland.

Two patients (1.35%) had recurrence after MWA. Two recurrent nodules showed regrowth at the marginal region of the previous nodule at the 18-month and 24-month follow-ups. Both of them showed BTN diagnosis by CNB and performed a second MWA procedure. After the secondary procedure,

two nodules decreased in size and did not recur during the follow-up period, which continued for more than 24 months and 30 months.

Follow-up

The follow-up duration of the 148 patients was 48 months. 48 months after MWA, the mean volume of the 148 nodules was significantly decreased from 15.6±9.4 cm^3 (range: 1.3-48.9 cm^3) to 0.6±0.6 cm^3 (range: 0-3.5 cm^3) (P <0.0001) (**Fig.1**), with a VRR of 96.9±2.5% (range: 90.4-100%) (**Fig.2**). Of all the nodules, 44 (29.7%) had become completely absorbed (**Table 1**).

All 148 patients underwent thyroid function examination before MWA and 1 month, 6 months, 12 months, and every 12 months after MWA, and none showed significant variation in thyroid function after MWA compared with before MWA.

Symptomatic and cosmetic problems

The symptom and cosmetic scores were 4.1±1.3 (range: 0-8) and 2.1±0.8 (range: 1-4) before MWA, respectively. 48 months later, it was significantly decreased to 0.7±0.5(range: 0-2) (P<0.0001) and 1.0±0.2(range: 1-2) (P=0.0002), respectively.

Discussion

In this study, 148 nodules in 148 patients were treated with MWA, and the patients were followed-up for 48 months. The long-term follow-up results of the study showed that MWA was effective and safe for the treatment of BTNs. Cheng [6] and Yue [20] reported the treatment of BNTs by MWA and achieved good results, but their follow-up time was less than 12 months. However, BNTs are a slowly progressing disease, and short-term follow-up may not be enough to accurately judge recurrence after MWA. Although Lim [15] treated BNTs with RFA and conducted long-term follow-up, the long-term efficacy of MWA treatment for BTNs at present is not clear.

In this study, MWA was used to treat BTNs, achieving good therapeutic effects for long-term follow-up. After 48 months of follow-up after MWA, the nodule volume was significantly reduced, with a VRR of 96.9±2.5% (range: 90.4-100%). In previous research [4, 6, 9, 10, 20–25], the follow-up duration after MWA and RFA was 6-12 months, and the mean VRR of the nodules was 45.99%-85.97% and 57.10%-84.79%, respectively, lower than that in our study. We think this is due to the short follow-up period. In Lim’s study [15], BTNs were treated with RFA and were followed up for 4 years, and the mean VRR was 93.4±11.7%, similar to the value obtained in our study. Moreover, the treatment of BTNs by MWA in this study significantly alleviated the patients' symptoms and cosmetic problems.

Our study revealed a recurrence rate of 1.35% (2/148), which was lower than that in Cheng's and Lim’s study, in which the recurrence rates were 7.7% (51/664) and 5.6% (7/126), respectively [6, 15]. We hypothesize three reasons for the low recurrence rate after MWA in this study. First, the application of

CEUS helped in quickly detecting the presence of residual nodules after MWA and in minimizing or avoiding recurrence through timely supplemental ablation. Second, during MWA, the supplying blood vessel was usually located at the edge of the nodule; thus, the marginal area of the nodule should be fully ablated. Third, careful planning before MWA and strict implementation of the plan during MWA were crucial for preventing recurrence after MWA.

This study showed that MWA was safe for treating BTNs. Five patients (3.38%) in this study had complications in the peri-MWA period, which was similar to Lim's study [15], and the overall complication rate in Lim's study was 3.6% (4/111).

In our study, two patients (1.35%) experienced bleeding during the MWA procedure, lower than previous studies on MWA for the treatment of BTNs, such as studies by Liu and Korkusuz, who found bleeding risk rates of 3.4% and 7.1%, respectively [11, 16]. The lower bleeding risk rate in this study was attributed to the following reasons. First, careful observation with colour Doppler prior to puncture could avoid some bleeding, which was caused by damage to the small blood vessels during the puncture process. Second, colour Doppler ultrasound was used to locate the bleeding site quickly and accurately, and MWA could be used to perform haemostasis with 1 minute of ablation at a power of 40 W.

One patient (0.68%) experienced hoarseness that recovered after 3 months, which was lower than Zhi Xi's [3] study (3.6%) and Cheng's [6] report (5.8%). Our experience shows that the treatment of BTNs should comprise full ablation under the premise of safety. Therefore, when ablating BTNs, heat injury of the peripheral nerves should be avoided as much as possible. If the duration of ablation is too long, it is important to quickly replenish the isolation liquid to avoid nerve injury [17–19].

Our study also demonstrated other advantages. The thyroid function of all 148 patients was reviewed 48 months after MWA, showing no significant variation compared with that before MWA. This shows that MWA does not cause hypothyroidism in patients, which is a very important advantage of MWA for BTNs.

This research also has some limitations. First, this research had a small sample size. Second, this study was conducted at a single centre; future studies should involve a multicentre, larger sample to further verify the results. Finally, although CNB was performed for all 148 nodules in this study to reduce the occurrence of false negatives, this cannot be completely avoided.

In conclusion, over long-term follow-up, MWA for the treatment of BTNs is effective and safe and is expected to be a potential first-line treatment.

Abbreviations

MWA, microwave ablation

BTNs, benign thyroid nodules

RFA, radiofrequency ablation

VRR, volume reduction rate

CNB, core-needle biopsy

CEUS, contrast-enhanced ultrasonography

Declarations

Data availability

Datasets generated during and/or analyzed during the current study are not publicly available but are available from the corresponding author on reasonable request.

Statements and Declarations

Competing Interests: The authors have no competing interests to declare that are relevant to the content of this article.

Funding: This work was supported by the Department of Science and Technology of Jilin Province (Grant No. 20190303140SF), the Jilin Provincial Health and Family Planning Commission (Grant No. 2019SCZ027) and the China Postdoctoral Science Foundation (Grant No. 2019M661219).

Acknowledgements

The authors would like to thank Xue-Qing Feng for her encouragement and support of this study.

Author Contributions:

Deng-Ke Teng and Hui Wang contributed to the study conception and design. Material preparation, data collection and analysis were performed by Wen-Hui Li and Cheng-Hai Quan. The first draft of the manuscript was written by Jia-Rui Du, and all authors commented on previous versions of the manuscript. All authors read and approved the final manuscript.

Compliance with ethical standards

Conflict of interest The authors have no competing interests to declare that are relevant to the content of this article.

Ethical approval This retrospective study involving human participants was in accordance with the ethical standards of the institutional and national research committee and with the 1964 Helsinki Declaration and its later amendments or comparable ethical standards. The Ethics Committee of the China-Japan Union Hospital of Jilin University approved this study.

Informed consent Informed consent was obtained from all individual participants included in the study.

References

1. S. Guth, U. Theune, J. Aberle, A. Galach, C.M. Bamberger, Very high prevalence of thyroid nodules detected by high frequency (13 MHz) ultrasound examination. Eur J Clin Invest. **39**(8):699-706 (2009). http:// doi.org/10.1111/j.1365-2362.2009.02162.x

2. C. Durante, G. Grani, L. Lamartina, S. Filetti, S.J. Mandel, D.S. Cooper, The Diagnosis and Management of Thyroid Nodules A Review. JAMA. **319**(9):914-924 (2018). https://doi.org/10.1001/jama.2018.0898

3. X. Zhi, N. Zhao, Y. Liu, J.B. Liu, C. Teng, L. Qian, Microwave ablation compared to thyroidectomy to treat benign thyroid nodules. Int J Hyperthermia. **34**(5):644-652 (2018). https://doi.org/10.1080/02656736.2018.1456677

4. B.W. Zheng, J.F. Wang, J.X. Ju, T. Wu, G. Tong, J. Ren, Efficacy and safety of cooled and uncooled microwave ablation for the treatment of benign thyroid nodules: a systematic review and meta-analysis (Review). Endocrine. **62**(2):307-317 (2018). https://doi.org/ 10.1007/s12020-018-1693-2

5. J. Yan, T. Qiu, J. Lu, Y. Wu, Y. Yang, Microwave ablation induces a lower systemic stress response in patients than open surgery for treatment of benign thyroid nodules. Int J Hyperthermia. **34**(5):606-610(2018). https://doi. org/10.1080/02656736.2018.1427286

6. Z. Cheng, Y. Che, S. Yu, S. Wang, D. Teng, H. Xu, J. Li, D. Sun, Z. Han, P. Liang, US-Guided Percutaneous Radiofrequency versus Microwave Ablation for Benign Thyroid Nodules: A Prospective Multicenter Study. Sci Rep. **7**(1):9554 (2017). https:// doi.org/10.1038/s41598-017-09930-7

7. A.P. Mainini, C. Monaco, L.C. Pescatori, C. De Angelis, F. Sardanelli, L.M. Sconfienza, G. Mauri, Image-guided thermal ablation of benign thyroid nodules. J Ultrasound. **20**(1):11-22 (2017). https://doi.org/10.1007/s40477-016-0221-6

8. D. Teng, G. Sui, C. Liu, Y. Wang, Y. Xia, H. Wang, Long-term efficacy of ultrasound-guided low power microwave ablation for the treatment of primary papillary thyroid microcarcinoma: a 3-year follow-up study. Journal of cancer research and clinical oncology. **144**(4):771-779 (2018). https://doi.org/10.1007/s00432-018-2607-7

9. W. Wu, X. Gong, Q. Zhou, X. Chen, X. Chen, B. Shi, US-guided percutaneous microwave ablation for the treatment of benign thyroid nodules. Endocr J. **64**(11):1079-1085 (2017). https:// doi.org/10.1507/endocrj. EJ17-0152

10. B. Feng, P. Liang, Z. Cheng, X. Yu, J. Yu, Z. Han, F. Liu, Ultrasound-guided percutaneous microwave ablation of benign thyroid nodules: experimental and clinical studies. Eur J Endocrinol. **166**(6):1031-1037

(2012). https:// doi.org/10.1530/eje-11-0966

11. Y.J. Liu, L.X. Qian, D. Liu, J.F. Zhao, Ultrasound-guided microwave ablation in the treatment of benign thyroid nodules in 435 patients. Exp Biol Med (Maywood). **242**(15):1515-1523 (2017). https:// doi.org/10.1177/1535370217727477

12. Huynh Quang K, Ngo Quoc H, Vu Huu V, Nguyen Van K, Nguyen Lam V, Efficacy of Microwave Ablation in the Treatment of Large (≥3 cm) Benign Thyroid Nodules. World J Surg. **44**(7):2272-2279 (2020). https://doi. org/10.1007/s00268-020-05432-2

13. D. Teng, L. Ding, Y. Wang, C. Liu, Y. Xia, H. Wang, Safety and efficiency of ultrasound-guided low power microwave ablation in the treatment of cervical metastatic lymph node from papillary thyroid carcinoma: a mean of 32 months follow-up study. Endocrine. **62**(3):648-654 (2018). https://doi.org/10.1007/s12020-018-1711-4

14. J.H. Kim, J.H. Baek, H.K. Lim, H.S. Ahn, S.M. Baek, Y.J. Choi, Y.J. Choi, S.R. Chung, E.J. Ha, S.Y. Hahn, S.L. Jung, D.S. Kim, S.J. Kim, Y.K. Kim, C.Y. Lee, J.H. Lee, K.H. Lee, Y.H. Lee, J.S. Park, H. Park, J.H. Shin, C.H. Suh, J.Y. Sung, J.S. Sim, I. Youn, M. Choi, D.G. Na, 2017 Thyroid Radiofrequency Ablation Guideline: Korean Society of Thyroid Radiology. Korean J Radiol. **19**(4):632-655 (2018). https://doi.org/10.3348/kjr.2018. 19.4.632

15. H.K. Lim, J.H. Lee, E.J. Ha, J.Y. Sung, J.K. Kim, J.H. Baek, Radiofrequency ablation of benign non-functioning thyroid nodules: 4-year follow-up results for 111 patients. Eur Radiol. **23**(4):1044-1049 (2013). https://doi.org/ 10.1007/s00330-012-2671-3

16. H. Korkusuz, F. Nimsdorf, C. Happel, H. Ackermann, F. Grunwald, Percutaneous microwave ablation of benign thyroid nodules. Functional imaging in comparison to nodular volume reduction at a 3-month follow-up. Nuklearmedizin Nuclear medicine. **54**(1):13-19 (2015). https://doi.org/10.3413/Nukmed-0678-14-06

17. D.K. Teng, H.Q. Li, G.Q. Sui, Y.Q. Lin, Q. Luo, P. Fu, J.R. Du, C.X. Jin, H. Wang, Preliminary report of microwave ablation for the primary papillary thyroid microcarcinoma: a large-cohort of 185 patients feasibility study. Endocrine. **64**(1):109-117 (2019). https://doi.org/10.1007/s12020-019-01868-2

18. M.K. Lee, J.H. Baek, S.R. Chung, Y.J. Choi, Y.M. Lee, T.Y. Kim, J.H. Lee, Effectiveness of Injecting Cold 5% Dextrose into Patients with Nerve Damage Symptoms during Thyroid Radiofrequency Ablation. Endocrinol Metab (Seoul). **35**(2):407-415 (2020). https://doi.org/10.3803/EnM.2020.35.2.407

19. P. Dong, X.L. Wu, G.Q. Sui, Q. Luo, J.R. Du, H. Wang, D.K. Teng, The efficacy and safety of microwave ablation versus lobectomy for the treatment of benign thyroid nodules greater than 4 cm. Endocrine. **71**(1):113-121 (2021). https://doi.org/10.1007/s12020-020-02338-w

20. W. Yue, S. Wang, B. Wang, Q. Xu, S. Yu, Z. Yonglin, X. Wang, Ultrasound guided percutaneous microwave ablation of benign thyroid nodules: safety and imaging follow-up in 222 patients. Eur J Radiol. **82**(1):e11-16 (2013). https://doi.org/10.1016/j.ejrad.2012.07.020

21. W.W. Yue, S.R. Wang, F. Lu, L.P. Sun, L.H. Guo, Y.L. Zhang, X.L. Li, H.X. Xu, Radiofrequency ablation vs. microwave ablation for patients with benign thyroid nodules: a propensity score matching study. Endocrine. **55**(2):485-495 (2017). https://doi.org/10.1007/s12020-016-1173-5

22. W.K. Jeong, J.H. Baek, H. Rhim, Y.S. Kim, M.S. Kwak, H.J. Jeong, D. Lee, Radiofrequency ablation of benign thyroid nodules: safety and imaging follow-up in 236 patients. Eur Radiol. **18**(6):1244-1250 (2008). https://doi.org/ 10.1007/s00330-008-0880-6

23. G. Russ, A.B. Hamou, S. Poirée, C. Ghander, F. Ménégaux, L. Leenhardt, C. Buffet, Learning curve for radiofrequency ablation of benign thyroid nodules. Int J Hyperthermia. **38**(1):55-64 (2021). https://doi.org/ 10.1080/02656736.2021.1871974

24. Elvin Y T Lim, Leong S, Harold H W Heah, C F Jeremy Ng, Chng CL, Too CW. Pilot study of single-session radiofrequency ablation of benign thyroid nodules in Singapore. Ann Acad Med Singap. **50**(3):277-279 (2021). https://doi.org/10.47102/annals-acadmedsg.2020290

25. G.M. Lee, J.Y. You, H.Y. Kim, Y.J. Chai, H.K. Kim, G. Dionigi, R.P. Tufano, Successful radiofrequency ablation strategies for benign thyroid nodules. Endocrine. **64**:316-321 (2019). https://doi.org/10.1007/s12020-018-1829-4

Tables

Table1. Mean volume, volume reduction rate and absorption rate of the nodules after MWA

Time	Mean volume of ablation area ( )	Mean volume reduction rate (%)	Completely absorption rate of nodules (%)	P value (vs. volume before MWA)
Before MWA	15.6±9.4	-	0.0	-
1 month later	12.5±7.6	20.9±7.3	0.0	0.000
3 months later	9.6±6.1	38.1±10.4	0.0	0.000
6 months later	8.0±5.2	52.8±12.8	0.0	0.000
12 months later	6.0±4.2	66.3±12.9	2.0	0.000
18 months later	4.6±3.4	75.3±12.0	9.5	0.000
24 months later	3.3±2.8	81.5±10.9	14.2	0.000
30 months later	2.5±2.3	87.1±9.3	18.9	0.000
36 months later	1.8±1.6	91.0±7.0	23.0	0.000
42 months later	1.2±1.1	94.4±4.4	27.0	0.000
48 months later	0.6±0.6	96.9±2.5	29.7	0.000

Figures

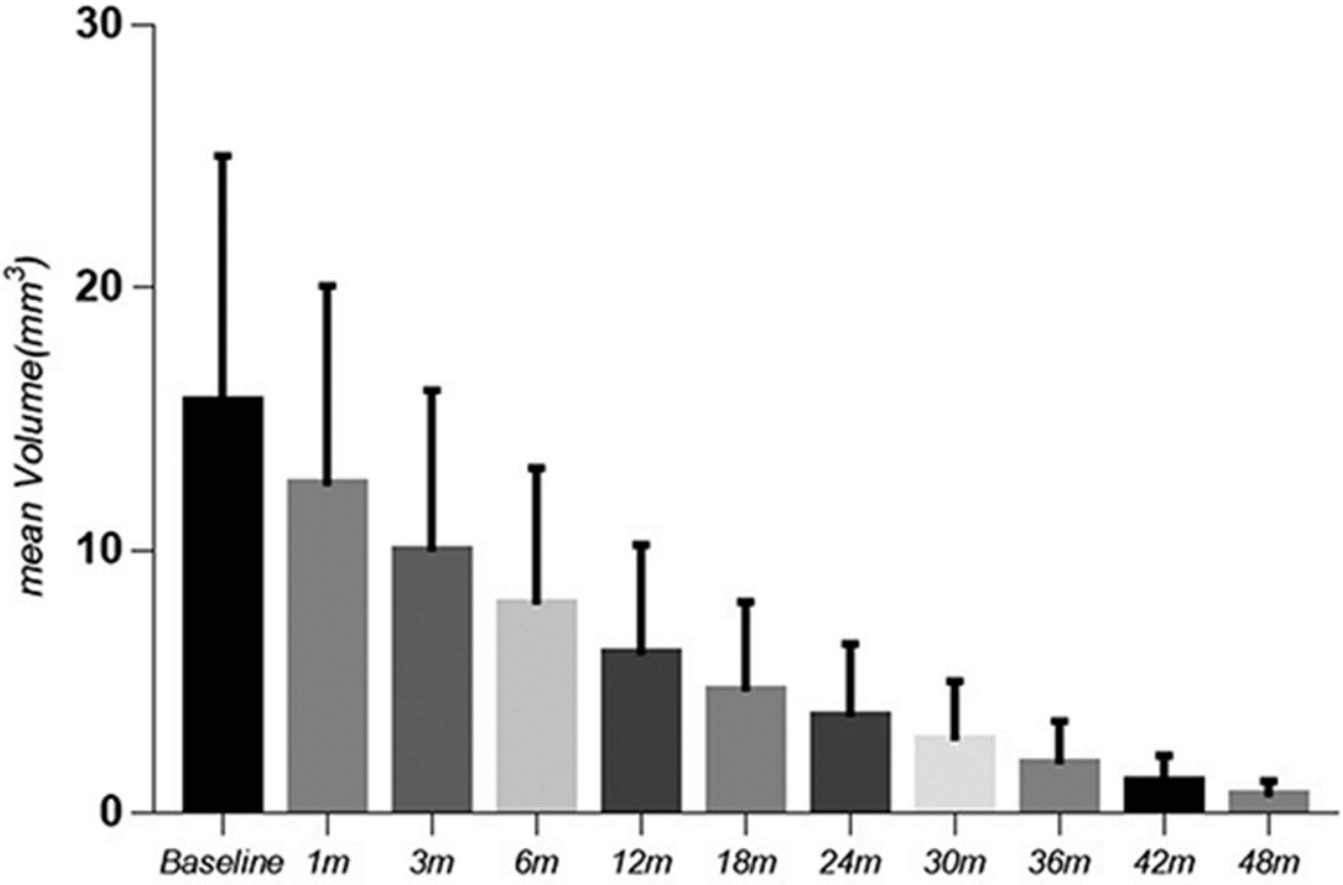

Figure 1

Variation in the mean volume before and after MWA at each follow-up point.

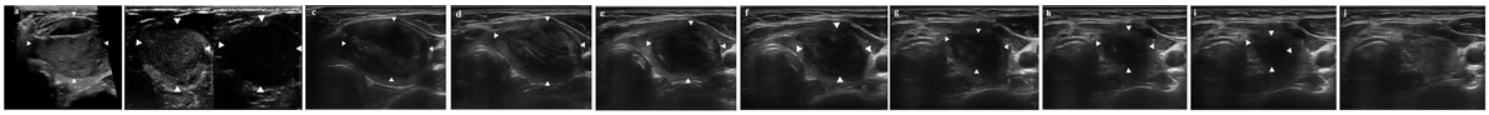

Figure 2

A 52-year-old woman with a diagnosis of a benign thyroid nodule in the left thyroid lobe. The images show the nodule before and during follow-up after MWA. 2a. Before MWA, the nodule measures 4.6 cm × 3.1 cm × 3.5 cm in size and 26.1 cm3 in volume.2b. CEUS shows uniform low enhancement of the nodule before MWA.2c. 1 month after MWA, the ablation area measures 4.4 cm ×2.8 cm × 3.3 cm in size and 21.3 cm3 in volume.2d. 3 months after MWA, the ablation area measures 3.8 cm × 2.2 cm × 3.3 cm and 14.4 cm3 in volume.2e. 6 months after MWA, the ablation area measures 3.4 cm × 2.1 cm × 2.3 cm and 8.6 cm3 in volume.2f. 12 months after MWA, the ablation area measures 3.0 cm × 1.8 cm × 2.0 cm and 5.7 cm3 in volume.2g. 18 months after MWA, the ablation area measures 2.5 cm × 1.3 cm × 1.5 cm and 2.6 cm3 in volume.2h. 24 months after MWA, the ablation area measures 1.7 cm × 1.0 cm × 1.4 cm and

1.2 cm3 in volume.2i. 30 months after MWA, the ablation area measures 1.3 cm × 0.6 cm × 1.0 cm and 0.4 cm3 in volume.2j. 36 months after MWA, the ablation area has vanished.