

# Development of an Algorithm To Differentiate Uterine Sarcoma From Fibroid Using MRI and LDH Levels

**Ayako Suzuki**

Kindai University Faculty of Medicine

**Aki Kido**

Kyoto University

**Mitsuru Matsuki**

Kindai University Faculty of Medicine

**Yasushi Kotani** (✉ [y-kotani@med.kindai.ac.jp](mailto:y-kotani@med.kindai.ac.jp))

Kindai University Faculty of Medicine

**Kosuke Murakami**

Kindai University Faculty of Medicine

**Yukio Yamanishi**

Japanese Red Cross Wakayama Medical Center

**Isao Numoto**

Kindai University Faculty of Medicine

**Hidekatsu Nakai**

Kindai University Faculty of Medicine

**Tomoyuki Otani**

Kindai University Faculty of Medicine

**Ikuo Konishi**

Kyoto University

**Masaki Mandai**

Kyoto University

**Noriomi Matsumura**

Kindai University Faculty of Medicine

---

## Research Article

**Keywords:** algorithm, uterine sarcoma, fibroid, MRI

**Posted Date:** November 30th, 2021

**DOI:** <https://doi.org/10.21203/rs.3.rs-1085919/v1>

**License:**  This work is licensed under a Creative Commons Attribution 4.0 International License.

[Read Full License](#)

---

# Abstract

This study aimed to establish an evaluation method for detecting uterine sarcoma with 100% sensitivity using MRI and serum LDH levels. One evaluator reviewed the MRI images and LDH values of a total of 1801 cases, including 36 cases of uterine sarcoma and 1765 cases of uterine fibroids. The reproducibility of the algorithm was also examined using a test set of 61 cases, including 14 cases of uterine sarcoma, by four evaluators with different imaging experience and abilities. From the MRI images and LDH values of 1801 cases of uterine sarcoma and uterine fibroid, we found that all sarcomas were included in the group with high T2WI and either high T1WI, unclear margin, or high LDH value. In addition, when cases with DWI were examined, all sarcomas had high DWI. Among the 36 sarcoma cases, the group with positive findings in T2WI, T1WI, margin, and serum LDH levels all had a poor prognosis ( $p = 0.015$ ). The reproducibility of the algorithm was examined by four evaluators, and the sensitivity of sarcoma detection ranged from 71–93%. We established an algorithm that is not uterine sarcoma if tumors in the myometrium with low T2WI and DWI.

## Introduction

Uterine fibroids are a frequent benign disease with a predilection for sexual maturity. Myomectomy is the surgical treatment of choice for uterine fibroids to preserve fertility, and in recent years laparoscopic myomectomy is often performed. A power morcellator has been commonly used during laparoscopic myomectomy<sup>1</sup>. However, if uterine sarcoma, which is latent in a very rare frequency, cannot be distinguished preoperatively, surgery using a morcellator in the preoperative diagnosis of uterine fibroids may lead to dissemination of sarcoma cells in the abdominal cavity, which may be lethal<sup>1</sup>. For this reason, the US Food and Drug Administration guidelines recommend against the use of laparoscopic power morcellation for tumors diagnosed as uterine fibroids<sup>1–4</sup>.

On the other hand, many reports suggest that uterine sarcoma can be differentiated from leiomyoma by magnetic resonance imaging (MRI). Characteristic findings of uterine sarcoma include high T2 weighted Image (WI), diffusion weighted image (DWI), and T1WI, and unclear margins<sup>5</sup>. Recently, there have been studies to differentiate atypical degenerative myoma from sarcoma, based on the consensus that it is easy to differentiate typical myoma from sarcoma<sup>6</sup>. Some studies have tried to quantify signal intensity to find the cut-off, and others have tried to introduce machine learning<sup>7,8</sup>. In addition to imaging findings, it is well known that Lactate Dehydrogenase (LDH) levels are often elevated in uterine sarcoma<sup>9</sup>.

However, most of the studies have conducted retrospective studies with small sample sizes. The usefulness of the procedure has not been examined from the viewpoint of excluding uterine sarcoma and safely performing surgery as uterine fibroids. In this sense, we thought that the research needed in gynecological practice is to determine the negative findings to determine that the disease can be safely treated as a myoma, rather than to look for positive findings of sarcoma to improve the percentage accuracy of differentiation from degenerative myoma.

We aimed to qualitatively evaluate simple MRI images and LDH levels of a total of 1801 uterine fibroids and uterine sarcomas in the simplest way possible and to create an algorithm for detecting uterine sarcomas with 100% sensitivity.

## Results

### **Determination of evaluation criteria for T2WI and DWI by review of previous reports**

First, we reviewed previous reports and determined the criteria for evaluating T2WI. In the previous reports, most of them compared T2WI with outer myometrium when evaluating tumorous lesions, and there were seven papers with 46 cases; in 2007, the skeletal muscle was found to have a high T2WI<sup>10-17</sup>. However, in 2007, one case of leiomyosarcoma was reported that was higher than skeletal muscle but lower than myometrium, and later, one of three cases of leiomyosarcoma was iso~low (“iso~low” is described as “low”) compared with outer myometrium<sup>17</sup>. For ESS, there was a report that only one out of two patients was high compared to outer myometrium. In terms of ESS, there were two reports that only one of two cases was high compared to outer myometrium<sup>17</sup>. Therefore, using outer myometrium as a criterion, it is impossible to detect 100% of uterine sarcoma. On the other hand, the signal intensity of skeletal muscle was lower than that of outer myometrium, and the sarcoma reported so far had a higher signal intensity than that of skeletal muscle in all cases (Table 2).

Regarding DWI, when the criterion for high DWI was signal intensity greater than or equal to the endometrium, one of four leiomyosarcoma patients and two of 14 patients had low DWI<sup>11,15</sup>. On the other hand, when myometrium, which has a lower signal intensity than endometrium, was used as the criterion, all cases of sarcoma reported so far had a high signal intensity (Table 3).

T2WI was defined as high when the signal intensity was higher than that of skeletal muscle, and DWI was defined as high when the signal intensity was higher than that of the myometrium. DWI was defined as high signal intensity over myometrium.

Margin and T1WI have not been reported to provide 100% sensitivity in the diagnosis of sarcoma and were used according to previous reports (see Methods)<sup>18,19</sup>.

### **Establishment of a sarcoma diagnosis algorithm**

A.S. (the first author of this paper) then developed an algorithm to diagnose sarcoma with 100% sensitivity. Eighteen sarcomas were found in the Kyoto cohort of 1387 cases, and all of them had high T2WI (as expected) when compared to skeletal muscle. In addition, sarcomas always met one of the following criteria: high T1WI, unclear margin, or high LDH. Therefore, high T2WI and one of the other three factors were defined as the algorithm for picking up sarcomas with 100% sensitivity. On the other hand, out of 1369 uterine fibroids, 407 had high T2WI, and only 26 were positive for the algorithm (Fig. 1A).

Furthermore, when the Kindai cohort I was evaluated in the same way, among 293 cases, nine cases of sarcoma were algorithm positive, and 29 cases of myoma were algorithm positive (Fig. 1B). In the Kyoto cohort and Kindai cohort I, the overall percentage of algorithm-positive cases was 4.5%, including 2.9% for myoma and 1.6% for sarcoma (Fig. 1C). The sensitivity of the sarcoma diagnosis was 100%, specificity 97%, positive predictive value 36%, and negative predictive value 100%.

Finally, Kindai cohort II was also analyzed. Of the 10 cases diagnosed as sarcoma by the pathology report, nine were algorithm positive, but one was algorithm negative. The pathology review of the one case changed the diagnosis to myoma. On the other hand, of 102 randomly selected myomas, nine were algorithm positive (Fig. 1D).

### **Analysis of algorithm positive cases**

We identified positive cases from all four cohorts (Kyoto cohort, Kindai cohort I and II) (n = 94). We found that (i) the group with positive results for all four algorithm factors had only leiomyosarcoma or high-grade ESS and no myoma. (ii) The group with positive results for the three imaging factors of the algorithm had mostly low-grade ESS and only one myoma. (iii) The remaining group had more myomas (Fig. 2A). Prognostic analysis showed that the prognosis of group (i) was poor (p = 0.015). In addition, when we examined the 40 cases with available DWI images among the algorithm-positive cases, sarcomas were found to be high DWI in all cases (Fig. 2C).

### **Evaluation of inter-examiner agreement**

Next, using the algorithm established by A.S. (reader a), we examined whether other readers could diagnose sarcoma as algorithm positive in a test set of 61 cases, including 14 cases of sarcoma [Fig. 3, Table 4, S1-61 (Age, Pathology, Final results of T2WI, T1WI, DWI, and margin discussed by five doctors, LHD value)]. As a result, readers b, c, and d diagnosed sarcoma as 100% high in both T2WI and DWI, while the match rate with reader a for T1WI and margin was only 43–86%. For readers b, c, and d, the positive rate was 93% (13/14), which was the same even when low DWI was excluded. In contrast, readers b, c, and d in leiomyoma had lower concordance rates with reader a than sarcoma, ranging from 53% to 62% for T2WI and 62% to 83% for DWI. Reader e had a low algorithm positivity rate of 71% (10/14) for sarcoma but a high concordance rate of 93% (13/14) with the original diagnostic report.

The sarcoma for which readers b, c, d, and e failed to show a positive algorithm was diagnosed as sarcoma by preoperative biopsy because of a vaginal bleeding tumor at the time of initial diagnosis. In addition, the sarcoma for which readers c and d failed to show a positive algorithm had an LDH level of 217 IU/L (normal value  $\leq$  222 IU/L) at the time of MRI scan but rose to 268 IU/L before surgery and eventually showed a positive algorithm. Therefore, when combined with the clinical information, the results of readers b, c, and d were sufficient to suspect sarcoma preoperatively in all sarcoma cases. Reader e showed that if “high T2WI or high DWI” was considered as “high T2WI”, the preoperative increase in LDH level would have resulted in a positive algorithm in all cases. If “high T2WI or high DWI” is considered to be “high T2WI”, all patients would have been positive for the algorithm due to increased

preoperative LDH levels. In actual clinical practice, in two of the three cases of myoma in the reading report, the attending physician judged the mass to be myoma, and over the next few months, the mass grew and was subsequently diagnosed as sarcoma.

### **Treatment strategies for intramyometrial masses using sarcoma diagnostic algorithms**

Finally, based on the above data and taking into account the reproducibility of the diagnosis, we have presented our ideas on how to use sarcoma diagnostic algorithms to safely treat intramuscular masses (Fig. 4).

## **Discussion**

To establish a reproducible evaluation method for MRI, it is essential to make the evaluation criteria simple and clear. In many papers, the criterion for evaluating T2WI to diagnose uterine sarcoma has been whether or not the signal intensity is higher than that of the outer myometrium (Table 2). However, when the signal intensity of T2WI is compared with that of the outer myometrium, it is often low in sarcoma<sup>17</sup>. Furthermore, we recently found that most of the low-grade ESS are low T2WI when compared to outer myometrium (data not shown, paper in submission). In addition, when the criterion for DWI is endometrium, sarcoma that is often lower than that has been reported<sup>13,15</sup>. Similarly, in the present study, we found sarcomas with low T2WI compared to outer myometrium and low DWI compared to the endometrium (S 1-61). These criteria have been used in previous reports because many studies have tried to clarify the difference between degenerated leiomyoma and sarcoma, which have relatively high T2WI and DWI signal intensity, rather than aiming for 100% sensitivity in sarcoma detection. The T2WI signal intensity of the myometrium varies greatly with the menstrual cycle, while that of skeletal muscle is constant and lower than that of the myometrium<sup>8,20</sup>. Therefore, we used skeletal muscle as the reference for T2WI and myometrium as the reference for DWI and were able to detect sarcoma with 100% sensitivity in four patients, except for reader e (Fig. 3). Considering the risk of parasitic myoma, a power morcellator may be acceptable while using a containment system<sup>1-4</sup>.

In the present study, there were no cases of sarcoma in the reader group when both T2WI and DWI were high, but T1WI was low, the margin was clear, and LDH was low; however, in the reader b, c, and d groups, there was one case of sarcoma in each group (Fig. 3). These “mixed” sarcoma cases were cases that could have been diagnosed with suspected sarcoma preoperatively due to the clinical course, but it would be dangerous to assume that sarcoma is not included in this category at this time. Therefore, minimally invasive surgery (MIS) using a power morcellator should be avoided as much as possible after discussing this with the patient. If it is done, it should be done carefully using a containment system. And if both T2WI and DWI are high, with either high T1WI, unclear margin, or high LDH, sarcoma should be suspected as algorithm positive (Fig. 1). In such cases, guidelines and MIS should not be performed as a “case of suspected malignancy”<sup>1-4</sup>. In particular, if all three imaging findings are positive, the possibility of sarcoma is extremely high, and if LDH is high, the prognosis may be poor (Fig. 2). Consistent with our results, it has been reported that elevated LDH expression in uterine sarcoma correlates with poor

prognosis<sup>23</sup>. Thus, our simple algorithm can be reproduced even by non-specialists in gynecological MRI imaging and is directly relevant to medical treatment policy (Fig. 4).

The limitations of this study are: (i) it is a retrospective study, (ii) the sample size is relatively small to verify the high sensitivity of detection, as there were only 36 cases of sarcoma in the cohort, while there were 1801 cases in the entire cohort, and (iii) the data are heterogeneous, as we used images from an older era. (iv) Smooth muscle tumour of uncertain malignant potential was excluded, and (v) the sensitivity of the algorithm for sarcoma detection was not 100% in the study of interobserver agreement. In the present study, even when limited to sarcoma, the rate of agreement in evaluating individual factors was low, especially for margin (Table 4). One of the reasons for this result was that the criteria were communicated to the narrative and evaluated based on it instead of using actual MRI images in the training set. In Japan, the number of MRIs per capita is much larger than in other countries, and almost all cases of surgery for the diagnosis of uterine fibroids or uterine sarcoma are performed preoperatively with MRI without contrast<sup>22</sup>.

In conclusion, we have proposed the first diagnostic algorithm to identify sarcoma close to 100% sensitivity. Once this algorithm is established and commonly used, it is expected to minimize the risk of latent uterine sarcoma and allow safe treatment, including MIS.

## Materials And Methods

### Study population

In this study, we enrolled patients who underwent surgery for tumors larger than 3 cm in the myometrium and underwent MRI before treatment and were pathologically diagnosed as leiomyosarcoma, low or high-grade endometrial stromal sarcoma (ESS), or leiomyoma. The Kyoto cohort was conducted at Kyoto university hospital from January 1986 to March 2005. The Kyoto cohort consisted of sarcoma (n = 18) and leiomyoma (n = 1369) treated at Kyoto university hospital between January 1986 and March 2005. The leiomyoma group included one case of postoperative parasitic leiomyoma. In the Kyoto cohort and Kindai cohort I, all patients who fulfilled the criteria for leiomyoma and sarcoma were included in the study. Ten patients who were treated at Kindai university hospital from January 2014 to December 2018 and diagnosed with sarcoma (1 case later became leiomyoma as described in Results) were included in the study, including one case that later became a leiomyoma) and randomly selected leiomyomas of the same period (n = 102).

This study was conducted under the auspices of Kindai University (approval number R02-036) and Kyoto University (approval number G288). All research was performed in accordance with Ethical Guidelines for Medical and Health Research Involving Human Subjects. All study subjects provided informed consent and assent in principle, but those who could not be contacted were given the opportunity to refuse to participate in the study by opting out. Those who refused to give consent were excluded from the study.

### MRI protocol

## **Kyoto University**

Magnetic resonance imaging scanning was conducted using a 1.5-T MR imaging system (Signa; GE Medical Systems, Milwaukee, USA. or Symphony; Siemens Healthineers, Erlangen, Germany) equipped with a phased-array coil. Routine clinical sequences included axial and sagittal T2WI (Fast Spin Echo) and sagittal T1WI (spin echo). Detailed parameters are shown in Table 1. Before MRI examination, 20 mg of butyl scopolamine (Buscopan; Nippon Boehringer Ingelheim, Tokyo, Japan) was administered intramuscularly to reduce bowel motion, unless contraindicated.

## **Kindai University**

Magnetic resonance imaging scanning was conducted using 1.5-T MR imaging systems (Signa HD xt; GE Healthcare, Milwaukee, USA, or Intera Achieva, Philips Healthcare, Best, the Netherlands) equipped with phased array coils. Routine clinical sequences included T1-weighted spin-echo (SE) or fast SE (FSE) images in axial or sagittal planes and T2-weighted FSE images in axial and sagittal planes. Detailed parameters are shown in Table 1.

## **Review of the literature to determine the evaluation criteria for T2WI or DWI**

We searched PubMed for “uterine sarcoma MRI” and identified 384 articles as of February 2021. Among these articles, 13 original papers that evaluated uterine leiomyosarcoma or ESS by specifying what they compared to in T2WI or DWI were included in the analysis.

## **The setting of evaluation criteria**

On T2WI, the lesions were classified according to the Oguchi type classification, which we proposed previously<sup>23</sup>. In T2WI, tumorous lesions other than degenerated areas were evaluated, and if the signal intensity was clearly higher than that of skeletal muscle, the case was classified as high T2WI, and if it was lower than that of skeletal muscle, as low T2WI. Tumors with high T2WI are consistent with tumors classified as type 4 or 5 in the Oguchi type classification, which we proposed previously<sup>23</sup>. On T1, the signal intensity (SI) of skeletal muscle was set as the reference standard<sup>18</sup>. Therefore, ‘high SI’ was defined as higher SI than skeletal muscle, and ‘low SI’ was similar to or lower SI than skeletal muscle. On DWI, the reference standard of SI was normal uterine outer myometrium and evaluated in  $b = 1000$  s/mm<sup>2</sup>. Then, ‘high SI’ was defined in case of similar to or higher than normal uterine outer myometrium. If SI was high because of hemorrhage, it was evaluated as ‘high SI’. Regarding tumor border evaluation, it was defined as ‘clear’ when the tumor margin was definitely traced<sup>24</sup>. The LDH value was determined by whether the value at the time of the MRI scan and the most recent value was higher than the standard institutional value. When multiple uterine fibroids were found, the lesion larger than 3 cm and with high T2WI signal intensity was adopted.

## **Evaluation method of inter-examiner agreement**



Author A.S. (reader a), an obstetrician and gynecologist with more than 20 years of experience, who has knowledge in this field and has written a review paper, evaluated the images of all study cases and developed the diagnostic algorithm<sup>5</sup>. For the test set to evaluate the inter-examiner agreement, we randomly selected 31 leiomyomas with high T2WI (including 14 algorithm-positive cases) and 16 leiomyomas with low T2WI (including 16 algorithm-positive cases), in addition to 14 sarcoma cases with available DWI images in the Kindai cohort I and II. A.S. informed the other examiners of the narrative method for T2WI, T1WI, and DWI.

Reader b was a diagnostic radiologist with more than 20 years of experience, specializing in gynecology. Reader c was a fellow in diagnostic radiology with less than 5 years of experience. Reader d was a gynecologist with 18 years of experience. Reader e was an obstetrician with 15 years of experience. Reader a and d knew the clinical information. Reader b, c, and e were not involved in the diagnosis or treatment of any of the cases in the Kindai cohort. Reader b, c, and e had all the clinical information, including pathology results, LDH levels, and age. All clinical information, including pathology results, LDH levels, and age, were blinded.

### **Pathology review**

In this cohort, a case of uterine sarcoma, which was thought to be incorrectly pathologically diagnosed, was reviewed by Dr. Sachiko Minamiguchi, a pathologist specializing in gynecologic oncology at a different institution from A.S. and who was not a co-author of this article. The pathology was reviewed by Dr. Sachiko Minamiguchi, a pathologist specializing in gynecologic tumors who belongs to a different institution from A.S. and is not a co-author of this paper.

### **Statistical analysis**

Survival analysis was performed by log-rank test. Statistical analysis was performed using Graphpad Prism version 9.0, and  $p < 0.05$  was considered statistically significant.

## **Declarations**

### **Acknowledgement**

Dr. Sachiko Minamiguchi of Kyoto University Department of Diagnostic Pathology performed the pathology review. Dr. Takefumi Hamakawa, Department of Radiology, Kindai University, evaluated the images as a volunteer for the interobserver agreement. We thank them for their cooperation.

### **Author contributions**

Ayako Suzuki: Concept and design, data collection, data analysis, article writing, approved the final version.

Aki Kido: Data collection, data analysis, article writing, approved the final version.

Mitsuru Matsuki: Data collection, data analysis, article writing, approved the final version.

Yasushi Kotani: Data collection, data analysis, article writing, approved the final version.

Kosuke Murakami: Data analysis, article writing, approved the final version.

Yukio Yamanishi: Data collection, data analysis, article writing, approved the final version.

Isao Numoto: Data analysis, article writing, approved the final version.

Hidekatsu Nakai: Data analysis, article writing, approved the final version.

Tomoyuki Otani: Data collection, data analysis, article writing, approved the final version.

Ikuo Konishi: Supervision, article writing, approved the final version.

Masaki Mandai: Supervision, article writing, approved the final version.

Noriomi Matsumura: Data analysis, article writing, approved the final version.

### **Declaration of Competing Interest**

The authors report no conflict of interest.

## **References**

1. Glaser, L. M., Friedman, J., Tsai, S., Chaudhari, A. & Milad, M. Laparoscopic myomectomy and morcellation: A review of techniques, outcomes, and practice guidelines. *Best Pract. Res. Clin. Obstet. Gynaecol*, **46**, 99–112 (2018).
2. Parker, W. H. *et al.* U.S. Food and Drug Administration's Guidance Regarding Morcellation of Leiomyomas: Well-Intentioned, But Is It Harmful for Women? *Obstet. Gynecol*, **127**, 18–22 (2016).
3. Halaska, M. J. *et al.* ESGO Council, European Society of Gynecological Oncology Statement on Fibroid and Uterine Morcellation. *Int. J. Gynecol. Cancer*, **27**, 189–192 (2017).
4. ACOG Committee Opinion No. 770: Uterine Morcellation for Presumed Leiomyomas. *Obstet. Gynecol*, **133**, e238–e248 (2019).
5. Suzuki, A. *et al.* Differential Diagnosis of Uterine Leiomyoma and Uterine Sarcoma using Magnetic Resonance Images: A Literature Review. *Healthcare*, **7**, 158 (2019).
6. Bi, Q. *et al.* Utility of Clinical Parameters and Multiparametric MRI as Predictive Factors for Differentiating Uterine Sarcoma From Atypical Leiomyoma. *Acad. Radiol*, **25**, 993–1002 (2018).
7. Malek, M. *et al.* Investigating the diagnostic value of quantitative parameters based on T2-weighted and contrast-enhanced MRI with psoas muscle and outer myometrium as internal references for differentiating uterine sarcomas from leiomyomas at 3T MRI. *Cancer Imaging*, **19**, 20 (2019).

8. Nakagawa, M. *et al.* Machine Learning to Differentiate T2-Weighted Hyperintense Uterine Leiomyomas from Uterine Sarcomas by Utilizing Multiparametric Magnetic Resonance Quantitative Imaging Features. *Acad. Radiol*, **26**, 1390–1399 (2019).
9. Glorie, N., Baert, T., Bosch, V. A. N. D. E. N., Coosemans, A. N. & T. & Circulating Protein Biomarkers to Differentiate Uterine Sarcomas from Leiomyomas. *Anticancer Res*, **39**, 3981–3989 (2019).
10. Tanaka, Y. O., Nishida, M., Tsunoda, H., Okamoto, Y. & Yoshikawa, H. Smooth muscle tumors of uncertain malignant potential and leiomyosarcomas of the uterus: MR findings. *J. Magn. Reson. Imaging*, **20**, 998–1007 (2004).
11. Tamai, K. *et al.* The utility of diffusion-weighted MR imaging for differentiating uterine sarcomas from benign leiomyomas. *Eur. Radiol*, **18**, 723–730 (2008).
12. Namimoto, T. *et al.* Combined use of T2-weighted and diffusion-weighted 3-T MR imaging for differentiating uterine sarcomas from benign leiomyomas. *Eur. Radiol*, **19**, 2756–2764 (2009).
13. Tasaki, A. *et al.* Differential diagnosis of uterine smooth muscle tumors using diffusion-weighted imaging: correlations with the apparent diffusion coefficient and cell density. *Abdom. Imaging*, **40**, 1742–1752 (2015).
14. Lin, G. *et al.* Comparison of the diagnostic accuracy of contrast-enhanced MRI and diffusion-weighted MRI in the differentiation between uterine leiomyosarcoma / smooth muscle tumor with uncertain malignant potential and benign leiomyoma. *J. Magn. Reson. Imaging*, **43**, 333–342 (2016).
15. Li, H. M. *et al.* Diffusion-Weighted Imaging for Differentiating Uterine Leiomyosarcoma From Degenerated Leiomyoma. *J. Comput. Assist Tomogr*, **41**, 599–606 (2017).
16. Takeuchi, M., Matsuzaki, K. & Harada, M. Clinical utility of susceptibility-weighted MR sequence for the evaluation of uterine sarcomas. *Clin. Imaging*, **53**, 143–150 (2019).
17. Lakhman, Y. *et al.* Differentiation of Uterine Leiomyosarcoma from Atypical Leiomyoma: Diagnostic Accuracy of Qualitative MR Imaging Features and Feasibility of Texture Analysis. *Eur. Radiol*, **27**, 2903–2915 (2017).
18. Ando, T. *et al.* Uterine smooth muscle tumours with hyperintense area on T1 weighted images: differentiation between leiomyosarcomas and leiomyomas. *Br. J. Radiol*, **91**, 20170767 (2018).
19. Cornfeld, D. *et al.* MRI appearance of mesenchymal tumors of the uterus. *Eur. J. Radiol*, **74**, 241–249 (2010).
20. Haynor, D. R. *et al.* Changing appearance of the normal uterus during the menstrual cycle: MR studies. *Radiology*, **161**, 459–462 (1986).
21. Song, K. J. *et al.* Expression and prognostic value of lactate dehydrogenase-A and -D subunits in human uterine myoma and uterine sarcoma. *Med. (Baltim)*, **97**, e0268 (2018).
22. Yamashita, Y. *et al.* The essence of the Japan Radiological Society/Japanese College of Radiology Imaging Guideline. *Jpn. J. Radiol*, **34**, 43–79 (2016).
23. Oguchi, O. *et al.* Prediction of histopathologic features and proliferative activity of uterine leiomyoma by magnetic resonance imaging prior to GnRH analogue therapy: correlation between T2-weighted

- images and effect of GnRH analogue. *J. Obstet. Gynaecol*, **21**, 107–117 (1995).
24. Cornfeld, D. *et al.* MRI appearance of mesenchymal tumors of the uterus. *Eur. J. Radiol*, **74**, 241–249 (2010).
  25. Fukunishi, H. *et al.* Unsuspected uterine leiomyosarcoma: magnetic resonance imaging findings before and after focused ultrasound surgery. *Int. J. Gynecol. Cancer*, **17**, 724–728 (2007).
  26. Thomassin-Naggara, I. *et al.* How to differentiate benign from malignant myometrial tumours using MR imaging. *Eur. Radiol*, **23**, 2306–2314 (2013).
  27. Sato, K., Yuasa, N., Fujita, M. & Fukushima, Y. Clinical application of diffusion-weighted imaging for preoperative differentiation between uterine leiomyoma and leiomyosarcoma. *Am. J. Obstet Gynecol.* **210**, 368.e1-368.e8 (2014)
  28. Sumi, A. *et al.* Assessment of MR Imaging as a Tool to Differentiate between the Major Histological Types of Uterine Sarcomas. *Magn. Reson. Med. Sci*, **14**, 295–304 (2015).

## Tables

Due to technical limitations, table 1 is only available as a download in the Supplemental Files section.

Table 2  
The signal intensity of uterine sarcoma by T2WI.

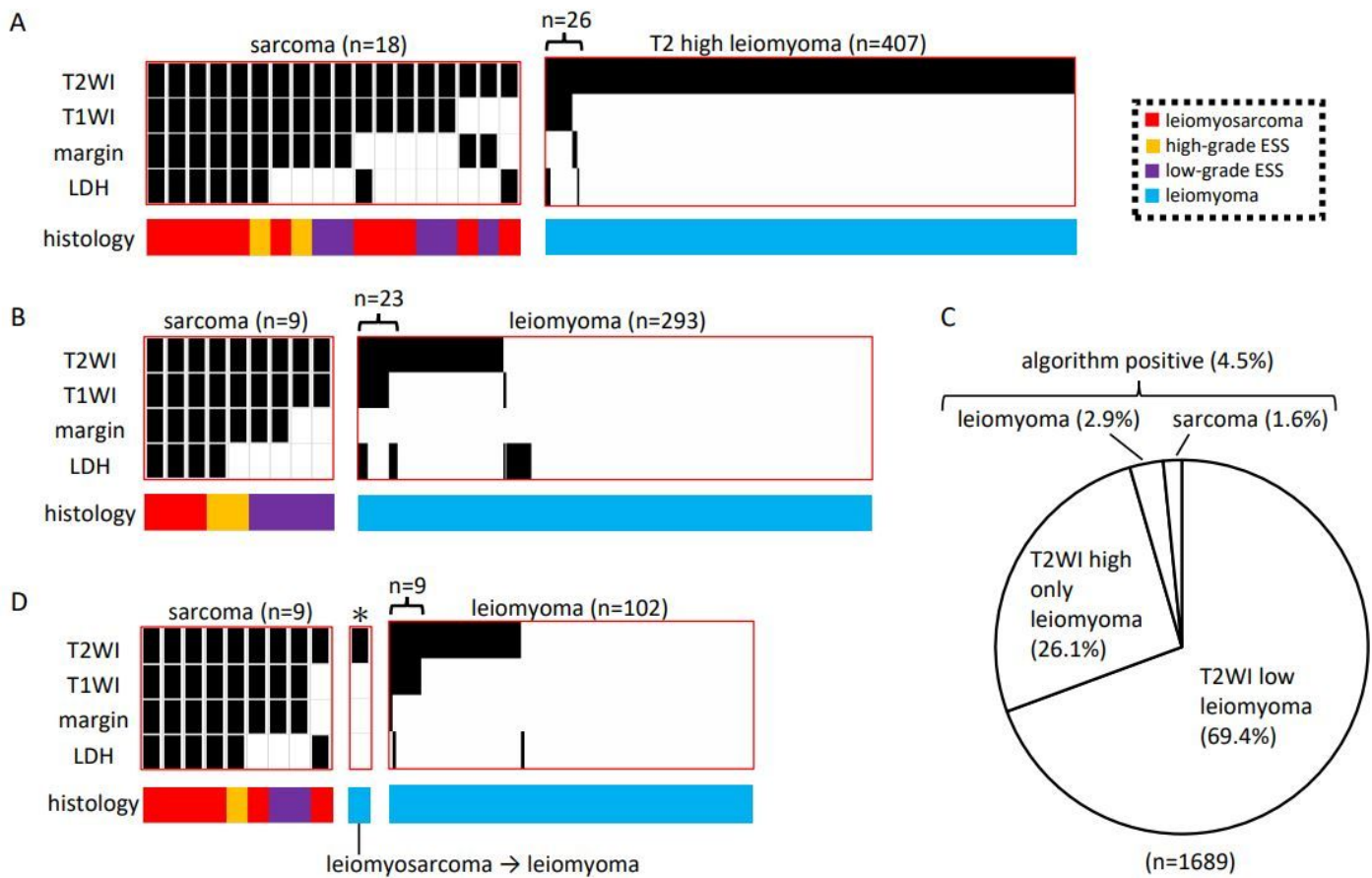
| comparison with  | histology | high | low  | year                            | Reference                                |
|------------------|-----------|------|------|---------------------------------|--|
| outer myometrium | LMS       | 9    | 0    | 2004                            | Tanaka YO et al. <sup>10</sup>           |
|                  |           | 0    | 1    | 2007                            | Lakhman Y et al. <sup>17</sup>           |
|                  |           | 6    | 0    | 2008                            | Tamai K et al. <sup>11</sup>             |
|                  |           | 3    | 1    | 2010                            | Cornfeld D et al. <sup>24</sup>          |
|                  |           | 4    | 0    | 2009                            | Namimoto T et al. <sup>12</sup>          |
|                  |           | 6    | 0    | 2015                            | Tasaki A et al. <sup>13</sup>            |
|                  |           | 6    | 0    | 2016                            | Lin G et al. <sup>14</sup>               |
|                  |           | 9    | 10   | 2017                            | Lakhman Y et al. <sup>17</sup> (a)       |
|                  |           | 11   | 8    | 2017                            | Lakhman Y et al. <sup>17</sup> (b)       |
|                  |           | 16   | 0    | 2017                            | Li HM et al. <sup>15</sup>               |
|                  | 3         | 0    | 2019 | Takeuchi M et al. <sup>16</sup> |  |
|                  | ESS       | 1    | 1    | 2008                            | Tamai K et al. <sup>11</sup>             |
|                  |           | 1    | 1    | 2010                            | Cornfeld D et al. <sup>24</sup>          |
|                  |           | 2    | 0    | 2009                            | Namimoto T et al. <sup>12</sup>          |
| 1                |           | 0    | 2019 | Takeuchi M et al. <sup>16</sup> |  |
| skeletal muscle  | LMS       | 1    | 0    | 2007                            | Fukunishi H et al. <sup>25</sup>         |
|                  |           | 3    | 0    | 2013                            | Thomassin-Naggara I et al. <sup>26</sup> |
|                  | ESS       | 11   | 0    | 2013                            | Thomassin-Naggara I et al. <sup>26</sup> |

Table 3  
The signal intensity of uterine sarcoma by DWI.

| comparison with | histology | high | low | year | Reference                       |
|-----------------|-----------|------|-----|------|---------------------------------|
| endometrium     | LMS       | 4    | 1   | 2008 | Tamai K et al. <sup>11</sup>    |
|                 |           | 5    | 0   | 2014 | Sato K et al. <sup>27</sup>     |
|                 |           | 14   | 2   | 2017 | Li HM et al. <sup>15</sup>      |
|                 | ESS       | 2    | 0   | 2008 | Tamai K et al. <sup>11</sup>    |
| myometrium      | LMS       | 6    | 0   | 2015 | Tasaki A et al. <sup>13</sup>   |
|                 |           | 6    | 0   | 2016 | Lin G et al. <sup>14</sup>      |
|                 |           | 3    | 0   | 2019 | Takeuchi M et al. <sup>16</sup> |
|                 | ESS       | 1    | 0   | 2019 | Takeuchi M et al. <sup>16</sup> |
| skeletal muscle | LMS       | 8    | 0   | 2015 | Sumi A et al. <sup>28</sup>     |
|                 | ESS       | 6    | 0   | 2015 | Sumi A et al. <sup>28</sup>     |

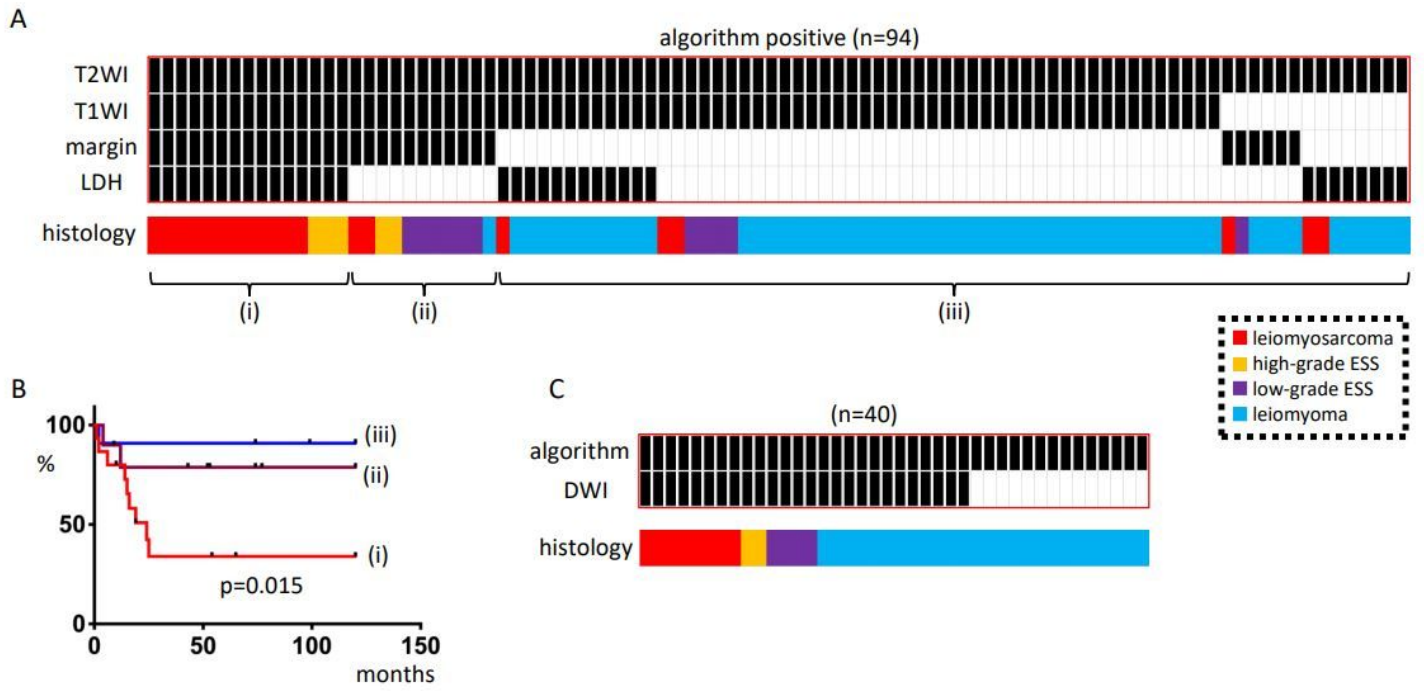
Due to technical limitations, table 4 is only available as a download in the Supplemental Files section.

## Figures



**Figure 1**

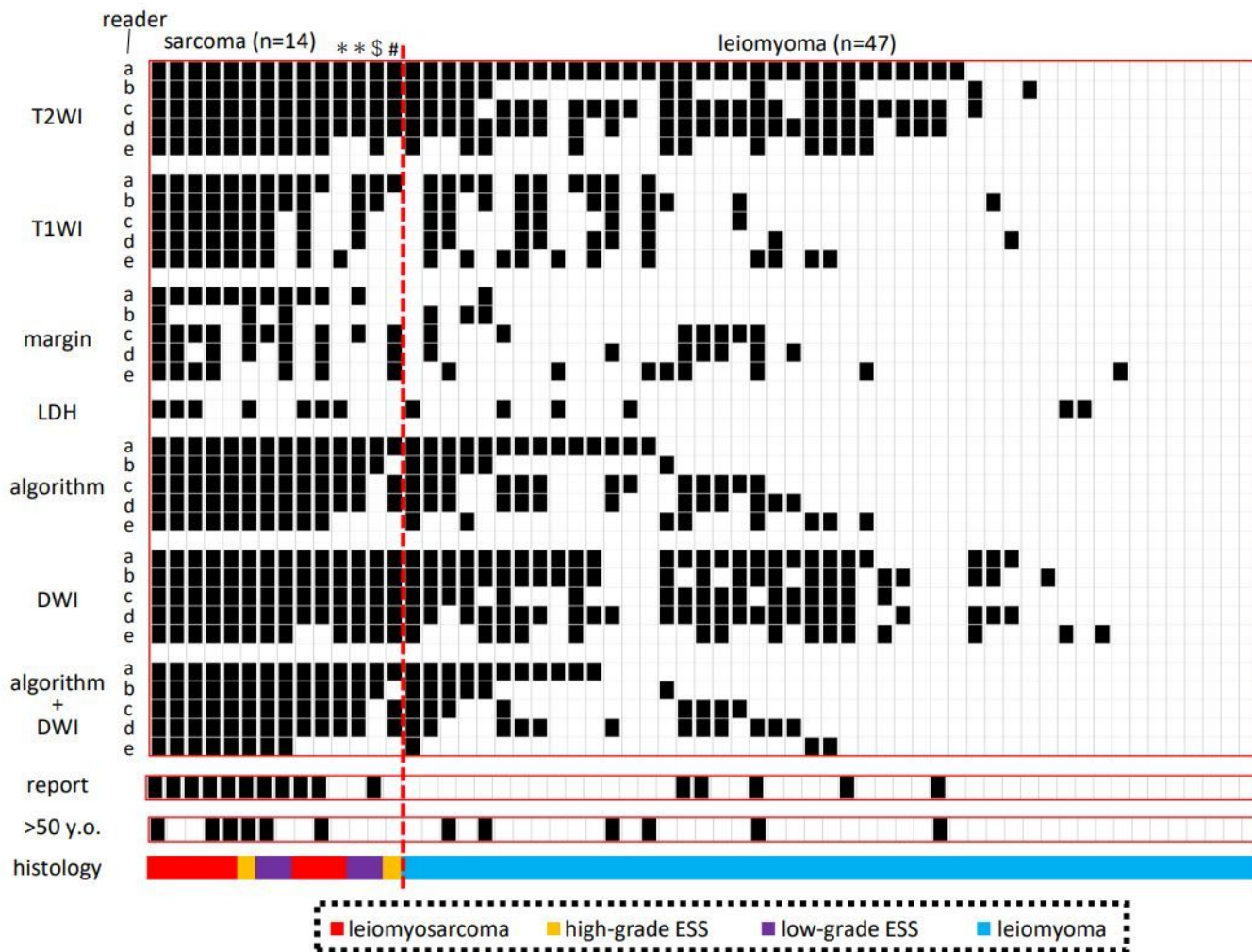
Differentiation of uterine sarcoma from uterine fibroids by MRI images and LDH levels. A) Analysis of the Kyoto cohort. All 18 sarcomas were T2 high, and the others were either T1 high, unclear margin, or high LDH (sarcoma diagnostic algorithm). Of the 1369 myomas, 407 were high T2. B) Kindai cohort I analysis. All nine sarcomas were algorithm positive, and 23 of 293 myomas were algorithm positive. c) Total of the Kyoto cohort and Kindai cohort I. Of 1689 cases, 4.5% were algorithm positive. d) Analysis of Kindai cohort II. D) Analysis of Kindai cohort II; one case was originally diagnosed as sarcoma but was found to be myoma by pathology review after algorithm negative. All other nine sarcomas were algorithm positive, and of 102 randomly selected uterine fibroids, nine were algorithm positive. Black in the heatmap indicates T2; high, T1; high, margin; unclear, LDH; high. The type of histology is indicated by color.



**Figure 2**

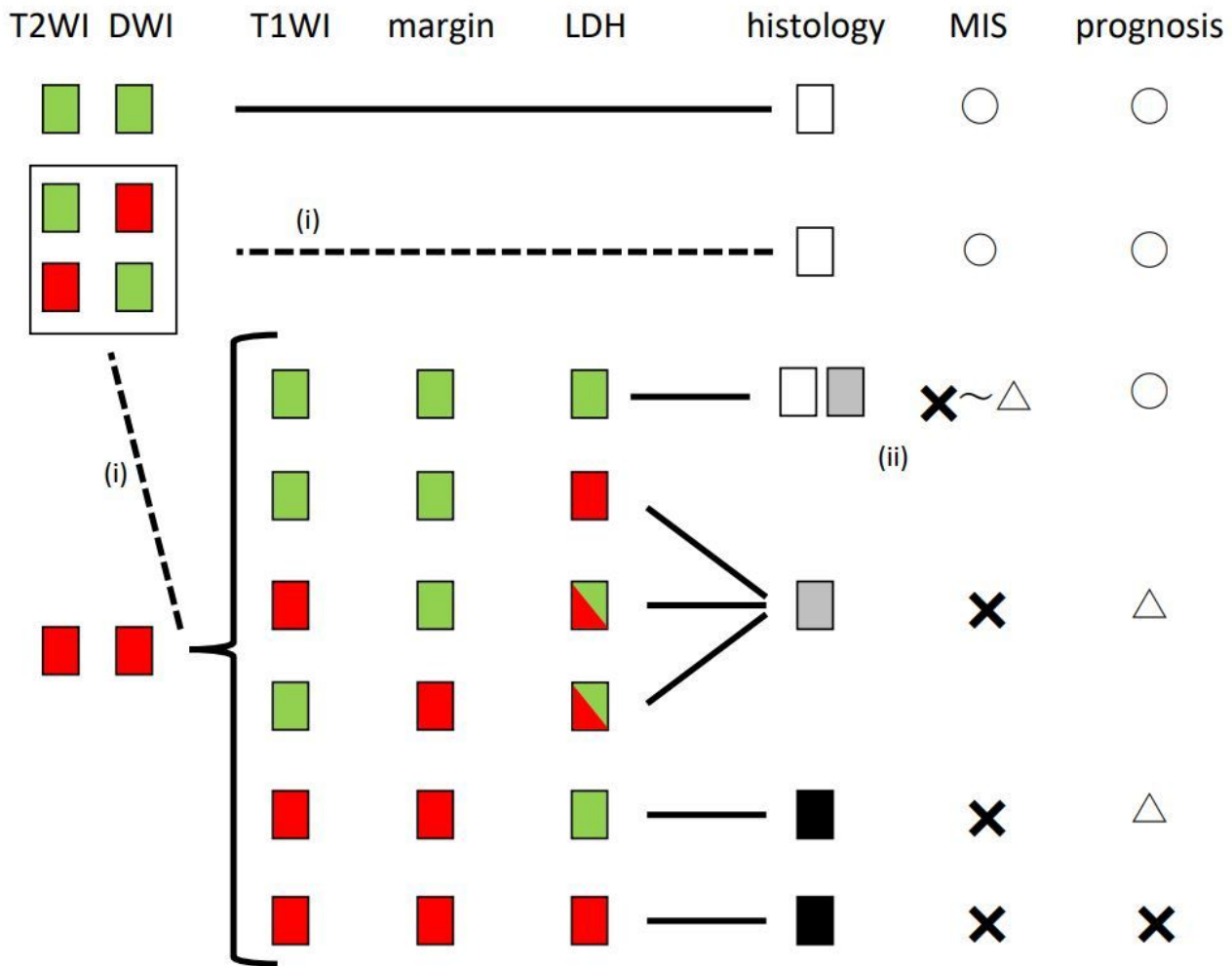
Analysis of algorithm-positive cases. A) Algorithm-positive cases in Kyoto cohort, Kindai cohort I, and Kindai cohort II (n = 94). The cases were divided into three groups: (i) all four factors of the algorithm were positive, (ii) three factors of the image were positive, and (iii) others. (ii) All but one were sarcomas; (iii) most were myomas, but some were sarcomas; B) Prognosis differed among the three groups, with (i) having the poorest prognosis; C) Forty of the algorithm-positive cases had available DWI, and DWI was high for all sarcomas. All sarcomas were DWI high. Heatmap shows cases with DWI high in black.





**Figure 3**

Verification of reproducibility of image evaluation. We selected sarcoma cases with available DWI from Kindai cohort I and II and randomly selected algorithm positive myoma, T2 high only myoma, and T2 low myoma, respectively. Algorithm + DWI was determined by taking DWI into account. The algorithm + DWI was determined by considering the DWI and a positive algorithm, but a low DWI was marked as negative in white. >50 y.o.; cases older than 50 years. The patient was followed up in the outpatient clinic for several months before surgery was performed. \$; Before surgery, LDH level was elevated, and both reader c and d were algorithmically positive. #; Tumor protruded vaginally, and sarcoma could be diagnosed preoperatively.



**Figure 4**

Evaluation method and treatment algorithm for intramuscular uterine masses. Red; High T2WI, high DWI, high T1WI, unclear margin, high LDH; green indicates low; histology: white for leiomyoma, grey for s/o sarcoma, black for sarcoma, For histology, white indicates leiomyoma, grey indicates s/o sarcoma, and black indicates sarcoma. MIS; minimally invasive surgery. (i) Normally, a low T2 or DWI indicates no sarcoma, but when evaluated by a non-gynecological MRI specialist, either or both may be positive. However, when evaluated by a non-gynecological MRI specialist, if either of them is positive, it is safe to treat it as a case where both are positive. (ii) If both T2WI and DWI are high and the other factors are negative, the result will be negative for the algorithm. However, the reproducibility of that assessment is not 100% and does not completely eliminate the suspicion of sarcoma. Morcellators should be avoided or at least used within a bag.

## Supplementary Files

This is a list of supplementary files associated with this preprint. Click to download.

- [1.docx](#)
- [2.docx](#)
- [3.docx](#)
- [4.docx](#)
- [5.docx](#)
- [6.docx](#)
- [7.docx](#)
- [8.docx](#)
- [9.docx](#)
- [10.docx](#)
- [11.docx](#)
- [12.docx](#)
- [13.docx](#)
- [14.docx](#)
- [15.docx](#)
- [16.docx](#)
- [17.docx](#)
- [18.docx](#)
- [19.docx](#)
- [20.docx](#)
- [21.docx](#)
- [22.docx](#)
- [23.docx](#)
- [24.docx](#)
- [25.docx](#)
- [26.docx](#)
- [27.docx](#)
- [28.docx](#)
- [29.docx](#)
- [30.docx](#)
- [31.docx](#)
- [32.docx](#)
- [33.docx](#)

- 34.docx
- 35.docx
- 36.docx
- 37.docx
- 38.docx
- 39.docx
- 40.docx
- 41.docx
- 42.docx
- 43.docx
- 44.docx
- 45.docx
- 46.docx
- 47.docx
- 48.docx
- 49.docx
- 50.docx
- 51.docx
- 52.docx
- 53.docx
- 54.docx
- 55.docx
- 56.docx
- 57.docx
- 58.docx
- 59.docx
- 60.docx
- 61.docx
- Table1.jpg
- Table4.jpg