

Royal Jelly ameliorates 6-mercaptopurine induced spermatogenesis impairment and testicular apoptosis by regulating PI3K/AKT pathway in male rats

Khalid Hashem (✉ khalidshaabanshashem@yahoo.com)

Beni Suef University <https://orcid.org/0000-0001-5303-4739>

Ahmed Z. Abdelazem

Beni Suef University

Naglaa W. Abdelbaky

Beni Suef University

Research

Keywords: 6MP, male infertility, testicular dysfunction, FSH, LH and Androgen receptor.

Posted Date: March 19th, 2020

DOI: <https://doi.org/10.21203/rs.2.20288/v2>

License: © ⓘ This work is licensed under a Creative Commons Attribution 4.0 International License.

[Read Full License](#)

Abstract

Testicular apoptosis is an obvious adverse effect of many chemotherapeutic agents. One of these chemotherapeutic drugs is 6-mercaptopurine (6MP) which has a powerful anticancer effect. On the contrary, it has an adverse effect on the male reproductive system. This study aimed to evaluate the prospective ameliorative effects of Royal Jelly (RJ) on 6MP induced testicular apoptosis and investigate the mechanistic pathway of protection. For this aim, forty male adult albino rats were divided into four equal groups (n= 10): control rats, RJ group (200 mg/kg.b.wt. of RJ for 30 day P.o.), 6MP group (5 mg/kg.b.wt of 6MP for 20 day P.o.), and RJ+6MP group pretreated with RJ (200 mg/kg.b.wt. for 10 day P.o.), and continued with 6MP (5 mg/kg.b.wt, P.o) for 20 day. After 30 days blood samples, epididymis and testis were collected to investigate sex hormones, sperm parameters, histological and molecular changes of testicular tissues, that include anti-oxidants activity, caspase-3, TNF- α , gene expression of Androgen receptors (AR) and P53 also protein concentration of PI3K, AKT, Nrf2 and HO1 were estimated. The results of our study revealed that Pretreatment of Royal Jelly (RJ) abrogated 6MP induced spermatogenesis impairment by ameliorating sperm count, motility and morphology, regulating AR mRNA expression and sex hormones levels. RJ ameliorated testicular damage of 6MP exposed rats through restoring testicular antioxidant/oxidative redox, inhibiting caspase-3 activity and P53 mRNA expression as well as regulation of PI3K, AKT, Nrf2 and HO1 protein levels. Our data concluded that RJ protected testicular tissue from 6MP induced apoptosis by regulation PI3K/AKT pathway.

1. Introduction

6-Mercaptopurine (6MP) was the first purine analog to prove beneficial for neoplastic diseases treatment (Whalen 2018). It is used in cancer therapy to maintain the remission of acute lymphoblastic leukemia (Stuckert, Schafer et al. 2019). 6MP has a potent powerful immunomodulatory effect in treatment of inflammatory bowel disease, systemic lupus erythromatosus, organ transplant rejection and rheumatoid arthritis (Mohammadi and Kassim 2019).

6MP mechanism of action is incorporation of 6- thiothiopyrimidine nucleotides into DNA during DNA synthesis process. The antagonistic effect of 6MP on purine bases could result in alteration in DNA-protein interaction or DNA mismatch repair, therefore induces cytotoxicity (Whalen 2018).

Efficacy of 6MP is associated with various adverse effects on body organs induced toxicity as hepatotoxicity (Wu, Shen et al. 2006), bone marrow suppression and infertility (Bendre, Shaddock et al. 2005). 6MP induced male reproductive organ toxicity include testicular atrophy, Leydig cell failure and spermatogenesis impairment (Morgan, Lynch et al. 2015).

Recent trends in treating diseases promote uses of natural products to protect the body against the adverse effects of some chemotherapeutic drugs (Golmohammadi, Sagha et al. 2019). Royal Jelly (RJ) is considered an effective adjuvant to chemotherapies. RJ is secreted by hypo-pharyngeal glands of worker honeybee and consider a principal food of queen honeybee, RJ components are important for cell growth

and tissue repair, it consists of water (50%–60%), proteins (18%), carbohydrates (15%), lipids (3%–6%), mineral salts (1.5%), and vitamins (Nagai and Inoue 2004). Previous studies reported that RJ can act as a potent anti-inflammatory and antioxidant when used as an adjuvant to certain drugs (Silici, Ekmekcioglu et al. 2009, Ghanbari, Nejati et al. 2016). RJ enhanced spermatogenesis and ameliorated the adverse effects some drugs on the reproductive organs (Jalali, Najafi et al. 2015, Temamoğulları, Aral et al. 2018). The underlying protective mechanism of RJ against 6MP induced testicular apoptosis and oxidative stress is not clearly studied. Therefore, our study focused on the impact of RJ to prevent reproductive complications in male albino rats when used as adjuvant to 6MP, and following the mechanistic pathway of protection through measuring biochemical, molecular, and histological changes occurred in the testis.

2. Material And Methods

2.1. Chemicals

Royal jelly was obtained from GlaxoSmithKline Company, Egypt. RJ capsule (1 gm) was opened and dissolved in physiological saline (0.9% NaCl). 6-mercaptopurine (5gm package) were purchased from Sigma–Aldrich Company, USA, 6MP powder was grinding then suspended in physiological saline (0.9% NaCl). MDA and antioxidant parameters were estimated using commercial kits (Bio-diagnostic for Research Kits, Egypt). Molecular kits were obtained from QIAGEN Company, USA. Other kits and tools were purchased from high quality sources

2.2. Experimental animals

Forty adult male albino rats, 8 weeks old, weighting an average 180-200 g were transferred to the animal house of biochemistry laboratory two weeks prior to the experiment initiation for acclimatization. The rats were housed under standard laboratory conditions maintained at 12-hour light / day cycle and ambient temperature of $25 \pm 2^{\circ}\text{C}$. All experiments were conducted in accordance with the criteria of the investigations and Ethics Committee of the Community Laws governing the use of experimental animals of Beni-suef University.

2.3. Experimental design:

After the adaptation period, rats were randomly assigned to 4 groups (n= 10 rats): group I (control group); rats received saline orally by gastric gavage tube for 30 days, Group II (RJ group); rats received RJ (200 mg/kg B.W.) for 30 days (Ahmed, Khalaf et al. 2014), Group III (6MP group); rats received saline (0.9% NaCl) for 10 successive days followed by 6MP (5 mg/kg B. W.) daily for 20 day. Group IV (RJ + 6MP): Rats received RJ (200 mg/kg B.W.) daily for 30 days, at the 10th day rats administered 6MP (5 mg/kg B. W.) for 20 days. All measured parameters were blinded examined to confirm the accuracy of the results.

Figure (1): Summary of the experimental design.

2.4. Blood sampling and tissue collection:

After 24 hours from the last administered dose, under ether anesthesia, blood was collected from the medial canthus blood capillaries of the eye by capillary tube (Parasuraman, Raveendran et al. 2010) in labeled dry centrifuge tubes which were leaved for coagulation then were centrifuged at 1000g for 20 minutes. Clear sera were separated in labeled Eppendorf tubes and preserved in deep freezer (-80°C) until analysis for detection of sex hormones.

At the time of sacrifice, the animals were euthanized by cervical dislocation (dislocation of spinal cord column from brain by applying pressure to neck). Testis were dissected out and weighed. The right testis was immediately fixed in 10 % neutral formalin for histomorphological study and the left testis was washed in physiological saline then silicate into two parts, the first part was homogenized by using homogenizer (Ortoalresa, Spain) for biochemical analysis. The second part was used for molecular investigation (real time PCR and western blotting techniques).

2.5. Weighting testes, epididymis and Semen evaluation

After scarification of rats, the testes were removed along with its epididymis and weighted separately. Also, The Testes and epididymis were separately immersed in 5 ml normal saline in a measuring cylinder and recording its volumes. The cauda epididymis were isolated and immersed immediately in physiological saline (0.9 % NaCl),then incubated to allow spermatozoa separation from epididymis tubules, supernatant was added by percentage (1:100) to solution contains 1ml formalin (35%), 25mg of Eosin,5gm of NaHCO₃ in 100 ml water (Ahmed and pharmacology 2015). For sperm counting, 10µl of the prepared mixture was transferred to the counting chambers of homocytometer under light microscope (Sanli, China Mainland), stand for 5 minutes and count sperms at 40 X. For sperm viability determinations, equal volumes of sperm solution and Eosin-Nigrosin stain were mixed , spread thin film on clean slide and examined under light microscope to count dead (pink) sperms and live (unstained) sperms, then calculate the ratio of viable sperms in the sample (Wyrobek, Gordon et al. 1983). Determination of sperms motility was done by addition of semen solution to Tris-buffer, and count motile sperms at 40 X in comparison with total sperms count. Abnormal forms were examined also at 40 X, and recorded to calculate its percentage (Sönmez, Türk et al. 2005).

2.6. Histopathological examination

Testis was fixed in 10 % neutral formalin for 48 hours. And then processed according to Bancroft and Gamble (2008) (Suvarna, Layton et al. 2018), then washed in running water, graduated ethanol (50%, 70%, 95% then 100 %) respectively, 2h for each, cleared in xylene and embedded in paraffin wax at 70 °C, blocking in paraffin and then undermined in microtome. Tissues sections were mounted on 4µ-6µ on clean glass slides and stained by Hematoxylin and Eosin (H&E). Microscopically examined and photographed by using light microscope (Sanli, China Mainland). The histological sections were examined for the presence of congestion, tubular degeneration, cellular vacuolation and Pyknosis of cell lining seminiferous tubules. The histological changes were scored from 0 to 3 according to the histological findings, where 0 represents no pathological findings, and 1, 2 and 3 represent pathological

findings in <33%, 33–66% and >66% of the testes, respectively. The scores for each parameter were calculated and the total scores were obtained and presented as means \pm SEM.

2.7. Tissue preparation of the homogenate

0.5 g of testis was homogenized in 5 ml physiological saline and centrifuged at 20,000 \times g for 30 min at 4 °C. The supernatants were collected and stored at - 80°C for the assessment of reduced glutathione(GSH), glutathione reductase (GR), catalase, superoxide dismutase(SOD), lipid peroxidation (MDA), caspase-3, TNF- α

2.8. Sex hormones assay

Enzyme Linked Immunosorbent Assay (ELISA) kit (MyBioSource Company, USA) was used for estimation of serum levels of testosterone , FSH (follicular stimulating hormone) and LH (leutinizing Hormone) following the instructions of kits protocol, the principle is based on antigen antibody reaction.

2.9. Oxidant/antioxidant assay

The testicular content of lipid peroxidation represented in Malondialdehyde (MDA) was measured according to protocol described by Ohkawa (1979), assay is based on reaction of MDA with thiobarbituric acid to form reactive colored product, absorbance of colored product can be measured at 534 nm, concentration of MDA calculated from standard curve using standard concentrations (Ohkawa, Ohishi et al. 1979). Catalase activity in testis sample was estimated using hydrogen peroxide substrate according to instructions described by Aebi, H. (1984) (Aebi 1984). Super oxide dismutase was estimated according to the method described by Koracevic et al.(2001) (Koracevic, Koracevic et al. 2001). glutathione reduced (GSH) was assayed colorimetrically, follow the method of Beutler E. (1963) , the method based on the reduction of 2-nitrobenzoic acid through reaction with glutathione reduced to produce colored compound, reduced chromogen absorbance can be measured at 405 nm, and its concentration is directly proportional to the concentration of GSH (Beutler, Duron et al. 1963). Glutathion reductase (GH) assay was performed according to the method of Brigelius, et al (Brigelius, Muckel et al. 1983)

2.10. ELISA assay for measuring Caspase-3 and TNF- α

Caspase-3: was assayed by rat caspase-3 ELISA kit according to instructions of manufacturer MBS1602954 MyBioSource Company, USA

Tumor Necrosis Factor- alpha (TNF- α) level: was estimated as a pro-inflammatory marker using rat TNF- α ELISA kits according to manufacturer's instructions of MyBioSource Company, USA (MBS 490379) (Berry, Brightling et al. 2007)

2.11. Western blotting assay for assessing PI3K, AKT, Nrf2 and HO1

Testicular samples were homogenized using RIPA lysis buffer (buffer enables protein extraction from cytoplasmic membrane and nuclear proteins), the lysate was kept on ice for 30 minutes on shaker, then

centrifuged at ~16,000xg for 30 minutes at 4°C, cell debris was removed and supernatant was transferred to a new tube for further protein concentration determination analysis.

Quantitative estimation of protein was assayed according to instructions of Bradford Protein Assay Kit (Markham Ontario L3R 8T4 Canada). Extracted protein in each sample was added to equal volume of loading buffer(4% SDS, 20% glycerol, 10% 2-mercaptoethanol, 0.125MTrisHCl, 0.004% bromophenol blue), the mix was boiled at 95 °C for 5 minutes. Protein in loading buffer were electrophoresed using 10% SDS PAGE then electro-transferred to polyvinylidene difluoride(PVDF) membranes .The membrane was blocked in tris-buffered saline with Tween 20 buffer and 3% bovine serum albumin (BSA) for 1 hr. The membrane was incubated overnight with anti PI3K , AKT, Nrf2 and HO1 antibodies (Thermofisher. USA) separately, Beta actin was used as control. After washing 4 times for 5 min each in DPBS (tween-20), the blot was incubated with the corresponding Goat anti-rabbit IgG for 1 h, washed and then developed , finally protein band images were recorded in BioMax film, and quantified using densitometry and Molecular Analyst Software (Bio-Rad, Richmond, CA, USA).

2.12. DNA fragmentation assay

DNA was extracted from testicular tissue by using chemical method of DNA purification (Collins, Schandl et al. 1997), DNA fragmentation percentage was estimated by addition of tetron-X-buffer with vortex for fragmented DNA releasing, then addition of tetrachloroacetic acid(5%) and heated at 90°C for 15minuts. Samples were measured calorimetrically with diphenylamine stain at 600 nm. Gel electrophoresis analysis for the DNA was done according to the method described by K Weber, M Osborn (Weber and Osborn 1969), finally gels were illuminated with ultraviolet light at 300 nm and photographic record was made to show the fragmented DNA in comparison with DNA ladder .

2.13. Quantitative Real time polymerase chain reaction (RT- qPCR): P53 mRNA and androgen receptors (AR) mRNA expression

Gene expression was estimated through three steps. i) RNA extraction, ii) complementary DNA (cDNA) synthesis, iii) Real time qPCR assay. (i)RNA in testicular tissues (homogenate) was isolated using Qiagen tissue extraction kit (Qiagen, USA) according to instructions of manufacture, lysis buffer TLT was added to 30mg of testis tissues , the tissue was lysed and homogenized using homogenizer for 40 seconds, the lysate was centrifuged for 3 min and the supernatant was transferred into microcentrifuge tube, 350µl of 70% ethanol was added to the cleared lysate on RNeasy spin column high to washed three times using wash buffer of the kits, RNeasy spin column was placed in a new 1.5 ml collection tube. 50µl RNase-free water was added directly to the spin column membrane, and centrifuged for 1 min at ≥8000 rpm to elute the RNA. The concentration of RNA was obtained using nano drop spectrophotometry. (ii)The produced total RNA (0.5–2 µg) was used as a template for cDNA synthesis with random primers using high capacity cDNA reverse transcription kit(Fermentas, USA). cDNA master mix was prepared according to kit's instructions and was added to RNA-Primers mixture to produce cDNA . (iii)Real-time qPCR reaction were performed using (Applied Biosystems, USA) with software version 3.1 (StepOne™, USA)., gene

expression technique employed following the method of Pfaffl (2001)(Pfaffl 2001) . The primer sequence was shown in table 1. PCR components include 1 µl of forward primer, 1 µl of reverse primer, 5 µl of cDNA template, 5.5 µl RNAase free water and 12.5 µl syber green mix. The total volume is 25 µl. Running 40 RT-qPCR cycles according to the condition of kits then data were calculated using version 3.1 (StepOne™, USA), software, The relative expression of P53 and androgen receptor was calculated using the comparative Ct method. The values were compared to beta actin genes and reported as fold change

Table 1. Primers of targeted genes (P53 and AR) with β- actin

AR primer	Forward primer; 5'-TGTGGTCAAGTGGGCCAAG-3'; Reverse primer; 5'-TGCCATCTGGTCATCCACAT-3'.
P53 primer	Forward primer; 5'- CGCAAAGAAGAAGCCACTA-3 Reverse primer; 5'-TCCACTCTGGGCATCCTT-3
B- actin	Forward primer; 5'-TGTTTGAGACCTTCAACACC-3' Reverse primer; 5'-CGCTCATTGCCGATAGTGAT-3'

2.14. Statistical analysis

Results were analyzed using one-way analysis of variance (one way ANOVA) test and presented as mean ± standard error (SEM), and followed by Tukey–Kramer methods for post hoc analysis. A value of p<0.05 was considered statistically significant.

3. Results

3.1. Histopathological examination results:

The histopathological examination of rat testis from the control group (fig.2a) indicated that the complete spermatogenesis; seminiferous tubules (ST) were lined by spermatogonial cells, Sertoli cells with the presence of Leydig cells (L) in the interstitial tissue. Testicular tissue of RJ group showed more or less normal seminiferous tubules having complete spermatogenesis (fig.2b). Examination of 6MP group revealed presence of severe testicular degeneration (vacuolation) (V) in the tubular cells and necrosis (pyknosis) (Blue arrow) of seminiferous tubules (fig2c) manifested by loss of tissue architecture and accompanied with accumulation of the degenerated cells within the lumen. Interstitial areas were widened with Leydig cells degeneration and presence of severe congestion (Black arrow). In RJ+6MP group, histologically, the testicular tissue showed variable degrees of improvement to the degree to be similar to that of control group (fig. 2d)

3.2. Effect of 6MP and RJ on testicular weights and epididymis length

RJ alone gives the same results of safety such as control group without any significant differences, so they referred as control group.

Firstly we investigate the effects of 6MP alone and with RJ pre-treatment on testis weight, volume and tail of Epididymis of rats. Data in table (2) showed the significant decrease in testis weights, volume and in the length of epididymis in 6MP treated group at $P < 0.05$ compared to the control group. Prior administration of RJ in RJ+6MP group evanished this decrement in compare to 6MP group by a significant degree at $P < 0.05$.

Table 2. The weights and volumes of testes and epididymis of different treated groups.

Groups	Testes		Tail of Epididymis	
	Weight (g)	Volume (cm ³)	Weight (g)	Volume (cm ³)
Control group	5.3±0.3	4.76 ± 0.01	0.9±0.04	2.8±0.21
RJ group	4.9±0.01	4.5±0.06	0.8±0.01	2.6±0.01
6MP group	3.01±0.02 ^a	2.12± 0.02 ^a	0.3 ± 0.01 ^a	0.91 ± 0.03 ^a
RJ+6MP group	4.1±0.01 ^b	4.3±0.02 ^b	0.6±0.01 ^b	2.7±0.01 ^b

The results were expressed as means ± SE n = 10. The data were analyzed by using one way ANOVA test. a: indicates a significant difference compared to control at level $p < 0.05$. b: indicates a significant difference compared to 6MP at $P < 0.05$.

3.3. Effect of 6MP and RJ on various sperm parameters in treated rats

Administration of 6MP significantly decreased sperm motility %, sperm count and sperm viability% at $P < 0.05$ when compared with control group. Also 6MP caused a significant increase of sperm abnormalities % when compared to control group at $P < 0.05$. In RJ+6MP group; RJ caused a significant increase of sperm motility %, sperm count and sperm viability% with a concurrent reduction of sperm abnormalities % compared to 6MP group at $P < 0.05$. Semen analysis of RJ group showed no significant difference compared to control at $P < 0.05$.

Table 3. The changes in sperm motility, viability, abnormality percentage and sperm count in all examined rats

Groups	Motility %	Sperm cell count. (X 10 ⁶)	Viability (%)	Abnormalities (%)
Control group	81.6±1	30±2	90.2±1.09	15.9±0.9
RJ group	77.8±1.01	31±0.1	88.2±0.1	16.3±0.3
6MP group	40.2 ± 0.5a	15.9±0.4a	50.5± 1a	42.1± 0.5a
RJ+6MP group	79.9±1b	29.32±1b	88.12±1.2b	16.5± 1b

The results were analyzed by using one way ANOVA test and expressed as means ± SE, n = 10. The data. a: indicates a significant difference compared to control at level p<0.05. b: indicates a significant difference compared to 6MP at P<0.05.

3.4. Effect of 6MP and RJ on testicular AR mRNA expression and serum testosterone, FSH and LH concentrations

As shown in table (3); AR mRNA significantly decreased in 6MP group at P<0.05 compared to control group, while pre-administration of RJ prevent the negative effect of 6MP on AR mRNA that revealed in significant increase of AR mRNA in RJ+6MP group at P<0.05 compared to 6MP group.

6MP treated rats showed a significant increase of FSH, LH and a significant decrease of testosterone level at P<0.05, compared to control group. The levels of FSH and LH of RJ+6MP group were significantly decreased and serum testosterone level was significantly increased at P<0.05 when compared to 6MP group. The levels of AR mRNA expression and hormonal levels of RJ group and control are not significant at P<0.05.

Table 3. The effect of 6MP on AR mRNA expression (fold change in relation to β-actin), testosterone, FSH and LH concentrations in different treated groups.

The results were expressed as means ± SE n = 10. The data were analyzed by using one way ANOVA test. a: indicates a significant difference compared to control at level p<0.05. b: indicates a significant difference at P<0.05.

3.5. Effects of 6MP and RJ on testicular antioxidant/ oxidative redox.

The results in Fig3 depicted that administration of 6MP disturbed the testicular antioxidant/oxidative redox and caused a significant testicular oxidative stress. This effect was indicated by the ability of 6MP to cause a significant depletion of testicular GSH concentration, GR, Catalase and SOD activities with a concurrent increase of MDA level in 6MP group as compared with control group at P<0.05. In RJ+6MP group; pretreatment of RJ restored the testicular antioxidant/ oxidative redox. This protective effect was

indicated by the significant increase of GSH concentration, GR, Catalase, SOD activities and the significant reduction of MDA level in RJ+6MP group compared to 6MP group at $P < 0.05$. In addition, testicular antioxidant/oxidative redox of RJ group showed no significant difference compared to control group at $P < 0.05$.

3.6. The effect of 6MP and RJ on testicular PI3K, AKT, Nrf2 and HO1 of different treated groups.

Western blotting results (Fig. 3) showed that administration of 6MP significantly decreased the expression of testicular PI3K, AKT, Nrf2 and HO1 protein levels in 6MP group compared to control group at $P < 0.05$. RJ significantly increased PI3K, AKT, Nrf2 and HO1 protein levels in RJ+6MP group compared to 6MP at $P < 0.05$. PI3K and AKT protein levels in RJ+6MP group were significantly lower than control group at $P < 0.05$ while Nrf2 and HO1 protein levels of RJ+6MP group showed no significant difference as compared to control group at $P < 0.05$.

3.7. The effect of 6MP and RJ on TNF- α , DNA fragmentation%, P 53 mRNA expression and caspase-3 of different treated groups.

Results in Fig. 4 showed that 6MP significantly increased TNF- α , DNA fragmentation %, P53 mRNA expression and caspase-3 in 6MP group compared to control group at $P < 0.05$. RJ administration reduced testicular inflammatory marker, DNA damage and apoptosis. This effect was indicated by the significant reduction of TNF- α , DNA fragmentation %, P53 and caspase-3 respectively in RJ+6MP group compared to 6MP group at $P < 0.05$. TNF- α and DNA fragmentation % of RJ+6MP group were higher than those in control group at $P < 0.05$. There was no significant difference between P53 and caspase-3 of RJ+6MP and control group at $P < 0.05$.

Discussion

6MP is an active metabolite of azathioprine. It is clinically used in chemotherapy and immunosuppression. Despite, the efficacy of 6MP in treatment, it has cytotoxic effect on normal body tissues (Clark, Hsia et al. 1960, Tapner, Jones et al. 2004). Our study focused on 6MP gonadotoxicity, infertility problems and the prophylactic effect of RJ through studying changes in sperm parameters and seminiferous tubules.

It is reported that the active metabolites of 6MP damages rapidly dividing cells, such as those in reproductive organs of adults (Bendre, Shaddock et al. 2007). The reduction of the testicular and epididymal weight in 6MP treated rats indicated its obvious gonadotoxic effect. This effect was confirmed by the histological study of testicular tissues which showed a severe atrophy of many seminiferous tubules with wide interstitial spaces, few numbers of spermatozoa and spermatogenic cells, also morphology distortion and atrophy of Leydig cells. In agreement with our results, Karawya et.al; reported that azathioprine induced testicular atrophy, histological distortion and impaired spermatogenesis in male albino rats (Karawya and El-Nahas 2006).

Statistical analysis of semen parameters in 6MP treated rats revealed a severe reduction of sperm count, motility and viability, as well as an increase in abnormal forms of spermatozoa. This effect of 6MP could be explained by the ability of 6MP to interfere with nucleic acid synthesis of rapidly dividing somatic and germ cells resulting in germ cell apoptosis and germ cell mutations (Brown, Aljefri et al. 2019).

Our data indicated that 6MP treatment significantly decreased gene expression of ARs in 6MP treated rats. ARs are nuclear receptors highly expressed in testis and play a crucial role in spermatogenesis maintenance. The reduction of ARs and their knockout alters the reproductive development and spermatogenesis (Wang, Yeh et al. 2009).

Spermatogenesis is highly susceptible to reactive oxygen species (ROS) levels, which increases spermatogenic cells apoptosis and induces seminiferous epithelium damage (Moazamian, Polhemus et al. 2015), testicular dysfunction and sperm abnormalities (Pahune, Choudhari et al. 2013). In the metabolic process of 6MP, xanthine oxidase converts 6MP to thiouric acid, a reaction capable of producing ROS, almost H_2O_2 (Kelley, Khoo et al. 2010). We demonstrated that 6MP alters testicular antioxidant/ oxidative redox by decreasing testicular antioxidants; GSH concentration, GR, catalase and SOD activities with a concurrent increase of testicular lipid peroxidation by increasing MDA level. Protein concentration of Nrf2 and HO1 were significantly decreased in 6MP treated rats. Türk et al., (2010) proved the correlation between oxidative stress and sperm abnormalities (Türk, Sönmez et al. 2010). In consistent with these reports our results showed that reduction of antioxidants was associated with DNA fragmentation and was accompanied by significant increased percentages of abnormal, dead and immotile sperms in 6MP treated rats.

Our data indicated that the significant increase in TNF- α in 6MP treated rats has been associated with increasing abnormal forms of sperms and reduction in sperm viability. Also, TNF- α has the ability to induce testicular apoptosis (Rath and Aggarwal 1999, Ségui, Cuvillier et al. 2001, Chen and Goeddel 2002).

To insight into 6MP-induced testicular apoptosis, we evaluated PI3K and AKT protein expression, pro-apoptotic caspase-3 activity and mRNA expression of P53. PI3K/AKT signaling pathway plays a pivotal role in cell apoptosis, proliferation and differentiation (Franke 2008). In addition, PI3K/AKT is related to the growth and development of testicular tissue and is involved in the interaction between FSH and Sertoli cells (Walker and Cheng 2005). PI3Ks are a family of important lipid kinases. PI3K can be activated by cell surface receptor (Lee, Suk et al. 2008) and it can act as a messenger molecule involved in signal transduction which is the first regulator of AKT activation. The activated PI3K1 can make AKT transverse to the cell membrane and activate it. In accordance with our findings, Reggio et al., (2017), report that 6MP down regulated PI3K/AKT pathway (Reggio, Spada et al. 2019).

Down-regulation of PI3K/AKT pathway can result in the activation of caspase-3 and trigger apoptosis (Wang, Wang et al. 2017). In support to the previous report this study illustrated that administration of 6MP for 20 days induced down-regulation of PI3K and AKT which was associated with high activity of

caspase-3 and over expression of P53 in 6MP treated rats. In confirm to our result Kanemitsu, et al., (2009) reported that 6MP induced apoptosis through P53, caspase-3 pathway (Kanemitsu, Yamauchi et al. 2009).

It is reported that the overexpression of caspase-3 is associated with Leydig cell atrophy in 6MP treated rats (Morgan, Lynch et al. 2015). Leydig cells are decisive to production of testosterone, which can effect on function of Sertoli cells. Atrophy of Leydig cells results in reduction of testosterone levels that also associated with elevated values of FSH and LH. Therefore premature detachment of spermatids may occur due to decrement in testosterone level and impairment of spermatogenesis (Karawya and El-Nahas 2006, Kumar, Narayana et al. 2006).

Herein, we evidenced the ameliorative effects of RJ in 6MP-induced testicular dysfunction and the ability of RJ to improve spermatogenesis process in RJ pretreated rats. The data of RJ+6MP clearly revealed a significant increase in testicular weight, sperm count, motility and viability as well as reduction in abnormal forms of sperms which reversed the impairment occurred in 6MP treated rats. The improvement of histomorphological data of RJ pretreated rats evidenced the ability of RJ for tissue repair and protection against tissue damage, in accordance with our finding Temamoğulları, et.al report that the protective effect of RJ against mice testicular degeneration and spermotoxicity induced by flunixin (Temamoğulları, Aral et al. 2018).

Pre-administration of RJ increase serum testosterone and reduced the concentration of FSH and LH in RJ+6MP group, RJ ability to increase serum testosterone levels might be due to Zn containing which has an essential role in spermatogenesis (Fallah, Mohammad-Hasani et al. 2018)

Antioxidant activity of RJ has been reported (Delkhoshe-Kasmaie, Malekinejad et al. 2014, Najafi, Nejati et al. 2014, Ghanbari, Nejati et al. 2015). In agreement with previous reports we evidenced that RJ pretreatment restored levels of SOD, catalase, GR and GSH to approach normal control levels and scavenged ROS, therefore reduced lipid peroxidation (low MDA level). The ability of RJ to scavenge the ROS might be due to RJ up-regulation of Nrf2 expression which increased significantly in RJ pretreated rats with concurrent increase in HO-1 protein levels in compare with 6MP treated rats. in consistence with our data Almeer, et al (2018) illustrate that RJ abrogated the testicular oxidative stress induced by cadmium through up-regulation of Nrf2 (Almeer, Soliman et al. 2018). Nrf2 up regulation stimulates the expression of HO-1, up-regulation of Nrf2/HO1 pathway increases antioxidants activity and protects against tissue (Bae, Ha et al. 2016) damages, in agreement with this report our histopathological finding of RJ+6MP revealed markedly improvement in seminiferous tubules appearance as well as Leydig cell numbers in compare with 6MP group. In addition to antioxidant activity of RJ, it has anti-inflammatory effects, Kohno, et al reported the inhibitory effect of RJ on pro-inflammatory cytokines by activation of macrophages (Kohno, Okamoto et al. 2004), also report of Aslan, Z, et al who illustrated that RJ abrogated renal inflammation induced by ethylene glycol (Aslan and Aksoy 2015). In the present study we found that rats which pretreated with RJ revealed markedly decreased TNF- α activity when compared

with 6MP treated rats, this result evidenced the inhibitory effect of RJ on TNF- α which was associated with spermatogenesis enhancement.

Anti-apoptotic effect of RJ is supported by report of Karadeniz, A., et al., (2011) who suggest that RJ acts as anti-apoptotic and antioxidant agent (Karadeniz, Simsek et al. 2011). In addition Valiollahpoor Amiri, et al report that RJ inhibit apoptosis by increasing the expression of BCL2 (Valiollahpoor Amiri, Deldar et al. 2016). In present study we insight into the mechanistic pathway of RJ anti-apoptotic effect through following PI3K/AKT pathway and pro-apoptotic caspase-3 with deepen in P53 mRNA gene expression. Pre-administration of RJ induced up-regulation of PI3K/AKT pathway and caspase-3 inhibition. Data of RJ pretreated rats revealed that high protein levels of PI3K and AKT was associated with decrement in caspase-3 activity and P53 mRNA expression. In addition, histopathological data of RJ+6MP appeared to restore normal number of Leydig cells and seminiferous tubule appearance that approach control data. Normal size and number of Leydig cells was observed in RJ pretreatment also testosterone level was restored to approach normal control level. The positive impact of RJ on Leydig cells could be due to suppression of caspase-3 activity, (Morgan, Lynch et al. 2015) reported that caspase-3 activity induced Leydig cell death. The possible mechanism of RJ protection against 6MP-induced apoptosis is the up-regulation of PI3K/AKT pathway and inhibition of caspase-3 activity. A recent study proved that PI3K/AKT pathway correlates with Nrf2 expression in testicular tissue and regulates the level of Nrf2-dependent inducible expression of HO-1 (Bashir, Shagirtha et al. 2019). In support with the previous report, we reported that RJ up-regulation of PI3K/AKT pathway was concurrent with increasing in Nrf2 protein levels in RJ pretreated rats.

Finally, the present study proves that Royal Jelly is a safe product for albino rats and can be used in combination with 6MP to reduce or mitigate 6MP toxicity on testicular tissues through up-regulation of PI3K/AKT pathway, Nrf2/HO-1 pathway and down regulation of caspase-3, P53 gene expression and TNF- α . In confirm to our results Ahmed, W.M., et al., report that RJ prevent hepatotoxicity induced by azathioprine (Ahmed, Khalaf et al. 2014). RJ acts as scavenger to ROS therefore decrease DNA fragmentation percent, increase antioxidants activity and decrease peroxidation levels in testicular tissues. The efficacy of RJ as anti-inflammatory, antioxidant and anti-apoptotic agent qualify it to attenuate chemotherapy induced toxicity and prevent testicular dysfunction caused by 6MP

Conclusion

The present study demonstrates that RJ protects 6MP-induced testicular injury via regulating PI3K/AKT signaling pathway. Therefore, RJ might be a promising treatment for infertility diseases related to testicular injuries. Further studies should be done to investigate many other mechanisms of RJ against 6MP induced testicular damage.

List Of Abbreviations

6MP: 6-Mercaptopurine

RJ: Royal Jelly

P.o: Per os

TNF- α : Tumor Necrosis Factor- α

AR: Androgen receptors

PI3K: phosphoinositide-3 kinase

AKT: protein Kinase B

H01: Heme Oxygenase-1

Nrf2: Nuclear Factor erythroid 2-related factor 2

GSH: reduced glutathione

GR: glutathione reductase

SOD: superoxide dismutase

MDA: Malondialdehyde

ROS: Reactive Oxygen species

Enzyme Linked Immunosorbent Assay (ELISA)

FSH: follicular stimulating hormone

LH: leutinizing Hormone

cDNA: complementary deoxyribonucleic acid

mRNA: messenger ribonucleic acid

RT- qPCR: Quantitative Real time polymerase chain reaction

H&E: Hematoxylin and Eosin

Declarations

Acknowledgment

The authors thank the Laboratory of biochemistry and chemistry of nutrition, the Department of Pathology of faculty of veterinary medicine, Beni-Suef University for their assistance.

Authors' contributions: KS and AZ designed the study and prepared the manuscript. KS and NW performed the experiments. KS, AZ and NW assisted in the data analysis and helped prepare the manuscript. All authors read and approved the final manuscript.

Funding: authors declare that they haven't received any kind of financial support.

Availability of data and materials:

The datasets used and/or analyzed during the current study available from the corresponding author on reasonable request.

Ethics approval and consent to participate:

All procedures were approved by the Committee for the Ethics on Animal Care and Experiments of Beni-Suef University.

Consent for publication: All authors agree to the submission of this article for publication.

Competing interests: The authors declare that they have no competing interests.

Author details:

1: Biochemistry Department, Faculty of Veterinary Medicine, Beni-Suef University, Egypt. 2: Biotechnology and Life Sciences Department, Faculty of Postgraduate Studies for Advanced Sciences, Beni-Suef University, Egypt. Corresponding author: Khalid Shaaban Hashem (K. S. Hashem)

khalidshaabanhashem@yahoo.com Contact/ Address: Biochemistry department, Faculty of veterinary medicine, Beni-Suef University, Beni-Suef 62511, Egypt.

References

- Aebi, H. (1984). [13] Catalase in vitro. Methods in enzymology. Academic Press, Elsevier. **105**: 121-126.
- Ahmed, M. A. J. T. and a. pharmacology (2015). "Amelioration of nandrolone decanoate-induced testicular and sperm toxicity in rats by taurine: effects on steroidogenesis, redox and inflammatory cascades, and intrinsic apoptotic pathway." **282**(3): 285-296.
- Ahmed, W. M., A. Khalaf, W. A. Moselhy, G. M. J. E. t. Safwat and pharmacology (2014). "Royal jelly attenuates azathioprine induced toxicity in rats." Environmental toxicology and pharmacology **37**(1): 431-437.
- Almeer, R., D. Soliman, R. Kassab, G. AlBasher, S. Alarifi, S. Alkahtani, D. Ali, D. Metwally and A. J. I. j. o. m. s. Abdel Moneim (2018). "Royal Jelly Abrogates Cadmium-Induced Oxidative Challenge in Mouse Testes: Involvement of the Nrf2 Pathway." International journal of molecular sciences **19**(12): 3979.

- Aslan, Z. and L. J. I. b. j. u. Aksoy (2015). "Anti-inflammatory effects of royal jelly on ethylene glycol induced renal inflammation in rats." International braz j urol **41**(5): 1008-1013.
- Bae, W. J., U. Ha, J. B. Choi, K. S. Kim, S. J. Kim, H. J. Cho, S. H. Hong, J. Y. Lee, Z. Wang, S. Y. J. O. M. Hwang and C. Longevity (2016). "Protective effect of decursin extracted from *Angelica gigas* in male infertility via Nrf2/HO-1 signaling pathway." Oxidative Medicine and Cellular Longevity **2016**.
- Bashir, N., K. Shagirtha, V. Manoharan and S. Miltonprabu (2019). "The molecular and biochemical insight view of grape seed proanthocyanidins in ameliorating cadmium-induced testes-toxicity in rat model: implication of PI3K/Akt/Nrf-2 signaling." Bioscience reports **39**(1): BSR20180515.
- Bendre, S. V., J. G. Shaddock, V. N. Dobrovolsky, R. J. Albertini, R. H. J. E. Heflich and M. mutagenesis (2007). "Effect of chronic azathioprine treatment on germ-line transmission of Hprt mutation in mice." Environmental and Molecular mutagenesis **48**(9): 744-753.
- Bendre, S. V., J. G. Shaddock, R. E. Patton, V. N. Dobrovolsky, R. J. Albertini, R. H. J. M. R. F. Heflich and M. M. o. Mutagenesis (2005). "Lymphocyte Hprt mutant frequency and sperm toxicity in C57BL/6 mice treated chronically with Azathioprine." Mutation Research/Fundamental and Molecular Mechanisms of Mutagenesis **578**(1-2): 1-14.
- Berry, M., C. Brightling, I. Pavord and A. J. J. C. o. i. p. Wardlaw (2007). "TNF- α in asthma." Current opinion in pharmacology **7**(3): 279-282.
- Beutler, E., O. Duron, M. J. J. o. L. Kelly and C. Medicine (1963). "Colorimetric method for determination of glutathione reductase concentration." Journal of Laboratory and Clinical Medicine **61**: 882.
- Brigelius, R., C. Muckel, T. P. Akerboom and H. J. B. p. Sies (1983). "Identification and quantitation of glutathione in hepatic protein mixed disulfides and its relationship to glutathione disulfide." Biochemical pharmacology **32**(17): 2529-2534.
- Brown, S. M., K. Aljefri, R. Waas and P. Hampton (2019). "Systemic medications used in treatment of common dermatological conditions: safety profile with respect to pregnancy, breast feeding and content in seminal fluid." Journal of Dermatological Treatment **30**(1): 2-18.
- Chen, G. and D. V. J. S. Goeddel (2002). "TNF-R1 signaling: a beautiful pathway." Science **296**(5573): 1634-1635.
- Clark, P., Y. Hsia and R. J. B. m. j. Huntsman (1960). "Toxic complications of treatment with 6-mercaptopurine." British medical journal **1**(5170): 393.
- Collins, J. A., C. A. Schandl, K. K. Young, J. Vesely, M. C. J. J. o. H. Willingham and Cytochemistry (1997). "Major DNA fragmentation is a late event in apoptosis." Journal of Histochemistry & Cytochemistry **45**(7): 923-934.

- Delkhoshe-Kasmaie, F., H. Malekinejad, M. Khoramjouy, A. Rezaei-Golmisheh and H. J. S. b. i. r. m. Janbaze-Acyabar (2014). "Royal jelly protects from taxol-induced testicular damages via improvement of antioxidant status and up-regulation of E2f1." Systems biology in reproductive medicine. **60**(2): 80-88.
- Fallah, A., A. Mohammad-Hasani, A. H. J. J. o. r. Colagar and infertility (2018). "Zinc is an essential element for male fertility: A review of zn roles in men's health, germination, sperm quality, and fertilization." Journal of reproduction & infertility. **19**(2): 69.
- Franke, T. J. O. (2008). "PI3K/Akt: getting it right matters." Oncogene **27**(50): 6473.
- Ghanbari, E., V. Nejati and M. J. I. J. o. R. B. Khazaei (2016). "Antioxidant and protective effects of Royal jelly on histopathological changes in testis of diabetic rats." International Journal of Reproductive BioMedicine **14**(8): 519.
- Ghanbari, E., V. Nejati, G. Najafi, M. Khazaei, M. J. I. j. o. f. Babaei and sterility (2015). "Study on the effect of royal jelly on reproductive parameters in streptozotocin-induced diabetic rats." International journal of fertility & sterility. **9**(1): 113.
- Golmohammadi, M. G., M. Sagha, S. A. Ziai, M. A. Abdollahifar and H. J. U. j. Nazarian (2019). "Protective Effect of Gallic Acid on Testicular Tissue, Sperm Parameters, and DNA Fragmentation against Toxicity Induced by Cyclophosphamide in Adult NMRI Mice." Urology journal.
- Jalali, A. S., G. Najafi, M. Hosseini and A. J. I. j. o. r. m. Sedighnia (2015). "Royal jelly alleviates sperm toxicity and improves in vitro fertilization outcome in stanozolol-treated mice." Iranian journal of reproductive medicine **13**(1): 15.
- Kanemitsu, H., H. Yamauchi, M. Komatsu, S. Yamamoto, S. Okazaki, K. Uchida, H. J. N. Nakayama and teratology (2009). "6-mercaptopurine (6-MP) induces p53-mediated apoptosis of neural progenitor cells in the developing fetal rodent brain." Neurotoxicology and teratology. **31**(4): 198-202.
- Karadeniz, A., N. Simsek, E. Karakus, S. Yildirim, A. Kara, I. Can, F. Kisa, H. Emre, M. J. O. m. Turkeli and c. longevity (2011). "Royal jelly modulates oxidative stress and apoptosis in liver and kidneys of rats treated with cisplatin." Oxidative medicine and cellular longevity. **2011**.
- Karawya, F. S. and A. F. J. C. T. El-Nahas (2006). "The protective effect of vitamin C on Azathioprine induced seminiferous tubular structural changes and cytogenetic toxicity in albino rats." Cancer Ther **4**: 125-134.
- Kelley, E. E., N. K. Khoo, N. J. Hundley, U. Z. Malik, B. A. Freeman, M. M. J. F. R. B. Tarpey and Medicine (2010). "Hydrogen peroxide is the major oxidant product of xanthine oxidase." Free Radical Biology and Medicine **48**(4): 493-498.
- Kohno, K., I. Okamoto, O. Sano, N. Arai, K. Iwaki, M. Ikeda, M. J. B. Kurimoto, biotechnology, and biochemistry (2004). "Royal jelly inhibits the production of proinflammatory cytokines by activated

macrophages." Bioscience, biotechnology, and biochemistry **68**(1): 138-145.

Koracevic, D., G. Koracevic, V. Djordjevic, S. Andrejevic and V. Cosic (2001). "Method for the measurement of antioxidant activity in human fluids." J Clin Pathol **54**(5): 356-361.

Kumar, S. G., K. Narayana, K. Bairy, U. J. D'Souza, V. P. Samuel, K. J. M. R. G. T. Gopalakrishna and E. Mutagenesis (2006). "Dacarbazine induces genotoxic and cytotoxic germ cell damage with concomitant decrease in testosterone and increase in lactate dehydrogenase concentration in the testis." Mutation Research/Genetic Toxicology **607**(2): 240-252.

Lee, S., K. Suk, I. K. Kim, I. S. Jang, J. W. Park, V. J. Johnson, T. K. Kwon, B. J. Choi and S. H. Kim (2008). "Signaling pathways of bisphenol A-induced apoptosis in hippocampal neuronal cells: Role of calcium-induced reactive oxygen species, mitogen-activated protein kinases, and nuclear factor- κ B." Journal of neuroscience research **86**(13): 2932-2942.

Moazamian, R., A. Polhemus, H. Connaughton, B. Fraser, S. Whiting, P. Gharagozloo and R. J. J. M. B. s. o. r. m. Aitken (2015). "Oxidative stress and human spermatozoa: diagnostic and functional significance of aldehydes generated as a result of lipid peroxidation." MHR: Basic science of reproductive medicine **21**(6): 502-515.

Mohammadi, O. and T. A. Kassim (2019). Azathioprine. StatPearls [Internet], StatPearls Publishing.

Morgan, J. A., J. Lynch, J. C. Panetta, Y. Wang, S. Frase, J. Bao, J. Zheng, J. T. Opferman, L. Janke and D. M. J. S. r. Green (2015). "Apoptosome activation, an important molecular instigator in 6-mercaptopurine induced Leydig cell death." Scientific reports **5**: 16488.

Nagai, T. and R. J. F. c. Inoue (2004). "Preparation and the functional properties of water extract and alkaline extract of royal jelly." Food chemistry **84**(2): 181-186.

Najafi, G., V. Nejati, A. S. Jalali and E. J. I. J. o. T. V. Zahmatkesh (2014). "Protective role of royal jelly in oxymetholone-induced oxidative injury in mouse testis." Iranian Journal of Toxicology **8**(25).

Ohkawa, H., N. Ohishi and K. J. A. b. Yagi (1979). "Assay for lipid peroxides in animal tissues by thiobarbituric acid reaction." Analytical biochemistry **95**(2): 351-358.

Pahune, P. P., A. R. Choudhari, P. A. J. J. o. c. Muley and d. r. JCDR (2013). "The total antioxidant power of semen and its correlation with the fertility potential of human male subjects." Journal of clinical and diagnostic research: JCDR. **7**(6): 991.

Parasuraman, S., R. Raveendran and R. Kesavan (2010). "Blood sample collection in small laboratory animals." Journal of pharmacology & pharmacotherapeutics **1**(2): 87.

Pfaffl, M. W. J. N. a. r. (2001). "A new mathematical model for relative quantification in real-time RT-PCR." Nucleic acids research **29**(9): e45-e45.

- Rath, P. C. and B. B. J. J. o. c. i. Aggarwal (1999). "TNF-induced signaling in apoptosis." Journal of clinical immunology **19**(6): 350-364.
- Reggio, A., F. Spada, M. Rosina, G. Massacci, A. Zuccotti, C. Fuoco, C. Gargioli, L. Castagnoli and G. J. S. r. Cesareni (2019). "The immunosuppressant drug azathioprine restrains adipogenesis of muscle Fibro/Adipogenic Progenitors from dystrophic mice by affecting AKT signaling." Scientific reports **9**(1): 4360.
- Ségui, B., O. Cuvillier, S. Adam-Klages, V. Garcia, S. Malagarie-Cazenave, S. Lévêque, S. Caspar-Bauguil, J. Coudert, R. Salvayre and M. J. T. J. o. c. i. Krönke (2001). "Involvement of FAN in TNF-induced apoptosis." The Journal of clinical investigation **108**(1): 143-151.
- Silici, S., O. Ekmekcioglu, G. Eraslan and A. J. U. Demirtas (2009). "Antioxidative effect of royal jelly in cisplatin-induced testes damage." Urology **74**(3): 545-551.
- Sönmez, M., G. Türk and A. J. T. Yüce (2005). "The effect of ascorbic acid supplementation on sperm quality, lipid peroxidation and testosterone levels of male Wistar rats." Theriogenology **63**(7): 2063-2072.
- Stuckert, A. J., E. S. Schafer, M. B. Bernhardt, P. Baxter, J. J. L. Brackett and Lymphoma (2019). "Use of allopurinol to reduce hepatotoxicity from 6-mercaptopurine (6-MP) in patients with acute lymphoblastic leukemia (ALL)." Leukemia & Lymphoma: 1-4.
- Suvarna, K. S., C. Layton and J. D. Bancroft (2018). Bancroft's Theory and Practice of Histological Techniques E-Book, Elsevier Health Sciences.
- Tapner, M. J., B. E. Jones, W. M. Wu and G. C. J. J. o. h. Farrell (2004). "Toxicity of low dose azathioprine and 6-mercaptopurine in rat hepatocytes. Roles of xanthine oxidase and mitochondrial injury." Journal of hepatology **40**(3): 454-463.
- Temamoğulları, F., F. Aral and R. J. P. j. o. v. s. Yılmaz (2018). "Royal jelly protection on flunixin meglumine-induced spermiotoxicity and testicular degeneration in mice." Polish journal of veterinary sciences.
- Türk, G., M. Sönmez, A. O. Çeribaşı, A. Yüce and A. J. I. I. Ateşşahin (2010). "Attenuation of cyclosporine A-induced testicular and spermatozoal damages associated with oxidative stress by ellagic acid." International Immunopharmacology **10**(2): 177-182.
- Valiollahpoor Amiri, M., H. Deldar and Z. J. S. b. i. r. m. Ansari Pirsaraei (2016). "Impact of supplementary royal jelly on in vitro maturation of sheep oocytes: genes involved in apoptosis and embryonic development." Systems biology in reproductive medicine **62**(1): 31-38.
- Walker, W. H. and J. J. R. Cheng (2005). "FSH and testosterone signaling in Sertoli cells." Reproduction **130**(1): 15-28.

- Wang, H., J. Wang, J. Zhang, S. Jin, H. J. E. t. Li and pharmacology (2017). "Role of PI3K/AKT/mTOR signaling pathway in DBP-induced apoptosis of testicular sertoli cells in vitro." Environmental toxicology and pharmacology **53**: 145-150.
- Wang, R.-S., S. Yeh, C.-R. Tzeng and C. J. E. r. Chang (2009). "Androgen receptor roles in spermatogenesis and fertility: lessons from testicular cell-specific androgen receptor knockout mice." Endocrine reviews **30**(2): 119-132.
- Weber, K. and M. J. J. o. B. C. Osborn (1969). "The reliability of molecular weight determinations by dodecyl sulfate-polyacrylamide gel electrophoresis." Journal of Biological Chemistry **244**(16): 4406-4412.
- Whalen, K. (2018). Lippincott illustrated reviews: pharmacology, Lippincott Williams & Wilkins.
- Wu, Y. T., C. Shen, J. Yin, J. p. Yu, Q. J. P. R. A. I. J. D. t. P. Meng and T. E. o. N. P. Derivatives (2006). "Azathioprine hepatotoxicity and the protective effect of liquorice and glycyrrhizic acid." An International Journal Devoted to Pharmacological and Toxicological Evaluation of Natural Product Derivatives **20**(8): 640-645.
- Wyrobek, A. J., L. A. Gordon, J. G. Burkhart, M. W. Francis, R. W. Kapp Jr, G. Letz, H. V. Malling, J. C. Topham and M. D. J. M. R. R. i. G. T. Whorton (1983). "An evaluation of the mouse sperm morphology test and other sperm tests in nonhuman mammals: A report of the US Environmental Protection Agency Gene-Tox Program." Mutation Research/Reviews in Genetic Toxicology **115**(1): 1-72.

Figures

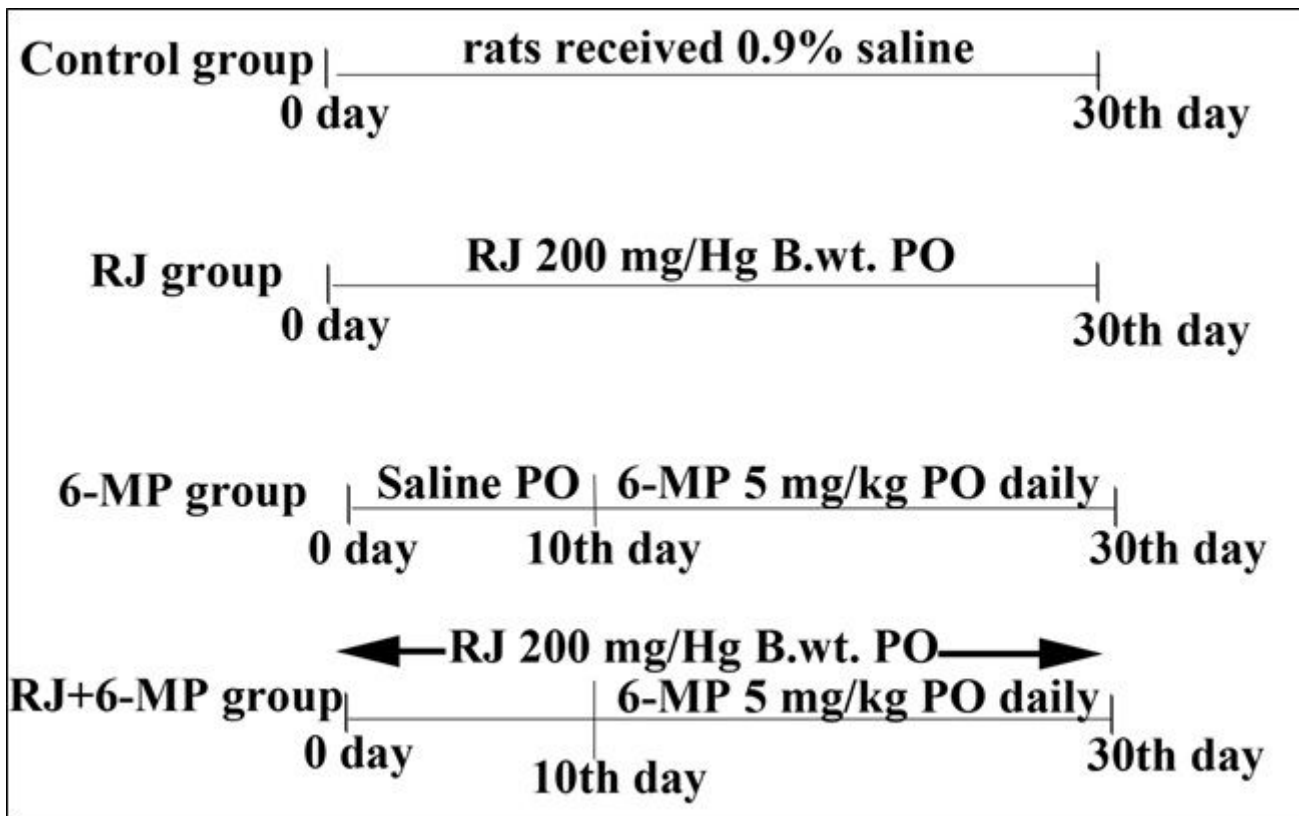


Figure 1

Summary of the experimental design shows the different treated groups, specific dose and duration of each treatment.

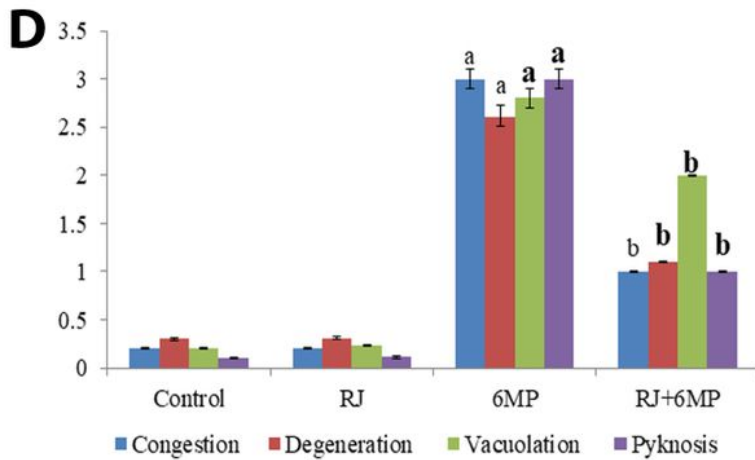
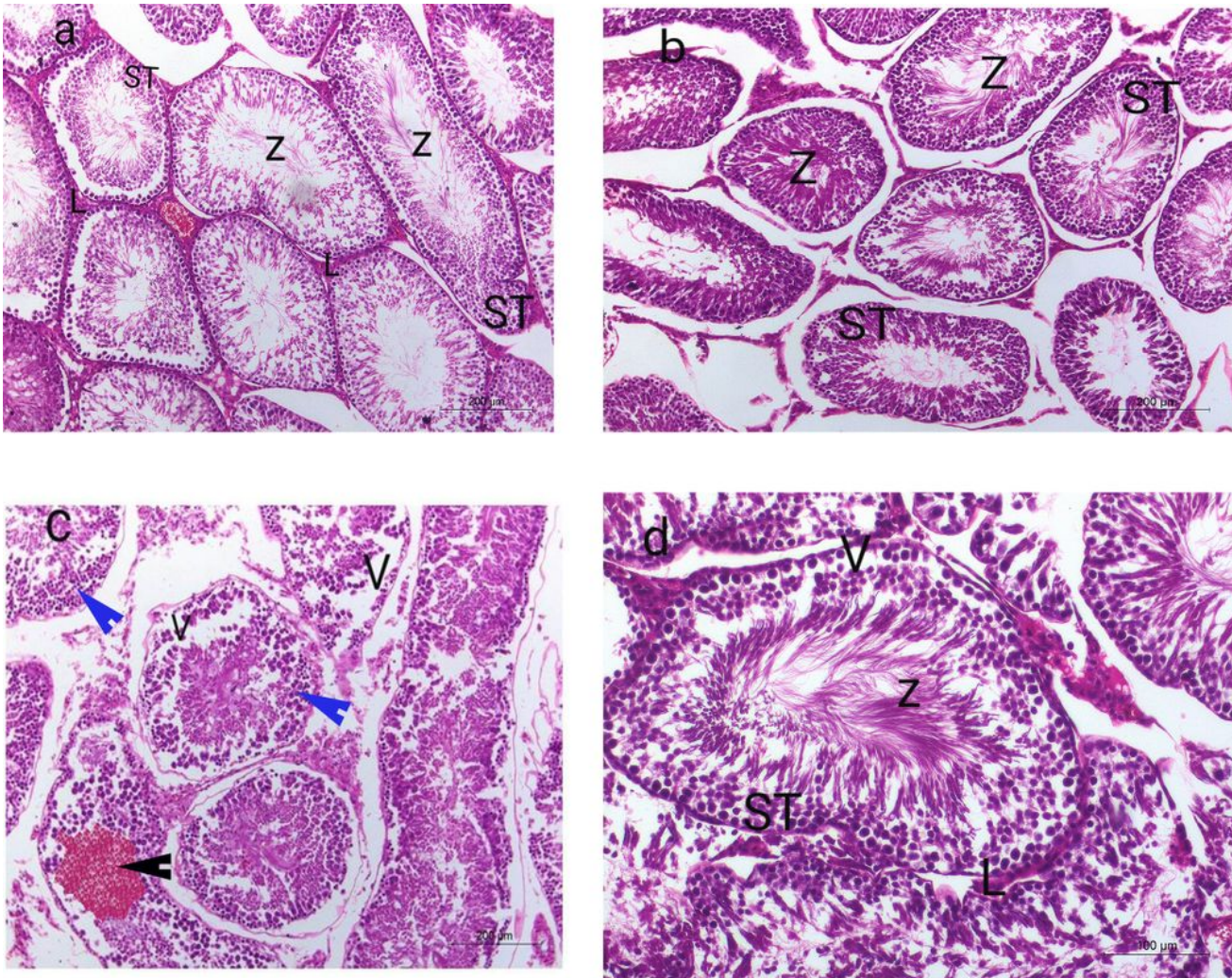


Figure 2

Representative photomicrographs of H&E-stained sections of rat testes in each experimental group: a) Light microscopy of the testicular tissue of control group showed a complete spermatogenesis; seminiferous tubules (ST) were lined by spermatogonial cells, Sertoli cells with the presence of Leydig cells (L) in the interstitial tissue, (Z) spermatozoa. b) The testicular tissue of RJ group showed more or less normal seminiferous tubules having complete spermatogenesis. c) The testicular tissue of 6MP

group revealed the presence of severe testicular degeneration; vacuolation (V) in the tubular cells and pyknosis (Blue arrow) of seminiferous tubules, loss of tissue architecture and accompanied with accumulation of the degenerated cells within the lumen. Interstitial areas were widened with degenerated Leydig cells and presence of severe congestion (Black arrow). d) testicular tissue of RJ+6MP group showed variable degrees of improvement to the degree to be similar to that of control group. The histopathological examination of rat testis from the control group (fig.2a) indicated that (fig.2b). (fig. 2d)

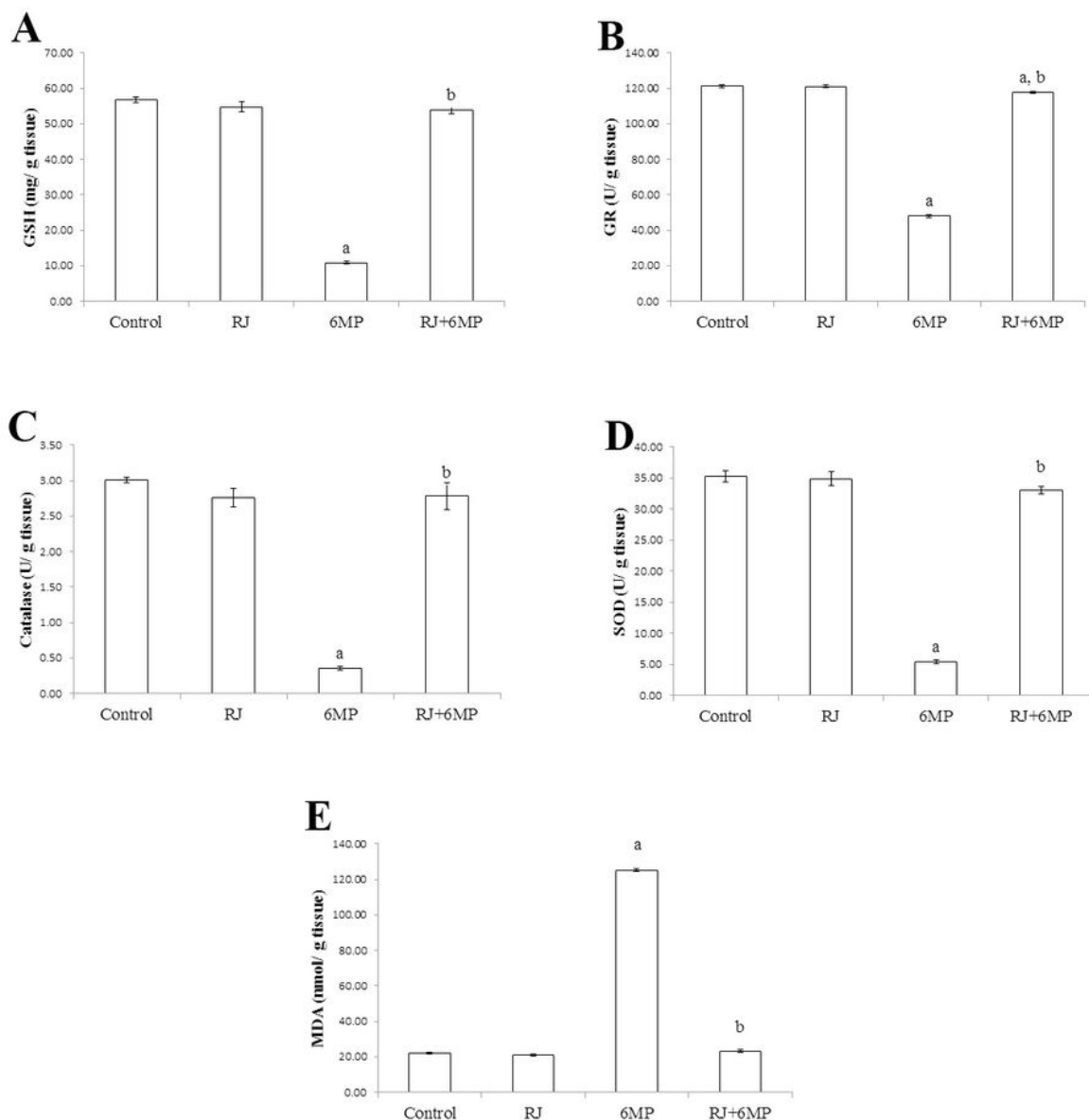


Figure 3

Testicular antioxidant/oxidative redox parameters. A) GSH; reduced glutathione (mg/ g tissue). B) GR; glutathione reductase (U/ g tissue), C) Catalase (U/ g tissue), D) SOD; super oxide dismutase (U/ g tissue) and E) MDA; malonaldehyde (nmol/ g tissue). Values are means \pm SE, n = 10. a indicates a significant difference compared to control group at P<0.05. b indicates a significant difference compared to 6MP at P<0.05.

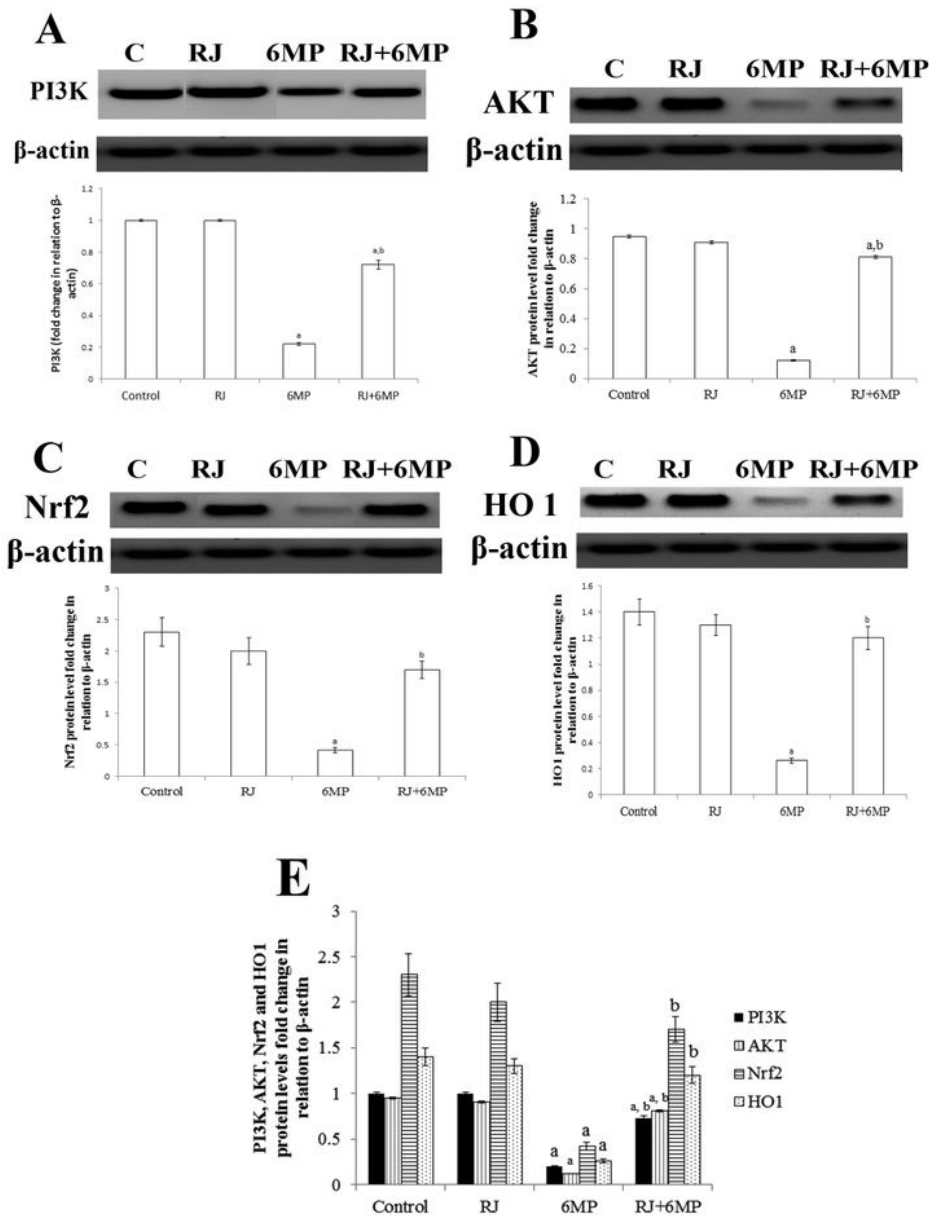


Figure 4

Effect of 6MP on testicular PI3K/AKT-Nrf2/HO1 pathway-related protein expression. A) The most representative images of western blotting and the expression level of PI3K protein relative to β -actin. B) The most representative images of western blotting and the expression level of AKT protein relative to β -actin. C) The most representative images of western blotting and the expression level of Nrf2 protein relative to β -actin. D) The most representative images of western blotting and the expression level of HO1 protein relative to β -actin. E) comparison of PI3K, AKT, Nrf2, HO1 protein levels in different treated groups. Values are means \pm SE, n = 10. a indicates a significant difference compared to control group at P<0.05. b indicates a significant difference compared to 6MP group at P<0.05.

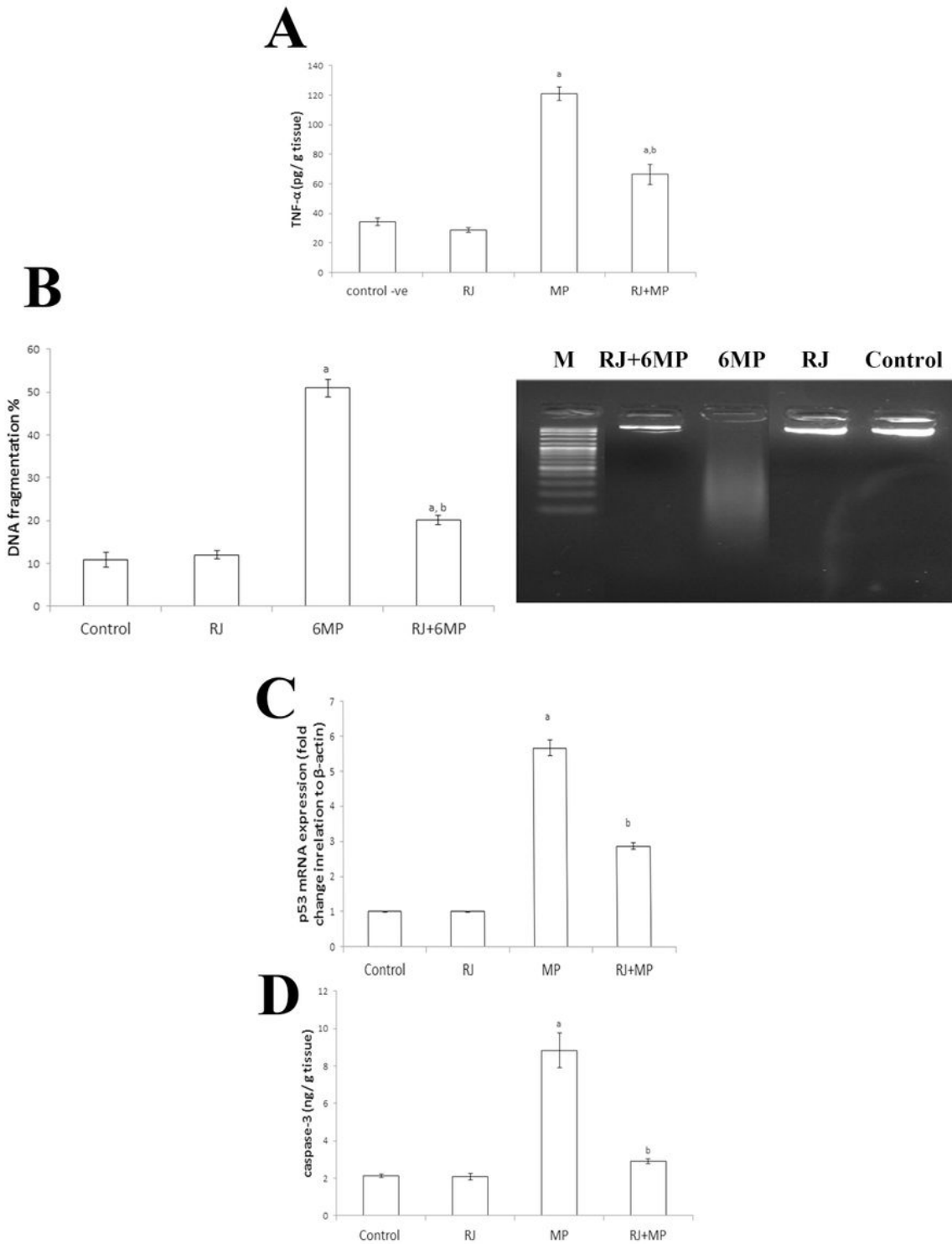


Figure 5

The effect of 6MP on testicular TNF- α , DNA fragmentation %, P53 mRNA and caspase-3. A) TNF- α ; tumor necrosis factor alpha in different treated groups. B) DNA fragmentation % in different treated groups. C) P53 mRNA expression by real time PCR in different treated groups. E) Caspase-3 level in different treated groups. Values are means \pm SE, n = 10. a indicates a significant difference compared to control group at P<0.05. b indicates a significant difference compared to 6MP at P<0.05.