Radiologist's Perspectives on the Use of Imaging for Diagnosis and Monitoring of Chronic Nonbacterial Osteomyelitis

Farzana Nuruzzaman (farzana.nuruzzaman@stonybrookmedicine.edu)
Stony Brook Children's Hospital https://orcid.org/0000-0002-2660-019X

Mingqian Huang
Mount Sinai Hospital

Christian M. Hedrich
Women's and Children's Health Network

Hermann J. Girschick
Vivantes Klinikum im Friedrichshain

Julie Cherian
Stony Brook Children's Hospital

T. Shawn Sato
UIHC: The University of Iowa Hospitals and Clinics

Polly J. Ferguson
The University of Iowa Roy J and Lucille A Carver College of Medicine

Karen B. Onel
Hospital for Special Surgery

Xing Wang
Seattle Children's Research Institute

Yongdong Zhao
Seattle Children's Hospital

Research article

Keywords: chronic nonbacterial osteomyelitis, survey, imaging, radiology

Posted Date: November 19th, 2020

DOI: https://doi.org/10.21203/rs.3.rs-109523/v1

Abstract

Background. Radiological imaging is integral to the diagnosis of chronic nonbacterial osteomyelitis (CNO). Objectives of this study were: 1) to determine imaging modalities and features deemed important by radiologists in the diagnostic workup of suspected CNO cases; 2) to generate input from radiologists regarding monitoring of patients with CNO.

Methods. The population targeted were actively practicing radiologist physician members of the Society of Skeletal Radiology. The survey was administered online through RedCap. Fisher's exact test was used to examine associations between any two categorical variables. FDR adjusted p-values were used for the pairwise comparisons of proportions for more than 2 groups. A mixed effects logistic regression model was used to assess the association between variables.

Results. Half of the survey respondents were pediatric radiologists, subspecializing in musculoskeletal radiology and 54% had >10 years of experience. Radiologists considered CNO in the radiological imaging interpretation differential diagnosis an average of 10 cases per year. 79% and 45% of respondents reported high confidence in identifying imaging features of CNO on whole body MRI (WBMRI) and localized MRI, respectively. The level of confidence dropped to 25% and 19% when interpreting X-rays or bone scintigraphy. Among all imaging modalities interpreted “always” in the initial diagnostic workup of potential cases of CNO, X-rays (52%) were most commonly interpreted, followed by localized MRI (46%) and WBMRI (35%). In established cases of CNO, wherein WBMRI was the most frequently requested (48%), followed by localized MRI (26%) and X-rays (25%).

Conclusions. By radiologists, WBMRI is currently considered the most useful imaging modality for initial diagnosis and monitoring of CNO by radiologists. Findings from this survey will promote discussion within a focused group to develop imaging recommendations for the diagnostic workup and disease monitoring in CNO.

Background

Chronic nonbacterial osteomyelitis (CNO), with its severe form chronic recurrent multifocal osteomyelitis (CRMO), is an auto-inflammatory bone disease that causes skeletal inflammation characterized by bone pain and swelling that primarily affects children [1]. Radiological imaging is integral to the diagnosis of CNO as illustrated by its inclusion in all previously suggested diagnostic criteria [2, 3]. Despite these criteria, CNO is still diagnosed on the basis of excluding alternative etiologies including infection and malignancy. Thus, patients with CNO still experience an average diagnostic delay of 2 years [4]. Utilizing whole-body (WB) imaging, especially WBMRI (magnetic resonance imaging), has improved the sensitivity of detecting CNO lesions [5, 6]. Radiologists have a significant impact on imaging workflows and play an important role in making decisions regarding further diagnostic testing including bone biopsy for clinicians.

Disease monitoring of CNO can be challenging due to lack of guidelines, abnormal physical exam findings or laboratory aberration. WBMRI was deemed as the gold standard for disease monitoring [7]. A majority of pediatric rheumatologists caring for patients with CNO reported using new lesions on radiographic imaging as a marker of disease activity [7]. However, the lack of standardization for follow up imaging leads to variability in both frequency and modality. Thus, we conducted a survey of radiologists through the Society of Skeletal Radiology. The objectives of this study were: 1) to determine imaging modalities and radiographic features deemed important by radiologist physicians in the diagnostic workup of potential CNO cases; 2) to generate input from radiologist physicians regarding the long-term imaging monitoring of established patients with CNO. This information is a key step towards the development of consensus imaging guidelines in CNO, which may allow for earlier diagnosis and standardization of long-term imaging monitoring for patients with CNO, thereby improving patient outcomes.

Methods

This research project was approved by Stony Brook University's Institutional Review Board. The survey **(Supplement 1)** was developed based upon feedback from a subgroup of the Childhood Arthritis and Research Alliance (CARRA) CRMO Workgroup. Multiple-choice questions were used and free-text responses were solicited in addition to general questions. The survey was administered through a REDCap database [8]. The survey was distributed through the Society of Skeletal Radiology (SSR) via Email. Initial email and two reminders were sent over 12 weeks between May 7, 2019 and August 7, 2019. Questions included individual practice type/experience, the utilization of specific imaging modalities in the diagnosis of potential cases of CNO, long-term imaging monitoring of established cases of CNO, and confidence levels in identifying CNO features on various imaging modalities. Responses were summarized using frequencies and percentages. Reported percentages were out of the total number of respondents. Fisher's exact test was used to examine associations between any two categorical variables. FDR adjusted p-values were used for the pairwise comparisons of proportions for more than 2 groups. A mixed effects logistic regression model was used to assess the association between variables.

Results

Sixty-six out of 1500 (5%) attending physicians from Society of Skeletal Radiology answered the survey. A large proportion of respondents had greater than 10 years of experience (28 respondents). Two-thirds of respondents worked in North America, while the remaining were distributed between Europe and Asia primarily. Thirty-four respondents were pediatric musculoskeletal radiologists (54%), 19 respondents were general pediatric radiologists (29%), and 13 respondents were adult musculoskeletal (MSK) radiologists (20%). Two-thirds of respondents (66%) spent less than or equal to half of their time reading specifically MSK imaging. Sixty-eight percent of respondents (36/53) considered CRMO on the differential diagnosis in less than 10 new cases per year **(**Table 1**).** Not all questions were answered by every survey participant, resulting in small decreases in denominator values for select questions.

Table 1
Survey Respondents Characteristics and Demographics

Characteristics	N* (%)
Subspecialty	
Pediatric Musculoskeletal Radiology	**34 (52)**
Pediatric General Radiology	**19 (29)**
Adult Musculoskeletal Radiology	**13 (20)**
Location of Professional Institution	
North America	**36 (68)**
Other[#]	**17 (32)**
Year of Attending Physician/Consultant Experiences	
> 10 years	**28 (54)**
≤ 10 years	**24 (46)**
Time Spent on MSK Imaging	
> 50% of time	**18 (34)**
≤ 50% of time	**35 (66)**
New Cases per year CNO considered in Imaging	
≥ 10	**17 (32)**
< 10	**36 (68)**
Established CNO Cases per year followed by Imaging	
≥ 10	**19 (42)**
< 10	**26 (58)**
*= number of participants who responded to survey question	
[#]= Asia, Europe, South America, Australia	

Twelve of forty-nine respondents (25%), felt “completely confident” or “very confident” in identifying imaging studies of CNO on X-ray alone, in contrast to 37/49 (79%) on whole body MRI, or 22/49 (45%) on localized MRI (Fig. 1). There was no difference in respondents who reported high confidence levels on WBMRI depending on primary location of practice (North America; 82% vs Other; 71%) ($p = 0.3$). Confidence levels in identifying features of CNO on WBMRI did not significantly differ by years of practice in radiology (54% and 46% reporting high confidence for those with ≤ 10 years of experience vs. >10 years of practice experience). However, confidence levels in identifying features of CNO on X-ray (33

vs 67%) and computerized tomography (CT) scan (30 vs. 70%) did seem to be lower in respondents with less than 10 years of experience. More respondents who read MSK imaging < 50% of the time felt high levels of confidence in identifying features on WBMRI. Confidence levels in identifying features of CNO on localized MRI appears to be associated with the number of cases interpreted per year. Those with more experience interpreting cases of potential CNO reported increased levels of confidence ($p = 0.004$). Across radiologists' experience level, respondents feel most confident in WBMRI compared to X-rays for identifying features of CNO (odds ratio 73, $p < 0.001$).

Per radiologists, sites of bone involvement deemed "typical" for CNO were in descending order: metaphysis of long bones (74%; 49/66), clavicle (71%, 47/66), and long bones in lower extremity (61%, 40/66), iliosacral bones (41%, 27/66), vertebrae (36%; 24/66), mandible (36%; 24/66), long bones in upper extremity (26%; 17/66), diaphysis of long bones (14%; 9/66), and other including feet (5%; 3/66).

Among all imaging modalities that were "always" requested in the initial diagnostic workup of potential cases of CNO, X-rays (52%) were most commonly interpreted, followed by localized MRI (45%) and WBMRI (35%), which suggested the sequence of utilization of these three imaging modalities in new cases. In established cases of CNO, wherein WBMRI was the most frequently interpreted (48%), followed by localized MRI (26%) and X-rays (25%) (Fig. 2).

Among responders who interpreted MRI images for evaluating CNO (n = 43), 95% found the STIR sequences to be helpful, followed by T1 (74%), DWI (diffusion weighted imaging) (42%), post contrast T1 (40%), T2 (40%), and T1 with fat saturation (FS) (19%). Findings of active CNO disease to radiologists included signal changes suggestive of bone marrow edema (93%), soft tissue inflammation (83%), and periosteal reaction (74%). 72% of respondents reported using an established WBMRI protocol at their institutions. Sequences used in established MRI protocols were: short tau inversion recovery (STIR) or turbo inversion recovery magnitude (TIRM) (n = 31, 100%), T1 (n = 21, 68%), diffusion weighted imaging (DWI) (n = 8, 26%), post contrast T1 (n = 3, 10%), regular T2 (n = 2, 7%), and other (namely post contrast T2 Dixon = 2, 6%).

Reported frequencies of suggesting a bone biopsy when imaging is suggestive of CNO were 44% (rarely), 27% (sometimes), 16% (never), 11% (often), and 2% (always). More than half of respondents felt that clinical/laboratory information was "fairly to very" important to prompt a recommendation of bone biopsy in radiological interpretation (15/18). The most common imaging features on X-Rays/CTs that led respondents to suggest a bone biopsy were disorganized bone formation (64%, 56%), moth-eaten appearance (61%, 56%), and lytic lesions (50%, 44%), respectively and presence of soft tissue mass (68%), soft tissue swelling (44%) and hyperintensity of bone marrow at unifocal site (24%) on MRI.

No respondents reported using a systemic classification system when reporting radiological reports.

Discussion

To our knowledge, this is the first survey to assess the overall practice of a sampling of radiologists in the imaging evaluation of both potential CNO and long-term imaging monitoring of patients with established CNO. Using a survey, we captured important aspects of the confidence levels, imaging utilization patterns, attitudes towards WBMRI's role in the diagnosis and monitoring of CNO and imaging features that may correlate with increased change of bone biopsy.

It is notable that while a large number of respondents had greater than 10 years of experience as attending radiologists, the majority of them evaluated fewer than 10 potential new cases per year. This may be due to the fact that CNO being a relatively rare condition emphasizing the need for collaborative studies to determine clinical imaging scoring and in turn measurable outcomes for prospective clinical trials.

Typical sites of CNO per radiologists reporting to this survey appears to consistent with existing descriptions of bone involvement in cohorts of pediatric patients with CNO in which there is a predilection towards metaphyses of long bones, particularly those of the lower extremity [9], clavicle, and pelvis. In one published cohort of 30 pediatric patients with CNO, the most common distribution of CNO bone lesions were, in descending order of frequency: ankle (33%), clavicle (24%), calcaneus (19%), and femur (17%) [10]. In a more recent cohort of 70 pediatric patients with CNO from 3 tertiary centers in the United States, the most frequent sites of CNO involvement were: tibia (41%), pelvis (34%), femur (29%), vertebrae (24%), clavicle (23%), fibula (21%), and mandible (21%) [11].

Initial Diagnostic Workup of Potential CNO Cases

Radiologist physicians were more confident in identifying imaging features suggestive of CNO on MRI as compared to X-ray. Indeed, this observation was identified across all levels of experience among radiologists. This attitude aligns with prior research showing that MRI is superior to XR in identification of CNO lesions [12]. MRIs are more sensitive than XR, particularly in early disease in which plain radiographs are often entirely normal [13]. Imaging modalities with higher dose of radiation such as CT and bone scintigraphy are performed in more than of half of patients with CNO despite bone scintigraphy being less sensitive in the metaphysis or epiphysis of long bones of growing children [3] and CT scan's lack of sensitivity to identify inflammatory lesions. The sequence of imaging modality interpretation in workup for potential CNO cases usually started with plain radiographs, followed by regional MRI and then WBMRI. This is similar to the order of the imaging modalities reported by pediatric rheumatologists in a study by Zhao *et.al.*, in which among all imaging modalities used often or always, XR (89%) were most commonly used diagnostic imaging modality, followed by regional MRI (78%), and bone scintigraphy (43%) [5]. This sequential pattern of utilization contributes to the increased time from presentation to diagnosis.

A majority of respondents preferred a combination of STIR, T1 and DWI sequences in the MRI images of potential CNO cases. The sequences that were preferred by radiologists did not entirely correlate with existing studies which suggest that gadolinium-enhanced T1 or strongly T2 weighted sequences (TIRM)

with fat saturation can be used and are superior to conventional radiographs or scintigraphy [13]. DWI's use in musculoskeletal diagnoses is a relatively new technique that may not have been as widely available in the past [14]. More recently, STIR sequences in the coronal plane were most thought to be helpful in CNO, as well as reported to be the most commonly utilized sequence in routine WBMRI protocol [15]. The benefits of a coronal STIR sequence allow a larger field of view than axial sequences and the ability to highlight multiple pathologies especially within solid viscera and bone marrow, generally less artifact, and more homogenous fat suppression compared to fat-suppressed conventional T2-weighted images [16]. Thus, there have been changing views in regards to which sequences may be most sensitive and specific for evaluating for CNO by MRI reported in the literature, especially as findings may vary during different phases of clinical remission in children.

WBMRI is the most sensitive modality to detect active bone lesions in CNO [7, 17–19]. However, it appears to be underutilized as only 35% of radiologists responding to this survey used it for the initial diagnostic workup of CNO. This is in concordance with prior reported data, in which only about 36% of pediatric rheumatologists used this technique [7] though WBMRI usage varies among centers [9]. There was a discrepancy about interpretation of bone scan and MRI. In the survey study from pediatric rheumatologists, bone scintigraphy was used more often than MRI, which may be related to better overall availability [7]. However, due to its high radiation exposure and lack of sensitivity in CNO, its use is less preferred. Thus, it is critical to increase awareness of the role of WBMRI in disease monitoring of CNO and to decrease barriers towards its use.

While not routinely suggested, certain imaging features were felt to raise the need for potential bone biopsy to confirm a diagnosis of CNO by a small proportion of radiologists. Both Jannson *et al.* and Roderick *et al*. suggested a scoring system in which a threshold score to obtain a bone biopsy in a child based on multiple clinical, lab, and imaging factors; specifically, whether bone scintigraphy was negative or showed unifocal lesions [2, 3]. As MRI may be more sensitive than bone scintigraphy, particularly in growing children and radiologists feel more confident in identifying features of CNO on MRI as compared to bone scintigraphy, its inclusion in any potential future scoring systems for obtaining a bone biopsy would be helpful to avoid invasive diagnostic methods in children and perhaps help children be diagnosed earlier on in their disease.

Long Term Imaging Monitoring in Established Cases of CNO

In established cases of CNO, while MRI was most frequently interpreted, only half of respondents disclosed its use that suggested an underutilization of MRI even in patients with a known diagnosis of CNO. This is worrisome in that some patients may have an underestimation of their disease burden by lack of WBMRI as it has shown that about one-third of patients with CNO may have asymptomatic lesions that are only detected by WBMRI [3, 9] and that clinical remission does not necessarily equate radiological remission [15, 19].

Radiological definition of active and inactive disease has not been specifically detailed in CNO. In the survey reported, most respondents agreed that signal changes suggestive of bone marrow edema (60.6%) and soft tissue inflammation (54.4%) on MRI indicated active CNO disease. A disease activity score (PedsCNO score) developed by Beck *et al.* included the number of radiological lesions [17]. Additionally, 68% of physicians felt that resolution of abnormal MRI signals suggested a feature of inactive diseases [7]. However, the total number of lesions reported may be affected by whether a WBMRI was performed or not. Therefore, disease status should include imaging findings in addition to patient reported outcomes, physical exam findings, lab markers. Ideally, WBMRIs should at least be performed at diagnosis to help exclude alternative diagnoses if multifocal lesions are present as well as help identify unexpected/clinically silent lesions particularly of the spinal column, which may necessitate more aggressive therapy to prevent long-term damage [18]. Also, because imaging can show changes in disease activity that is affected by treatments [18, 20–21], its inclusion is important for prospective follow-up of patients. More than one quarter of patients with CNO (26.7%) reported difficulties with obtaining MRI imaging [3]. As physicians previously reported that treatment decisions are often made upon radiographic imaging, this may lead to inadequate treatment and therefore affect patient outcomes.

Furthermore, this study illustrates the dichotomy between radiologist preference and real-life utilization practices of images in CNO. While 35% of respondents utilized a WBMRI, its use may be limited due to costs, reimbursement options, and the amount of time that may be required. However, as MRI technology advances, shortening imaging time while maintaining high quality is possible. This is particularly important in younger patients who may need sedation so a risk/benefit analysis must be done. In our experience, certain centers have CNO protocols, only applying coronal STIR or TIRM sequences, that allow the images to be acquired within 20–30 minutes, and there are reports of some WBMRI protocols requiring one hour or less from localization to completion. Despite this, Schooler *et al.* reported that about a quarter of respondents reported using a WBMRI protocol requiring greater than 60 minutes [16]. Adopting a more feasible WBMRI protocol based on an international group's consensus and applying the developed standardized scoring [23] can be used in randomized clinical trials for treatments in CNO.

Our study has several limitations. Firstly, the response rate from radiologist physicians was low; hence there could have been survey-sampling bias. However, this may suggest the unfamiliarity of CNO imaging in initial diagnosis and long-term imaging monitoring among the general radiologist community as a whole. Secondly, there may be deviations between answers to the survey and actual practice. Thirdly, the definition of CNO may vary among physicians.

Despite the limitations, this study identifies key issues and unanswered questions among radiologists around diagnostic approaches, and disease monitoring using imaging technologies. Results from this study will guide further discussion within a focused group to develop consensus imaging guidelines for children with CNO. Indeed, the imaging for CNO has advanced over the years, particularly in the ability to improve image quality with shortened image times for MRI, in particular WBMRI, highlighting the need for re-assessment of current imaging guidelines in which it is still considered "investigational" [24]. Guidelines are used in a variety of practices and developed from different sources from peer-review

literatures to expert panels. Due to the lack of utilization of WBMRI, which is often hindered by insurance denials, underestimation of disease burden often occurs. Updated consensus imaging guidelines may help ease insurers' concerns of unnecessary tests, therefore increasing approval of utilization of WBMRI in CNO, reducing overall patient costs, and adding value to healthcare. Additionally, a targeted guideline for imaging may lead to improved overall healthcare costs by reaching correct diagnosis of CNO early and avoiding inappropriate and harmful treatments such as prolonged antibiotics, and even long-term intravenous line usages.

Conclusions

Among radiologists participating in this survey, WBMRI is considered the most useful imaging modality for initial diagnosis and monitoring of CNO by radiologists across all experience levels. Certain morphological features including disorganized bone structure, moth-eaten appearance, lytic lesions, soft tissue mass/swelling and unifocal signal hyperintensity of bone marrow most likely result in a bone biopsy to exclude differential diagnoses. Statements from this survey will be used by a focused group, including radiologists and pediatric rheumatologists with extensive experience in diagnosing and managing CNO, to develop imaging guidelines for the diagnostic workup and disease monitoring in CNO and contribute to earlier diagnosis and individualized care.

Abbreviations

CNO
chronic nonbacterial osteomyelitis
WBMRI
whole body magnetic resonance imaging
CRMO
chronic recurrent multifocal osteomyelitis
CARRA
Childhood Arthritis and Research Alliance
MSK
musculoskeletal
CT
computerized tomography
DWI
diffusion weighted imaging
STIR
short tau inversion recovery
TIRM
turbo inversion recovery magnitude

Declarations

Ethics approval

This study was reviewed and approved by the human research protection program at Stony Brook University Institutional Review Board (#1343738-2).

Consent for publication

Not applicable

Availability of data and materials

De-identified data available upon request to corresponding author with attainment of proper data transfer agreements as per institutional guidelines.

Competing interests

Y. Zhao, P. Ferguson, C. Hedrich, H. Girschick: Consultant for Novartis

Funding

Funding for Statistical Analysis: Seattle Children's Hospital CRMO Research

Authors' Contributions

FN, MH, CH, HG, JC, TS, PF, KO, and YZ conceptualized and designed study including survey development and administration. FN collected the data. XW, FN, YZ contributed to data analysis and performed data interpretation. XW performed most of the statistical analysis. FN wrote the first draft of the manuscript. All authors read and approved the final manuscript.

Acknowledgements

We acknowledge the contributions of all radiologist physicians who responded to the survey.

References

1. Ferguson PJ, Laxer RM. Autoinflammatory bone disorders. In: Cassidy J, Petty R, Lindsley C, Laxer RM, editors. Textbook of Pediatric Rheumatology. Amsterdam: Elselvier; 2011. pp. 661–73.
2. Jansson A, Renner ED, Ramser J, et al. Classification of non-bacterial osteitis: retrospective study of clinical, immunological and genetic aspects in 89 patients. Rheumatology. 2007;36(1):154–60.
3. Roderick MR, Shah R, Rogers V, Finn A, Ramanan AV. Chronic recurrent multifocal osteomyelitis (CRMO)–advancing the diagnosis. Pediatr Rheumatol Online J. 2016;14:47.

4. Oliver M, Lee TC, Halpern-Felsher B, Murray E, Schwartz R, Zhao Y. Disease burden and social impact of pediatric chronic non-bacterial osteomyelitis from the patient and family perspective. Pediatr Rheumatol. 2018;16:1–8.
5. Fritz J, Tzaribatchev N, Claussen CD, Carrino JA, Horger MS. Chronic recurrent multifocal osteomyelitis: comparison of whole-body MR imaging with radiography and correlation with clinical and laboratory data. Radiology. 2009;252(3):842–51.
6. Guerin-Pfyffer S, Guillaume-Czitrom S, Tammam S, Kone-Paut I. Evaluation of chronic recurrent multifocal osteitis in children by whole-body magnetic resonance imaging. Joint Bone Spine. 2012;79(6):616–20.
7. Zhao Y, Dedeoglu F, Ferguson PJ, Lapidus SK, Laxer RM, Bradford MC, Li SC. Physicians' perspectives on the diagnosis and treatment of chronic nonbacterial osteomyelitis. Int J Rheumatology. 2017;76(9):49–42.
8. Harris PA, Taylor R, Thielke R, Payne J, Gonzalez N, Conde JGJ. Research electronic data capture (REDCap)–a metadata-driven methodology and workflow process for providing translational research informatics support. Biomed Inform. 2009;42(2):377–81.
9. Schnabel A, Range U, Hahn G, Berner R, Hedrich CM. Treatment response and long term outcomes in children with chronic nonbacterial osteomyelitis. J Rheumatol. 2017;44(7):1058–65.
10. Girschick HJ, Raab P, Surbaum S, Trusen A, Kirschner S, Schneider R, Papadopoulos T, Müller-Hermelink HK, Lipsky PE. Chronic non-bacterial osteomyelitis in children. Ann Rheum Disease. 2005;64(2):279–85.
11. Borzutzky A, Stern S, Reiff A, Zurakowski D, Steinberg EA, Dedeoglu F, Sundel RP. Pediatric chronic nonbacterial psteomyelitis. Pediatrics. 2012;130;e1190.
12. Morbach H, Schneider P, Schwarz T, Hofmann C, Raab P, Neubauer H, Düren C, Beer M, Girschick HJ. Comparison of magnetic resonance imaging and 99mTechnetium-labelled methylene diphosphonate bone scintigraphy in the initial assessment of chronic non-bacterial osteomyelitis of childhood and adolescents. Clin Exp Rheumatol. 2012;30:578–82.
13. Hedrich CM, Hofmann SR, Pablik J, Morbach H, Girschick HJ. Autoinflammatory bone disorders with special focus on chronic recurrent multifocal osteomyelitis (CRMO). Pediatr Rheumatol Online J. 2013;11:47.
14. Baliyan V, Das CJ, Sharma R, Gupta AK. Diffusion weighted imaging: technique and applications. World J Radiol. 2016;8(9):785–98.
15. Leclair N, Thörmer G, Sorge I, Ritter L, Schuster V, Hirsch FW. Whole-body diffusion-weighted imaging in chronic recurrent multifocal osteomyelitis in Children. PLoS ONE. 2016;11(1):e0147523.
16. Schooler GR, Davis JT, Daldrup-Link HE, Frush DP. Current utilization and procedural practices in pediatric whole-body MRI. Pediatric radiology. 2018;48(8):1101–7.
17. Beck C, Morbach H, Beer M, et al., Chronic nonbacterial osteomyelitis in childhood: prospective follow-up during the first year of anti-inflammatory treatment. Arthritis Research and Therapy. 2010. 12; R74.

18. Zhao Y, Wu EY, Oliver MS, Cooper AM, Basiaga ML, Vora SS, Lee TC, Fox E, Amarilyo G, Stern SM, Dvergsten JA, et al. Consensus treatment plans for chronic nonbacterial osteomyelitis refractory to nonsteroidal anti-inflammatory drugs and/or with active spinal lesions. Arthritis Care Res. 2017;70:1228–37.
19. Voit A, Arnodli A, Douis H, Bleisteiner F, Jansson MK, Reiser MF, Weckbach S, Jansson AF. Whole-body magnetic resonance imaging in chronic recurrent multifocal osteomyelitis: clinical long term assessment may underestimate Activity. J Rheumatol. 2015;42:1455–62.
20. Kellenberger CJ, Epelman M, Miller SF, Babyn PS. Fast STIR whole-body MR imaging in children. Radiographics. 2004;24:1317–30.
21. Zhao Y, Chauvin NA, Jaramillo D, Burnham JM. Aggressive therapy reduces disease activity without skeletal damage progression in chronic nonbacterial osteomyelitis. The Journal of Rheumatology. 2015;42(7):1245–51.
22. Bhat CS, Roderick M, Sen EE, et al. Efficacy of pamidronate in children with chronic non-bacterial osteitis using whole body MRI as a marker of disease activity. Pediatr Rheumatol. 2019;17:35.
23. Zhao Y, Sato TS, Nielsen SM, Beer, Huang M, Iyer RS, McGuire M, et al. Development of a scoring tool for chronic nonbacterial osteomyelitis magnetic resonance imaging and evaluation of its interrater reliability. J Rheumatol. 2020;47(5):739–47.
24. eviCORE Clinical Guidelines. Musculoskeletal Imaging Policy. Version 1.0 2020. https://www.evicore.com/-/media/files/evicore/clinical-guidelines/solution/cardiology-and-radiology/2020/evicore_msk_imaging_eff021420_pub101519.pdf. Accessed February 14, 2020.

Figures

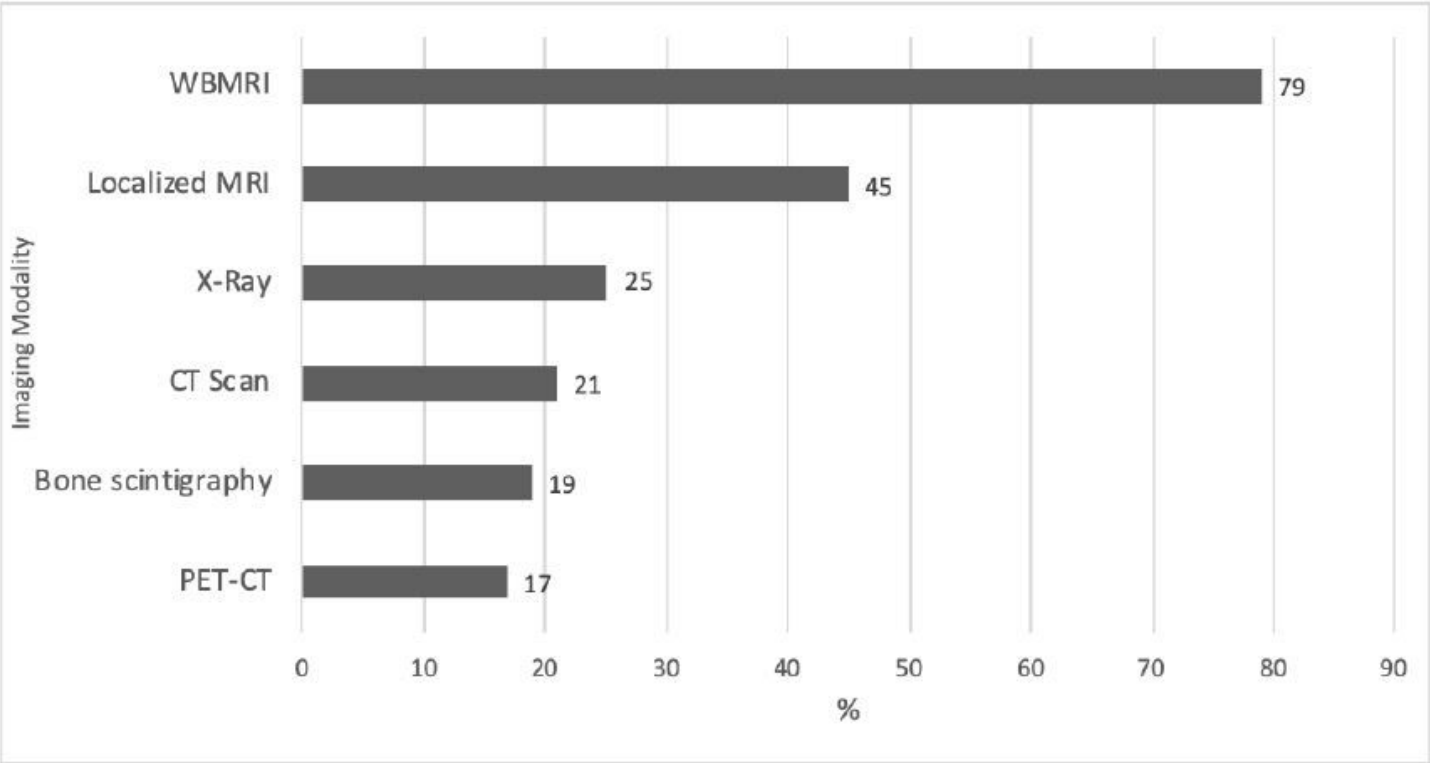

Figure 1

Percent reporting high confidence in identifying CNO imaging features, by imaging modality

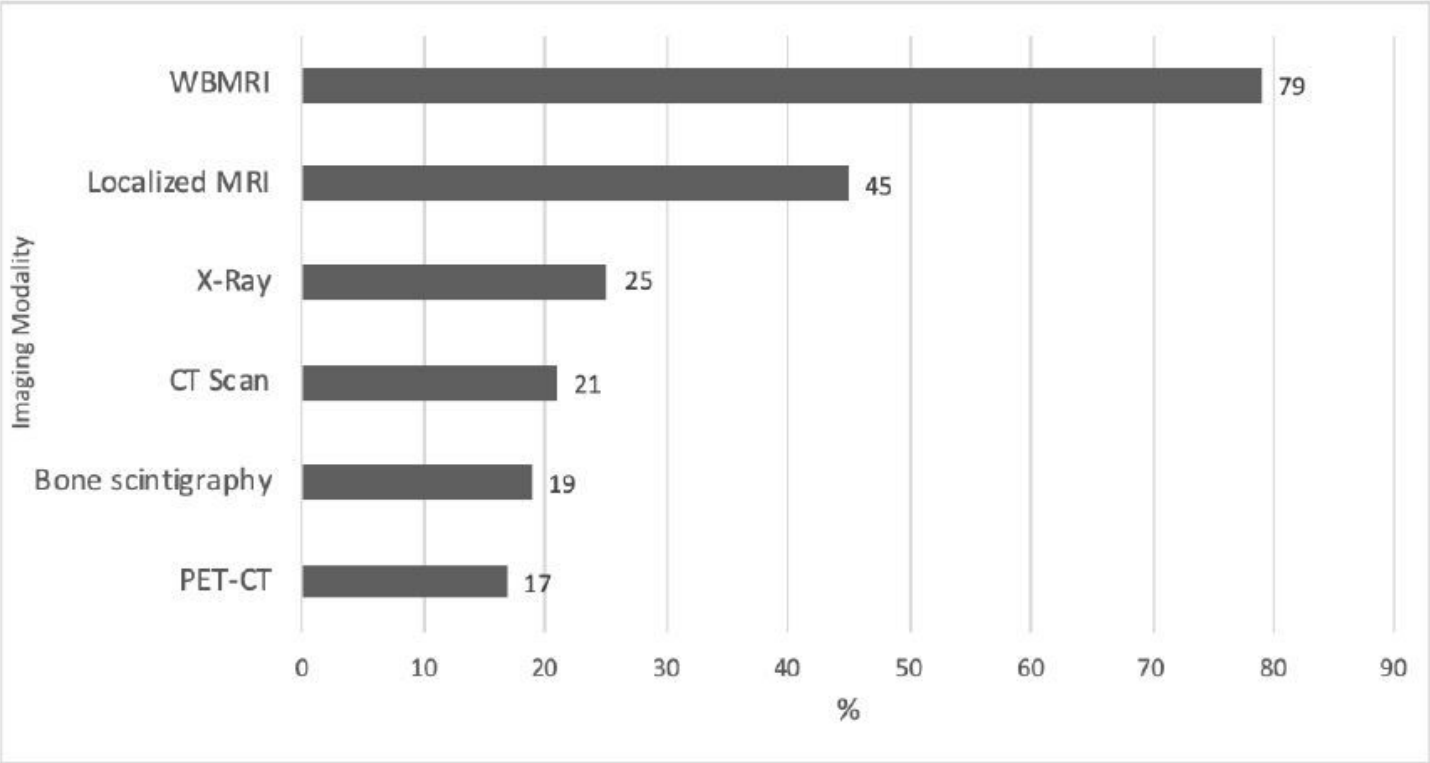

Figure 1

Percent reporting high confidence in identifying CNO imaging features, by imaging modality

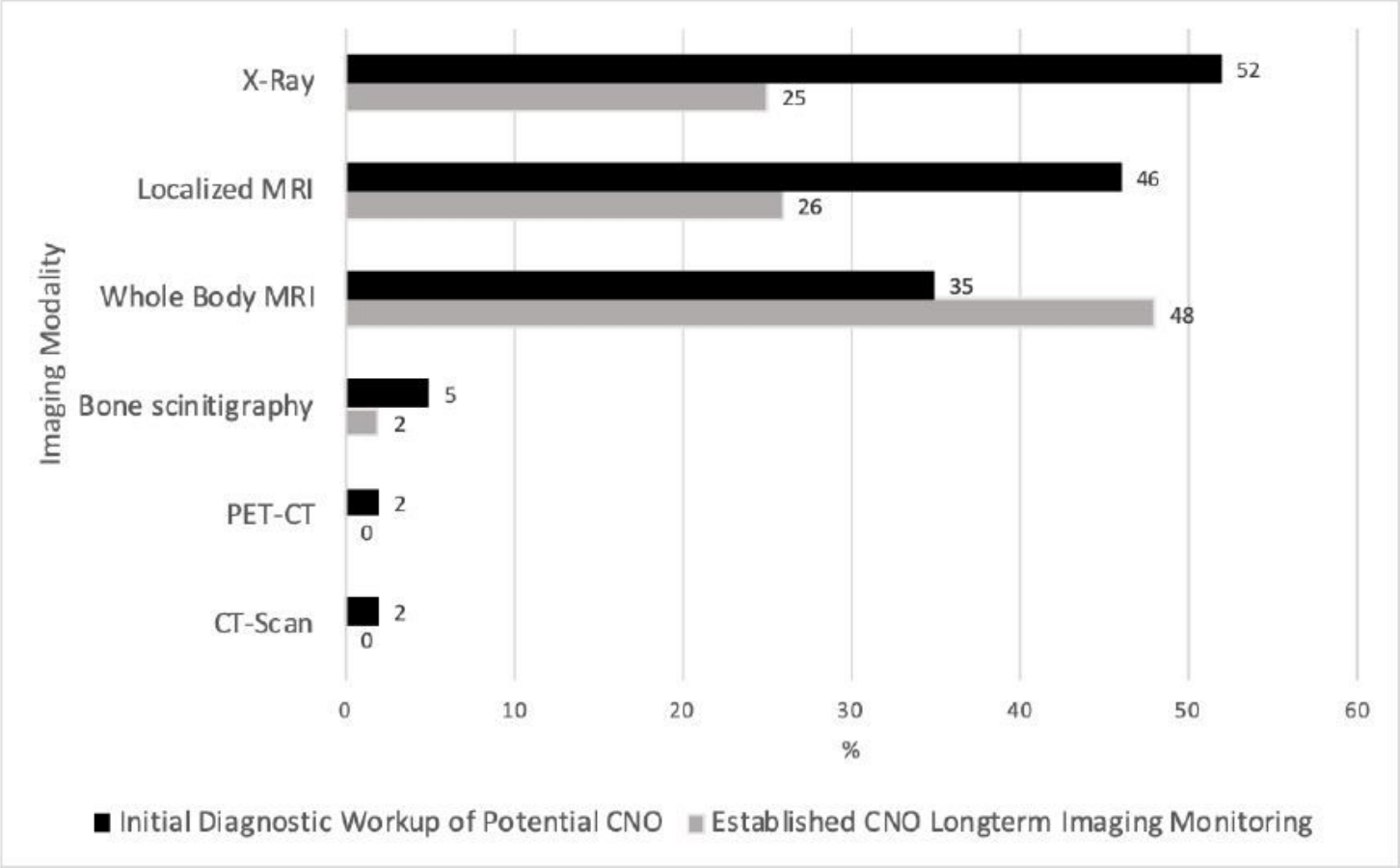

Figure 2

Percent interpreted imaging modality “always” in initial diagnostic workup and long-term imaging monitoring of patients with possible CNO and established CNO, respectively

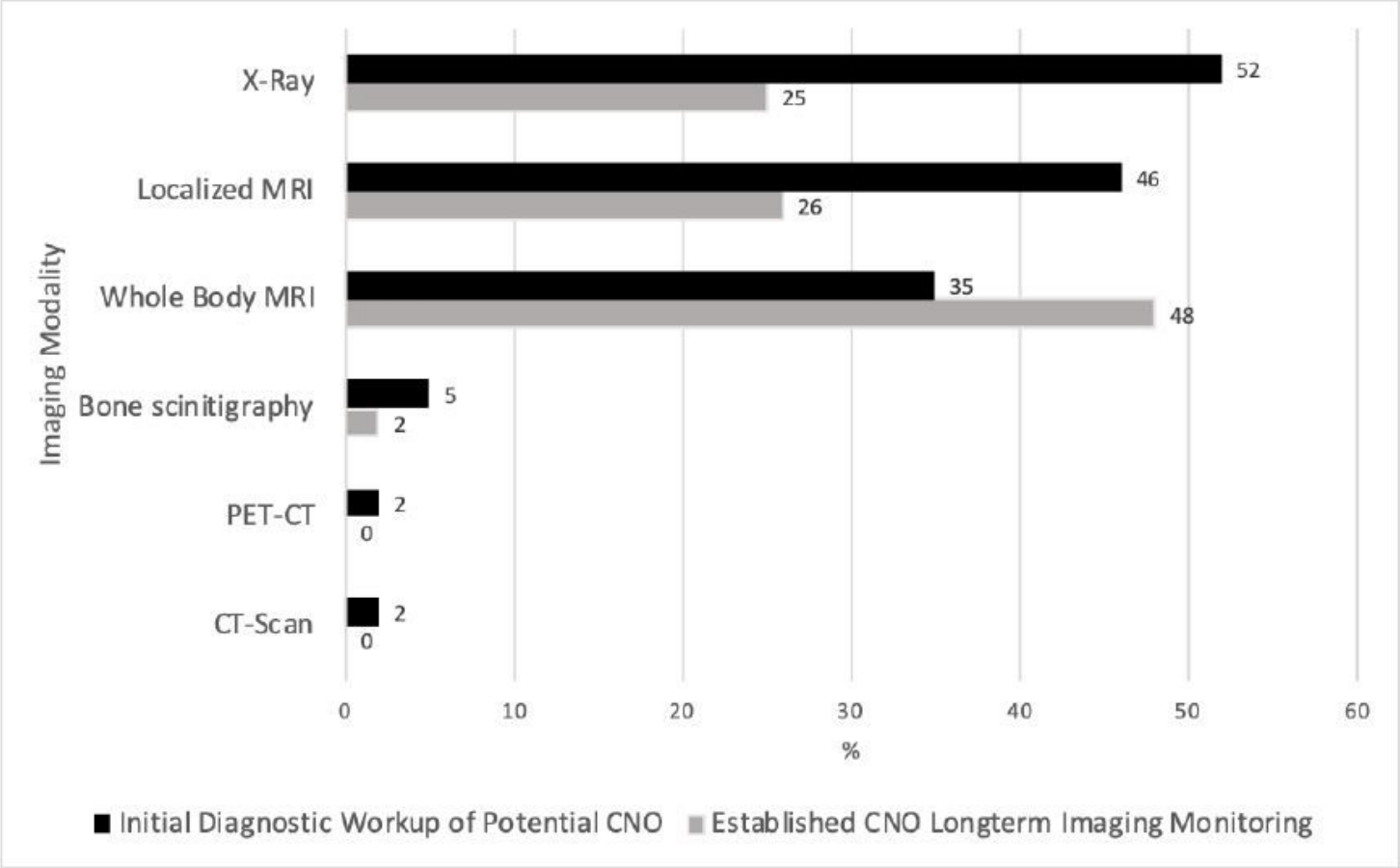

Figure 2

Percent interpreted imaging modality “always” in initial diagnostic workup and long-term imaging monitoring of patients with possible CNO and established CNO, respectively