New Modification of Vertical Muscle Transposition to Enhance Abducting Force in Sixth Nerve Palsy

Santa Heede (santa.heede@gmx.de)
Universitatsklinikum Hamburg-Eppendorf https://orcid.org/0000-0002-2624-0980

Irina Kovalevskaya
Military Medical Academy

William Astle
Calgary Health Region

Sandra Valeina
Bernu Kliniska Universitates Slimnica

Uwe Griebenow
Berufsakademie Sachsen

Research Article

Keywords: sixth nerve palsy, vertical muscle transposition, modification, abduction

Posted Date: December 13th, 2021

DOI: https://doi.org/10.21203/rs.3.rs-1098734/v1

Abstract

Purpose:

Since 1907, multiple transposition procedures have been established for the treatment of abducens paralysis. In this study, we try to determine where the transposed muscle should be reattached in order to increase the tangential force necessary to improve abduction.

Methods:

Retrospective case review of 12 consecutive patients with abducens paralysis. All patients underwent the transposition procedure between 2016 and 2019.

Vertical rectus muscles are transposed to the insertion of lateral rectus muscle: The temporal parts are joined and sutured to the sclera on top of the lateral rectus muscle in the middle of the insertion. The nasal parts are sutured to the sclera following the spiral of Tillaux. The muscle junction suture is placed 8 mm from the insertion: The temporal parts of the vertical muscles bellies are joined and sutured to the lateral rectus muscle.

A full tendon transposition was performed on 11 patients, a half tendon transposition procedure on one patient. The minimum follow-up was 3 months.

Results:

The mean preoperative deviation was ET of 37° (range: ET 24° to ET 51°). The mean preoperative abduction limitation was 5 mm from midline (range: -7 to -1mm). The postoperative mean deviation was ET of 2° PD (range: 0 to ET 5°). The postoperative mean abduction improvement was 5mm past midline (range: +2 to +6mm). There were no complications, or signs of anterior segment ischemia.

Conclusions:

To achieve the maximal abductive force from the transposed muscles, we suggest that the vertical muscles be reattached as close as possible to the middle of the lateral rectus insertion.

Introduction

Abducens nerve palsy (6th cranial nerve) is the most common of the isolated ocular motor nerve palsies.

For over 100 years the strabismus surgeons have attempted to find the perfect method to improve and normalize abduction weakness induced by the palsy. Since 1907, multiple transposition procedures have been established with good results, yet the search continues to consistently restore fusion and normal ductions [1–7].

The idea of all transposition procedures is to shift the forces of the vertical muscles to the paralytic lateral rectus muscle. The outcome of the surgery depends not only on the severity of nerve damage, but also on how constricted the medial rectus muscle becomes [1, 8].

Interestingly, when comparing different studies [9], every transposition procedure can achieve a satisfactory outcome in the primary position. The major problem is to move the eye past the midline, and restore normal duction of the eye.

For example physics can calculate where a pulling string should be attached to a ball in order to achieve a maximal tractive force. The calculation of a three-dimensional mechanical problem can be very complicated. To describe the distribution of forces on an eyeball a two-dimensional case can be considered. Figures 1a to 1b show a virtual eye with attached muscle at point M. F_Z represents the tractive force produced by a muscle. F_T represents the tangential force causing the eye to rotate, whereas F_R equals a radial force and does not result in any rotation. The muscle strength is therefore most effective if attached at point M (angle $\alpha = 0°$). The larger the angle α, the less effective is the tangential force F_T.

Those two-dimensional calculations supported the idea, that the most effective tangential force can be achieved if a transposed muscle was attached to the middle of the lateral rectus muscle insertion or at the point M, respectively.

Our main objective in this study was to evaluate the enhanced abduction achieves after such a modified transposition procedure.

Study Design

Retrospective case review of 12 consecutive patients with sixth nerve paralysis.

A new modification of transposition procedure for abducens palsy was created and performed by surgeon S.H. During the 15th congress “Ophthalmologicum Balticum 2016” the procedure was introduced and discussed with surgeons I.K. ,W.A. and S.V. To create a sufficient cluster of patients, a decision was made to perform the new modification in different countries by different surgeons: S.H., I.K. and W.A.

Each patient presenting with sixth nerve paralysis received the new modification. Each surgeon was at liberty to augment the transposition with additional procedures if needed, such as Botox injection in medial rectus muscle, an additional lateral rectus resection, or a half tendon transposition, if deemed necessary.

All patients underwent the transposition procedure between 2016 and 2019.

The surgeries were performed at the Children’s Clinical University Hospital in Riga (Latvia), the Military Medical Academy, St Petersburg (Russian Federation) and the *Alberta Children's Hospital Calgary,*

Canada. The data has been collected and analyzed.

Methods

After approval by the Research Ethics Committee of Riga Stradins University in Latvia, the medical records of all twelve patients were reviewed retrospectively.

Twelve patients with abducens nerve palsy and limited abduction that did not reach the midline were included. The age range of the patients was 8 to 63 years.

Nine patients developed an abducens palsy after trauma, one patient secondary to a brain tumor, and one patient due to *alcoholic neuropathy. One patient developed a pseudo palsy due to a lost muscle, after strabismus surgery in childhood (Table 1).*

Orthoptic measurements

All patients underwent ophthalmological (best corrected vision at distance, slit lamp and fundus examination) and orthoptic assessments.

The primary angle of deviation was measured in prism diopters, at both distance and at near. For statistical evaluation, the values of prism diopters were converted in degrees. A fixation target was used. Motility was measured monocularly in millimeters, using Kestenbaum-Glasses. The paralytic eye was illuminated with a light source positioned at the root of the nose at a distance of 40 cm. The resulting corneal light reflex was determined as point zero or midline. The patient was then asked to maximally abduct, attempting to look to the paralytic side. The difference from point zero and the middle of corneal light reflex (slightly nasally) during maximal abduction was measured, in millimeters, using the Kestenbaum-Glasses. If the middle of cornea did not reach the midline, the inability to abduct was labeled with a minus sign (-), in millimeters. If the eye passed the midline, the abduction was labeled with a plus sign (+).

Surgical technique

All surgeries were performed under general anesthesia.

All patients received the modified transposition procedure: eleven patients received a full-tendon transposition. One patient received a half-tendon transposition when absence of the lateral rectus muscle was discovered. To decrease the risk of anterior segment ischemia, a half-tendon transposition was performed.

Additionally five patients received botulinum toxin A injections into the medial rectus muscle: four intraoperatively, and one patient one year before surgery. The decision for Botox injection during surgery was made with a positive forced duction test, secondary to a tight medial rectus muscle.

Two patients received lateral rectus resection during surgery. The decision for this procedure was based on discovering a saggy and thin lateral rectus muscle at the time of dissection.

Two patients received a medial rectus recession one year prior to the transposition procedure. *One patient had a bilateral abducens palsy, and received a recession /resection procedure in one eye, and a modified transposition in other eye. For analysis, we included only the motility results of the eye undergoing the transposition (table 1).*

All surgeries were performed by three surgeons: either S.H. , I.K. or W.A.

*Forced duction test*under anesthesia was performed during every*strabismus*surgery, prior to the transposition procedure. The surgical technique included either a full-tendon, or half-tendon transposition of the vertical recti muscles, to the palsied lateral rectus muscle, following the spiral of Tillaux. The conjunctival incision was made from the 12 to 6 o'clock positions, parallel to the limbus and 4mm from limbus. The frenulum between the superior oblique and superior rectus was carefully freed, as well as the connection between the inferior rectus and lower lid retractors. Both vertical rectus muscles were dissected free for 15 mm. In a half-tendon transposition, a short muscle hook was used to bluntly dissect the vertical muscles into two parts. Prior to the dissection, both *anterior* ciliary vessels were inspected to be sure that each part of the muscle contained one. The vertical muscles were then transposed to the insertion of lateral rectus muscle: The temporal parts were joined and sutured to the sclera, on top of the lateral rectus muscle, in the middle of the insertion. The nasal parts of the transposed muscled were then sutured to the sclera, following the spiral of Tillaux.

The muscle junction suture was placed 8 mm from the insertion of lateral, and in the middle of the lateral rectus muscle: The temporal parts of the vertical muscles bellies were joined and sutured to the lateral rectus muscle. Double armed 6-0 polyglactin (Vicryl) sutures were used (Fig. 2a, 2b, 2c).

If requires 2.5 units of Botox were injected into the belly of the medial rectus muscle.

Postoperative examination

An examination under slit lamp was performed within 3 weeks after surgery. The aim of frequent slit lamp examinations was to detect any signs of anterior segment ischemia. Minimum follow-up for all patients was 3 months post-operatively (range: 3mo to 2 years).

Results

Abduction

For assessing abduction improvement post-operatively the data from all twelve patients was reviewed. The augmented transposition improved the abduction of all 12 patients from median -5mm (range: -7 to -1mm) to +5mm (range: +2 to 6mm).

The paralytic eyes of all patients gained an additional 5 to 13 mm of abduction post-operatively (median: 9mm) (Table 1).

Deviation

Pre-operatively the mean distance primary deviation for eleven eyes was 37° esotropia (range: 24° to 51°), with a mean near primary deviation of 31° esotropia (range: 20° to 51°). Three months post surgery, the mean distance primary deviation was 2° ET (range: 0 to 5°), and the near primary deviation 1° ET (range: ET 3° to XT 1°).

Four patients had an esophoria, no manifest esotropia (range: EP 2° to EP 7°) post-operatively.

After surgery three patients had a head posture of 5° or less to avoid the remaining esotropia.

One patient (no. 4, Table 1) had diplopia in primary position but was diplopia free adopting a head posture of 5°. This patient received prisms to achieve fusion in primary position.

Two patients developed a vertical deviation post-operatively with a phorias of 2° and 6° respectively. In both cases the operated eye was hypotropic. Both patients did not have any symptoms or cosmetic concerns with the vertical deviation. No patients complained of torsional diplopia.

Complications

There were no complications during or after surgery. There were no signs of anterior segment ischemia.

Discussion

Sen and colleagues published an extensive literature review of 27 surgical studies with different transposition procedures for abducens palsy in 2019 [9]. All techniques achieved good postoperative results for deviations in primary position: range from slight esotropia of 0,7 PD to esotropia of 32 PD.

Our post-operative results correspond with the majority of other studies: The mean primary deviation at distance postoperatively in our 11 patients (no. 11 was excluded due to bilateral surgery) was ET of 2° (range: 0 to 5°).

In 1997, Foster presented a new modification of vertical muscle transposition [4]. With a posterior fixation suture 8mm posterior to the palsied lateral rectus insertion the abducting force was improved post-operatively. The premise of the Foster procedure is to reduce the space between the transposed vertical muscles and the lateral rectus muscle which then alters the force vectors of the transposed muscles.

The difference in our modified transposition technique is to achieve the maximal traction by attaching the transposed muscles exactly over the middle of the lateral rectus muscle, rather than on each side of the palsied lateral. A muscle junction suture placed in the middle and about 8mm from the insertion, like Foster suggested, could potentially extend the force vector even more. This simplified two-dimensional calculation supported our idea to modify the transposition procedure as noted (Fig. 1a, 1b).

Theoretically the union of vertical muscles with the lateral rectus muscle may cause some scarring with the paralytic muscle, thus potentially shortening and tightening the muscle, similar to a small resection procedure.

Our results demonstrate that our modified transposition procedure leads to a good improvement in abduction ability (Fig. 3 to 8). The mean abduction after surgery was 5 mm beyond midline (range: +2 to +6mm).

The paralytic eyes of all patients gained an additional 5 to 13 mm of maximally possible abduction (median: 9mm) (Table 1).

To determine the motility we used a Kestenbaum-Glasses. The comparison with other studies is more difficult though. The majority of studies use a 6 point scale, whereas 0 means full abduction and -6 means no abduction at all. There are also 5 point scales or 8 point scales in use [10, 11].

Many surgical studies achieve post-operatively an abduction of about -3, which would correspond to 2 to 3 mm beyond midline [4, 5, 11–15] .

Foster achieved after his modified transposition an abduction of -3.5 to -3.0.

Flanders and colleagues combined the full-tendon transposition with Botox injection in the medial rectus muscle. The postoperative mean abduction was -1.7 [10].

The lateral rectus muscle has only one ciliary arteria in comparison to medial rectus muscle. The risk in developing ischemia after resecting the lateral rectus is lower than after recessing the medial rectus [16–20]. Plication of lateral rectus would reduce the risk of ischemia even more, but considering the additional overlying of vertical rectus muscle the thickening could be too excessive.

Unfortunately our patient group isn’t homogenous regarding the surgery procedure: Only three patients received a single modified full-tendon transposition. The abduction beyond the midline after surgery for those three patients was +4mm, +5mm or +6mm respectively.

We think that the combination of vertical muscle transposition augmented with a Botox injection into the medial rectus could improve surgical results further. One of the most important factors in determining the effectiveness of vertical muscle transposition is how restricted the antagonist medial rectus muscle has become over time. Since an additional recession would increase the risk of ischemia, chemodenervation is a solution to this problem.

There are two possibilities discussed in the literature: Botox injection either some months before surgery or intraoperatively with the transposition:

Flanders and colleagues suggest the Botox injection 2 to 8 months before surgery [10] whereas Rosenbaum und Leiba with colleagues used the Botox injection during surgery[21, 22].

As with any vertical muscle transposition, potential complications such as loss of vertical movement, limitation of adduction, and the potential for inducing globe retraction or eyelid anomalies should be considered carefully.

Our results suggest, that the best location for reattaching transposed vertical muscles in order to increase the abductive force in patients with abducens palsy is over top of the middle of the lateral rectus muscle. Fear of overlapping muscles and potential scarring seems to be unfounded. This series of patients, allows the conclusion that this transposition procedure described should be considered as a viable surgical alternative for this complex group of patients.

References

1. Hummelsheim E (1907) Über Sehnentransplantation am Auge. Ophthal Gesselschaft, pp 34–248
2. Jensen CD (1964) Rectus muscle union: a new operation for paralysis of the rectus muscles.Trans Pac Coast Otoophthalmol Soc Annu Meet.:359–387
3. Am O'Connor (1935) Tendon transplantation in ocular muscle paralysis. Am J Ophthalmol RJO 18:813–8201:18:813–820
4. Foster SR (1997) Vertical Muscle Transposition Augmented With Lateral Fixation.J AAPOS:20–30
5. Couser NL, Lenhart PD, Hutchinson AK (2012) Augmented Hummelsheim procedure to treat complete abducens nerve palsy. J AAPOS 16:331–335
6. Neugebauer A, Fricke J, Kirsch A, Rüssmann W (2001) Modified transposition procedure of the vertical recti in sixth nerve palsy. Am J Ophthalmol 131:359–363
7. Muraki S, Nishida Y, Ohji M (2013) Surgical results of a muscle transposition procedure for abducens palsy without tenotomy and muscle splitting. Am J Ophthalmol 156:819–824
8. Kolling GH (2001) Zur Therapie der Abduzensparalyse. Ophthalmologe 98:1169–1175
9. Sen S, Dhiman R, Saxena R, Phuljhele S, Sharma P (2019) Vertical rectus transposition procedures for lateral rectus palsy: A systematic review. Indian J Ophthalmol 67:1793–1799
10. Flanders M, Qahtani F, Gans M, Beneish R (2001) Vertical rectus muscle transposition and botulinum toxin for complete sixth nerve palsy. Can J Ophthalmol 36:18–25
11. Del Pilar González M, Kraft SP (2015) Outcomes of three different vertical rectus muscle transposition procedures for complete abducens nerve palsy. J AAPOS 19:150–156
12. Kinori M, Miller KE, Cochran M, Patil PA, El Sahn M, Khayali S, Robbins SL, Hertle RW, Granet DB (2015) Plication augmentation of the modified Hummelsheim procedure for treatment of large-angle esotropia due to abducens nerve palsy and type 1 Duane syndrome. J AAPOS 19:311–315
13. Lee Y-H, Lambert SR (2017) Outcomes After Superior Rectus Transposition and Medial Rectus Recession Versus Vertical Recti Transposition for Sixth Nerve Palsy. Am J Ophthalmol 177:100–105
14. Paysse EA, Brady McCreery KM, Ross A, Coats DK (2002) Use of augmented rectus muscle transposition surgery for complex strabismus. Ophthalmology 109:1309–1314

15. Esser J, Schmitz F, Eckstein A (2009) Augenmuskelchirurgie bei einseitiger Abduzensparese. Klin Monatsbl Augenheilkd 226:812–817
16. France TD, Simon JW (1986) Anterior Segment Ischemia Syndrome Following Muscle Surgery: The AAPO&S Experience. J Pediatr Ophthalmol Strabismus 23:87–91
17. Hayreh SS, Scott WE (1978) Fluorescein Iris Angiography. II. Disturbances in Iris Circulation Following Strabismus Operation on the Various Recti. Arch Ophthalmol 96:1390–1400
18. Olver JM, Lee JP (1992) Recovery of Anterior Segment Circulation after Strabismus Surgery in Adult Patients. Ophthalmology 99:305–315
19. Rakesh BK, Ravi BK (2015) Anterior segment ischemia following Hummelsheim procedure in a case of sixth nerve palsy. Indian J Ophthalmol 63:543–544
20. Saunders RA, Phillips MS (1988) Anterior Segment Ischemia after Three Rectus Muscle Surgery. Ophthalmology 95:533–537
21. Leiba H, Wirth GM, Amstutz C, Landau K (2010) Long-term results of vertical rectus muscle transposition and botulinum toxin for sixth nerve palsy. J AAPOS 14:498–501
22. Rosenbaum AL, Kushner BJ, Kirschen D (1989) Vertical rectus muscle transposition and botulinum toxin (Oculinum) to medial rectus for abducens palsy. Arch Ophthalmol 107:820–823

Tables

Table 1: Patient characteristics

Patient/ gender	Age/ years	Etiology	pre-OP/ distance	post-OP/ distance	post-OP/ HP, DB	pre-OP/ abd./ mm	post-OP/ abd./mm	Surgery
1. / m	8	trauma	ET 51°	ET 2° EP 7°, -VD2°	HP 5°, no DB	-7	+4	f. Tx + Botox
2. / m	49	trauma	ET 37°	ET 3°, +VD6°	--	-7	+3	f. Tx + Botox
3. / m	51	lost muscle	ET 41°	ET 5°, EP 20°	--	-6	+5	h. Tx + Botox
4. / m	59	*alcoholic neuropathy*	ET 43°	ET 2°	HP 5°, DB	-7	+4	* f. Tx
5. / f	63	brain tumor	ET 25°	ET 1°	--	-6	+4	** f. Tx
6. / m	51	trauma	ET 40°	ET 0, EP 5°	--	-1	+6	f. Tx + Botox
7. / f	39	trauma	ET 31°	ET 0, EP 2°	--	-4	+5	***f. Tx
8. / f	58	trauma	ET 33°	ET 3°	HP < 5°	-3	+2	**f. Tx
9. / m	49	trauma	ET 24°	ET 3°	--	-3	+4	f. Tx
10. / f	62	trauma	ET 42°	ET 0, EP 7°	--	-7	+6	****f. Tx
11. / m	35	trauma	ET 50°	ET 0, EP 5°	--	OD:-3 OS:+5	OD:+5 OS: +9	OD: v. Tx OS: R/R
12. / m	30	trauma	ET 31°	ET 1°	--	-3	+6	f. Tx

m= male; f= female; pre-OP: preoperative; post-OP= postoperative; distance = primary deviation angle, measured in prism diopters for distance, recalculated in degrees; ET= esotropia; EP= esophoria; XP= exophoria; -VD= right eye hypotropic; +VD= right eye hypertropic; abd./mm = abduction measured in millimeters; OD= right eye; OS= left eye; HP= head posture; DB= diplopia; f. Tx = modified full-tendon transposition; h.Tx = modified half-tendon transposition; * = years before Resection-Recession procedure; ** = Transposition combined with lateral rectus resection; *** = Botox injection a year before; **** = a year before medial rectus recession.

Figures

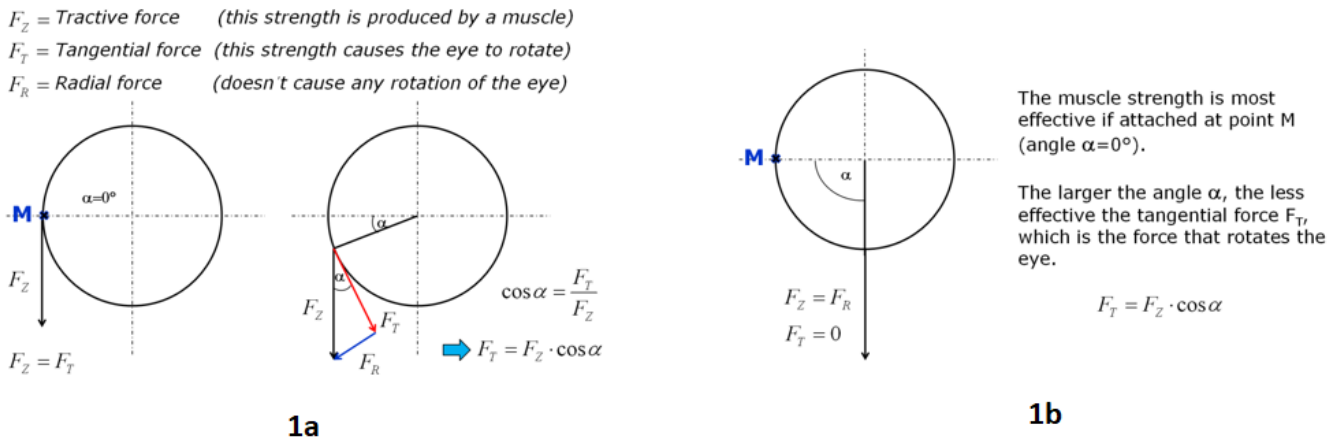

Figure 1

a: Tangential, tractive and radial force (Prof. Griebenow) b: Tangential force (Prof. Griebenow)

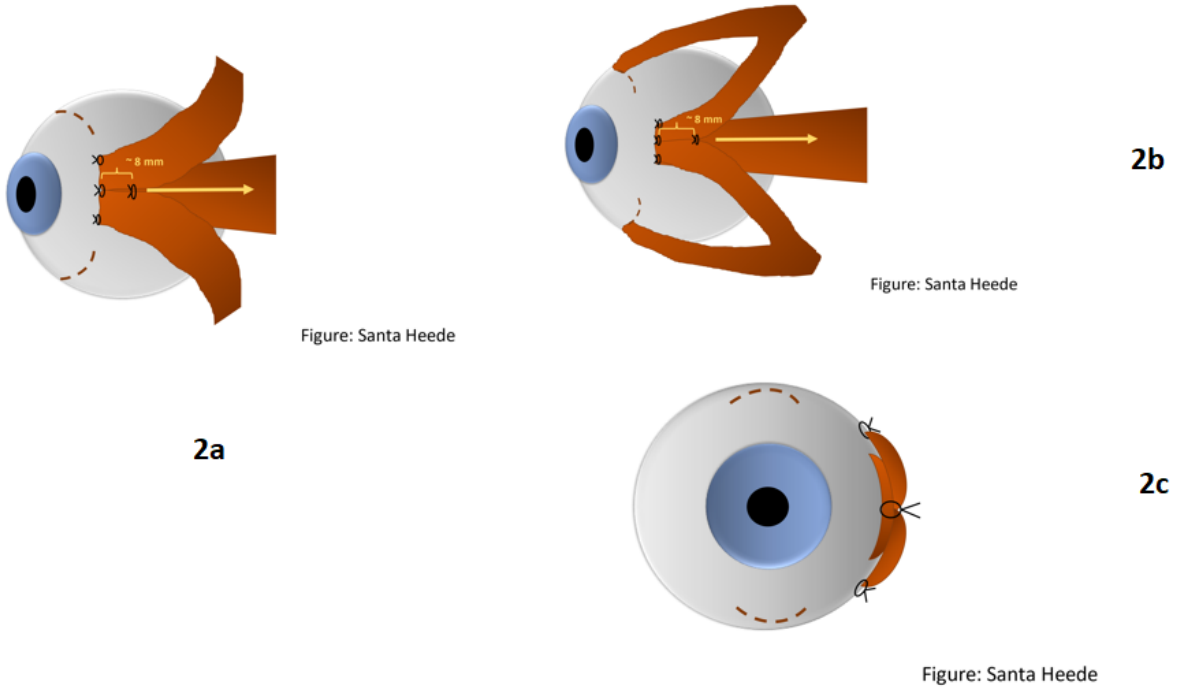

Figure 2

a: Simplified representation without detailed anatomy of modified full-tendon Transposition, side view. b: Simplified representation without detailed anatomy of modified half-tendon transposition, side view c: Simplified representation without detailed anatomy of modified full-tendon transposition, front view

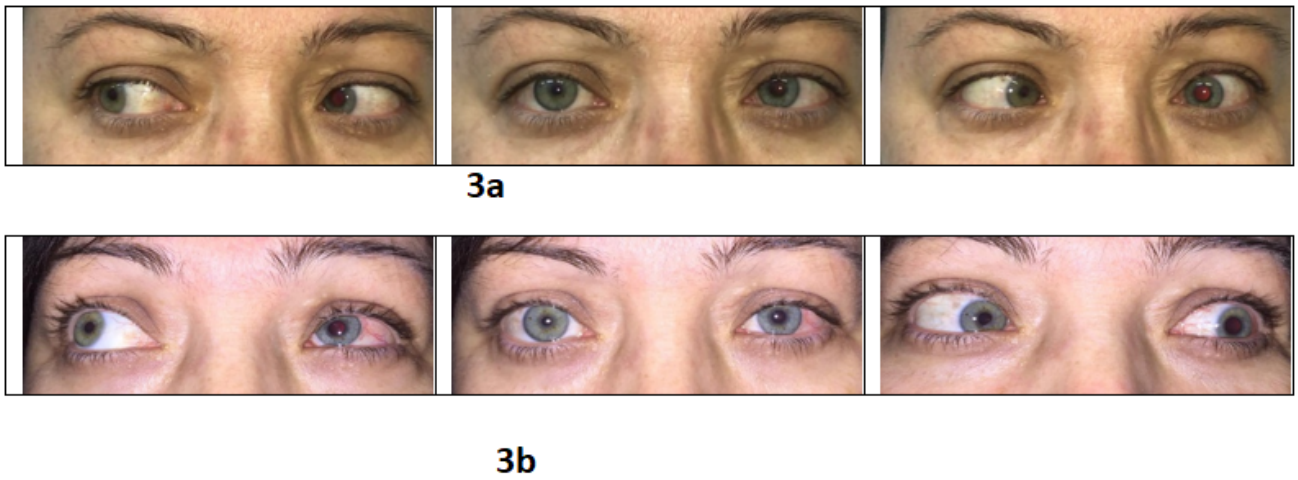

Figure 3

a:Patient no. 7: Prior-surgery, VI Palsy left eye b: Patient no. 7: one month after surgery

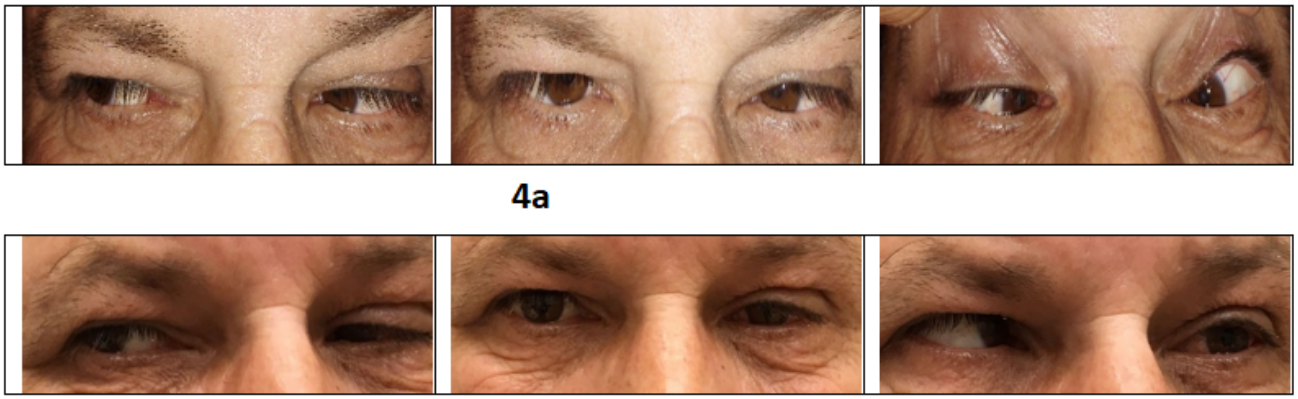

4a

4b

Figure 4

a: Patient no. 2: Prior-surgery, VI Palsy left eye b: Patient no. 2: one year after surgery

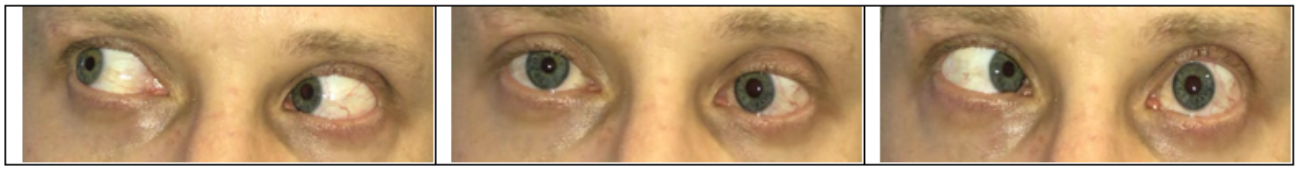

5a

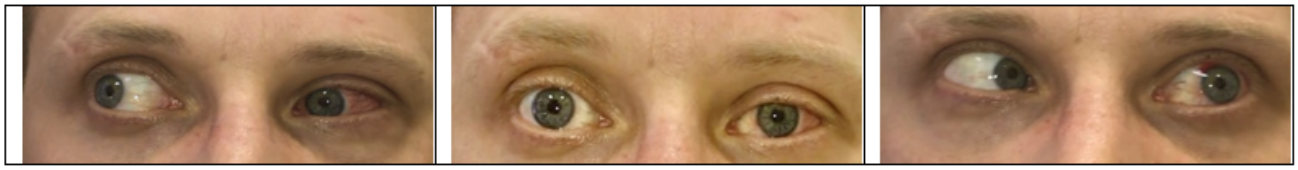

5b

Figure 5

a: Patient no. 12: prior-surgery, VI palsy left eye b: Patient no. 12: one month after surgery

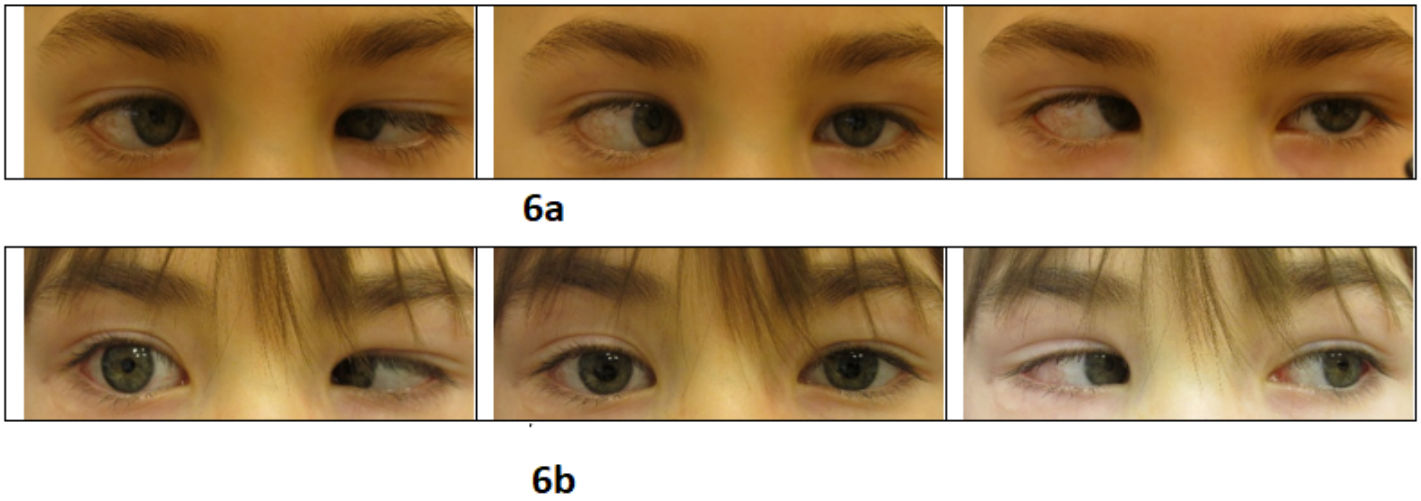

Figure 6

a: Patient no. 1: prior-surgery, VI Palsy right eye b: Patient no. 1: 2 years after surgery

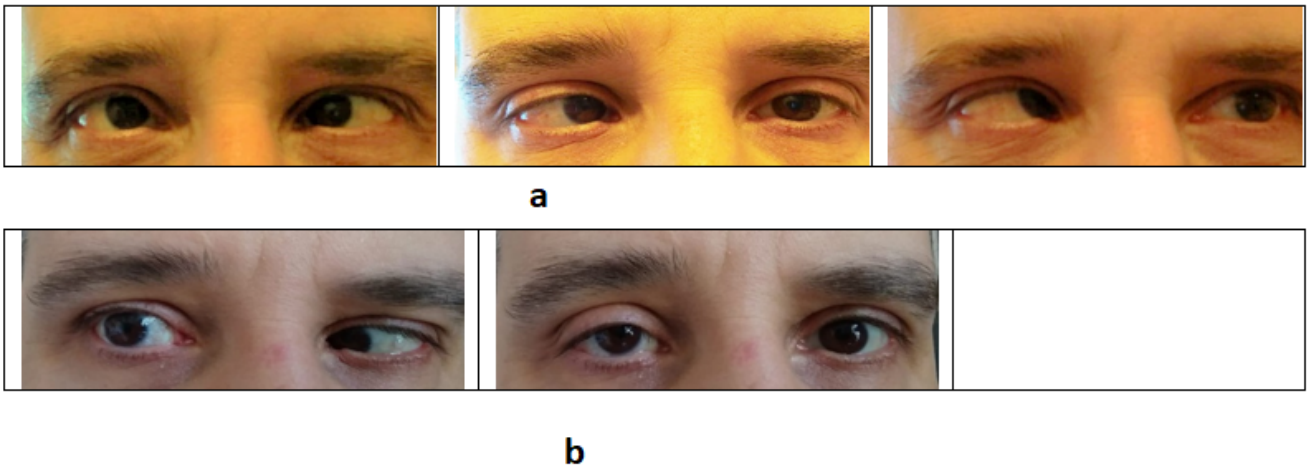

Figure 7

a: Patient no. 3: prior-surgery, lost muscle after previous strabismus surgery, right eye b: Patient no. 3: one year after surgery (unfortunately, photo of left gaze is missing)

Figure 8

a: Patient no. 11: prior-surgery, bilateral Palsy b: Patient no. 11: 3 months after surgery, right eye received the modified transposition