The Differences of the Acromiohumeral Interval Between Supine and Upright Radiographs of the Shoulder

Prakasit Sanguanjit
Thammasat University Hospital
Adinun Apivatgaroon (adino_ball@yahoo.com)
Thammasat University Hospital
Phanuwat Boonsun
Thammasat University Hospital
Surasak Srimongkolpitak
Thammasat University Hospital
Bancha Chernchujit
Thammasat University Hospital

Research Article

Keywords: Acromiohumeral interval, Rotator cuff tear, Supine shoulder radiograph

Posted Date: December 15th, 2021

DOI: https://doi.org/10.21203/rs.3.rs-1102599/v1

Abstract

Background: Acromiohumeral interval (AHI) is a measurement method to determine the superior migration of the humeral head in patients with rotator cuff tears.

Hypothesis/Purpose: The purpose of this study was to compare the AHI measurement in supine shoulder and upright shoulder radiographs, as well as magnetic resonance imaging (MRI), as well as to report the sensitivity, specificity, and accuracy in detecting full thickness rotator cuff tears.

Study Design: Diagnostic study.

Methods: From July 2020 to May 2021, evaluation of 86 shoulder radiographs in both supine & upright Grashey views compared with the MRI of the affected shoulder. Measurements of the AHI obtained from both radiographs and MRIs was determined by two independent orthopaedic surgeons. The intraclass correlation of the AHI measurement was tested. The difference between the AHI in each view was determined.

Result: The 86 shoulders were divided into 3 groups that included; 1) non-full thickness tear (50%), 2) full thickness (FT) tear 3 cm (33.7%), and 3) FT tear > 3 cm (16.3%). The mean difference of AHI noted was significantly lower in the supine radiographs than with the upright (1.34-1.37 mm.). The mean difference of the AHI was significantly lower in the MRI than the upright (1.62-1.87 mm.). AHI obtained from the supine radiographs and MRI had no significant differences. The area under the curve (AUC) of the upright and supine AHI in the diagnosis of the FT tears were at 0.649 and 0.642 accuracy. Upright AHI 7.09 mm. had 27.9% sensitivity and 100% specificity in diagnosing FT tears with 64% accuracy ($p<0.001$). The upright AHI cut off value of 9.52 mm. had 60.5% sensitivity, 67.4% specificity, and 64% accuracy ($p=0.01$). The supine AHI 6.56 mm. had 32.6% sensitivity, 100.0% specificity, and 66.3% accuracy ($p<0.01$). Supine AHI cut off value of 7.42 mm. had 41.9% sensitivity, 86.0% specificity, and 64.0% accuracy ($p=0.004$). The inter- and intra-rater reliability of AHI measurement in 3 views were of substantial to almost perfect agreement (0.668-0.824).

Conclusion: The AHI in supine radiographs were significantly lower than upright shoulder radiographs in all groups as divided by severity of the rotator cuff tear and was comparable with the MRI. For AHI ≤ 7 mm. in upright shoulder radiographs remains as a good diagnostic test of full thickness rotator cuff tears, while this value was not relevant for use as the cut point in the supine radiographs and MRI shoulders.

Level of evidence: Level III; Diagnostic study

Clinical Relevance: The AHI measurement in supine and upright radiographs are reliable and reproducible. The AHI ≤ 7 mm. in upright shoulder radiographs remains as a good diagnostic test of full thickness rotator cuff tears, while this value was not relevant for use as the cut point in the supine radiographs and MRI shoulders.

Introduction

Rotator cuff tears are one of the common shoulder problems seen in orthopaedic practice while plain radiographs are the standard, initial investigation for patients with rotator cuff tears. The acromion morphologies, os acromiale, and the congruence of glenohumeral articulation are radiographic features used to evaluate the possibility of underlying pathologies. The superior migration of the humeral head (SMHH) is a phenomenon in late-stage rotator cuff disease. The pathology of upward displacement of the humeral head is not clearly understood. Increased deltoid pull, lack of stabilization by the rotator cuff and absence of tendon structures as space holders have been considered. [1, 2] Acromiohumeral interval (AHI) is one of the measurement methods used to calculate the SMHH. The mean AHI in shoulders with an intact rotator cuff is approximately 10 mm. (7-14 mm.). [3, 4] While the AHI ≤ 7 mm. measured on an anteroposterior radiograph suggests subacromial space narrowing and is indicative of large rotator cuff tears and the likelihood of successful outcomes after the repair is reduced. [2–4] The AHI value may be increased by the gravity during upright arm position and has the possibility to get the false negative result in detecting rotator cuff tears. Measurement of the AHI from supine MRIs is lower than measurement in upright shoulder radiographs [5] but plain radiographs are still the most initial investigation for rotator cuff-related patients. The supine shoulder radiographs may have less chance of confounding the AHI measurement by gravity and may have less false negative to detect the rotator cuff tears.

The purpose of this study was to compare the AHI measurement in supine shoulder and upright radiographs as well as MRI of the same shoulder in patients who had either in non-full thickness, small full thickness, or large full thickness rotator cuff tears and to report the sensitivity, specificity, and accuracy of each imaging modality to detect rotator cuff tears.

Materials And Methods

The study population consists of 86 patients (34 men, 52 women; mean age, 61.06 years). All shoulder radiographs and MRIs were performed at Thammasat University Hospital, from the period of July 2020 to May 2021, were compared. The inclusion criteria were patient more than 18 years of age and patients with suspected rotator cuff related shoulder pain who underwent an MRI of the affected shoulder. The exclusion criteria were patients who had a fracture around the shoulder, a history of shoulder surgery, severe osteoarthritis, rotator cuff tear arthropathy, and/or a history of septic or inflammatory arthritis in the shoulder.

Compliance with ethical standards:

All procedures performed in studies involving human participants were in accordance with the ethical standards of the ethics committee of the Thammasat University Hospital in accordance with relevant guidelines and regulations. The study was approved by the ethics committee of the Thammasat University Hospital (Registration no. MTU-EC-OT-2-031/64). The informed consent was obtained from all subjects.

Imaging protocol:

Shoulder radiograph (Grashey view): Radiographs were performed with a Simens X-ray vacuum technology (Simens Healthcare, Jiangsu China) assessment included true anteroposterior radiographs with the arm in a neutral position. The patients' scapula parallel to the image receptor (rotating the body 35°- 45° forward). The beam was angled 20° craniocaudally. All radiographs were prospectively acquired with the patient in the upright and supine positions.

MRI shoulder: The MRI examinations of the shoulders were performed in a supine position with a MAGNETOM Skyra is 3T MRI, Siemens Healthcare Headquarters (Siemens Healthcare GmbH Henkestr, Erlangen Germany). The same units and the same protocols were used on all shoulder MRIs during the study period. The imaging planes were as follows; transverse, coronal oblique (perpendicular to the glenoid) and sagittal oblique (parallel to the glenoid). The Picture Archiving and Communication System (PACs), Synapse program (Fujifilm Medical Systems Inc., Hanover Park, Illinois) were used to make all measurements, on both radiographs and MRIs.

Measurement of Acromiohumeral Interval:

Two blinded orthopaedic surgeons, separately measured the AHI on shoulder radiographs (Grashey view) and on the sagittal oblique MRI. The process of reviewing the images required the Picture Archiving and Communication System (PACS) work station. The AHI was measured in millimeters. The interpretations by 2 reviewers consisted of the assessment of inter-observer and intra-observer reliability, the interval period of measurement was 2 weeks. The AHI of the shoulder radiographs was measured by using the distance between the dense cortical bone at the inferior aspect of the acromion and the subchondral lamina of the humeral head. [3] The shortest distance was measured. The same measurement was performed by reviewers on sagittal oblique T1-weighted MRI. The AHI was measured at the shortest distance between the lowest part of the acromion and the center of the subchondral cortex of the humeral head. [5]

Patient grouping:

Patients were classified in 3 groups as measured by a fellowship-trained, sports medicine surgeon, in accordance to the antero-posterior tear size of posterosuperior rotator cuff in sagittal MRI shoulder. Group 1, non-full thickness tear. Group 2, full thickness tear 3 cm. Group 3, full thickness tear > 3 cm.

Statistical analysis was performed using SPSS (Version 25, IBM, Armonk, New York, USA) Demographic data, Quantitative data (age, height, weight, BMI and size of rotator cuff tear) represented by mean ± standard deviation (SD). Qualitative data (sex, site and number of patients in each group) represented by percentage.

Comparison of the AHI in radiographs and MRI: *p-value* by ANOVA test and Paired t-test were used for assessing differences in the AHI between shoulder radiographs in the supine and upright positions, and MRIs of the shoulder. A p value < 0.05 was considered statistically significant.

The intraclass correlation (ICC) was determined based on Landis and Koch. [6] The value range of the ICC is between 0 and 1.0. The ICC is high when there is a high level of conformity. (ICC value = 1.0 Perfect agreement, 0.99 to 0.81 = Almost perfect agreement, 0.80 to 0.61 = Substantial agreement, 0.60 to 0.41 = Moderate agreement, 0.40 to 0.21 = Fair agreement, 0.20 to 0.01 = Slight agreement, and 0.0 to −0.1 = Poor agreement)

Results

Eighty-six consecutive radiographs and MRI imaging sets were recorded between July, 2020 and May, 2021 and were evaluated according to the inclusion and exclusion criteria. The mean age was 61.1 ± 11.4 years. Mean BMI was 24.54. There were 52 (60.5%) women. There was 58.1% of the patients were right site affected. The mean tear size was 1.28 cm with median of 0.7 cm (range 0-5.4 cm).

The 86 shoulders were divided to 3 groups. The predominant of study population was non-full thickness rotator cuff tear (NFT) (50%), while 33.7% was full thickness tear (FT) 3 cm, and 16.3% was full thickness tear > 3 cm. (Table 1)

According to patient grouping, the patients in the full thickness tear groups were older than those in the non-full thickness tear group (p=0.011). Gender and BMI showed no significant differences between groups. Right shoulders were affected in full-thickness tear patients more frequently than in those with non-full thickness tears. There were significant differences in tear and retraction sizes for each group. (*p<0.001)* (Table 2)

AHI measurement

Overall, there was a significant difference *(p < 0.001)* in the AHI measurements according to tear size groups in supine & upright position shoulder radiographs (Grashey view) and shoulder MRIs.

Comparison of AHI (Table 3)

There was a significant difference of the AHI obtained from the upright and supine shoulder radiographs in all groups. The mean difference was lower in the supine radiographs (1.34-1.37 mm.).

There was a significant difference of the AHI obtained from the upright shoulder radiographs and MRIs in both groups. The mean difference was lower in the MRI (1.62-1.87 mm.).

There was no significant difference of the AHI obtained from the supine radiographs and MRIs (0.25-0.53 mm.). Our findings indicate that AHI measurement from supine shoulder radiographs was equivalent in predictive value to the MRI measurement and lower than that from upright shoulder radiographs.

When studying sensitivity and specificity of the AHI measurement in rotator cuff tears using ROC analysis, the result showed an area under the curve (AUC) of 0.649 in the AHI measurement from upright radiographs and an AUC of 0.642 from supine radiographs (Figure 1).

Analysis of the cut off value of the AHI in diagnosis of a full thickness rotator cuff tear from upright and supine radiographs are showed in table IV. With the AHI value 7.09 mm. in upright radiographs, the sensitivity and specificity to diagnose full thickness superoposterior rotator cuff tears were 27.9% and 100.0% respectively with 64% accuracy ($p<0.001$). The AHI cut off value of 9.52 mm. in upright radiographs had 60.5% sensitivity, 67.4% specificity, and 64% accuracy ($p=0.01$).

In the supine radiographs, the AHI 6.56 mm. had 32.6% sensitivity, 100.0% specificity, and 66.3% accuracy ($p<0.01$). Using an AHI cut off value of 7.42 mm., the sensitivity and specificity in diagnosing full thickness superoposterior rotator cuff tears were 41.9% and 86.0% respectively with 64.0% accuracy ($p=0.004$). (Appendix 1)

Regarding interrater reliability and validity of the measurements, the ICC of the individual measures between the two examiners, the inter- and intra-rater reliability [6] of the AHI measurement in 3 views have shown “substantial to almost perfect agreement” (0.668-0.824). (Table 4)

Discussion

The AHI is the shortest distance between the inferior cortex of the acromion and the top of the humeral head, the normal AHI is 7-14 mm. [3,4] Patients with an AHI ≤ 7 mm suggests a large rotator cuff tear. [2-4] Gruber et al. measured AHI on standard AP radiographs and found that the AHI measurement was reliable and reproducible. [7] This study also found that the AHI measurements, in either supine or upright radiographs and MRIs, were reliable and reproducible.

Oliveira et al. evaluated the AHI in shoulder MRIs and found that the AHI on MRIs is not influenced by gravity, degree of superior migration in relation to size, retraction and topography of the rotator cuff tear. [1] Merzayan et al. found significant differences in AHI measurements between radiographs and MRIs of the same shoulder with a massive rotator cuff tear. The AHI was lower on MRI when compared with radiograph. [5]

In this study, the AHI measurement from upright, supine radiographs, and MRI correlated with the rotator cuff tear size. The AHI had a lower value in larger tears than in the smaller tears. The AHI measurement of upright shoulder radiographs was higher compared with the supine films and the MRI with a significant difference *($p<0.001$).* There was no difference in the comparison of the AHI from supine shoulder radiographs and MRIs. This finding was in agreement with previous studies. [1,8] The AHI measurement in supine radiographs and MRIs were smaller than the AHI in upright shoulder radiographs, due to the effect of gravity to the arm. An AHI value ≤ 7 mm. in upright radiographs did not have the same cut point value as in the supine radiographs and MRIs in the diagnosis of FT rotator cuff tears. Regarding the AUC of our study, the AHI measurement from upright, supine radiographs, and MRI had poor overall accuracy. So, AHI measurement, with any other radiographic methods, would not be suitable in the single standard method for the use of detecting of a superoposterior rotator cuff tear.

In the upright AHI, the low sensitivity (27.9%) of the AHI ≤ 7 mm. in diagnosing an FT rotator cuff tear represents the limited value of the upright AHI to be used as a screening tool for detecting a FT rotator cuff tear. While the 100% specificity represents a valuable tool as a diagnostic test in FT rotator cuff tear. This statistic analysis was based on 64% accuracy. The AHI cut off value of 9.52 mm. had 60.5% sensitivity, 67.4% specificity, and 64% accuracy (p=0.01).

In the supine AHI, the measurement value was lower than in the upright radiographs. The AHI ≤ 6.56 mm. had 100% specificity while 32.6% sensitivity, and 66.3% accuracy (p<0.01) for ruling in a FT rotator cuff tear. Using an AHI cut off value of ≤ 7.42 mm., the sensitivity and specificity for diagnosing a FT, superoposterior rotator cuff tear were 41.9% and 86.0% respectively with 64.0% accuracy (p=0.004).

The strength of this study is that this is the first study to analyze the effected of gravity in plain shoulder radiographs with the AHI measurement correlated to the presentation of a FT, superoposterior rotator cuff tear, the measurement methods are also be validated with the reliability test. This study had some limitations, the number of patients in tear size group is different, the no-full thickness tear group was younger than the full thickness tear group, and there were small numbers of patients with large to massive tear sizes (FT > 3 cm) and this might affect the interpretation of outcomes.

Conclusion

The AHI in supine was significantly lower than upright shoulder radiographs in all groups divided by severity of rotator cuff tear. This was comparable with the MRI. An AHI ≤ 7 mm. in upright shoulder radiograph is still remains a good diagnostic test for a full thickness rotator cuff tear while this value was not relevant for use as a cut point for the supine radiographs and shoulder MRIs.

Declarations

Acknowledgment

We wish to thank the Department of Orthopaedics, Faculty of Medicine, Thammasat University and Thammasat University Hospital for the kindly support.

Conflict of Interest

No conflict of interest related to publication

References

1. de Oliveira França, F. *et al.* Evaluation of the acromiohumeral distance by means of magnetic resonance imaging umerus. *Revista brasileira de ortopedia*, **51** (2), 169–174 https://doi.org/10.1016/j.rboe.2016.01.008 (2016).

2. Saupe, N. *et al.* Association between rotator cuff abnormalities and reduced acromiohumeral distance. *AJR. American journal of roentgenology*, **187** (2), 376–382 https://doi.org/10.2214/AJR.05.0435 (2006).
3. Hufeland, M. *et al.* The acromiohumeral distance in the MRI should not be used as a decision criterion to assess subacromial space width in shoulders with an intact rotator cuff. Knee surgery, sports traumatology, arthroscopy:. *official journal of the ESSKA*, **29** (7), 2085–2089 https://doi.org/10.1007/s00167-020-06090-6 (2021).
4. Ongbumrungphan, W., Srikhum, W. & Chernchujit, B. The Effect of Radiographic Beam Angle on Acromiohumeral Interval: 3D-CT Analytic Study. *Journal of the Medical Association of Thailand = Chotmaihet thangphaet*, **98** (Suppl 3), S61–S65 (2015).
5. Mirzayan, R. *et al.* Is there a difference in the acromiohumeral distances measured on radiographic and magnetic resonance images of the same shoulder with a massive rotator cuff tear? *Journal of shoulder and elbow surgery*, **29** (6), 1145–1151 https://doi.org/10.1016/j.jse.2019.10.020 (2020).
6. Landis, J. R. & Koch, G. G. The measurement of observer agreement for categorical data., **33** (1), 159–174 (1977).
7. Gruber, G. *et al.* Measurement of the acromiohumeral interval on standardized anteroposterior radiographs: a prospective study of observer variability. *Journal of shoulder and elbow surgery*, **19** (1), 10–13 https://doi.org/10.1016/j.jse.2009.04.010 (2010).
8. Bernhardt, G. A., Glehr, M., Zacherl, M., Wurnig, C. & Gruber, G. Observer variability in the assessment of the acromiohumeral interval using anteroposterior shoulder radiographs. *European journal of orthopaedic surgery & traumatology: orthopedie traumatologie*, **23** (2), 185–190 https://doi.org/10.1007/s00590-012-0942-y (2013).

Tables

Table 1: Summary of the demographic data of patients.

Variables	Statistics
Age	61.1 ± 11.4
Height (cm.)	161.8 ± 7.1
Weight (kg.)	64.4 ± 10.7
BMI	24.54 ± 3.48
Sex	
Male	34 (39.5%)
Female	52 (60.5%)
Side	
Right	50 (58.1%)
Left	36 (41.9%)
Tear size (cm.)	1.28 ± 1.46
Median (range)	0.7 (0 - 5.4)
Group	
Non-full thickness tear	43 (50%)
Full thickness tear 3 cm.	29 (33.7%)
Full thickness tear > 3 cm.	14 (16.3%)

Table 2: Summarizes the demographic data according to tear size group. (NFT = non-full thickness tear, FT = full thickness tear)

	NFT	FT 3 cm.	FT > 3 cm.	p-value
N	43	29	14	
Tear size (cm.)	0	1.31 ± 0.47	4.21 ± 0.82	<0.001
Retraction size (cm.)	N/A	1.72 ± 0.94	3.64 ± 0.68	<0.001
Age	57.6 ± 12.2	65.6 ± 10.1	62.3 ± 7.8	0.011
BMI	24.88 ± 3.07	24.23 ± 3.28	24.13 ± 5	0.666
Sex				
Male	13 (30.2%)	16 (55.2%)	5 (35.7%)	0.100
Female	30 (69.8%)	13 (44.8%)	9 (64.3%)	
Side				
Right	16 (37.2%)	22 (75.9%)	12 (85.7%)	<0.001
Left	27 (62.8%)	7 (24.1%)	2 (14.3%)	

p-value obtained by ANOVA test and Chi-square test.

Table 3: Summarizes the AHI measurement according to tear size group. (NFT = non-full thickness tear, FT = full thickness tear)

	NFT	FT 3 cm.	FT > 3 cm.	p-value
N	43	29	14	
AHI (Upright) (mm.)	10.09 ± 1.67	9.38 ± 1.87	8.1 ± 3.02	0.006
AHI (Supine) (mm.)	8.73 ± 1.45	8.03 ± 1.48	6.75 ± 2.69	0.001
AHI (MRI) (mm.)	8.48 ± 1.43	7.7 ± 1.41	6.23 ± 2.37	<0.001
Upright vs Supine				
Mean Difference (95%CI) (mm.)	1.37 (1.09, 1.64)	1.35 (1.08, 1.61)	1.34 (0.87, 1.82)	
p-value	<0.001	<0.001	<0.001	
Upright vs MRI				
Mean Difference (95%CI) (mm.)	1.62 (1.2, 2.03)	1.68 (1.14, 2.23)	1.87 (0.86, 2.88)	
p-value	<0.001	<0.001	0.002	
Supine vs MRI				
Mean Difference (95%CI) (mm.)	0.25 (-0.05, 0.55)	0.34 (-0.06, 0.73)	0.53 (-0.27, 1.33)	
p-value	0.099	0.091	0.177	

p-value by ANOVA test and Paired t test.

Table 4: Summarizes the inter/ intra observer reliability, AHI = acromiohumeral interval, CI = confidence interval

	ICC	95%CI
Inter Reliability		
AHI(Upright)	0.824	0.739 - 0.878
AHI (Supine)	0.774	0.689 - 0.834
AHI (MRI)	0.747	0.642 - 0.82
Intra Reliability		
AHI(Upright)	0.753	0.666 - 0.817
AHI (Supine)	0.668	0.551 - 0.754
AHI (MRI)	0.697	0.591 - 0.776

Figures

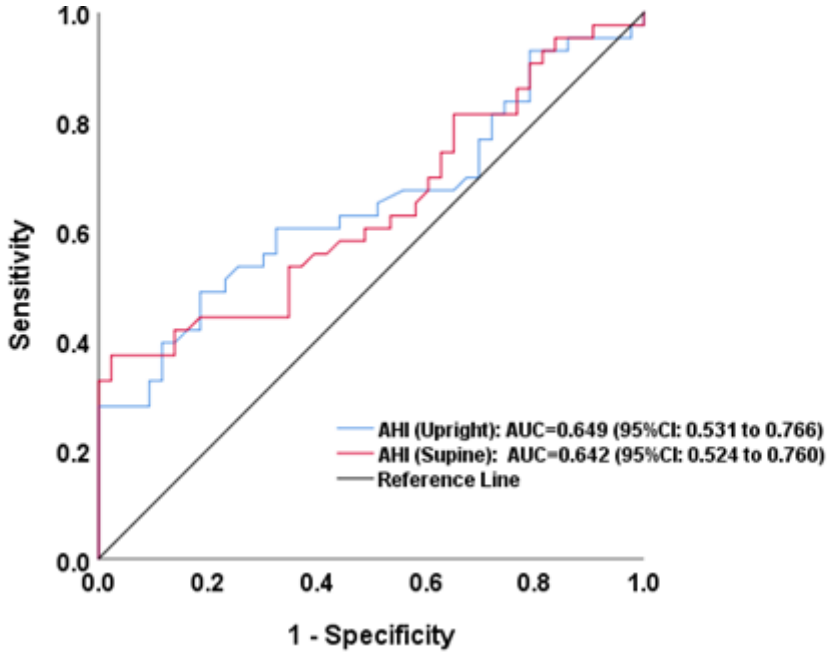

Figure 1

ROC curve of the AHI measurement from upright and supine radiographs.

Supplementary Files

This is a list of supplementary files associated with this preprint. Click to download.

- Appendix1CutoffoftheAHI.docx