Osteoperiosteal Decortication And Bone Grafting Combined With Wave Plating For Treating Femoral Shaft Aseptic Atrophic Nonunion After Intramedullary Nailing

Yao Lu
Xi'an Hong Hui Hospital
Cheng Ren
Xi'an Hong Hui Hospital
Yibo Xu
Xi'an Hong Hui Hospital
Liang Sun
Xi'an Hong Hui Hospital
Qian Wang
Xi'an Hong Hui Hospital
Haobo Ye
Xi'an Medical University
Ming Li
Xi'an Hong Hui Hospital
Hanzhong Xue
Xi'an Hong Hui Hospital
Qiang Huang
Xi'an Hong Hui Hospital
Zhong Li
Xi'an Hong Hui Hospital
Teng Ma (gukemt@163.com)
Honghui Hospital, Xi'an Jiaotong University https://orcid.org/0000-0003-3864-6600
Kun Zhang
Xi'an Hong Hospital

Research Article

Keywords: femoral shaft nonunion, decortication, augmentative plate, intramedullary nailing

Posted Date: March 7th, 2022

DOI: https://doi.org/10.21203/rs.3.rs-1103167/v1

Abstract

Introduction: Nonunion of the femoral shaft after intramedullary nailing fixation remains a challenge for orthopedic surgeons. This study aimed to evaluate osteoperiosteal decortication and iliac bone graft combined with wave plating for treating femoral shaft aseptic atrophic nonunion after intramedullary nailing.

Methods: This retrospective study included 22 patients (2 women, 20 men with a mean age of 40.8 years [range, 19–61 years]) with femoral shaft aseptic atrophic nonunion that were treated with osteoperiosteal decortication and iliac bone graft combined with wave plating between January 2016 and January 2020. Cases of infected nonunion, hypertrophic nonunion, and nonunion after plate osteosynthesis were excluded. The clinical outcomes were assessed by the Samantha radiographic grading scale and the Paley scale.

Results: The mean follow-up period was 18.8 months (range, 12–35 months). Bone union was achieved in 22 patients. Union was achieved eventually in two cases. The average clinical healing time for nonunion was 5.7 months (range, 3–14 months). The mean Samantha X-ray score was 5.7 ± 0.45. All patients showed excellent and good clinical results (Paley). One patient developed a superficial infection that was cured after a dressing change.

Conclusions: Osteoperiosteal decortication and bone graft combined with wave plating is an excellent method for treating femoral shaft aseptic atrophic nonunion after intramedullary nailing.

Background

Femoral shaft fractures are a common high-energy trauma, accounting for 6% of all fractures[1]. Intramedullary nailing (IMN) is the gold standard treatment for femoral shaft fractures. In recent years, with the continuous development of the IMN technique and its expanding clinical indications, the incidence of bone nonunion after IMN of femoral shaft fractures is reportedly 10%[2]. This has become a key issue affecting patient prognosis. However, controversy persists regarding the management of nonunion after IMN of femoral shaft fractures, including surgical or non-surgical treatment. For both aseptic hypertrophic and atrophic nonunion cases after femoral shaft fractures, exchange nailing has been considered the gold standard, with a reported success rate of 70–100%[3, 4]. With the continuous research on nonunion, increasing clinical reports have described the failure rate of the above treatment methods, especially in cases of aseptic atrophic nonunion[5, 6]. In addition, there are different styles of IMN, which make it impossible to remove them, and some patients cannot afford to replace them for financial reasons.

In recent years, plate augmentation with IMN retention has become an effective option for femoral shaft nonunion. Plate augmentation can improve the biomechanical environment of the nonunion site without causing more biological damage at union rates of 88.5–99.8%[7, 8]. Judet[9] first reported that osteoperiosteal decortication effectively managed femoral shaft nonunion. Youngho[10] also reported that osteoperiosteal decortication effectively treats oligotrophic and atrophic femoral shaft nonunion. However, these conclusions were based on some cases after plate fixation.

Here we report the results of patients with aseptic atrophic nonunion after IMN of femoral shaft fractures were treated with Judet's osteoperiosteal decortication technique and autogenous iliac bone grafting combined with wave plate augmentation with IMN retention.

Patients And Methods

In this retrospective study, 22 patients who underwent revision surgery at our center for aseptic atrophic nonunion after IMN of femoral shaft fractures between January 2016 to January 2020 were included in this retrospective study. The inclusion criteria were as follows: ①diagnosis of aseptic atrophic nonunion after IMN for managing femoral shaft fractures; ②having undergone revision surgery; and ③postoperative follow-up ≥12 months. The exclusion criteria were as follows:①subclinical septic nonunion;②pathological fracture;③refusal to complete follow-up; and ④lack of complete clinical data before and/or after surgery. This study was reviewed and approved by the Ethics Committee of Honghui Hospital, Xi'an Jiaotong University. All participating patients provided signed informed consent.

To standardize the data, we adopted several accepted nonunion criteria. First, nonunion was defined as: ① a fracture that is at least 9 months old that has not shown any signs of healing on radiographic examination; and ② a lack of progressive healing for three consecutive months[11]. Second, atrophic nonunion was defined as a demonstrable callus on radiographic examination when a fracture line persists beyond the expected time for union[12]. Third, the criteria for septic nonunion is consistent with previous studies[6]. The diagnosis of infective nonunion was based on intraoperative tissue biopsy of specimens obtained from the nonunion site of the femoral stem. During the procedure, three tissue biopsies were taken from each nonunion site; if all results were negative for bacterial growth, the patient was included in the study[6].

The previous IMN was left in place. A new incision was made over the nonunion site. The skin, subcutaneous, and broad fascia of the nonunion site were incised layer by layer. Care was taken to protect the periosteum and surrounding soft tissues to avoid excessive disruption of blood flow to the nonunion site. The cortical surface of the nonunion site was decorticated using the Judet's osteoperiosteal decortication technique. Autologous bone was harvested from the iliac crest. Next the autologous iliac bone with cortex was bitten into a slender strip using an occlusal forceps, whiel the cortical strip of iliac bone was placed on the cancellous bone surface to protect the cancellous bone. An avoidance technique was used to fix the plate so that the fixation screw avoided the IMN. Staggered fixation to the contralateral side was performed; finally, the stripped bone cortex and periosteum were sutured to the muscle. The soft tissue was adequately isolated from the nonunion site. The bone graft and internal fixation were assessed by radiography.

Patient general results, including age, sex, side of injury, follow-up time, clinical healing time, and complications, were analyzed. All cases were contacted at a minimum of 12 months later for clinical and radiographic follow-up until bone union is achieved. The Samantha radiographic grading scale was used to

evaluate union quality[13]. The Paley scale was used to assess clinical outcomes, including joint function and bone results[14]. The preoperative and final follow-up data were recorded and used to analyze the statistical differences.

Statistical analysis

The statistical data were processed using GraphPad Prism 9.0. The Shapiro-Wilk test was used to determine whether the data were normally distributed. The data are expressed as mean ± standard deviation. Values of $P < 0.05$ were considered statistically significant.

Results

Twenty-two patients (two women, 20 men; mean age, 40.8 years [range, 19–61 years]) with femoral shaft aseptic atrophic nonunion were included in this retrospective study. The injury mechanism of the fractures was a simple fall in 4 patients, a traffic accident in 11, a fall from a height in 6, and a hit by an object in 1. The patients' baseline data are provided in Table 2.

Table 1
Radiographic grading scale for the degree of healing

Description	Grade
* No changes from the immediate postoperative appearance	0
* A slight increase in radiodensity distinguishable from the graft	1
* Recognizable increase in radiodensity, bridging of one cortex with new-bone	2
formation to the graft	
* Bridging of at least one cortex with the material of nonuniform radiodensity,	3
early incorporation of the graft suggested by the obscurity of graft borders	
* Defect bridged on both medial and lateral sides with the bone with uniform radiodensity,	4
cut ends of the cortex still visible, and graft and new bone not easy to differentiate	
* Same as grade 3, with at least one of four cortices obscured by new bone	5
* Defect bridged by new uniform bone, cut ends of cortex no longer distinguishable,	6
and graft no longer visible	

Table 2
Summary of the patient variables and outcomes of femoral shaft nonunion

Patient	Age	Sex	Side	Mechanism	Number of	Graft	Time to union	follow-up	Samantha	Paley result		Complications
No.	(years)	(M/F)	(L/R)	of injury	previous surgeries	material	(month)	(month)	X-ray score	bone	function	
1	37	M	R	Simple fall	1	Iliac bone	6	12	6	Excellent	Excellent	None
2	53	M	R	Simple fall	2	Iliac bone	12	12	5	Excellent	Excellent	Delayed union
3	47	F	R	Traffic accident	2	Iliac bone	14	18	5	Excellent	Good	Delayed union
4	28	M	L	Traffic accident	1	Iliac bone	5	13	5	Excellent	Excellent	None
5	19	M	R	Fall from a height	1	Iliac bone	3	18	6	Excellent	Excellent	None
6	52	M	L	Traffic accident	1	Iliac bone	6	21	6	Excellent	Excellent	None
7	29	M	L	Traffic accident	2	Iliac bone	3	32	6	Excellent	Excellent	None
8	51	M	L	Traffic accident	3	Iliac bone	6	16	5	Excellent	Excellent	None
9	61	M	L	Fall from a height	1	Iliac bone	4	24	6	Excellent	Excellent	None
10	48	M	L	Hit by an object	1	Iliac bone	5	18	6	Excellent	Excellent	None
11	33	M	R	Fall from a height	1	Iliac bone	4	35	6	Excellent	Good	None
12	42	F	L	Traffic accident	1	Iliac bone	4	12	6	Excellent	Excellent	None
13	45	M	L	Traffic accident	1	Iliac bone	7	12	6	Excellent	Excellent	None
14	51	M	R	Fall from a height	1	Iliac bone	6	24	6	Excellent	Excellent	None
15	53	M	L	Simple fall	3	Iliac bone	4	30	6	Excellent	Excellent	Sterile wound leakage
16	38	M	R	Traffic accident	1	Iliac bone	6	20	6	Excellent	Excellent	None
17	43	M	L	Traffic accident	1	Iliac bone	4	18	6	Excellent	Excellent	None
18	32	M	R	Simple fall	1	Iliac bone	6	12	5	Excellent	Excellent	None
19	27	M	R	Traffic accident	1	Iliac bone	3	16	6	Excellent	Excellent	None
20	23	M	R	Fall from a height	1	Iliac bone	6	15	6	Excellent	Excellent	None
21	30	M	L	Fall from a height	1	Iliac bone	4	24	5	Excellent	Good	None
22	55	M	L	Traffic accident	1	Iliac bone	4	12	6	Excellent	Excellent	None

The mean follow-up time was 18.8 months (range, 12–35 months). All patients

had clinical and radiographic evidence of union although two showed slightly delayed union (united at 14 and 10 months), and the average union time for nonunion was 5.7 months (range, 3–14 months). The mean score on Samantha X-ray was 5.7 ± 0.45. The functional results were excellent in 19 cases and good in three. The bone evaluation outcomes were excellent in all 22 patients, none of whom suffered a nerve or vascular injury. One patient showed sterile wound leakage that was resolved after a dressing change. (Table 2).

Discussion

IMN is the gold standard method for managing adult femoral shaft fractures. In recent years, with the continuous development of IMN techniques and the expanding clinical indications, the incidence of nonunion after IMN of femoral shaft fractures is reportedly 10%[2]. When encountered, it represents serious economical, functional, and psychological burdens on patients.

Exchange nailing with reamed larger-diameter nails is suitable for treating cases of aseptic atrophic nonunion after IMN for femoral shaft fractures[15]. However, there are conflicting reports of its success. Swanson[16] investigated 50 patients with aseptic femoral nonunion who underwent exchange nailing at a mean 25 months and found a 100% healing rate. Oh[17] used exchange nailing to treat cases of aseptic femoral nonunion, and the success rate was 93%. However, a meta-analysis of five randomized controlled trials (256 patients) indicated a union rate of 78.9%[18]. Plate fixation is also a preferred treatment method. The success rate of augmentative plating with bone grafting in the treatment of nonunion is reportedly 100%[19]. Schulz[20] used wave plating to treat cases of aseptic femoral nonunion and reported a success rate of 85.3% and a mean time to union of 7.3 months (range, 3–19 months).

Christiano[8] reported that augmentation plating for the treatment of femoral aseptic shaft nonunion leaving the IMN in situ featured excellent and good clinical outcomes in all patients. The healing rate of the nonunion site was 86%. The mean time to union was 11.7 months (range, 2–16 months). A recent meta-analysis demonstrated that the femoral shaft nonunion rate was 98.7% (225/228) in the augmentative plating group and 78.9% (202/256) in the exchange nailing group, while the mean union time was 9.0 months in the augmentative plating group and 10.9 months in the exchange nailing group[18].

Judet[9] first reported that osteoperiosteal decortication was an effective and simple technique for managing femoral shaft nonunion, but this claim was based on cases treated after plate fixation. There were no clinical studies of osteoperiosteal decortication that developed nonunion following IMN of femoral shaft fractures. In recent years, with the application of biomechanics in orthopedics, augmentative plating has featured a significantly higher union rate for femoral shaft atrophic nonunion cases[6]. Ramoutar[21] reported that 96 cases of nonunion were treated with Judet's decortication and an additional plate with or without bone grafting with union rates of 94.6% without a bone graft and 95% with a bone graft. Autogenous bone grafting is still recommended to enhance healing in most cases of atrophic nonunion[22].

In our study, we performed Judet's decortication and wave plate augmentation of the IMN combined with bone grafting in all cases and obtained a 100% union rate. The mean time to union (5.7 months) is lower than that reported by another study[15, 18, 23]. The results were evaluated using the Paley bone and functional scores. The functional results were excellent in 19 cases and good in three. The bone evaluation outcomes were excellent in 22 patients. There were two cases of delayed union, but union was achieved eventually in both. One patient showed sterile wound leakage that was cured after a dressing change.

Plate augmentation with retention of the IMN in situ for nonunion of femoral shaft fracture has many advantages, such as providing additional rotational stability, the nail left in situ preventing bending load on the plate, minimal incisions, no need for an extensive approach, less blood loss, and early rehabilitation[24]. For the additional plates, there are various types of plates and fixation methods, such as large fragment plates (4.5 mm) or small fragment plates (3.5 mm), a dynamic compression plate or locked compression plate, non-locking or locking screws, and bicortical or unicortical screws.

According to a biomechanical study, Ma[25] compared different screw types and several auxiliary plates for the treatment of nonunion of femoral shaft fracture after IMN. The authors found that the use of three screws on each side allowed additional rotational stability than the use of two screws on each side. There was no significant difference between single cortical locking screw fixation and bicortical screw fixation with identical screw numbers. They recommended three single cortical locking or bicortical screws on each side. However, they had a greater tendency to adopt bicortical screw fixation in patients with a history of osteoporosis, especially elderly patients. Gautier[26] found that single-cortical locking screw fixation must have sufficient cortical thickness to provide mechanical stability, especially in patients with osteoporosis. Due to the limited residual space after IMN fixation to the femoral shaft, it is difficult to achieve double cortical fixation using 4.5-mm system screws. In addition, the locking plate and screw system cannot adjust the screw angle due to its own intrinsic characteristics. As such, we recommend dual cortical fixation using a 3.5-mm plate system and cortical screws.

There are some limitations to the current study. First, it was a retrospective single-center study with a small sample size. Therefore, a large-scale prospective randomized case-control study is required to evaluate the effectiveness of Judet's decortication, autogenous bone grafting, wave plate augmentation, and IMN retention. Second, this study confirmed the safety and feasibility of femoral shaft nonunion treated with Judet's decortication and autogenous bone grafting combined with wave plate augmentation. However, a study with a longer follow-up period is required to ensure a comprehensive evaluation.

Conclusion

In conclusion, here we obtained bony union in all 22 patients with no cases of implant failure or significant complications. Our study suggests that osteoperiosteal decortication and autogenous iliac bone graft combined with wave plate augmentation effectively treats femoral shaft nonunion after IMN.

Abbreviations

IMN: Intramedullary nailing.

Declarations

Acknowledgements

Not applicable.

Authors' contributions

TM, YL and KZ participated in the design of this study. CR, YX and LS performed the statistical analysis. QW, HY, ML, HX, QH and ZL carried out the study and collected important background information. YL drafted the manuscript. All authors read and approved the final manuscript.

Funding

None.

Availability of data and materials

All data analyzed in this study has been provided in the manuscript.

Ethics approval and consent to participate

This study was approved by the ethics committee of Honghui Hospital, Xi'an Jiaotong University. All patients provided informed consent prior to participation in the study.

Consent for publication

Yes.

Competing interests

The authors declare that they have no competing interests.

References

1. Denisiuk M, Afsari A. Femoral Shaft Fractures. Treasure Island (FL): StatPearls Publishing, 2021.
2. Pihlajamäki HK, Salminen ST, Böstman OM. The treatment of nonunions following intramedullary nailing of femoral shaft fractures. J Orthop Trauma, 2002, 16: 394–402.
3. Yu CW, Wu CC, Chen WJ. Aseptic nonunion of a femoral shaft treated using exchange nailing. *Chang Gung Med J*, 2002, 25: 591–8.
4. Ru J, Xu H, Kang W, et al. Augmentative compression plating versus exchanging reamed nailing for nonunion of femoral shaft fracture after intramedullary nailing: A retrospective cohort study. Acta Orthop Belg, 2016, 82: 249–57.
5. Yang KH, Kim JR, Park J. Nonisthmal femoral shaft nonunion as a risk factor for exchange nailing failure. J Trauma Acute Care Surg, 2012, 72: E60-4.
6. Lai PJ, Hsu YH, Chou YC, et al. Augmentative antirotational plating provided a significantly higher union rate than exchanging reamed nailing in treatment for femoral shaft aseptic atrophic nonunion - retrospective cohort study. BMC Musculoskelet Disord, 2019, 20: 127.
7. Medlock G, Stevenson IM, Johnstone AJ. Uniting the un-united: should established non-unions of femoral shaft fractures initially treated with IM nails be treated by plate augmentation instead of exchange IM nailing? A systematic review. Strategies Trauma Limb Reconstr, 2018, 13: 119–28.
8. Uliana CS, Bidolegui F, Kojima K, et al. Augmentation plating leaving the nail in situ is an excellent option for treating femoral shaft nonunion after IM nailing: a multicentre study. Eur J Trauma Emerg Surg, 2020. DOI:10.1007/s00068-020-01333-0.
9. Judet PR, Patel A. Muscle pedicle bone grafting of long bones by osteoperiosteal decortication. Clin Orthop Relat Res, 1972, 87: 74–80.
10. Cho Y, Byun YS, Suh JD, et al. Osteoperiosteal Decortication and Autogenous Cancellous Bone Graft Combined with Bridge Plating for Non-hypertrophic Diaphyseal Nonunion. Clin Orthop Surg, 2021, 13: 301–6.
11. Haverstock BD, Mandracchia VJ. Cigarette smoking and bone healing: implications in foot and ankle surgery. J Foot Ankle Surg, 1998, 37: 69–74; discussion 78.
12. Frölke JP, Patka P. Definition and classification of fracture non-unions. Injury, 2007, 38 (Suppl 2): S19-22.
13. Salkeld SL, Patron LP, Barrack RL, et al. The effect of osteogenic protein-1 on the healing of segmental bone defects treated with autograft or allograft bone. J Bone Joint Surg 2001;83:803–16.
14. Paley D, Catagni MA, Argnani F, et al. Ilizarov treatment of tibial nonunions with bone loss. Clin Orthop Relat Res 1989;241:146–65.
15. Brinker MR,O'Connor DP. Exchange nailing of ununited fractures. J Bone Joint Surg Am, 2007, 89: 177–88..
16. Swanson EA, Garrard EC, Bernstein DT, et al. Results of a systematic approach to exchange nailing for the treatment of aseptic femoral nonunions. J Orthop Trauma, 2015, 29(1):21–7.
17. Oh JK, Bae JH, Oh CW, et al. Treatment of femoral and tibial diaphyseal nonunions using reamed intramedullary nailing without bone graft. Injury, 2008, 39: 952–9..
18. Jin YF, Xu HC,Shen ZH, et al. Comparing Augmentative Plating and Exchange Nailing for the Treatment of Nonunion of Femoral Shaft Fracture after Intramedullary Nailing: A Meta-analysis. Orthop Surg, 2020, 12: 50–7.
19. Birjandinejad A, Ebrahimzadeh MH, Ahmadzadeh CH. Augmentation plate fixation for the treatment of femoral and tibial nonunion after intramedullary nailing. Orthopedics, 2009, 32: 409.
20. Schulz AP, Faschingbauer M, Seide K, et al. Is the Wave Plate Still a Salvage Procedure for Femoral Non-union? Results of 75 Cases Treated with a Locked Wave Plate. Eur J Trauma Emerg Surg, 2009, 35: 127–31.
21. Ramoutar DN, Rodrigues J, Quah C, et al. Judet decortication and compression plate fixation of long bone non-union: is bone graft necessary? Injury. 2011;42(12):1430–4.

22. Kanakaris NK, Paliobeis C, Nlanidakis N, et al. Biological enhancement of tibial diaphyseal aseptic non-unions: the efficacy of autologous bone grafting, BMPs and reaming by-products. Injury, 2007, 38 (Suppl 2): S65-75.
23. Mittal KK, Gupta H, Kaushik N. Reunion of post nail aseptic non-union of diaphyseal femoral fractures by augmentation plating, decortication and bone grafting - Replacement for exchange nailing. Injury, 2021, 52: 1529–33.
24. Vaishya R, Agarwal AK, Gupta N, et al. Plate augmentation with retention of intramedullary nail is effective for resistant femoral shaft non-union. J Orthop, 2016, 13: 242–5.
25. Ma XZ, Zhang B, Wang MY, et al. Augmentative plating for treatment of nonunion of femoral shaft fracture after intramedullary nailing: a biomechanical study[J]. Chinese Journal of Orthopaedic Trauma, 2016,18(2):158–62.
26. Gautier E, Sommer C. Guidelines for the clinical application of the LCP. Injury,2003,34(Suppl.2):B63-76.

Figures

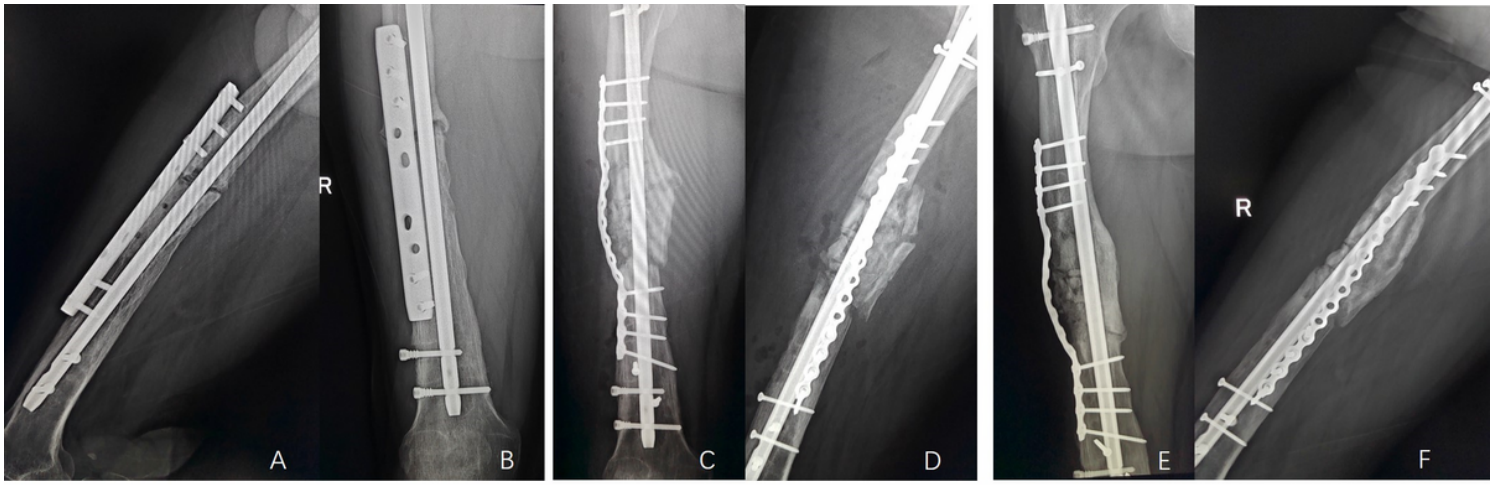

Figure 1

A 53-year-old male patient in whom a fracture of the right femoral shaft caused by a fall was internally fixed with a femoral intramedullary nail (open reduction) at a local hospital. At 1 year postoperative, the fracture did not heal and was treated with augmentation plating, leaving the nail in situ. Four years after the second operation, the fracture still did not heal (A, B). After osteoperiosteal decortication and iliac bone graft combined with wave plating, anteroposterior (C) and lateral (D) radiographs showed adequate bone grafting. The anteroposterior (E) and lateral (F) radiographs at 1 year postoperative showed full fracture healing.