Histopathological assessment of healing process using an amniotic membrane in osteotomy defects caused by piezosurgery and conventional surgery in rats

Semsettin Ilker
Private Dental Clinic

Alper Ilker
Atlas University

Efe Sivrikaya (efecans@msn.com)
Karadeniz Technical University

Research Article

Keywords: Amniotic membrane, bone healing, conventional rotary instruments, guided bone regeneration, piezosurgery

Posted Date: December 4th, 2020

DOI: https://doi.org/10.21203/rs.3.rs-110320/v1

Abstract

There is a paucity of studies aimed to compare the healing process of piezosurgery with conventional surgery. This study evaluated the histopathological assessment of healing process in osteotomy defects caused by these surgical methods in rats using an amniotic membrane (hAM). In this randomized controlled experimental study, there were 2 main groups: group 1 (Piezosurgery method-right tibia) and group 2 (Conventional surgery method-left tibia) and subgroups determined by the sacrification periods on the 7th (n = 20) and 21st days (n = 20). hAM was used in all groups. The primary outcome variable was new bone formation, while inflammation, necrosis, fibrotic tissue formation in the defective zone were secondary outcomes. 40 male Sprague Dawley rats were used. The 7th day fibrosis levels and the 7th new bone-building level of the group who underwent piezosurgery were found to be significantly higher than those of the group undergoing conventional surgery ($p < 0.05$) and the 21st new bone-building level was significantly lower than conventional surgery. In all rats, on the 21st day, there were statistically significant decreases in inflammation, fibrosis, and increases in the healing score ($p < 0.05$). Also, there was no statistically difference in new bone formation between 7st and 21st days ($p > 0.05$). The choice of conventional surgery when applying with hAM increases the new bone building in the late period.

Introduction

Traditionally, rotating instruments like conventional burs were the only option for hard tissue surgery until 1988.[1] Considering the tendency toward minimally invasive surgery, piezosurgery—a new osteotomy technique—has been introduced in oral and maxillofacial surgery.[2] Piezosurgery devices use micro-vibrations of scalpels at ultrasonic frequencies to perform osteotomies.[3] The use of it has become widespread in oral and maxillofacial surgery, with its selective cutting feature and not damaging tissues. Also, studies are indicating that it has positive effects on soft tissue compared with conventional surgery.

In a meta-analysis, Liu et al.,[4] described that there might be some advantages in terms of pain, mouth opening, swelling on third mandibular molar extraction with piezosurgery compared to conventional surgery. Similar results were reported in mandibular cyst enucleation.[3] Also, these two techniques were compared in crest preparation before implant application[5], inferior alveolar nerve and transposition[6], osteotomy and maxillary sinus augmentation procedure[7], and alveolar distraction [8] in the literature. It is described that the use of ultrasonic devices as piezosurgery for osteotomies has several advantages, including less surgical injury, cutting selectively, postoperative pain, and neurological complications [9,10] in these studies. However, the effects of these two techniques on bone healing using an amniotic membrane (hAM) are histopathologically controversial.

hAM is an intrauterine tissue that is widely used as a cell culture substrate in various surgical therapies because it facilitates the proliferation, differentiation, and functional organization of various cell types. It is a source of various factors and enzymes such as epidermal growth factor (EGF), keratinocyte growth

factor (CGF), hepatocyte growth factor (HGF), changing growth factor (TGF), steroid hormones (estrogen, progesterone), hydrolytic enzymes, and oxidation-reduction enzymes.[11,12] It is used as a physical barrier between the flap and the bone defect to promote the increase of regenerative cells in the area of the defect.[11]

Today, the use of hAM has become common in repairing bone defects.[13,14] Although piezosurgery has been reported to have positive effects healing process histopathologically and clinically, its use with the hAM is uncertain. The purpose of the present study was to compare the healing process in osteotomy defects caused by piezosurgery and conventional surgery using hAM in rats. The investigators hypothesized that piezosurgery would increase bone healing compared with conventional surgery in defects used hAM.The specific aims of the study were to measure 1) inflammatory levels, 2) fibrosis level, 3) healing scale, 4) new bone-building level, and 5) necrosis.

Results

All the rats survived during and after the surgery. No fractures or infections were observed in any of the rats post-operatively.

Light microscope images

7th day: Left tibia: More fibrous and bone tissues were observed compared with the right tibia (Figure 4 A-B). Also, more compact bone tissue was seen in the right tibia (Figure 4 B).

21st day: Left tibia: More compact bone tissue was seen (Figure 4C). Right: Thin, irregular cortical bone formation was present in the defect region (Figure 4D).

Comparison of groups

There was statistically significant difference between the piezosurgery and conventional surgery techniques on the 7th days in terms of fibrosis level (p=0.028) and new bone-building level (p=0.038), on 21^{s}t day in terms of new bone-building level (p=0.001) (Table 1). While fibrosis and new bone formation were higher in the piezosurgery group on the 7th day, new bone formation on the 21st day was higher in the conventional surgery group (Figure 5).

Table 1: Statistical evaluations regarding surgical method in groups.

	Day	Piezo Surgery Mean±SD (Median)	Conventional Surgery Mean±SD (Median)	[1]p
Inflammation	**7**	1,1±0,32 (1)	1,3±0,48 (1)	**0,276**
	21	0±0 (0)	0,2±0,42 (0)	**0,146**
Fibrosis	**7**	1,7±0,48 (2)	1,2±0,42 (1)	**0,028***
	21	0±0 (0)	0,3±0,48 (0)	**0,067**
New bone building	**7**	0,15±0,15 (0,1)	0,03±0,05 (0)	**0,038***
	21	0,16±0,07 (0,2)	0,37±0,1 (0,4)	**0,001****
Healing score	**7**	2,1±0,88 (2)	1,4±0,84 (1)	**0,064**
	21	5±0,82 (5)	5,2±0,42 (5)	**0,546**
Necrosis $_{n,\%}$	**7**	2 (%20)	6 (%60)	**[2]0,170**
	21	0 (%0)	1 (%10)	**[2]1,000**

[1] Mann Whitney U Test
[2] Fisher's Exact Test

** p<0.05* *** p<0.01*

Comparison of sacrification periods in piezosurgery group (Right tibias)

The inflammation and fibrosis levels on the 21st day were significantly lower than those on the 7th day. (p = 0.001, p = 0.001). Healing scores on the 21st day were found to be significantly higher than those on the 7th day in (p = 0.001). There was no statistically significant difference in the new bone building (p = 0.648) and necrosis (p = 0.474) (Table 2) (Figure 6).

Comparison of sacrification periods in conventional burs group (Left tibias)

The inflammation and fibrosis levels on the 21st day were significantly lower than on the 7th (p = 0.001, p=0.008). The new bone building and healing score were significantly higher on the 21st (p = 0.001). Healing scores on the 21st day were found to be significantly higher than on the 7th day (p = 0.001). There was no significant difference in necrosis (p = 0.677) (Table 2) (Figure 6).

Table 2: Statistical evaluations regarding surgical method in sacrification periods.

	Day	Piezosurgery Mean±SD (Median)	Conventional Surgery Mean±SD (Median)
Inflammation	**7**	1,1±0,32 (1)	1,3±0,48 (1)
	21	0±0 (0)	0,2±0,42 (0)
	[1]p	**0,001****	**0,001****
Fibrosis	**7**	1,7±0,48 (2)	1,2±0,42 (1)
	21	0±0 (0)	0,3±0,48 (0)
	[1]p	**0,001****	**0,001****
New bone building	**7**	0,15±0,15 (0,1)	0,03±0,05 (0)
	21	0,16±0,07 (0,2)	0,37±0,1 (0,4)
	[1]p	**0,648**	**0,001****
Healing score	**7**	2,1±0,88 (2)	1,4±0,84 (1)
	21	5±0,82 (5)	5,2±0,42 (5)
	[1]p	**0,001****	**0,001****
Necrosis $_{n,\%}$	**7**	2 (%20)	6 (%60)
	21	0 (%0)	1 (%10)
	[2]p	**0,474**	**0,057**

[1] Mann Whitney U Test *[2] Fisher's Exact Test* ** p<0.05* *** p<0.01*

Discussion

In oral and maxillofacial surgery, piezosurgery offers some important advantages such as the lower risk of damage to nerve and soft tissues, increased cutting ability [15], better hemostasis, and the reduction of postoperative pain and swelling.[1,16-18] Furthermore, hAM grafts can be used for barrier functions in the repair of bone defects.[19] Recently, hAM grafts and piezosurgery techniques were routinely applied in clinical practice.[1,19,20] However, the effects of piezosurgery and conventional rotary instruments on bone healing using hAM are histopathologically controversial. The purpose of the present study was to evaluate the hypothesis that piezosurgery would increase bone healing compared with conventional surgery in defects used hAM. In the present study, inflammatory levels, fibrosis level, healing scale, new

bone-building level, and necrosis in osteotomy defects caused by piezosurgery and conventional rotary instruments were evaluated histopathologically.

The results of the present study revealed that new bone building was higher in the piezosurgery group on the 7th day ($p = 0.038$) and on the 21st day new bone formation was higher in the conventional surgery group ($p = 0.001$). However, Preti et al.,[21] in the study where they investigated the biomolecular and histologic analysis of implants' osteointegration and they reported that on the 7th and 14th days, the new bone level and amount of osteoblast in the bone surgery site was higher than in the conventional drill surgery technique. Another study found that as a result of their study on dogs, bone level in osteotomy/osteoplasty with piezzo increased after 8 weeks compared to the conventional rotary instruments.[22] Bone healing probably related to various factors including searching methods, the size of the bone defect, and timing in histopathological examination.[23,24] Furthermore, Gomes et al.,[13] in their study on animals found that healing was delayed as shown by histological follow-up, in the group that used only the hAM. The reason for higher bone building levels in the conventional surgery on 21st day likely that the hAM maintains its tissue integrity by performing its barrier function in the present study.

It was stated that piezosurgery had better results in the early period of bone healing because as an ultrasound technique, it results in successful induction of osteoblast differentiation and proliferation.[25,26] This result may due to the increase in BMP4 and TGF-β2 in the first period in piezosurgery. It was reported that BMPs and TGF are important factors for chondrocyte differentiation and osteogenic differentiation in the healing process.[21] Similarly, in the present study, there were statistically significant increases in the new bone-formation level on the 7th day for the piezosurgery than the conventional technique. The early effect of hAM application in piezosurgery is not yet available in the literature, and studies on this subject are recommended.

Extreme tissue damage and necrotic cells at the operation area occurring due to traumatic surgeries result in an intense inflammatory response and provide a high level of edema due to the release of pro-inflammatory mediators such as bradykinin and prostaglandin E2.[22,27] However, in the present study, there was no significant difference between groups on inflammation, healing score, necrosis, and fibrosis. The reason for this may be the use of an amnion membrane.

It is stated that the hAM can be used as an alternative to the oral mucosa membrane because it causes rapid healing [28], less patient morbidity [29], and minimum complications [30]. Also, it can stimulate healing and improve the epithelialization of the oral mucosa because it contains growth factors such as TGF-α, TGF-β1, -2, -3, EGF, IGF, and VEGF.[11,30,31] Velez et al.,[32] conducted the first study in the field of dental implants using hAM and reported that amnion group was better compared to the group where no material was applied after surgery in terms of epithelialization and pain scoring on the 6-day during the early period. The reason it was used in the present study was to speed up and increase the healing process.

To our knowledge, this is the first study to address the relationship between piezosurgery and conventional rotary instruments histopathologically evaluating new bone formation, inflammation,

necrosis, fibrotic tissue formation, recovery score, and foreign body reaction using an hAM. One limitation of this study was that the sample size was relatively small compared to human studies. Therefore, necrosis is not detected in some subgroups. Also, this is an animal study, and the results of animal studies cannot easily be extrapolated to a human situation.

This study showed that the selection of conventional surgical procedure in defects used hAM affects new bone formation positively in the late period. Ultrasonic or conventional devices should be chosen based on their safety and efficiency. We would recommend the use of conventional surgery for defects using hAM. Future studies with larger samples are required to identify additional histopathologic features of both surgery methods used hAM.

Methods

Animal model

Fourty (n = 40) male Sprague Dawley rats (13 weeks old, weighing 240 ± 20 g) were used in the present study. The rats were kept in separate metal cages in an automated environment at a temperature of 21ºC ± 1ºC, a relative humidity of 40%–60%, and a lighting period of 12 hours light and 12 hours dark for the duration of the experiment. All the rats were fed a standard diet and allowed free mobilization during the experimental period. Rats were sacrificed on the 7th (n = 20) and 21st (n = 20) days. All the experimental procedures were approved and judged commendable by the Animal Research Ethics Committee of the University of Istanbul in compliance with the EU Directive 2010/63/EU for animal experiments.

Animal groups

2 main groups were created (n = 40) according to the surgical methods (Piezosurgery method and conventional burs method). Osteotomy defect was applied to the right tibia of the rats by piezosurgery and the left tibia by conventional method. Randomization was achieved by assigning the rats according to a sequential order of enrolment. Subgroups (n = 20) were also created according to the time of sacrifice (7th or 21st day).

Surgical Procedure

The rats were anesthetized by an intraperitoneal injection mixture of 5 mg/kg Xylazine hydrochloride and 6 mg/kg Ketamine HCL. The medial surfaces of the right and left hind legs of the rats fixed in the standard posture were shaved and prepped with betadine solution.

A 20–25 mm bilateral skin incision was made (the right and left tibia) extending to the periosteum and then, soft tissues around the tibial bones were dissected using a periosteal elevator. The periosteum surrounding the bone was also incised and exposed by gentle retraction and dissection. Also, 5-mm long and 3-mm wide defects containing cortical and cancerous bones were created (Figure 1) in all the groups using the SL4 tip piezzo instruments (23 W) in the right tibia (Figure 2A) and conventional instruments (2

mm round burs) (Figure 2B) in the left tibia, under irrigation with sterile physiological saline solution to minimize thermal damage. All the osteotomies were performed by the same surgeon, using all the aforementioned ultrasonic devices in the automatic scansion mode (from 24 kHz to 36 kHz). The Sterishield amnion patch (20mm x 20mm, Bonemank Allografts, Texas, USA) was used under the periosteum to cover the defect areas on the right and left iliac regions of all the rats (Figure 3A). For all the groups, the flaps were sutured with 3.0 silk (Permahand® Silk Suture, Ethicon, Johnson & Johnson, Livingston, Scotland) (Figure 3B).

Light microscopy monitoring and evaluation criteria

The operated rats were sacrificed successively at intervals of 1 and 3 weeks. After the rats were sacrificed using high doses of diethyl ether, the right and left iliac bones were removed in all the groups. The tibias, already fixed in formalin for one month, were immersed in formic acid-sodium nitrate solution for 15 days to attain complete decalcification. Then, each decalcified specimen was cut and shaped to fit into the defect sites and embedded separately in paraffin blocks. During the embedding, the positioning of the piece of tibia was standardized in an attempt to ensure that the same region was evaluated in all specimens. Serial sections of 5–7 µm thickness were taken from the paraffin blocks, placed on the slide, and deparaffinized in an oven at 70ºC. It was then stained with hematoxylin-eosin (H&E) and examined under different magnifications using a light microscope.

Cross sections obtained from the 7th and 21st days in all the groups were evaluated according to the following criteria: Inflammation, necrosis, fibrosis, and new bone formation described as covering in an area of 0%–5% (0), 5%–30% (1), 30%–60% (2), and 60% (3). Healing score was evaluated as Fibrous tissue (0), Incomplete cartilage structure (cartilage structure with fibrous tissue) (1), Completed cartilage structure (2), Incomplete bone structure in the ossification phase (3), Incomplete bone structure in the middle phase of ossification (5), Incomplete bone structure in the advanced phase of ossification or the completed bone structure (6). Foreign body reaction described as yes or no.

Statistical Analysis

IBM SPSS Statistics 22 software (IBM SPSS, Türkiye) was used for statistical analysis. Results were expressed as mean ± standard deviation. Test for normality of the different variables was done using the Shapiro Wilks test. Mann Whitney U test was used to compare parameters that’s were not normally distributed between the groups. Fisher's Exact Chi-Square test was used to compare qualitative data. Differences were considered significant when p value was <0.05.

Declarations

Data Availability Statement

All data generated or analysed during this study are included in this published article.

Author contributions

ISE performed the experiments and instructed him in performing the experiments. SEC the corresponding author designed the study and drafted the main manuscript text. ISE and IA contributed to interpretation of the data and revised the manuscript. All authors reviewed the manuscript

Additional Information

Corresponding author: Correspondence to Sivrikaya Efe Can

Competing Interests: The authors declare no competing interests.

References

1 Al-Moraissi, E. A., Elmansi, Y. A., Al-Sharaee, Y. A., Alrmali, A. E. & Alkhutari, A. S. Does the piezoelectric surgical technique produce fewer postoperative sequelae after lower third molar surgery than conventional rotary instruments? A systematic review and meta analysis. *Int J Oral Maxillofac Surg* **45**, 383-391, doi:10.1016/j.ijom.2015.10.005 (2016).

2 Anesi, A. *et al.* Structural and ultrastructural analyses of bone regeneration in rabbit cranial osteotomy: Piezosurgery versus traditional osteotomes. *Journal of cranio-maxillo-facial surgery : official publication of the European Association for Cranio-Maxillo-Facial Surgery* **46**, 107-118, doi:10.1016/j.jcms.2017.10.004 (2018).

3 Pappalardo, S. & Guarnieri, R. Randomized clinical study comparing piezosurgery and conventional rotatory surgery in mandibular cyst enucleation. *Journal of cranio-maxillo-facial surgery : official publication of the European Association for Cranio-Maxillo-Facial Surgery* **42**, e80-85, doi:10.1016/j.jcms.2013.06.013 (2014).

4 Liu, J., Hua, C., Pan, J., Han, B. & Tang, X. Piezosurgery vs conventional rotary instrument in the third molar surgery: A systematic review and meta-analysis of randomized controlled trials. *Journal of dental sciences* **13**, 342-349, doi:10.1016/j.jds.2016.09.006 (2018).

5 Li, X., Lin, X., Guo, J. & Wang, Y. The Stability and Survival Rate of Dental Implants After Preparation of the Site by Piezosurgery vs Conventional Drilling: A Systematic Review and Meta-Analysis. *The International journal of oral & maxillofacial implants* **30**, e51-e56, doi:10.11607/jomi.5913 (2020).

6 Metzger, M. C., Bormann, K. H., Schoen, R., Gellrich, N. C. & Schmelzeisen, R. Inferior alveolar nerve transposition–an in vitro comparison between piezosurgery and conventional bur use. *The Journal of oral implantology* **32**, 19-25, doi:10.1563/1548-1336(2006)32[19:IANTIV]2.0.CO;2 (2006).

7 Barone, A. *et al.* Osteotomy and membrane elevation during the maxillary sinus augmentation procedure. A comparative study: piezoelectric device vs. conventional rotative instruments. *Clinical oral implants research* **19**, 511-515, doi:10.1111/j.1600-0501.2007.01498.x (2008).

8 Gonzalez-Garcia, A., Diniz-Freitas, M., Somoza-Martin, M. & Garcia-Garcia, A. Piezoelectric and conventional osteotomy in alveolar distraction osteogenesis in a series of 17 patients. *The International journal of oral & maxillofacial implants* **23**, 891-896 (2008).

9 Arakji, H., Shokry, M. & Aboelsaad, N. Comparison of Piezosurgery and Conventional Rotary Instruments for Removal of Impacted Mandibular Third Molars: A Randomized Controlled Clinical and Radiographic Trial. *Int J Dent* **2016**, 8169356, doi:10.1155/2016/8169356 (2016).

10 de Freitas Silva, L. *et al.* Alveolar repair after the use of piezosurgery in the removal of lower third molars: a prospective clinical, randomised, double-blind, split-mouth study. *Br J Oral Maxillofac Surg* **57**, 1068-1073, doi:10.1016/j.bjoms.2019.09.017 (2019).

11 Kesting, M. R., Wolff, K. D., Nobis, C. P. & Rohleder, N. H. Amniotic membrane in oral and maxillofacial surgery. *Oral Maxillofac Surg* **18**, 153-164, doi:10.1007/s10006-012-0382-1 (2014).

12 Hao, Y., Ma, D. H., Hwang, D. G., Kim, W. S. & Zhang, F. Identification of antiangiogenic and antiinflammatory proteins in human amniotic membrane. *Cornea* **19**, 348-352, doi:10.1097/00003226-200005000-00018 (2000).

13 Gomes, M. F., dos Anjos, M. J., Nogueira, T. O. & Guimaraes, S. A. Histologic evaluation of the osteoinductive property of autogenous demineralized dentin matrix on surgical bone defects in rabbit skulls using human amniotic membrane for guided bone regeneration. *Int J Oral Maxillofac Implants* **16**, 563-571 (2001).

14 Semyari, H. *et al.* Evaluating the bone regeneration in calvarial defect using osteoblasts differentiated from adipose-derived mesenchymal stem cells on three different scaffolds: an animal study. *Cell and tissue banking* **17**, 69-83, doi:10.1007/s10561-015-9518-5 (2016).

15 Robiony, M., Polini, F., Costa, F., Zerman, N. & Politi, M. Ultrasonic bone cutting for surgically assisted rapid maxillary expansion (SARME) under local anaesthesia. *Int J Oral Maxillofac Surg* **36**, 267-269, doi:10.1016/j.ijom.2006.08.013 (2007).

16 Vercellotti, T. & Pollack, A. S. A new bone surgery device: sinus grafting and periodontal surgery. *Compend Contin Educ Dent* **27**, 319-325 (2006).

17 D'Agostino, A. *et al.* Does Piezosurgery Influence the Severity of Neurosensory Disturbance Following Bilateral Sagittal Split Osteotomy? *J Craniofac Surg* **30**, 1154-1162, doi:10.1097/SCS.0000000000005251 (2019).

18 Spinelli, G., Lazzeri, D., Conti, M., Agostini, T. & Mannelli, G. Comparison of piezosurgery and traditional saw in bimaxillary orthognathic surgery. *Journal of cranio-maxillo-facial surgery : official publication of the European Association for Cranio-Maxillo-Facial Surgery* **42**, 1211-1220, doi:10.1016/j.jcms.2014.02.011 (2014).

19 Li, W. *et al.* Investigating the Potential of Amnion-Based Scaffolds as a Barrier Membrane for Guided Bone Regeneration. *Langmuir : the ACS journal of surfaces and colloids* **31**, 8642-8653, doi:10.1021/acs.langmuir.5b02362 (2015).

20 Fenelon, M., Catros, S. & Fricain, J. C. What is the benefit of using amniotic membrane in oral surgery? A comprehensive review of clinical studies. *Clin Oral Investig* **22**, 1881-1891, doi:10.1007/s00784-018-2457-3 (2018).

21 Preti, G. *et al.* Cytokines and growth factors involved in the osseointegration of oral titanium implants positioned using piezoelectric bone surgery versus a drill technique: a pilot study in minipigs. *J Periodontol* **78**, 716-722, doi:10.1902/jop.2007.060285 (2007).

22 Vercellotti, T. *et al.* Osseous response following resective therapy with piezosurgery. *Int J Periodontics Restorative Dent* **25**, 543-549 (2005).

23 Spinato, S., Rebaudi, A., Bernardello, F., Bertoldi, C. & Zaffe, D. Piezosurgical treatment of crestal bone: quantitative comparison of post-extractive socket outcomes with those of traditional treatment. *Clinical oral implants research* **27**, 361-366, doi:10.1111/clr.12555 (2016).

24 Trombelli, L. *et al.* Modeling and remodeling of human extraction sockets. *J Clin Periodontol* **35**, 630-639, doi:10.1111/j.1600-051X.2008.01246.x (2008).

25 Malizos, K. N., Hantes, M. E., Protopappas, V. & Papachristos, A. Low-intensity pulsed ultrasound for bone healing: an overview. *Injury* **37 Suppl 1**, S56-62, doi:10.1016/j.injury.2006.02.037 (2006).

26 Li, J. K. *et al.* Comparison of ultrasound and electromagnetic field effects on osteoblast growth. *Ultrasound Med Biol* **32**, 769-775, doi:10.1016/j.ultrasmedbio.2006.01.017 (2006).

27 Smith, W. L. & Marnett, L. J. Prostaglandin endoperoxide synthase: structure and catalysis. *Biochim Biophys Acta* **1083**, 1-17, doi:10.1016/0005-2760(91)90119-3 (1991).

28 Rinastiti, M., Harijadi, Santoso, A. L. & Sosroseno, W. Histological evaluation of rabbit gingival wound healing transplanted with human amniotic membrane. *International journal of oral and maxillofacial surgery* **35**, 247-251, doi:10.1016/j.ijom.2005.09.012 (2006).

29 Martelloni, M., Montagner, G., Trojan, D. & Abate, R. Amniotic Membrane In Palatal Epithelial-Connective Tissue Reconstruction. *International medical case reports journal* **12**, 349-354, doi:10.2147/IMCRJ.S213275 (2019).

30 Kumar, S., Sugandhi, P., Arora, R. & Pandey, P. K. Amniotic membrane transplantation versus mucous membrane grafting in anophthalmic contracted socket. *Orbit* **25**, 195-203, doi:10.1080/01676830600575527 (2006).

31 Grzywocz, Z. *et al.* Growth factors and their receptors derived from human amniotic cells in vitro. *Folia Histochem Cytobiol* **52**, 163-170, doi:10.5603/FHC.2014.0019 (2014).

32 Velez, I., Parker, W. B., Siegel, M. A. & Hernandez, M. Cryopreserved amniotic membrane for modulation of periodontal soft tissue healing: a pilot study. *J Periodontol* **81**, 1797-1804, doi:10.1902/jop.2010.100060 (2010).

Figures

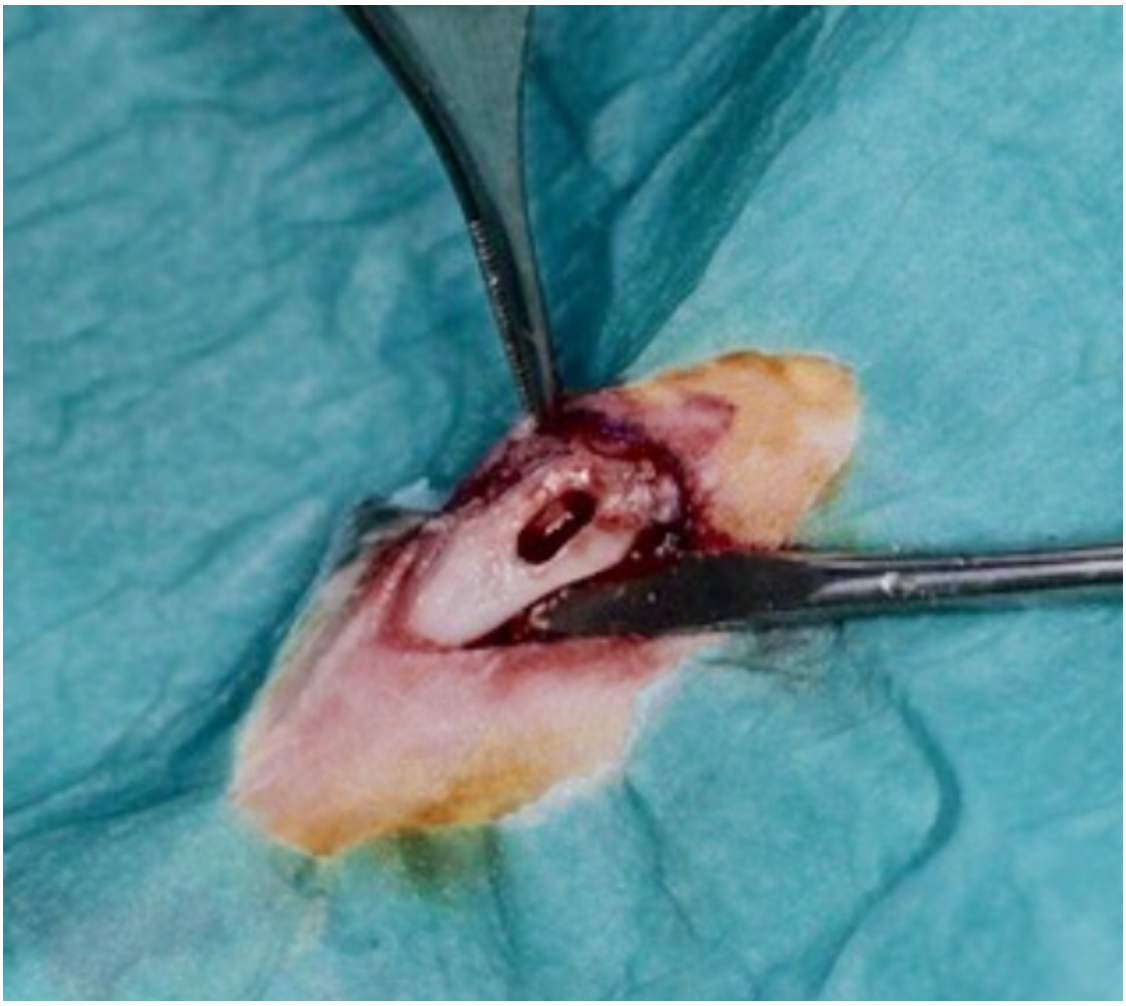

Figure 1

5-mm long and 3-mm wide defects containing cortical and cancerous bones were created in all the groups using piezo or hand-steel bur.

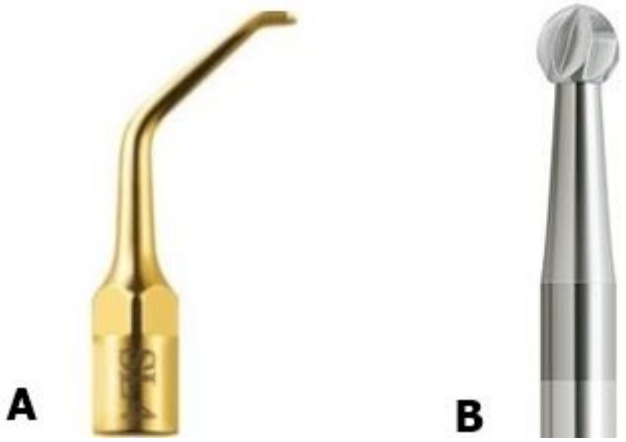

Figure 2

SL4 tip piezo instruments (23 W) (A) and 2 mm in diameter hand-steel (B) bur was used in the present study.

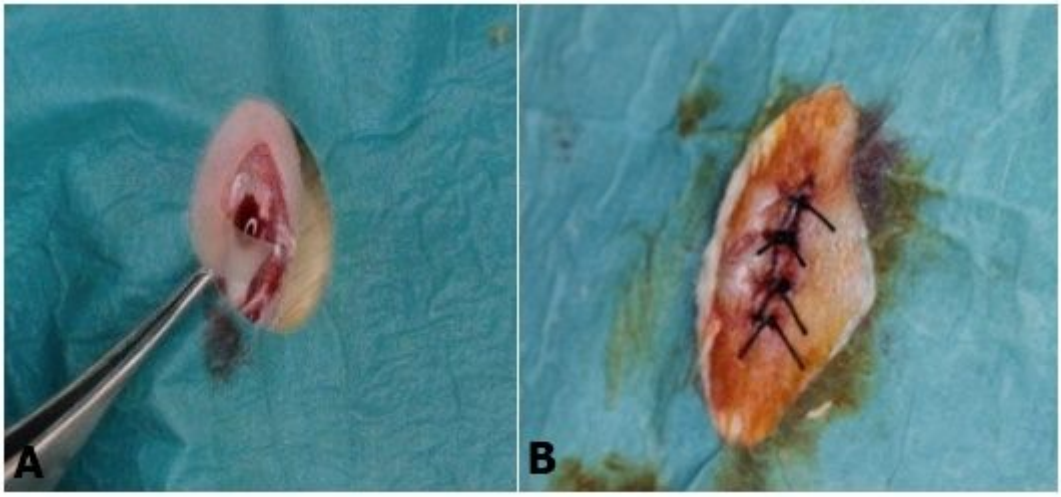

Figure 3

Amniotic membrane was applied to the defects in the tibia of rats (A), the flaps were sutured with 3.0 silk (B).

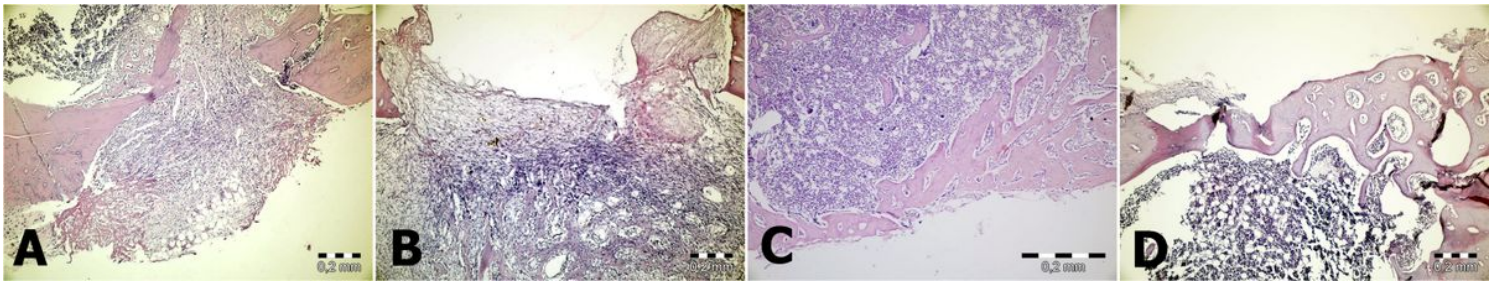

Figure 4

Histopathological findings of the groups on days 7 and 21 are shown. (H&E X 100) Conventional surgery (A) and Piezosurgery (B) on 7th day. Conventional surgery (C) and Piezosurgery (D) on 21st day. More compact bone was seen in B (7th day) and D (21th day)

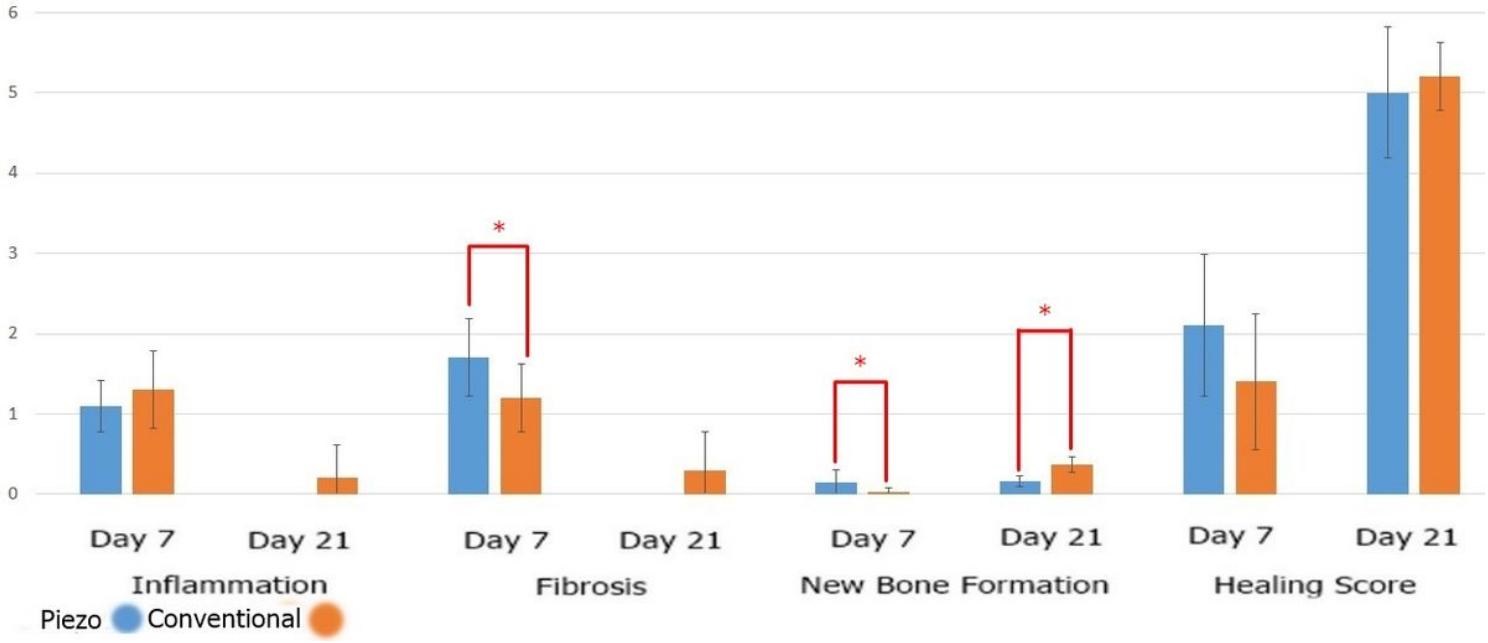

Figure 5

Graphic evaluations regarding the surgical method. *: indicates that the statistical difference was between piezosurgery and conventional surgery.

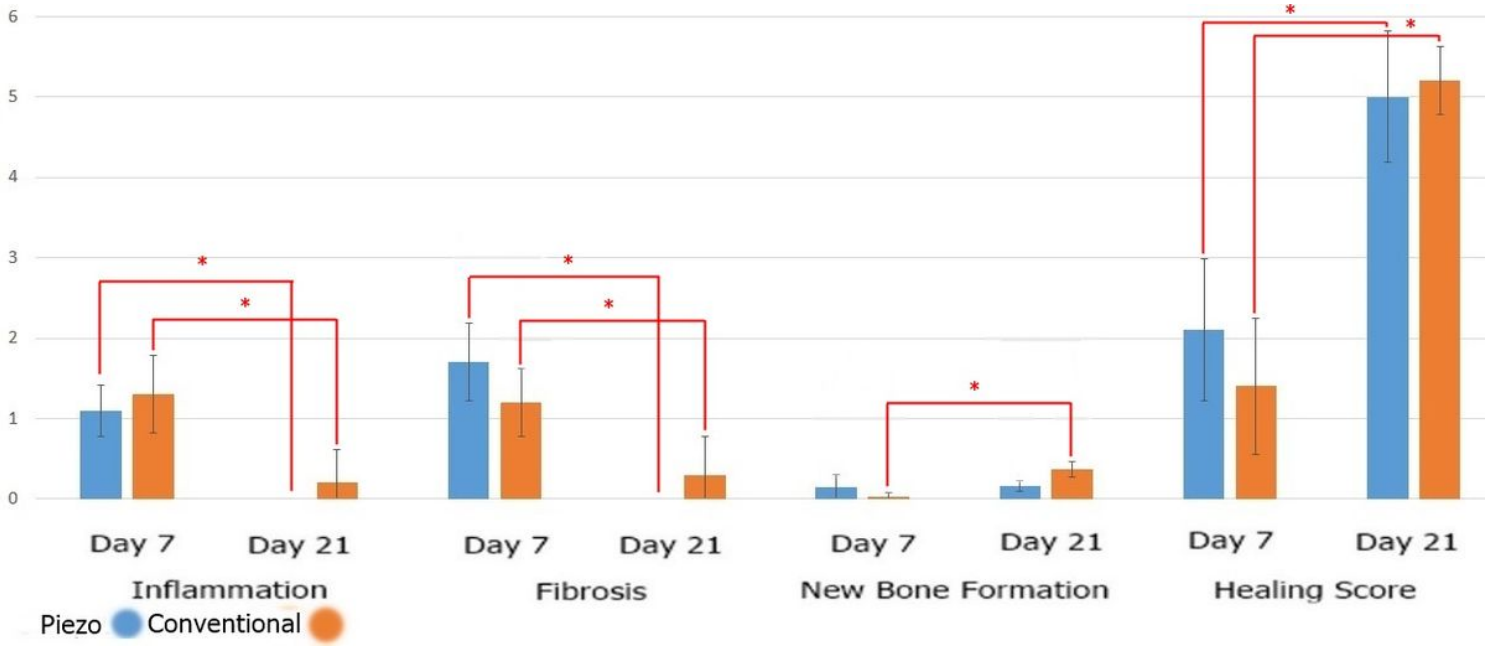

Figure 6

Graphic evaluations regarding the sacrification periods. *: indicates that the statistical difference was between 7th and 21st days.