Radiological study of the nasal septal body

canset aydın (cansetaydin@yahoo.com)
Medicana ankara hospital

övsen önay
Atilim University

melih gaffar gözükara
Amasya healthcare center

Hakan Ulubay
Medicana ankara hospital

Research Article

Keywords: turbinate, inferior, size, nasal, septal, middle

Posted Date: December 3rd, 2021

DOI: https://doi.org/10.21203/rs.3.rs-1104681/v1

Abstract

Objectives

The nasal septal body (NSB) is the thickened area of the septum located superior to the inferior turbinates and anterior to the middle turbinates. NSB contributes to nasal breathing via functionally and anatomically. The aim of the present study was to analyze NSB size and its association with such variables as age, septal deviation, and nasal turbinate size

Material and Methods

This retrospective study included 381 randomly selected patients that underwent paranasal sinus CT between 2014 and 2019. NSB size, septal deviation angle, and middle and inferior turbinate size were analyzed.

Results

NSB, inferior turbinate, middle turbinate, and inferior turbinate-P were significantly smaller on the deviated side. NSB, inferior turbinate, middle turbinate, and inferior turbinate-P size according to nasal septal angle was also significantly smaller on the deviated side. NSB and inferior turbinate size was positively correlated.

Conclusion

The NSB is an important structure for the regulation of air flow in the nose and should be evaluated in routine examination of the nose especially before the nasal surgery.

Introduction

The nasal septal body (NSB) is the thickened area of the septum located superior to the inferior turbinates and anterior to the middle turbinates [1]. The NSB is also referred to as the septal turbinate, septal cavernous body, septal intumescence, anterior septal tuberculum, septal erectile body, and Kiesselbach's ridge [1]. The NSB is an important structure for the regulation of air flow in the nose. The NSB is among the expansile tissues of the nose and plays a role in regulation of nasal resistance [2–4]. MRI and CT studies show that the anterior septal tissue has vasoactive expansile properties [1, 4]. This function is managed by its histological component, which differ from that of the rest of the septum [1, 2]. It contains a high proportion of venous sinusoids and glandular acini, with a prominence of glandular tissue [1, 2]. It was reported that the NSB has more venous sinusoids than glandular tissue [3]. Nonetheless, it has a thicker mucosal covering than the other sides of the septum and it is an important structure for nasal airway regulation.

The NSB is situated near the nasal valve and also anatomically contributes to regulation of nasal resistance [5], in addition to its histological function. The NSB can be observed via anterior rhinoscopy, endoscopic examination, and such radiological imaging techniques as CT and MRI. The aim of the present study was to analyze NSB size and its association with such variables as age, septal deviation, and nasal turbinate size in patients that underwent CT of the sinuses.

Material And Methods

This retrospective study was conducted at Medicana International Ankara Hospital, Radiology and Otorhinolaryngology Departments, Ankara Turkey. The study included 381 randomly selected patients that underwent paranasal sinus CT between 2014 and 2019. A256-slice multidetector GE revolution CT scanner was used and images were taken at 120kVp and 100 mA at 0.625 mm slice thickness. Exclusion criteria were sinonasal disease, maxillofacial trauma, a history of allergy, a history of surgery, use of topical nasal spray, oral antihistamines, oral steroids, or oral leukotriens, and age <18 years. Coronal sections of paranasal sinus CTs were used for measurements. NSB size, septal deviation angle, and middle and inferior turbinate size were analyzed. Septal deviation angle was measured according to a previously described method as mild (≤8°), moderate (9°-15°), and severe (≥16°) [6, 7]. NSB size, septal deviation angle, and inferior turbinate size were measured in sections in which the NSB was observed. In addition, middle turbinate and second inferior turbinate size was measured in sections which sizes were most prominent. The measurement of right side NSB was shown in Figure 1.The study protocol was approved by the Medicana International Ankara Hospital Ethics Committee and was conducted in accordance with the principles of the Declaration of Helsinki.

Statistical analysis

Statistical analysis was performed using IBM SPSS Statistics for Windows v.22.0 (IBM Corp., Armonk, NY). The distribution of variables was determined using visual (histogram and probability graphs) and analytical methods (Kolmogorov-Smirnov and Shapiro-Wilk tests). Data are presented as mean ± SD, median, and range. For comparison of continuous data for 2 dependent groups the paired sample t test was used for parametrically distributed values and the Wilcoxon signed rank test was used for non-parametrically distributed values. Correlations between variables were identified using Pearson’s (for parametric distribution) and Spearman’s correlation (for non-parametric distribution) tests. The level of statistical significance was set at $P < 0.05$ (95% CI), except for Pearson’s correlation test results, for which the level of statistical significance was set at $P < 0.01$.

Results

In total, 381 CT scans were evaluated. Size measurements of the NSB, middle turbinate, and inferior turbinates (first was measured on section which NSB measurement was also made; second was measured on the most prominent section and showed as Inferior turbinate-prominent) on both sides of the septum are shown in Table 1.

Table 1
NSB and Turbinate Sizes

NSB	Mean ± SD, mm	Range, mm
Deviated side	4.3 ± 1.2	1.3-11.1
Contralateral side	5.2 ± 1.2	2.3-9.9
Inferior turbinate		
Deviated side	6.7 ± 1.7	2.2-13.7
Contralateral side	7.3 ± 1.7	3.4-14.1
Inferior turbinate-prominent (P)		
Deviated side	10.7 ± 1.9	5.2-16.5
Contralateral side	11.0 ± 2.0	4.7-19.8
Middle turbinate		
Deviated side	7.2 ± 1.7	3.2-13.8
Contralateral side	7.7 ± 1.8	3.7-14.0

Septal deviations based on septal deviation angle were mild to moderate; there weren't any cases of severe septal deviation. Table 2 shows a comparison of measurements on both sides of the septum. NSB, inferior turbinate, middle turbinate, and inferior turbinate-P were significantly smaller on the deviated side (Table 2).

Table 2
Size (mm) comparison according to sides of the septum.

	Deviated side		**Contralateral side**		**P***
n = 381	Mean ± SD	Range	Mean ± SD	Range	
NSB	4.3 ± 1.2	1.3-11.1	5.2 ± 1.2	2.3-9.9	**<0.001**
Inferior turbinate	6.7 ± 1.7	2.2-13.7	7.3 ± 1.7	3.4-14.1	**<0.001**
Inferior turbinate-P	10.7 ± 1.9	5.2-16.5	11.0 ± 2.0	4.7-19.8	**0.003**
Middle turbinate	7.2 ± 1.7	3.2-13.8	7.7 ± 1.8	3.7-14.0	**<0.001**
*Paired sample t test.					

Table 3 shows that NSB, inferior turbinate, middle turbinate, and inferior turbinate-P size according to nasal septal angle was also significantly smaller on the deviated side.

Table 3
Size (mm) comparison according to nasal septal angle.

Septal Angle		Deviated side		Contralateral side		
		Mean ± SD	Median (range)	Mean ± SD	Median (range)	
≤8° (n = 362)	**NSB**	4.3 ± 1.2	4.3 (1.5-11.1)	5.1 ± 1.1	5.1 (2.3-9.9)	**<0.001***
	Inferior turbinate	6.7 ± 1.7	6.6 (2.2-13.7)	7.2 ± 1.7	7.2 (3.4-14.1)	**<0.001***
	Inferior turbinate-P	10.7 ± 1.9	10.9 (5.3-16.5)	11.0 ± 2.0	11.3 (4.7-19.8)	**0.019***
	Middle turbinate	7.2 ± 1.7	7.2 (3.2-13.8)	7.7 ± 1.8	7.7 (3.7-13.7)	**<0.001***
>9-15° (n = 19)	**NSB**	4.5 ± 1.8	4.7 (1.3-9.5)	6.4 ± 1.6	6.3 (2.7-9.6	**0.005****
	Inferior turbinate	6.9 ± 2.5	6.9 (2.2-12.4)	8.0 ± 1.8	8.3 (4.8-11.2)	**0.030****
	Inferior turbinate-P	10.1 ± 1.8	10. (5.2-13.0)	11.3 ± 1.9	11.3 (8.3-15.0)	**0.009****
	Middle turbinate	7.2 ± 2.2	6.8 (4.3-13.0)	8.2 ± 2.5	7.7 (4.4-14.0)	0.051**

*Paired sample t test. **Wilcoxon signed rank test.

NSB and turbinate size was positively correlated (significantly) on each side of the septum, except for middle turbinate size on the contralateral side of the septum (Table 4).

Table 4
Correlation between NSB and turbinate size.

	Deviated side		Contralateral side	
	Correlation Coefficient	P	Correlation Coefficient	P
Inferior turbinate	0.406	**<0.001***	0.293	**<0.001***
Inferior turbinate-P	0.172	**0.001***	0.206	**<0.001***
Middle turbinate	0.114	**0.026****	0.033	0.515

*P < 0.01 was considered statistically significant. **P < 0.05 was considered statistically significant.

Total NSB size (sum of the left and right sides) significantly decreased as patient age increased (Table 5).

Table 5
Correlation between total NSB size and patient age.

	Age (n = 381)	
	Correlation Coefficient	P
Total NSB Size	−0.110	0.032

Spearman's correlation test.

Discussion

The NSB is a part of the septum and has glandular and vascular structures [1, 2]. The NSB plays a role in humidification and regulation of nasal temperature via its glandular structures, and also plays a role in regulation of nasal airway resistance via its vasoexpansive structures and anatomical location. [1] The NSB is situated in a narrow space near the nasal valve [2, 3]. Even small changes in NSB size can have an anatomically important effect on nasal resistance.

Via its histological structures the NSB can change size and regulate nasal resistance like the turbinates do. The NSB is similar in structure and function to the turbinates, but the inferior turbinate has a greater number of sinusoids, is considered to be more vasoexpansive [4], and has less glandular tissue than the NSB [1]. In the present study, as expected, there was a positive correlation between NSB size and turbinate size, and the NSB and turbinates exhibited similar expansile patterns. In addition, the observed differences in NSB and turbinate size according to septal deviation side was also similar. Moreover, the NSB and turbinates were thinner on the deviated side, as reported earlier [6–8]. In the present study mean ± SD total NSB size was 9.5 ± 1.2 mm and there was a negative correlation between patient age and NSB size. Moreover, NSB size decreased with patient age, which is in agreement with Arslan [9] and can be explained by the well-known fact that general glandular tissue undergoes atrophy with age.

The present study was not a clinical study, but some clinical studies have shown positive outcomes on nasal obstruction following NSB surgical interventions [8]. Although there is a need for more clinical studies on NSB surgical interventions, the similar expansile nature of the NSB and turbinates indicates NSB and turbinate surgical interventions will yield similar outcomes. Based on the present findings we think that before nasal surgery is planned the NSB should be evaluated via physical examination and radiographic imaging, so as to prevent the misdiagnosis of high septal deviation and choose the optimal intervention.

Conclusions

The NSB has properties similar to those of the turbinates and plays an important role in nasal airway regulation. The NSB should be routinely evaluated in all patients with nasal obstruction.

Abbreviations

Nasal septal body (NSB)

Declarations

Ethics approval and consent to participate

The study protocol was approved by the Medicana International Ankara Hospital Ethics Committee and was conducted in accordance with the principles of the Declaration of Helsinki. Written informed consent was obtained from every patient.

Consent for publication

Not applicable.

Availability of data and material

The data used and/or analysed during the current study are available from hospital radiology department.

Competing interests

The authors declare that they have no competing interests.

Funding

The authors declare that they have no funding.

Authors' contributions

C.A wrote the main manuscript.Ö.Ö made the tables and figure. M.G made the statistical analysis. H.U made the radiologic measurements. All authors reviewed the manuscript finally

Acknowledgements

Thanks to all the peer reviewers and editors for their opinions and suggestions.

References

1. Wexler, D., I. Braverman, and M. Amar, *Histology of the nasal septal swell body (septal turbinate)*. Otolaryngol Head Neck Surg, 2006. **134**(4): p. 596–600.
2. Saunders, M.W., et al., *An anatomical, histological and magnetic resonance imaging study of the nasal septum*. Clin Otolaryngol Allied Sci, 1995. **20**(5): p. 434–8.

3. Costa, D.J., et al., *Radiographic and anatomic characterization of the nasal septal swell body*. Arch Otolaryngol Head Neck Surg, 2010. **136**(11): p. 1107–10.
4. Ng, B.A., R.G. Ramsey, and J.P. Corey, *The distribution of nasal erectile mucosa as visualized by magnetic resonance imaging*. Ear Nose Throat J, 1999. **78**(3): p. 159, 163–6.
5. Cole, P., *The four components of the nasal valve*. Am J Rhinol, 2003. **17**(2): p. 107–10.
6. Demirci, S., et al., *Correlation Between the Septal Body and the Nasal Turbinates in Patients With Deviated Nasal Septum*. J Craniofac Surg, 2016. **27**(1): p. 166–9.
7. Setlur, J. and P. Goyal, *Relationship between septal body size and septal deviation*. Am J Rhinol Allergy, 2011. **25**(6): p. 397–400.
8. Moss, W.J., et al., *A systematic review of the nasal septal turbinate: An overlooked surgical target*. Am J Otolaryngol, 2019. **40**(6): p. 102188.
9. Arslan, M., T. Muderris, and S. Muderris, *Radiological study of the intumescentia septi nasi anterior*. J Laryngol Otol, 2004. **118**(3): p. 199–201.

Figures

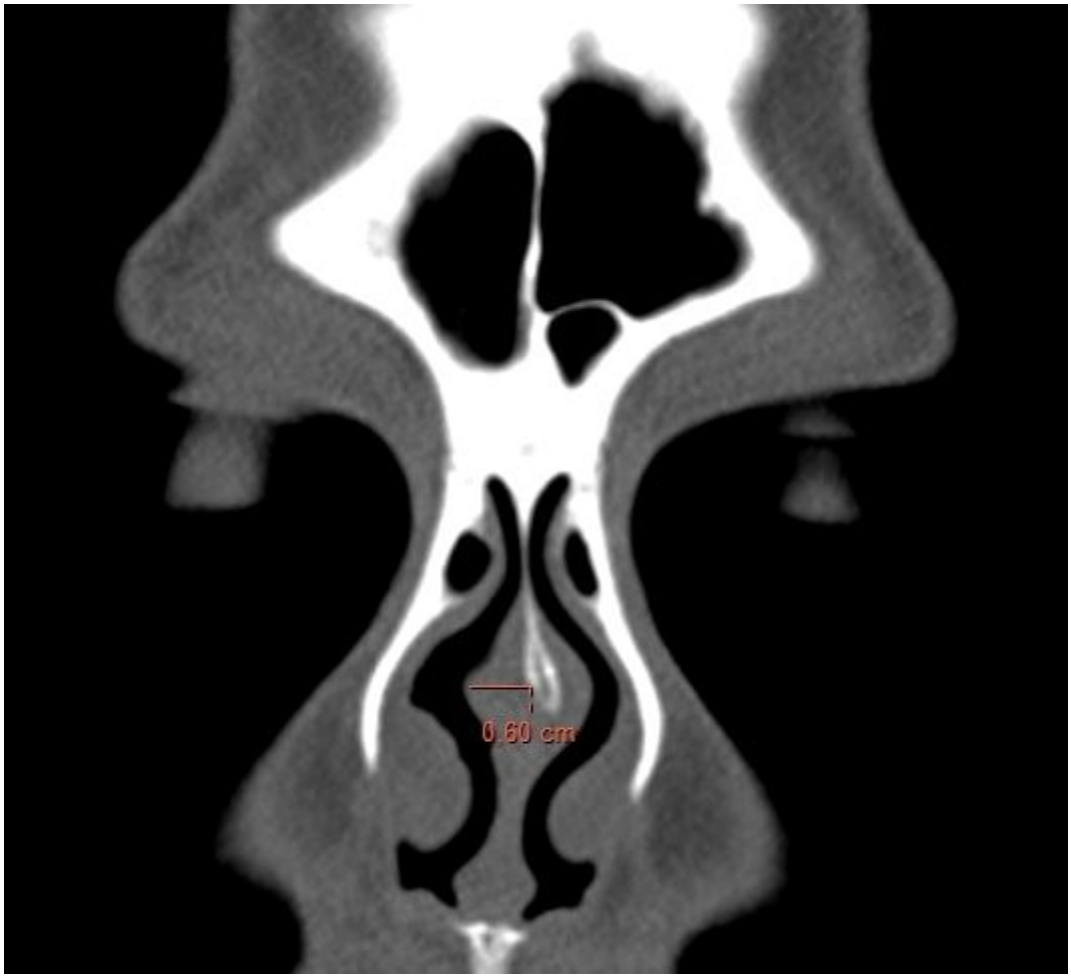

Figure 1

Coronal computed tomography image shows the right NSB