Efficacy and Safety of Cement Augmented Fenestrated Screws in the Surgery With Posterior Approach for Spinal Metastases

Qi Feng
The Fourth Hospital of Hebei Medical University
Donglai Wang
The Fourth Hospital of Hebei Medical University
Zibo Zang
The Fourth Hospital of Hebei Medical University
Jiangang Feng (saqn3j@163.com)
Department of Orthopedics, The Fourth Hospital of Hebei Medical University, No. 12 Health Road, Shijiazhuang 050011, Hebei Province, China

---

Research

Keywords: spinal metastasis, internal fixation, cement augmented pedicle screw group, pain score, progression-free survival time

Posted Date: November 20th, 2020

DOI: https://doi.org/10.21203/rs.3.rs-111295/v1

Abstract

Objective: To investigate the efficacy and safety of cement augmented fenestrated screws in the posterior approach for spinal metastases.

Methods: A total of 52 patients with spinal metastases who underwent surgery with posterior approach separation and internal fixation with pedicle screw in the Department of Orthopaedics of the Fourth Hospital of Hebei Medical University from January 2015 to January 2017 were analyzed retrospectively. There were 28 cases in the cement augmented pedicle screw group and 24 cases in the conventional pedicle screw group. The clinical data, preoperative and postoperative pain, and neurological function between the two groups were compared. After follow-up, every 3 months, the local progression-free survival time of patients in the two groups was recorded to explore the safety of cement augmented pedicle screws in posterior separation of spinal metastases, and to analyze the difference in efficacy between the two groups.

Results: There were no significant differences in sex, age, segments of the affected vertebra, Tomita score, Tokuhashi score, spinal instability neoplastic score (SINS), intraoperative blood loss and average postoperative hospital stays between the two groups. The average operation time was 161 ± 21 minutes in the cement augmented pedicle screw group and 135 ± 19 minutes in the conventional pedicle screw group, with a statistically significant difference. A total of 218 screws were implanted in the 28 patients of the cement augmented pedicle screw group, with an average of 1.3 ± 0.4 ml of cement injected into each screw. There was 1 case of cerebrospinal fluid leakage in each of the two groups, and no incision hematoma formation or infection occurred. There was no symptomatic pulmonary cement embolism in the cement augmented pedicle screw group. The preoperative VAS scores were not statistically different between the two groups. However, the VAS scores in the two groups decreased 3 months after surgery, which were 2.93 ± 1.33 and 4.17 ± 1.34, respectively, with statistical significance. The recovery of Frankel grading was found in 84.6% of all patients (44 cases in 52 patients), but there was no significant difference in Frankel grades between the two groups before and 3 months after surgery. During the follow-up period of 6-24 months, there were 10 cases of adjacent segmental metastasis (2 cases in cement augmented pedicle screw group and 8 cases in conventional pedicle screw group) and 8 cases of internal fixation failure (1 case cement augmented pedicle screw group and 7 cases in conventional pedicle screw group). The difference was statistically significant. Compared with the conventional pedicle screw group, the conventional pedicle screw group had a longer survival time of progression-free in the local and adjacent segments, and the difference was statistically significant.

Conclusion: The application of cement augmented pedicle screw in surgery of spinal metastases with the posterior approach is safe, and the pain score decreases more obviously 3 months after surgery. It can effectively reduce the adjacent segmental metastasis and failure rate of internal fixation and prolong the local progression-free survival time.

Introduction

In recent years, with the improvement of the level of diagnosis and treatment of malignant tumors, the survival time of patients with tumors is significantly prolonged, and the incidence of patients with bone metastasis is increasing year by year [1]. The spine is the most common site of metastasis. Bone destruction and spinal cord compression caused by spinal metastasis often lead to severe bone pain and neurological dysfunction. Effective spinal cord decompression surgery is needed to relieve the symptoms [2]. Bone destruction by spinal metastases leads to spinal instability, and combined pedicle screw fixation can maintain or reconstruct the spinal stability [3]. However, with the continuous development of medical treatment of malignant tumors, the survival time of patients with spinal metastases is gradually prolonged, and adjacent segmental metastases often occur after surgery. Studies showed that some patients with spinal metastases had adjacent segmental metastases with the development of the disease, resulting in Tomita type 7 spinal metastases [4], postoperative pain and neurological dysfunction for a second time. Meanwhile, bone destruction of vertebral segments with screw implantation may also lead to failure of internal fixation, requiring revision surgery, or even causing patients to give up treatment.

There are a variety of scoring systems for preoperative evaluation of surgical methods for spinal metastases, including the Tomita score [5] and the modified Tokuhashi score [6]. The survival time of patients can be comprehensively predicted according to the scoring system. Tomita classification [7] and WBB classification [8] are used to evaluate the invasive range of spinal metastases, and combined with spinal instability neoplastic score (SINS) [9] to evaluate spinal stability of patients with spinal metastases. NOMS score [10] and Harrinton score [11] were used to evaluate the treatment decision of spinal metastases. According to various kinds of scores and types, TES (Total en-bloc) surgery can achieve the purpose of local radical resection and reduce the local recurrence rate for patients with expected survival time of more than 1-year, solitary oligometastases and poor spinal stability [12]. For patients with short survival time and multiple metastases, palliative circumferential decompression, separation surgery [13] and pedicle screw-rod system fixation can be selected. Polymethylmethacrylate-(PMMA) augmented fenestrated screws/cement augmented pedicle screw is a new type of pedicle screw with a hollow type and lateral hole, which can inject bone cement into the vertebral body through the tail of the screw after screw implantation. Through the anchoring effect of bone cement, the fixation effect of pedicle screw can be enhanced [14]. It was originally used in spinal surgery in patients with osteoporosis to prevent the failure of internal fixation caused by bone mass loss of screw-implanted segments [15]. Biomechanical tests showed that it had a good anti-pullout effect, and it was safe and effective in the surgical model of osteoporosis and revision of the spine [16]. Currently, there are no reports on whether the cement augmented pedicle screw group can be used in the surgery of spinal metastases to reduce screw loosening caused by osteolytic destruction, prevent adjacent segmental metastasis and improve local control rate after spinal metastases.

In this study, patients with spinal metastases who underwent posterior separation were retrospectively analyzed and divided into two groups according to the application of cement augmented pedicle screws or conventional pedicle screws during operation. The clinical, imaging and pathological data, time of operation, the amount of bleeding and complications, pain and neurological function before and after

surgery were compared between the two groups. In addition, the local control and progression-free survival time of the patients after surgery were followed up. The safety and efficacy of cement augmented pedicle screws in the separation surgery of spinal metastases were evaluated.

Materials And Methods

Subjects

Patients with spinal metastases who underwent posterior separation surgery and pedicle screw internal fixation in the Department of Orthopaedics of the Fourth Hospital of Hebei Medical University from January 2015 to January 2017 were collected retrospectively. Inclusion criteria were as follows: (1) patients with a clear history of malignant tumor and spinal metastases were confirmed by puncture pathology before operation; (2) patients in good general condition and could tolerate the surgery, and the expected survival time was more than 3 months; (3) patients treated with posterior separation surgery combined with cement augmented pedicle screws or conventional pedicle screws for internal fixation; (4) patients with varying degrees of pain, neurological dysfunction and spinal instability; (5) patients with complete preoperative and postoperative clinical imaging data, as well as follow-up data. The endpoint for observation was local progression, loss of follow-up or death. Exclusion criteria were as follows: (1) patients without no pathological diagnosis before surgery, no pain and neurological injury, no spinal instability, or bone metastasis caused by severe destruction of adjacent multi-segmental bone, unable to implant screws; (2) patients with poor general condition, unable to tolerate the surgery; (3) patients advanced multiple organ metastasis, and the expected survival time before surgery was less than 3 months, and (4) the postoperative follow-up time was less than 3 months and the clinical imaging data were incomplete. A total of 52 cases were collected, including 25 males and 27 females, with an average age of 57.9 ± 8.9 years (the range was 36–72 years). There were 19 cases of primary lung cancer, 12 cases of renal carcinoma, 8 cases of esophageal cancer, 4 cases of colorectal cancer, 3 cases of gastric cancer, 3 cases of breast cancer, 2 cases of liver cancer, 1 case of ovarian cancer; 24 cases of thoracic vertebrae, 28 cases of lumbar vertebrae; 23 cases of single segment and 29 cases of adjacent two or more segments. This study was approved by the Ethics Committee of the Fourth Hospital of Hebei Medical University (No. 20170216), and all the patients signed the informed consent form.

Surgical procedures

Surgical Indications

Patients with preoperative systemic and local imaging evaluation showing that there were multiple metastatic bone metastases or other treatable visceral metastases, and obvious spinal cord compression and spinal instability, and palliative decompression and spinal stability reconstruction should be performed.

Preoperative Preparation

All patients completed the surgery under general anesthesia. The general condition and cardiopulmonary function were routinely evaluated before surgery. The expected bleeding volume was assessed according to the conditions of primary tumors, and 2–4 units of red blood cells and 200–400 ml of plasma were selectively prepared.

Surgical Methods

All the surgeries were performed by the same surgical team in the Department of Orthopaedics, the Fourth Hospital of Hebei Medical University. The posterior median approach was used to peel off and expose the spinous process and lamina of the affected vertebrae and 1–2 segments above and below the affected vertebrae. Pedicle screws were implanted through the pedicles of 1–2 segments above and below the affected vertebrae. Twenty-eight patients were treated with cement augmented pedicle screw (CEOXEN, WEGO, Shandong, China) and 24 patients were treated with conventional pedicle screws (UPASS5.5, WEGO, Shandong, China). The diameters of pedicle screws in both groups were 5.5 mm, 6.0 mm and 6.5 mm, and the lengths were 4.0 cm and 4.5 cm. The separation surgery was performed as follows: the posterior structures such as spinous process, ligament and lamina were removed in blocks, the lateral and anterior compression tissues of the dura mater were removed through entering the bilateral pedicles of the affected vertebrae. Circumferential decompression was fully performed for the spinal cord so that there was a 2–3 mm interval between the spinal cord and the anterior residual vertebrae. Of all the patients, 22 patients (39.3%) used dural patches for obstruction, 21 patients (40.4%) underwent combined affected segmental vertebroplasty before circumferential decompression. For patients in the cement augmented pedicle screw group, bone cement was injected into the tail of the screw, and the process was monitored by C-arm X-ray fluoroscopy.

Postoperative Treatment

Patients within the routine supine position after operation. The bedside X-ray was examined immediately to evaluate the screw implantation and bone cement injection. The drainage tube was removed when the daily drainage volume was less than 50 ml per day, and the brace was used for activity to get out of bed 24–48 h after removal, and the CT was reexamined for the operative segments. All patients were treated with standard bisphosphate drugs after operation, and appropriate chemotherapy, endocrine therapy, or targeted drug therapy were selected according to different primary lesions. After surgery, 73.1% of the patients received stereotactic body radiotherapy (SBRT) for the operative segments of the affected vertebrae.

Evaluation indicators

Tomita score and Tokuhashi score were used to evaluate the expected survival time of patients in the two groups. Visual analogue scale (VAS) was used to evaluate the pain of the patients, in which 1–3 points indicated mild pain, 4–6 points indicated moderate pain and 7–10 points indicated severe pain. The neurological function injury was evaluated by Frankel grading, which included grade A to E. The degree of spinal instability was evaluated by the SINS score according to the preoperative imaging.

Efficacy: The VAS score and Frankel grade of the two groups were recorded before and 3 months after operation, and the differences between the two groups were compared to evaluate the efficacy of the surgery.

Safety: The operation time, the amount of intraoperative blood loss, the amount of bone cement injected in the pedicle screw group and the complications of the surgery were recorded to evaluate the safety of cement augmented pedicle screw.

Follow-up evaluation: All patients were followed up by outpatient reexamination. The first follow-up was performed at 3 months after surgery, and then was performed every 3 months. The contents of reexamination included an X-ray of the surgical site, spinal CT and MRI. A whole body bone scan was performed every 6 months, and the metastasis was evaluated according to the CT or MRI reexamination of corresponding organs. The endpoint was tumor progression in local and adjacent segments or death of patients. According to the manifestations of X-ray and CT, as well as the corresponding clinical symptoms, the internal fixation failure (loosening, fracture, or pullout) was evaluated. If the translucent zone around the screw on the CT or screw displacement or fracture compared with that on the first postoperative CT, accompanied by activity pain due to the corresponding segment, it was identified as internal fixation failure. The failure rate of internal fixation was compared between the two groups of patients with different pedicle screws to analyze the efficacy of cement augmented pedicle screws. For the evaluation of local tumors, according to the re-examination of X-ray, CT and MRI, the increase of local soft-tissue shadow, bone destruction or aggravation of pathological fracture in the operative segment was identified as local tumor progression. The new abnormal signal, new bone destruction or aggravation of the original bone destruction in the adjacent segments were identified as the tumor progression in the adjacent segments. When the tumor progression occurred in the surgical or adjacent segment, it was regarded as the local progression, that was, the endpoint of observation. The time of loss of follow-up, death and local progression were recorded. The difference in local progression-free survival time between the two groups were compared, and the effect of different pedicle screws on the local control rate was analyzed.

Statistical analyses

SPSS21.0 (Chicago IL, USA) was used for statistical analysis. The measurement data were tested for normality at first, and the data in accordance with normal distribution were expressed by mean ± standard deviation, and the paired *t*-test was used for comparison between groups. The data that did not conform to the normal distribution was represented by the median (interquartile range), and the comparison between groups was performed by the nonparametric Mann-Whitney *U* test. The counting

data were expressed by percentage, and the chi-square test was used for comparison between groups. The difference of local progression-free survival between the two groups was calculated by the K-M survival curve. $P > 0.05$ was accepted as a statistically significant difference.

Results

General data of the two groups

There were no significant differences in sex, age, surgical sites, surgical segments and Tomita classification between the cement augmented pedicle screw group and conventional pedicle screw group (all $P > 0.05$, Table 1). The 52 patients had a Tomita score of 5–8 points, and a Tokuhashi score of 5–9 points. According to the preoperative imaging, all the patients had different degrees of spinal instability, and the SINS scores were 9–14 points. There were no significant differences in Tomita score, Tokuhashi score and SINS score between the two groups (all $P > 0.05$, Table 1).

Table 1
General clinical data of patients in the two groups

		Cement pedicle screw group	Conventional pedicle screw group	*P*
Sex	Male	13	12	0.797
	Female	15	12	
Age	> 60	17	14	0.862
	≤ 60	11	10	
Surgical sites	Thoracic vertebra	10	14	0.103
	Lumbar vertebra	18	10	
Surgical segments	Single segment	13	10	0.730
	≥ 2 segments	15	14	
Tomita classification	IV	6	4	0.904
	V	7	6	
	VI	8	9	
	VII	7	5	
Tomita score		6.96 ± 0.84	6.88 ± 0.80	0.697
Tokuhashi score		7.43 ± 0.92	7.79 ± 1.06	0.193
SINS score		11.36 ± 1.52	10.75 ± 1.15	0.116
Note: SINS, spinal instability neoplastic score.				

Surgical conditions, complications and postoperative treatment in the two groups

All the surgeries were performed smoothly, the processes of intraoperative screw implantation were smooth in both groups, and there was no intraoperative screw loosening. The average operation time was 163 ± 20 min in the cement augmented pedicle screw group and 138 ± 18 min in the conventional pedicle screw group, with a statistically significant difference ($P < 0.05$, Table 2). The combined intraoperative vertebroplasty was performed in 21 patients (40.4%), which was 12 patients in the cement augmented pedicle screw group and 9 patients in the conventional pedicle screw group ($P > 0.05$). The average amount of blood loss was 623 ± 185 ml in the cement augmented pedicle screw group and 733 ± 163 ml in the conventional pedicle screw group ($P < 0.05$, Table 2). For the 28 patients in the cement augmented

pedicle screw group, a total of 218 screws were implanted, with an average of 1.3 ± 0.4 ml bone cement injected into each screw.

Table 2
Surgical conditions, complications and postoperative treatment of patients in the two groups

		Cement pedicle screw group	Conventional pedicle screw group	*P*
Operation time (min)		163 ± 20	138 ± 18	< 0.001
Intraoperative blood loss (ml)		733 ± 163	623 ± 185	0.027
Postoperative hospital stays		8.3 ± 1.4	7.7 ± 1.0	0.086
Intraoperative vertebroplasty	Yes	12	9	0.695
	No	16	15	
Postoperative cerebrospinal fluid leakage	Yes	1	1	0.935
	No	27	24	
Postoperative SBRT	Yes	20	18	0.772
	No	8	6	
Note: SBRT, stereotactic body radiotherapy.				

The occurrence rate of postoperative cerebrospinal fluid leakage in the cement augmented pedicle screw group and conventional pedicle screw group was 3.6% (1 to 28) and 4.2% (1 to 24), respectively ($P < 0.05$, Table 2). Prone position, intermittent clamping and drainage were applied, and the incisions achieved primary healing without hematoma formation, infection and other complications. There was no significant difference in the occurrence rate of postoperative complications between the two groups. No symptomatic pulmonary cement embolism occurred in the cement augmented pedicle screw group. The average postoperative hospital stay was 8.3 ± 1.4 days in the cement augmented pedicle screw group and 7.7 ± 1.0 days in the conventional pedicle screw group, with no significant difference ($P > 0.05$, Table 2). The postoperative SBRT was performed in 20 and 18 patients in the cement augmented pedicle screw group and conventional pedicle screw group, respectively, with no significant difference between the two groups ($P > 0.05$, Table 2).

Efficacy and follow-up of cement augmented pedicle screw treatment

The preoperative VAS scores of the two groups were 5.79 ± 1.81 and 6.00 ± 2.04, respectively, with no significant difference between the two groups ($P > 0.05$, Table 3). Three months after surgery, the VAS scores of cement augmented pedicle screw group and conventional pedicle screw group were 2.93 ± 1.33

and 4.17 ± 1.34, respectively, and the difference between the two groups was statistically significant ($P < 0.01$, Table 3). The postoperative VAS scores in the two groups were significantly lower than those of before operation (both $P < 0.001$, Table 3).

Table 3
Efficacy and follow-up of cement augmented pedicle screw treatment

		Cement pedicle screw group	Conventional pedicle screw group	*P*
Preoperative VAS score		5.79 ± 1.81	6.00 ± 2.04	0.704
Postoperative VAS score		2.93 ± 1.33*	4.17 ± 1.34*	0.002
Preoperative Frankel grade	A, B	12	11	0.796
	C, D	16	13	
Postoperative Frankel grade	A, B	3	3	0.752
	C, D	18	13	
	E	7	8	
Failure of internal fixation	Yes	1	7	0.011
	No	27	17	
Adjacent segmental metastasis	Yes	2	8	0.017
	No	26	16	

Note: *, compared with preoperative VAS score, $P < 0.001$. VAS, visual analogue scale.

As for the recovery of neurological function injury, the Frankel grading in 84.6% (22/52) of patients recovered at least 1 grade 3 months after operation, but there was no significant difference in Frankel grades between the two groups before and after operation (all $P > 0.05$, Table 1).

Postoperative imaging of all patients showed that the position of pedicle screws was satisfactory (Fig. 1). Bone cement leakage occurred in 2 patients (7.1%) in the cement augmented pedicle screw group, all of which were leaked into the anterior vertebral venous plexus and no leakage into the posterior spinal canal. During the follow-up period, the failure rate of internal fixation for all patients was 15.4% (8/52), including one case in the cement augmented pedicle screw group and 7 cases in the conventional pedicle screw group, the difference was statistically significant ($P < 0.05$, Table 3). All patients were followed up for an average of 15.9 ± 5.2 months (the range was 6–24 months). During the follow-up period, there were 16 cases of local progression (10 cases of adjacent segmental metastasis or

progression, 6 cases of tumor progression in situ, Table 3). Four cases were lost for follow-up. The 6-month local control rate was 98.1% (51/52), and the 12-month local control rate was 65.4% (34/52). There was a significant difference in local progression-free survival between the two groups ($P < 0.05$, Fig. 2).

Discussion

The purpose of separation surgery for spinal metastatic tumors is to quickly relieve pain and spinal cord compression, maintain or reconstruct spinal stability, provide a safe distance for postoperative radiotherapy, reduce the risk of radiation-induced spinal cord injury and improve the efficacy of radiotherapy. Maintaining long-term and effective spinal stability is an important evaluation criterion of surgical efficacy. It is of great significance to explore the application prospect of cement augmented pedicle screw in the separation surgery of spinal metastases. In this study, we confirmed that cement augmented pedicle screws are effective in reducing the pain and adjacent segmental metastasis of spinal malignancy, failure rate of internal fixation, as well as prolonging the local progression-free survival time of patients.

Efficacy and safety of cement augmented pedicle screw

In previous studies, cement augmented pedicle screws were widely used in spinal surgery in patients with osteoporosis to improve screw fixation strength and reduce the incidence of internal fixation failure. Ghermandi et al. [17] performed 53 operations in 52 patients, and 247 cement augmented pedicle screws were implanted. The results showed that cement augmented pedicle screws can be used in tumor patients including revision surgery, osteoporosis and bone destruction. Chandra et al. [18, 19] applied cement augmented pedicle screws combined with O-TLIF or Mis-TLIF interbody fusion in patients with osteoporosis combined with lumbar spondylolisthesis, and achieved good results, satisfactory pain relief, and effective interbody fusion. Yuan et al. [20] treated 27 patients with continuous osteoporosis by cement augmented pedicle screw fixation guided by 3D navigation, which included 8 cases of thoracolumbar fracture, 18 cases of spinal degeneration and 1 case of revision. Except for 1 patient who died of postoperative pneumonia, the average improvement rate of the JOA score was 39.6%. Follow-up within 12 months after operation showed that 20 patients had bone fusion (bone fusion rate was 76.9%). No screw loosening was found, indicating that PMMA-enhanced thoracolumbar pedicle screw fixation guided by 3D navigation had a good effect on patients with osteoporosis. Karaka et al. followed up 55 patients with cement augmented pedicle screw fixation. Postoperative imaging showed bone cement leakage in 7 patients (12.7%), asymptomatic pulmonary cement embolism in 3 patients (5.4%), and deep incision infection in 3 patients (5.4%) [21]. Choy et al. [22] found, by CT scanning, in a patient with severe kyphosis after pedicle screw fixation that the augmentation of bone cement was limited to the end of the screw, and there was loosening and halo around the pedicle screw body. Moreover, there was evidence that the screw was pulled out, thus questioning the risks and benefits of spinal fusion with cement augmented pedicle screw fixation. Although the occurrence rate of this phenomenon was low, the indications should be carefully considered in the application of cement augmented pedicle screw fixation.

In addition, due to the lack of tap expansion channel and the process of balloon dilatation, the injection of bone cement into the vertebral body through pedicle screw under high pressure may increase the probability of bone cement entering into the blood, which will lead to pulmonary cement embolism (PCE). Ulusoy et al. [23] observed the application of cement augmented pedicle screws in 281 patients with spinal deformity and found that the overall incidence of radiological PCE was 16.3%. The incidence of symptomatic PCE was 1.4%. When the number of screws ≥ 7, the risk of symptomatic PCE increased significantly. When the number of screws > 14 and the dosage of cement was more than 20–25 cc, it may lead to increased pulmonary artery pressure and right ventricular dilatation.

In this study, we found that the overall failure rate of internal fixation in the patients during the follow-up period was 15.4%. It was considered that with the progression of spinal metastases, severe collapse of the vertebral body in front of the surgical segment led to aggravation of kyphosis or metastasis of adjacent screw segments, eventually resulting in screw loosening. However, there was only one case of screw loosening caused by adjacent segmental metastasis in the cement augmented pedicle screw group. Compared with the conventional pedicle screw group, the occurrence rate of internal fixation failure was significantly lower, and the difference was statistically significant. It is suggested that the cement augmented pedicle screws have a good fixation effect. In this study, the patients in the cement augmented pedicle screw group had no intraspinal cement leakage and no symptomatic cement embolism, suggesting that it has good safety.

Analysis of the curative effect of cement augmented pedicle screw fixation

At present, there is no case report on the application of cement augmented pedicle screws in spinal metastases. Sussman et al. [24] treated a patient with bone metastasis with spinal canal decompression and cement augmented pedicle screw internal fixation, which effectively relieved the pain symptoms of the patient. Wu et al. [25] implanted cement augmented pedicle screw fixation with the assistance of a spinal robot in a patient with multiple spinal metastases of the breast, which effectively improved the patient's quality of life. Kim [26] used percutaneous cement augmented pedicle screw fixation in 14 patients with spinal metastases. Results showed that the pain of patients was effectively relieved, which showed that cement augmented pedicle screw fixation can provide obvious pain relief and improve the quality of life for some patients with spinal metastases.

There were no significant differences in sex, age, surgical sites and segments between the two groups. The preoperative Tomita classifications were typed IV-VII, Tomita scores were 6–8 points, Tokuhashi scores were 5–9 points, SINS scores were 9–13 points, VAS scores were 2–10 points, and Frankel grading were grade A-D. These parameters were not significantly different between the two groups, indicating that the clinical data of the two groups were consistent with each grading system, and the curative effect can be compared. The expected survival time was shorter, and the stability of the spine was poor, so it was suitable for palliative decompression combined with spinal internal fixation. There was no significant difference in the proportion of patients who underwent vertebroplasty, as well as the

amount of bleeding during the operation. However, the operation time was longer in the cement augmented pedicle screw group, which was considered to be related to the need for multiple fluoroscopies during the injection of cement into the pedicle screw. Patients in both groups were treated with bisphosphate after operation, and there was no significant difference in the proportion of patients who received SBRT. Pain and neurological function were evaluated 3 months after operation, and it was found that neurological function was recovered in 84.6% of the patients. There was no statistical difference in Frankel grade between the two groups. The VAS scores were decreased after surgery in the two groups, and it was lower in the cement augmented pedicle screw group than that of the conventional pedicle screw group, and the difference was statistically significant, suggesting that the surgical decompression in the two groups was effective. The postoperative treatment was standardized, and the recovery of spinal function was good. The patients in the cement augmented pedicle screw group had better spinal stability after reconstruction. There were fewer patients with persistent pain due to spinal instability after operation.

Effect of cement augmented pedicle screw on local control rate

Postoperative additional radiotherapy for patients with spinal metastases was helpful to improve the local control rate of the tumor, but patients with spinal metastases were often complicated with spinal cord compression, and it was difficult to reach the effective radiation dose near the spinal cord lesions [27]. In addition, pedicle screws interfered with the radiation dose distribution of the vertebral body, resulting in insufficient radiation dose near the vertebral segment of spinal metastases [28]. Through the thermal and chemical effects in the process of solidification, bone cement can inhibit the invasion of bone metastases [29].

Cyteval et al [30] treated 49 patients with vertebral compression fractures by conservative treatment or vertebroplasty with a small amount of bone cement injection, respectively. It was found that there was no significant difference in the new fracture rate 3 months after operation between the two groups, suggesting that a small amount of cement cannot prevent the fracture of adjacent vertebrae. However, for spinal metastases, the dispersion and distribution of bone cement may affect the probability of local recurrence or progression. The bone cement was injected into the vertebral body through the tail of cement augmented pedicle screw and dispersed into the vertebral body through the window hole on the side of the screw, which limited the distribution and dispersion of bone cement to a certain extent, and the amount of bone cement injection was limited. In this study, the average amount of cement injected into each screw in the cement augmented pedicle screw group was 1.3 ± 0.4 ml. Compared with the conventional pedicle screw group, the adjacent segment metastasis rate was lower and the local progression-free survival time was significantly prolonged during the follow-up period. It is suggested that cement augmented pedicle screw fixation can effectively reduce the incidence of adjacent segment metastasis.

This study also has some limitations. Firstly, it was a retrospective study in a single center. Large scale multi-center randomized controlled studies are needed to further confirm the conclusions in this study in the future. Secondly, the sample size of patients is relatively small. We will collect more cases to expand the sample size of patients with spinal metastases who are treated with cement augmented pedicle screws in our center. Thirdly, due to the hollow design, the screws are easy to break. At present, the application of cement augmented pedicle screws with 5.0 mm or less in diameter is relatively rare, so there is a lack of reports and studies on the application in upper thoracic and cervical vertebrae. In addition, due to the increased times of fluoroscopy in the process of bone cement injection and the relative prolongation of operation time, we still need to be cautious about complications such as bone cement leakage and pulmonary cement embolism.

Conclusions

In conclusion, the application of cement augmented pedicle screws in the surgical operation of spinal metastatic tumors has a good effect, which can effectively reduce screw loosening and pull-out, reduce the failure rate of internal fixation, and prevent the occurrence of adjacent segmental metastasis and improve the local control rate.

Declarations

Funding

This work was supported by the Key Medical Science Research Projects of Hebei Province (No. 20170162).

Authors' contributions

We declare that all the listed authors have participated actively in the study and all meet the requirements of the authorship. Qi Feng and Jiangang Feng designed the study and drafted and edited the manuscript. Donglai Wang and Zibo Zang analyzed the data.

Ethics approval and consent to participate

This study was approved by the Ethics Committee of the Fourth Hospital of Hebei Medical University (No. 20170216), and all the patients signed the informed consent form.

Consent for publication

Not applicable

Availability of data and material

All the data and material were presented in the main paper.

Competing interests

All authors have no conflicts of interest to declare.

Acknowledgements

None

References

[1] Perez-Garcia J, Munoz-Couselo E, Cortes J. Bone metastases: Causes, consequences and therapeutic opportunities[J]. EJC Suppl, 2013,11(2):254-256. DOI: 10.1016/j.ejcsup.2013.07.035.

[2] Lo SS, Lutz ST, Chang EL, et al. ACR Appropriateness Criteria (R) spinal bone metastases[J]. J Palliat Med, 2013,16(1):9-19. DOI: 10.1089/jpm.2012.0376.

[3] Siegel GW, Biermann JS, Calinescu AA, et al. Surgical Approach to Bone Metastases[J]. Curr Osteoporos Rep, 2018,16(4):512-518. DOI: 10.1007/s11914-018-0463-7.

[4] Elder BD, Lo SF, Holmes C, et al. The biomechanics of pedicle screw augmentation with cement[J]. Spine J, 2015,15(6):1432-1445. DOI: 10.1016/j.spinee.2015.03.016.

[5] Depreitere B, Ricciardi F, Arts M, et al. Loss of Local Tumor Control After Index Surgery for Spinal Metastases: A Prospective Cohort Study[J]. World Neurosurg, 2018,117:e8-8e16. DOI: 10.1016/j.wneu.2018.04.170.

[6] Westermann L, Olivier AC, AUID- Oho, et al. Analysis of seven prognostic scores in patients with surgically treated epidural metastatic spine disease[J]. Acta Neurochir (Wien), 2020,162(1):109-119. DOI: 10.1007/s00701-019-04115-9.

[7] Kwon YM, Kim KS, Kuh SU, et al. Survival rate and neurological outcome after operation for advanced spinal metastasis (Tomita's classification > or = type 4)[J]. Yonsei Med J, 2009,50(5):689-696. DOI: 10.3349/ymj.2009.50.5.689.

[8] Halm H, Richter A, Lerner T, et al. [En-bloc spondylectomy and reconstruction for primary tumors and solitary metastasis of the spine][J]. Orthopade, 2008,37(4):356-366. DOI: 10.1007/s00132-008-1231-7.

[9] Arana E, Kovacs FM, Royuela A, et al. Spine Instability Neoplastic Score: agreement across different medical and surgical specialties[J]. Spine J, 2016,16(5):591-599. DOI: 10.1016/j.spinee.2015.10.006.

[10] Laufer I, Bilsky MH. Advances in the treatment of metastatic spine tumors: the future is not what it used to be[J]. J Neurosurg Spine, 2019,30(3):299-307. DOI: 10.3171/2018.11.SPINE18709.

[11] Davarski AN, Kitov BD, Zhelyazkov CB, et al. Surgical management of metastatic tumors of the cervical spine[J]. Folia Med (Plovdiv), 2013,55(3-4):39-45. DOI: 10.2478/folmed-2013-0026.

[12] Charest-Morin R, Flexman AM, Srinivas S, et al. Perioperative adverse events following surgery for primary bone tumors of the spine and en bloc resection for metastases[J]. J Neurosurg Spine, 2019:1-8. DOI: 10.3171/2019.6.SPINE19587.

[13] Cofano F, Di Perna G, Marengo N, et al. Transpedicular 3D endoscope-assisted thoracic corpectomy for separation surgery in spinal metastases: feasibility of the technique and preliminary results of a promising experience[J]. Neurosurg Rev, 2020,43(1):351-360. DOI: 10.1007/s10143-019-01204-2.

[14] Moon BJ, Cho BY, Choi EY, et al. Polymethylmethacrylate-augmented screw fixation for stabilization of the osteoporotic spine : a three-year follow-up of 37 patients[J]. J Korean Neurosurg Soc, 2009,46(4):305-311. DOI: 10.3340/jkns.2009.46.4.305.

[15] Bludau F, Welzel G, Reis T, et al. Phase I/II trial of combined kyphoplasty and intraoperative radiotherapy in spinal metastases[J]. Spine J, 2018,18(5):776-781. DOI: 10.1016/j.spinee.2017.09.011.

[16] Zajaczkowska R, 0000-0003-3511-5169 AO, Kocot-Kepska M, et al. Bone Pain in Cancer Patients: Mechanisms and Current Treatment[J]. Int J Mol Sci, 2019,20(23)DOI: 10.3390/ijms20236047.

[17] Ghermandi R, Pipola V, Colangeli S, et al. Polymethylmethacrylate-augmented fenestreted pedicle-screw fixation in low bone quality patients: a case series and literature review[J]. J Biol Regul Homeost Agents, 2018,32(6 Suppl. 1):71-76.

[18] Chandra VV, Prasad BC, Jagadeesh MA, et al. Segmental polymethylmethacrylate-augmented fenestrated pedicle screw fixation for lumbar spondylolisthesis in patients with osteoporosis - A case series and review of literature[J]. Neurol India, 2017,65(1):89-95. DOI: 10.4103/0028-3886.198229.

[19] Chandra VVR, Prasad BC, Jagadeesh MA, et al. Minimally invasive transforaminal lumbar interbody fusion using bone cement-augmented pedicle screws for lumbar spondylolisthesis in patients with osteoporosis. Case series and review of literature[J]. Neurol India, 2018,66(1):118-125. DOI: 10.4103/0028-3886.222826.

[20] Yuan Q, Zhang G, Wu J, et al. Clinical evaluation of the polymethylmethacrylate-augmented thoracic and lumbar pedicle screw fixation guided by the three-dimensional navigation for the osteoporosis patients[J]. Eur Spine J, 2015,24(5):1043-1050. DOI: 10.1007/s00586-013-3131-8.

[21] Karaca S, Enercan M, Levent UO, et al. Radiologic and clinical outcome of the cement augmented pedicle screws after a minimum 2-year follow-up[J]. Acta Orthop Belg, 2019,85(2):247-252.

[22] Choy WJ, AUID- Oho, Walsh WR, et al. Technical Note: Pedicle Cement Augmentation with Proximal Screw Toggle and Loosening[J]. Orthop Surg, 2019,11(3):510-515. DOI: 10.1111/os.12467.

[23] Ulusoy OL, Kahraman S, Karalok I, et al.Pulmonary cement embolism following cement-augmented fenestrated pedicle screw fixation in adult spinal deformity patients with severe osteoporosis (analysis of 2978 fenestrated screws) [J]. Eur Spine J. 2018 Sep;27(9):2348-2356. DOI: 10.1007/s00586-018-5593-1.

[24] Sussman ES, Ho A, Pendharkar AV, et al. Image-guided Percutaneous Polymethylmethacrylate-augmented Spondylodesis for Painful Metastasis in the Veteran Population[J]. Cureus, 2019,11(4):e4509. DOI: 10.7759/cureus.4509.

[25] Wu C, Lee CY, Huang TJ, et al. Cement-augmented pedicle screw insertion assisted by spinal robotic systems for widespread spinal metastases[J]. J Robot Surg, 2019,13(4):595-598. DOI: 10.1007/s11701-018-0886-2.

[26] Kim P, Kim SW. Bone Cement-Augmented Percutaneous Screw Fixation for Malignant Spinal Metastases: Is It Feasible?[J]. J Korean Neurosurg Soc, 2017,60(2):189-194. DOI: 10.3340/jkns.2016.0909.003.

[27] Barragán -Montero AM, Nguyen D, Lu W, et al. Three-dimensional dose prediction for lung IMRT patients with deep neural networks: robust learning from heterogeneous beam configurations[J]. Med Phys, 2019,46(8):3679-3691. DOI: 10.1002/mp.13597.

[28] Kim YJ, Kim JH, Kim K, et al. The Feasibility of Spinal Stereotactic Radiosurgery for Spinal Metastasis with Epidural Cord Compression[J]. Cancer Res Treat, 2019,51(4):1324-1335. DOI: 10.4143/crt.2018.653.

[29] Sadeghi-Naini M, Aarabi S, Shokraneh F, et al. Vertebroplasty and Kyphoplasty for Metastatic Spinal Lesions: A Systematic Review[J]. Clin Spine Surg, 2018,31(5):203-210. DOI: 97/BSD.0000000000000601.

[30] Cyteval C, Thomas E, Solignac D, et al. [Prospective evaluation of fracture risk in osteoporotic patients after low cement volume vertebroplasty][J]. J Radiol, 2008,89(6):797-801. DOI: 10.1016/s0221-0363(08)73786-7.

Figures

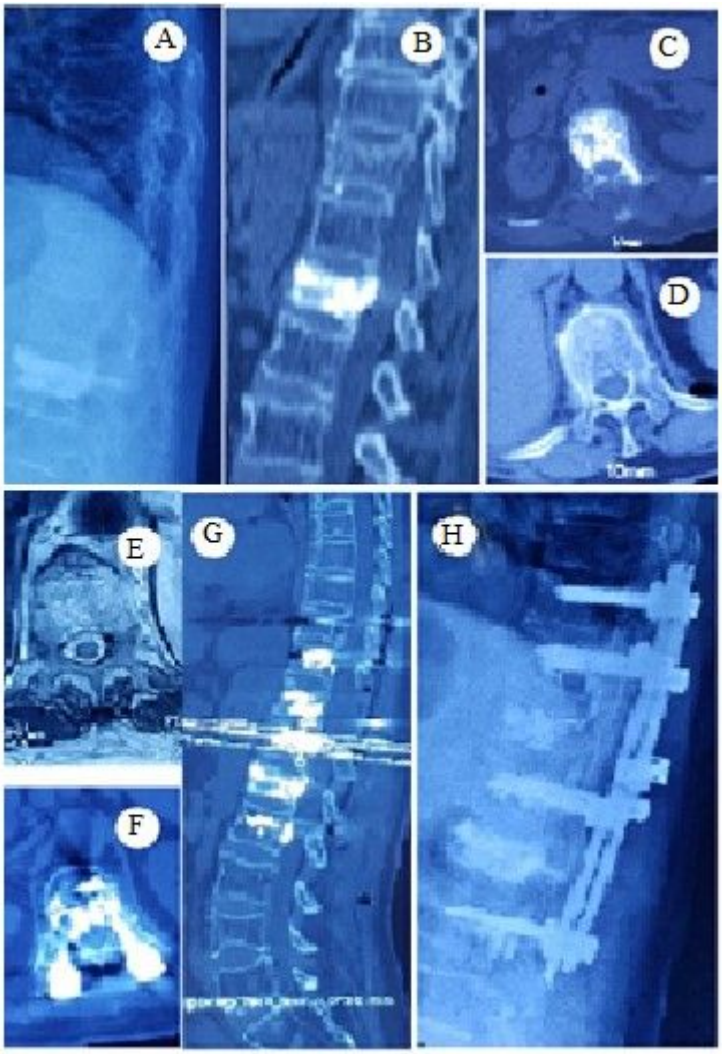

Figure 1

The patient was 56 years old, with multiple bone metastasis of lung cancer, who was hospitalized due to thoracolumbar and back pain. He has a previous history of vertebroplasty because of 1 lumbar metastasis. Preoperative reexamination showed partial invasion of bone cement into the spinal canal and bone destruction of the eleventh thoracic segment, which was considered as new metastasis. Tomita score was 6 points, modified Tokuhashi score was 7 points, VAS score was 6 points, Frankel grade was grade C, SINS score was 11 points. On November 1, 2016, posterior separation surgery, the eleventh thoracic vertebroplasty and cement augmented pedicle screw fixation were performed. The operation time was 150 minutes, and the intraoperative blood loss was 500ml. The VAS score at 3 months after operation was 2 points, and the Frankel grade was grade E. A: pre-operative thoracolumbar X-ray; B, C, D: Preoperative CT of thoracolumbar segments; E: Preoperative MRI of the eleventh thoracic vertebra; F, G: Postoperative CT; H: Postoperative X-ray of thoracolumbar segments.

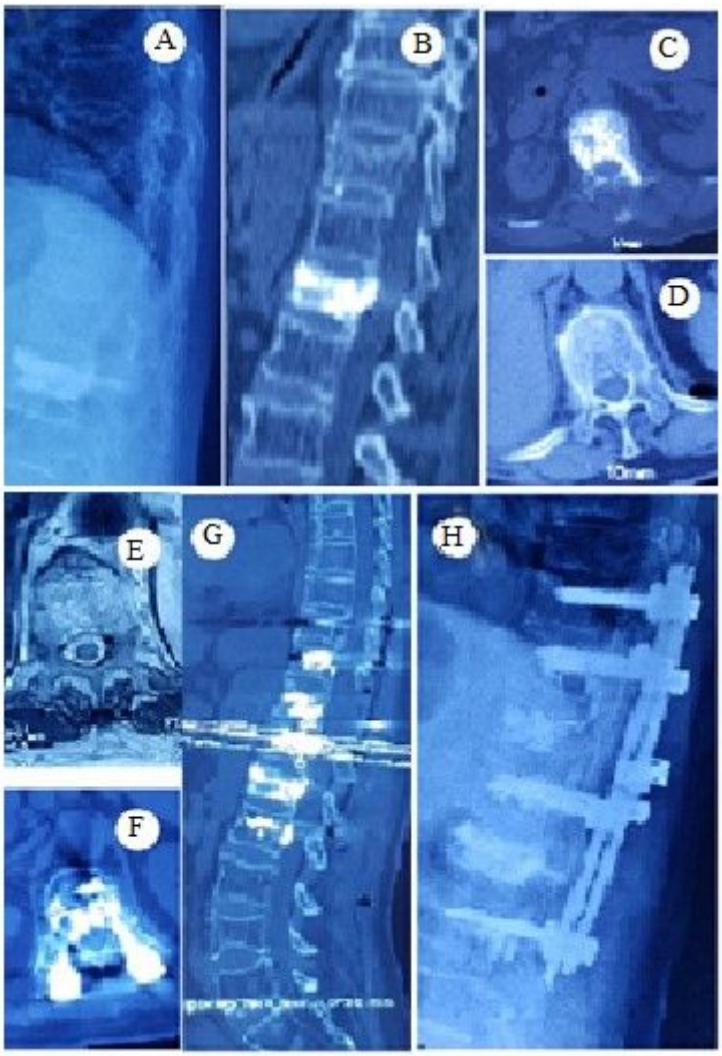

Figure 1

The patient was 56 years old, with multiple bone metastasis of lung cancer, who was hospitalized due to thoracolumbar and back pain. He has a previous history of vertebroplasty because of 1 lumbar metastasis. Preoperative reexamination showed partial invasion of bone cement into the spinal canal and bone destruction of the eleventh thoracic segment, which was considered as new metastasis. Tomita score was 6 points, modified Tokuhashi score was 7 points, VAS score was 6 points, Frankel grade was grade C, SINS score was 11 points. On November 1, 2016, posterior separation surgery, the eleventh thoracic vertebroplasty and cement augmented pedicle screw fixation were performed. The operation time was 150 minutes, and the intraoperative blood loss was 500ml. The VAS score at 3 months after operation was 2 points, and the Frankel grade was grade E. A: pre-operative thoracolumbar X-ray; B, C, D: Preoperative CT of thoracolumbar segments; E: Preoperative MRI of the eleventh thoracic vertebra; F, G: Postoperative CT; H: Postoperative X-ray of thoracolumbar segments.

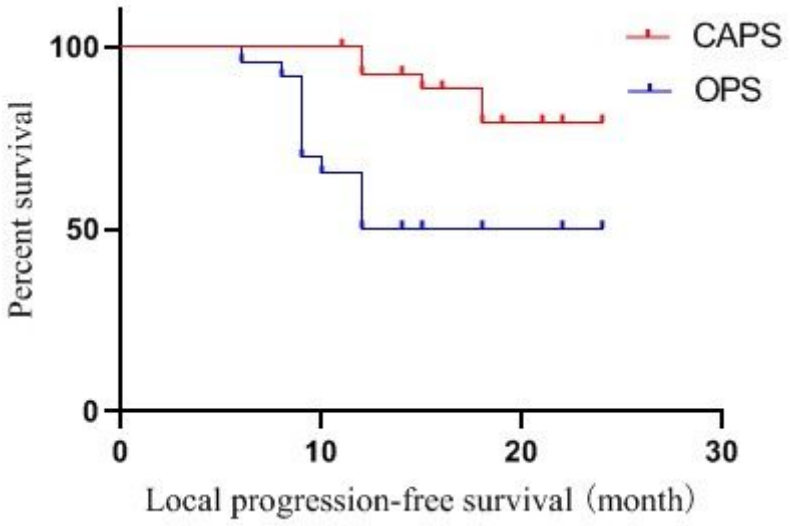

Figure 2

Local progression-free survival time of the two groups. CAPS: cement augmented pedicle screw group, OPS: ordinary pedicle screw group, P<0.05.

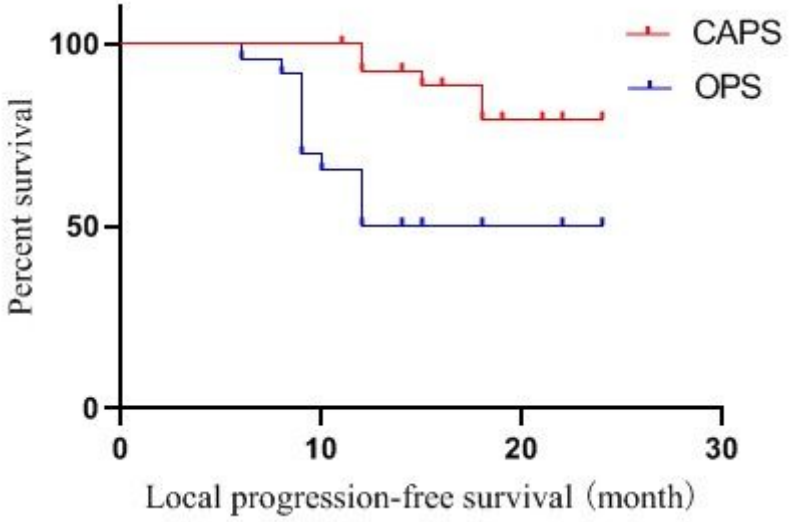

Figure 2

Local progression-free survival time of the two groups. CAPS: cement augmented pedicle screw group, OPS: ordinary pedicle screw group, P<0.05.