A Huge Mullerian Duct Remnants in An Adult: A Case Report and Literature Review

Yonghui Wang (wyh1661170553@163.com)
Beijing Tongren Hospital

Peng Xiang
Beijing Tongren Hospital

Wei Wang
Beijing Tongren Hospital

Shuang Li
Beijing Tongren Hospital

Hao Ping
Beijing Tongren Hospital

Yuexin Liu
Beijing Tongren Hospital

Case report

Keywords: müllerian duct remnants, laparoscopic surgery, diagnosis

Posted Date: November 20th, 2020

DOI: https://doi.org/10.21203/rs.3.rs-111300/v1

Abstract

Background: müllerian duct remnant is a disease which was reported infrequently. The cyst's size in this case is even rarer. We performed surgery on this patient and introduced the procedure in detail.

Case presentation: We present a case that a 58-year-old patient with a huge müllerian duct remnant between the prostate and rectum. Magnetic resonance imaging and computed tomography scan of abdominal and pelvic showed that a cystic lesion with a size of 14×10×10 cm in the pelvic cavity. There were no surgical contraindications were found after some related preoperative examinations, so the laparoscopic surgery was performed. The features of the mass of postoperative pathologic examination presented that the characteristics are consistent with the Müllerian duct.

Conclusions: Laparoscopic excision is a perfect way to manage müllerian duct remnant. This way can get good outcome and minimize the damage to the patient.

Background

Müllerian duct remnants(MDRs) is a rare congenital urinary disease caused by incomplete regression of the müllerian duct[1]. Although some MDRs are asymptomatic, this may present as a prostatic utricle cyst or as a pelvic mass of varying size[2]. Few cases with laparoscopic excision MDRs have been reported. Here we report a rare case of huge MDRs and provide our experience in management of MDRs.

Case Presentation

A 58 years old male with an 8-year history of low back pain was referred to our department. The patient had low back pain for eight years with no prostate-specific reason and he had no bladder irritation symptoms such as frequent micturition, urgency, or incontinence. But the low back pain is aggravated 4 months ago. Then he came to our department for treatment. He had been diagnosed as a hepatitis B virus carrier and had undergone a laparoscopic appendectomy thirty years ago. The scrotum and penis were normally developed, both testes were descended well and the size was normal. The prostate was untouchable on the rectal examination, and the doctor can't touch any lump.

Related laboratory examinations' indexes were within the normal range, including hemoglobin, leukocyte, serum electrolytes and creatinine, besides, urine culture was negative. Preoperative serum prostate-specific antigen (PSA) was 1.29 ng/ml and the results of other tumor markers (cancer antigen-199, cancer antigen-125,carcinoembryonic antigen, and alpha-fetoprotein) were negative. Abdominal and pelvic computed tomography scan revealed a large irregular cystic-solid mass in the right side of the pelvic cavity, and there are compartments in the mass. Contrast-enhanced CT showed that the moderate enhancement of the cyst wall (Fig. 1). The septa, the bladder and the rectum were compressed by the lesion, but there was no invasion (Fig. 2). Transrectal biopsy was underwent after all the above examinations. The pathological results confirmed that the mass contain müllerian ducts structure. Therefore, surgeons planned to perform laparoscopic excision of the cyst. The patient underwent flexible

cystoscopy before the procedure. Flexible cystoscopy was normal. Then, two ureteral stents were placed. After that, the surgeons injected methylene blue into the bladder to see if there was any bladder damage during the operation.

Following this, we pushed the bowel toward the patient's upper abdominal cavity through the laparoscope, then we marked the ureter which located at the bifurcation of the ILIACA vessel, opening the pelvic floor peritoneum on the left and right sides in order, then, we opened the peritoneum transversely along the surface of the bladder. After proper separation of the bladder, we pushed the bladder to the left side, a large cystic lesion can be seen on the pelvic floor. So, the clear liquid in the cyst can be extracted by a laparoscopic aspirator. In the process of separation, we found that the posterior wall of the sac wall was thick and the blood supply was abundant, so the wound surface oozed too much blood and relevant hemostatic measure were implemented. The mass contains multiple cysts with different contents. Some cysts with clear fluid while some cysts with chocolate-like fluid. We speculated that chocolate-like fluid may be caused by puncture bleeding. The whole separation process is operated according to the principle of tumor-free. The sac wall was resected completely and was sent for pathological examination. There were approximately 3,000 ml of blood loss during the procedure. The postoperative pathologic diagnosis confirmed the cystic lesion consistent with a müllerian duct cyst (Fig. 3).

Discussion And Conclusions

Both mesonephric duct (Wolffian) and paramesonephric (müllerian) ducts exist in early embryo coexist at 6 weeks of gestation and develop into the reproductive organ of males or female[3-5]. In the male embryo, anti-müllerian hormone(AMH)secreted by the testicles can cause the degeneration of the müllerian duct and prevent the differentiation of female genitalia at the 10th week of gestation[6-8]. If the AMH secreted from the Sertoli cells is insufficient or AMH can’t perform its function due to various reasons, that will result in müllerian duct regress incompletely, causing MDRs[9, 10]. MDRs is associated with abnormal development of the urinary system such as intersex disorders, hypospadias and cryptorchidism[11-13]. 90% of these cases discovered in the pediatric age[11-13]. However, if the MDRs is revealed late in life, the patient usually appeared with normal external genitalia while it does not deprive the ability of the patient’s fertility[12, 14]. The patient of our case is discovered to suffer MDRs at the age of 58, presenting with normal external genitalia and father two healthy daughters. This patient has two healthy daughters. Therefore, his ability of fertility is not affected by müllerian duct remnants. And this patient is already 58 years old. Given the two reasons, we didn't take the semen analysis of the patient.

More than half of the MDRs patients had no obviously clinical symptoms[15]. Other patients may suffer from multifarious complaints include frequent micturition, urgency, urinary retention, dysuria, postvoid dribbling, low urinary tract infection, infertility and voiding dysfunction[8, 13-15]. And It's also been documented that MDRs can cause urine retention[15-17]. Ultrasonography, computed tomography scan and magnetic resonance imaging of the abdomen and pelvic cavity can provide important and valuable information for the diagnosis of this disease[18]. Ultrasonography is a helpful method in ascertaining the nature and scoping of the mass, nevertheless, it is a procedure of operator-dependent[19]. In this case,

given the size of the mass, it's easy to find out this cystic lesion. CT scan and other imaging examination revealed a huge mass between the bladder and the rectum.

The major treatment method for symptomatic MDRs is surgical excision through laparoscope[3, 20, 21]. However, müllerian cysts can't be excised completely for the müllerian duct stick to the bladder wall in most cases[22]. But doctors need to perform the surgery and remove partial of the cyst. The aim of this kind of surgery is reduce the size of mass and relieve the symptoms caused by the MDRs. The laparoscope is a perfect facility for procedures because it can provide a perfect view and show the anatomical relationships between the organs clearly[23]. However, the procedure of separating the adhesions between organs can be difficult. That's because the cyst wall is stick to the surface of the bladder, prostate and pelvic floor muscle. Therefore, the process of separating the adhesion is time-consuming and prone to bleeding. The good news is that the patient recovered well after the operation and there are no reports in the literature that MDRs recurrent postoperatively[24]. After excision of müllerian duct, Aminsharifi et al., Hong et al. and Lima et al. reported no recurrence was found with 7 months, 3-56 months and 8-48 months follow-up in 2, 6 and 6 patients, respectively[20, 21, 25]. A three-month follow-up of the patient showed complete recovery of low back pain, besides, the image of the CT scan showed that the mass reduced visibly(the size of the mass is about 7×5×4cm) (Figure 4).

Laparoscopic excision is a perfect way for procedures need to be operated in restricted spaces. This method can provide a perfect view for operators and do minimally impair the patient compared to traditional procedures. Therefore, the patient can recover rapidly from this surgery.

Abbreviations

MDRs：Müllerian duct remnants, PSA：Prostate-specific antigen, AMH：Anti-müllerian hormone, CT：Computed tomography, MRI：Magnetic resonance imaging

Declarations

Ethics approval and consent to participate: The protocol was approved by the Ethics Committee of Beijing TongRen Hospital, Capital Medical University, Beijing, China.

Consent for publication: Written informed consent was obtained from the participants for publication of this article and any accompanying tables/images. A copy of the written consent is available for review by the Editor of this journal.

Availability of data and materials: The datasets used in the manuscript are available from the corresponding author.

Declaration of conflicting interest: There are no potential conflicts or relevant competing interests.

Funding: This study did not receive any funding.

Authors' contributions: WYH and XP made contributions to the acquisition of history, image and wrote the manuscript. LS carried out the pathology part interpretation and description. WW and PH performed the surgery, and reviewed the manuscript to give clinical opinions. LYX made supervision and helped reviewing the manuscript. The All the authors read and approved the final manuscript.

Acknowledgements: Not applicable.

References

1. Luo JH, Chen W, Sun JJ, Xie D, Mo JC, Zhou L, Lu J. Laparoscopic management of Mullerian duct remnants: four case reports and review of the literature. J Androl. 2008;29:638–42.
2. Aminsharifi A, Afsar F, Pakbaz S. Laparoscopic management of mullerian duct cysts in infants. J Pediatr Surg. 2011;46:1859–64.
3. Meng X, Liu J, Yu X, Wang S, Liu C, Ye Z. A giant Mullerian duct cyst in the perineum: a case report. Front Med. 2012;6:440–3.
4. Desautel MG, Stock J, Hanna MK. Mullerian duct remnants: surgical management and fertility issues. J Urol. 1999;162:1008–13;. discussion 1014.
5. GR C, SJ R, D I TK, LS JSMC. B: Development of the human female reproductive tract. Differ Res Biol Divers. 2018;103:46–65.
6. D I JS, GR MCAS. C, L B: Immunohistochemical expression analysis of the human fetal lower urogenital tract. Differ Res Biol Divers. 2018;103:100–19.
7. AL B. M P, SA M, P G: Emerging Roles of Anti-Müllerian Hormone in Hypothalamic-Pituitary Function. Neuroendocrinology. 2019;109:218–29.
8. M L, M M, N DS, G R, M L, T G, H L: **Robotic removal of Müllerian duct remnants in pediatric patients**: **our experience and a review of the literature**. *La Pediatria medica e chirurgica: Medical and surgical pediatrics* 2018, **40**:undefined.
9. RD M, EL YWBL, RR M. B: Osterix functions downstream of anti-Müllerian hormone signaling to regulate Müllerian duct regression. Proc Natl Acad Sci USA. 2018;115:8382–7.
10. dC SAPALGN, MC O-C, JY NJ. P, F X: Molecular mechanisms of hormone-mediated Müllerian duct regression: involvement of beta-catenin. Development. 2000;127:3349–60.
11. Ritchey ML, Benson RC, Kramer SA, Kelalis PP. Management of Müllerian Duct Remnants in the Male Patient. J Urol. 1988;140:795–9.
12. McDougall EM, Clayman RV, Bowles WT. Laparoscopic Excision of Müllerian Duct Remnant. J Urol. 1994;152:482–4.
13. Raicevic M, Saxena AK. Laparoscopic management of Mullerian duct remnants in the paediatric age: Evidence and outcome analysis. J Minim Access Surg. 2018;14:95–8.
14. Krstic ZD, Smoljanic Z, Micovic Z, Vukadinovic V, Sretenovic A, Varinac D. Surgical treatment of the Mullerian duct remnants. J Pediatr Surg. 2001;36:870–6.

15. Jaidane M, Hidoussi A, Slama A, Hmida W, Sorba NB, Mosbah F. An acute urinary retention in an old man caused by a giant Mullerian duct cyst: a case report. Cases J. 2009;2:203.
16. M H, R F, AJ K: **Mullerian Duct Cyst Causing Bladder Outlet Obstruction in a Patient with HNF-1β Gene Deletion**. *Current urology* 2016, 9:106–108.
17. NB MJAHASWH. S, F M: An acute urinary retention in an old man caused by a giant Müllerian duct cyst: a case report. Cases J. 2009;2:203.
18. Mueller GC, Hussain HK, Smith YR, Quint EH, Carlos RC, Johnson TD, DeLancey JO. Müllerian Duct Anomalies: Comparison of MRI Diagnosis and Clinical Diagnosis. Am J Roentgenol. 2007;189:1294–302.
19. JW HFC, dV SH. R R, R P, JL B, R vM: Prostate volume ultrasonography: the influence of transabdominal versus transrectal approach, device type and operator. European urology. 2004;46:352–6.
20. Hong YK, Onal B, Diamond DA, Retik AB, Cendron M, Nguyen HT. Robot-assisted laparoscopic excision of symptomatic retrovesical cysts in boys and young adults. J Urol. 2011;186:2372–8.
21. Lima M, Aquino A, Domini M, Ruggeri G, Libri M, Cimador M, Pelusi G. Laparoscopic removal of mullerian duct remnants in boys. J Urol. 2004;171:364–8.
22. Morgan RJ, Williams DI, Pryor JP. Müllerian Duct Remnants in the Male. Br J Urol. 1980;51:488–92.
23. KP P. WW H: Modified Open Laparoscopy Using a 5-mm Laparoscope. Obstetrics gynecology. 2016;127:535–8.
24. Coppens L, Bonnet P, Andrianne R, de Leval J. Adult mullerian duct or utricle cyst: clinical significance and therapeutic management of 65 cases. J Urol. 2002;167:1740–4.
25. F AA. A, S P: Laparoscopic management of müllerian duct cysts in infants. Journal of pediatric surgery. 2011;46:1859–64.

Figures

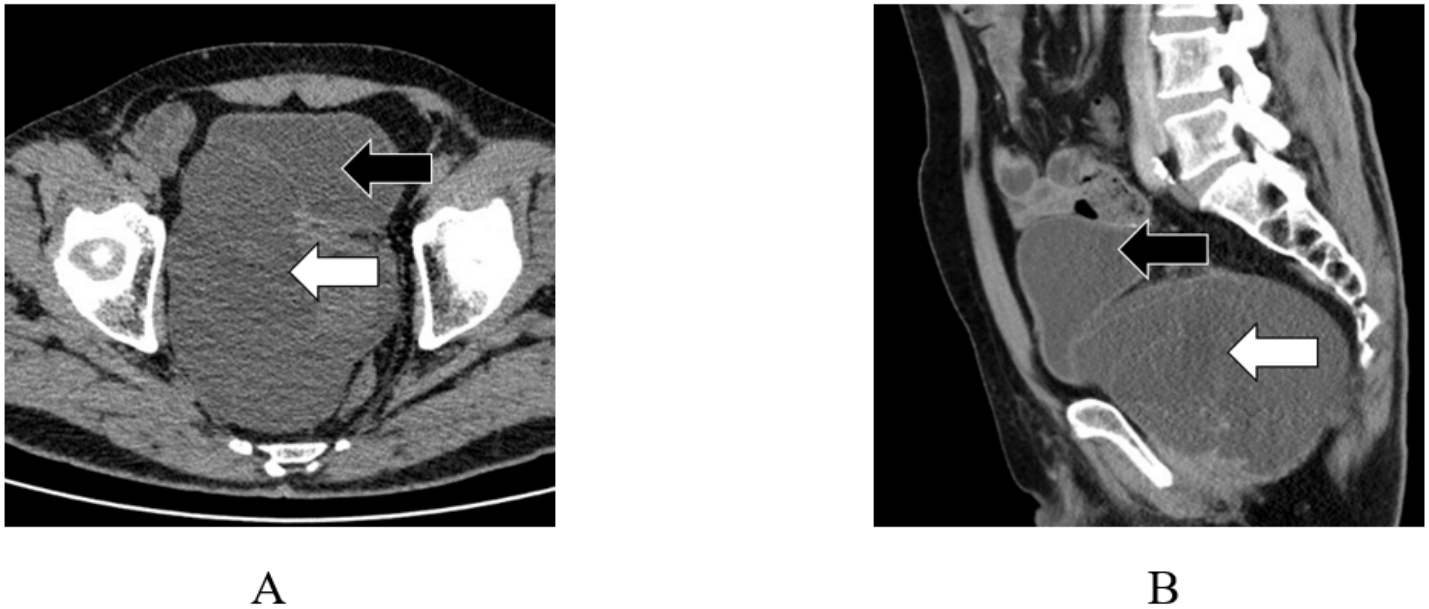

Figure 1

Transverse(A) and sagittal(B) CT scan images of the cyst. CT scan show a huge mass (white arrow) posterior to urinary bladder (black arrow). The urinary bladder was compressed by the lesion which located on the pelvic cavity.

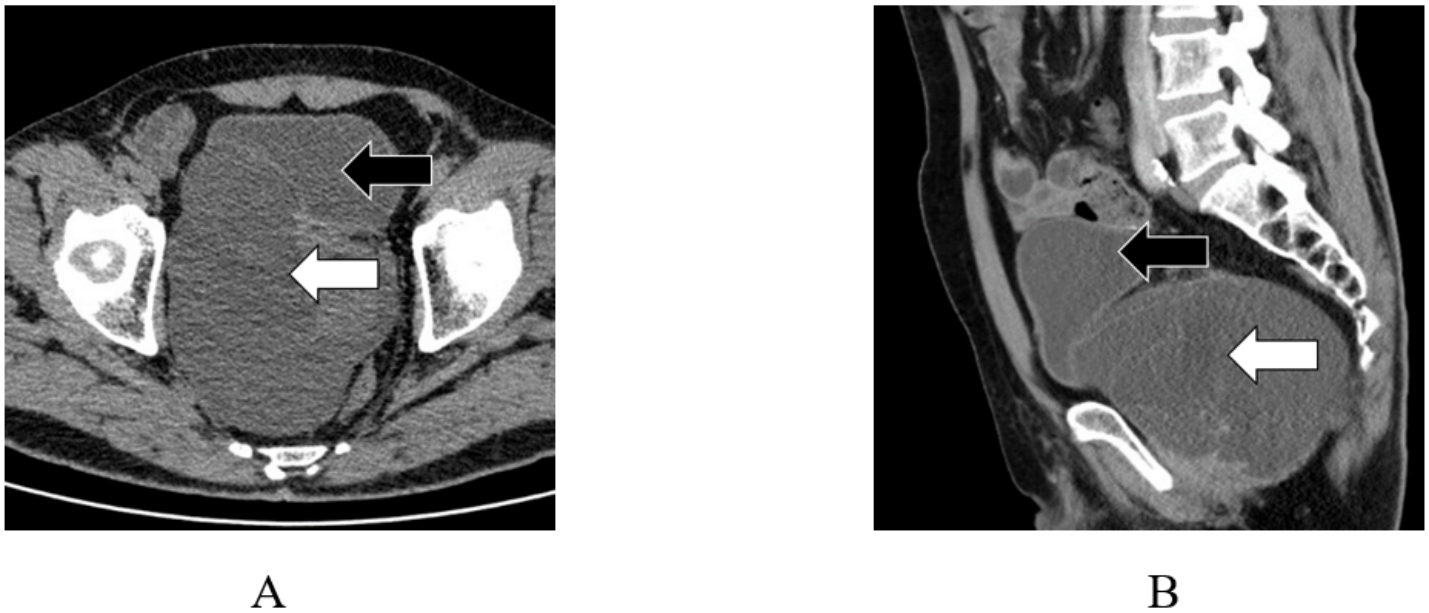

Figure 1

Transverse(A) and sagittal(B) CT scan images of the cyst. CT scan show a huge mass (white arrow) posterior to urinary bladder (black arrow). The urinary bladder was compressed by the lesion which located on the pelvic cavity.

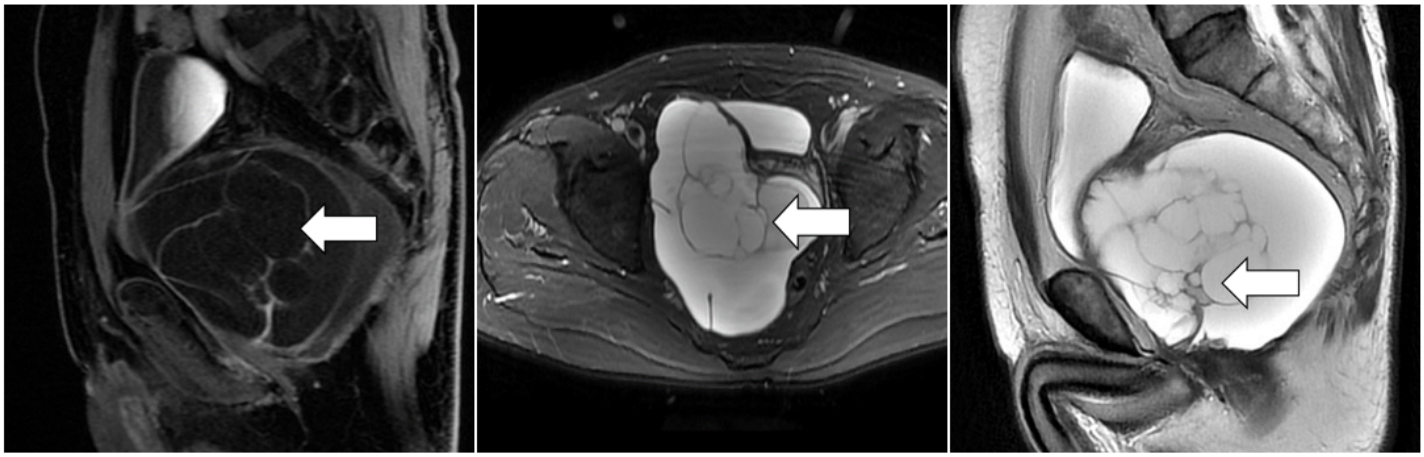

A B C

Figure 2

The MRI of the lesion. MRI show compartments in the mass (white arrow).

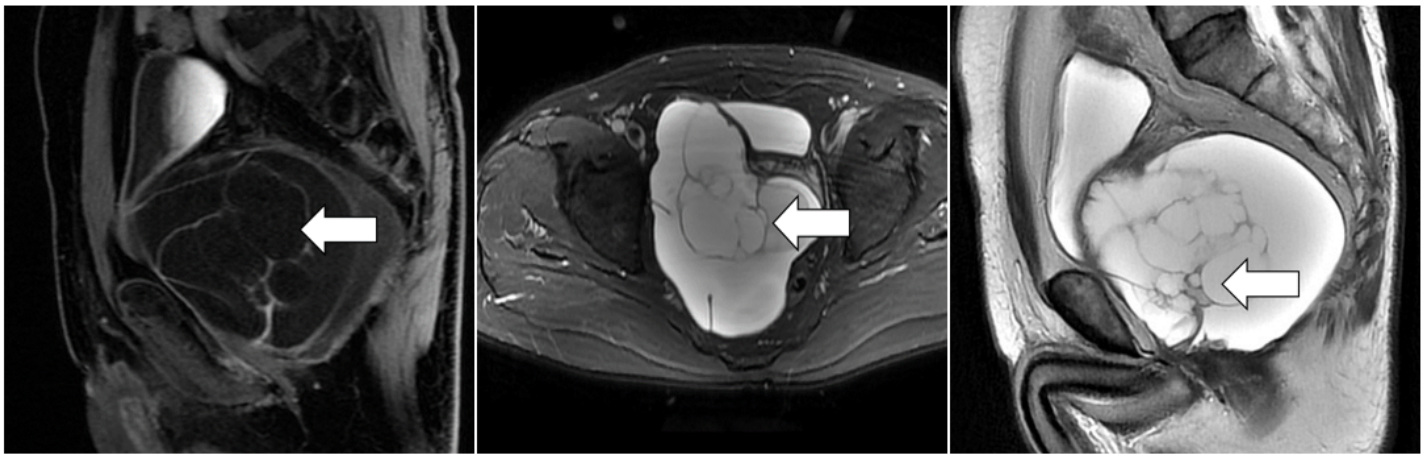

A B C

Figure 2

The MRI of the lesion. MRI show compartments in the mass (white arrow).

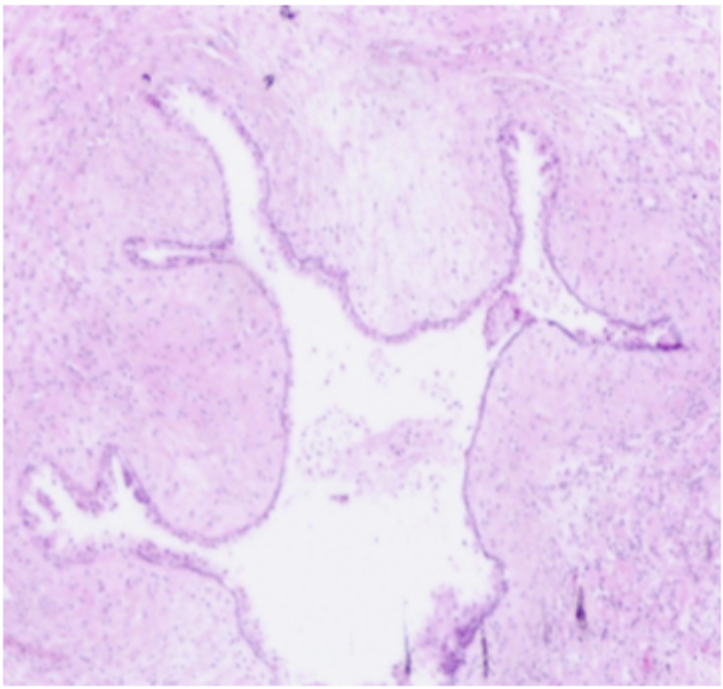

Figure 3

The pathological examination of the cyst. The biopsy of the cyst revealed columnar epithelial cells in the wall of the cyst, with some squamous cells in the view.

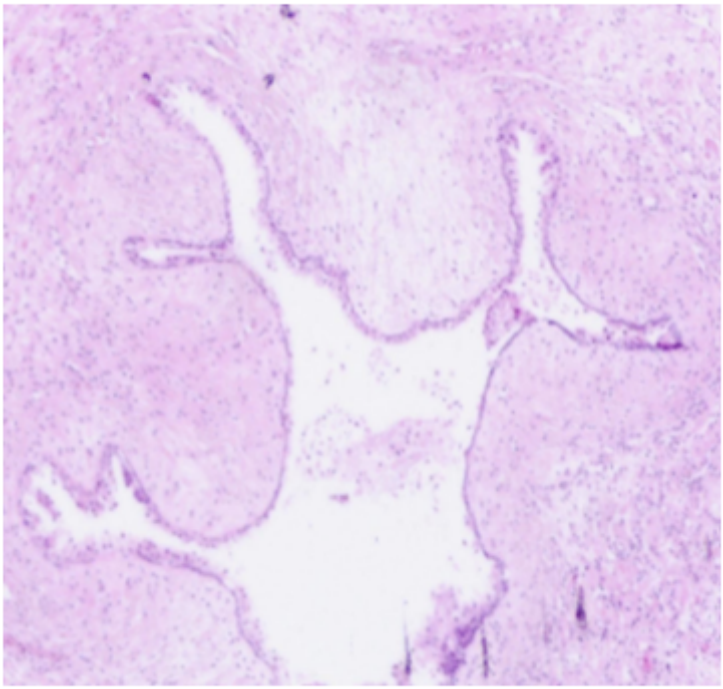

Figure 3

The pathological examination of the cyst. The biopsy of the cyst revealed columnar epithelial cells in the wall of the cyst, with some squamous cells in the view.

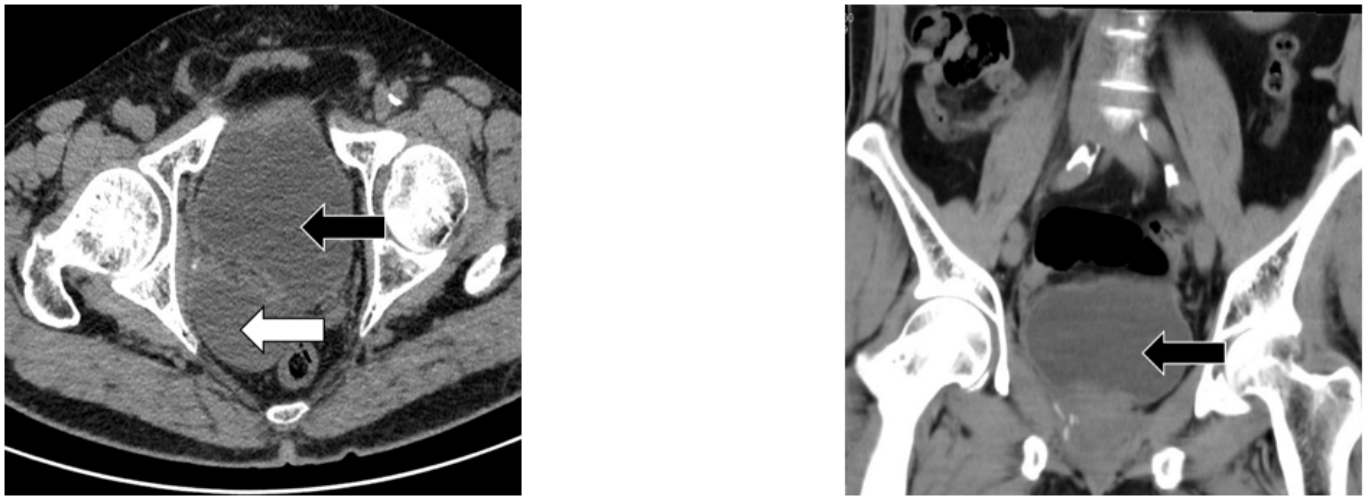

A B

Figure 4

Transverse(A) and coronal(B) planes of lower abdominal CT scan. The postoperatively three-month images show that the compression caused by the lesion was relieved, the shape and the position of the urinary bladder (black arrow) generally return to normal. There was fluid at the site of the original mass (white arrow). No müllerian structures were found at surgery performed three months later.

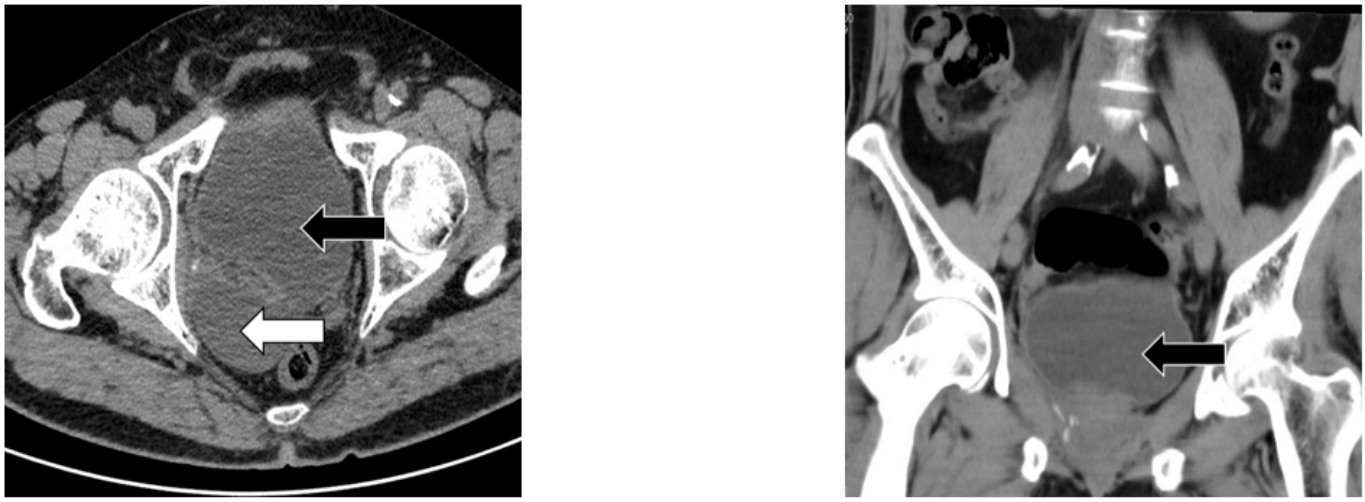

A B

Figure 4

Transverse(A) and coronal(B) planes of lower abdominal CT scan. The postoperatively three-month images show that the compression caused by the lesion was relieved, the shape and the position of the urinary bladder (black arrow) generally return to normal. There was fluid at the site of the original mass (white arrow). No müllerian structures were found at surgery performed three months later.