Cataract Progression Following Lens-Sparing Pars Plana Vitrectomy for Rhegmatogenous Retinal Detachment

Carlo Bellucci (carlo.bellucci89@gmail.com)
University of Parma
Lucia Benatti
University of Parma
Maurizio Rossi
University of Parma
Salvatore Antonio Tedesco
University of Parma
Arturo Carta
University of Parma
Giacomo Calzetti
University of Basel
Stefano Gandolfi
University of Parma
Paolo Mora
University of Parma

Research Article

Keywords: PPV, CES, cataract development, silicone oil tamponade, RRD, subcapsular forms

Posted Date: December 6th, 2021

DOI: https://doi.org/10.21203/rs.3.rs-1116359/v1

Abstract

Purpose: Lens-sparing pars plana vitrectomy (PPV) is often followed by cataract development. However, there have been few prospective studies evaluating the timing of cataract progression and potential associated factors.

Methods: This was an observational study conducted at the Ophthalmology Unit of the University Hospital of Parma (Parma, Italy). Patients presenting with rhegmatogenous retinal detachment (RRD), who underwent PPV with preservation of the lens, were examined according to a scheduled follow-up (3, 6 and 12 months after PPV) and then preoperatively when cataract extraction surgery (CES) was indicated, or at the end of the study follow-up period (May 2021). The primary outcome was the interval between PPV and CES indication (based on predefined refractive criteria).

Results: A total of 36 eyes of 36 patients (mean age: 52 ± 10 years) were included in the study. Nineteen eyes (53%) were indicated for CES a median of 14.5 months (IQR: 12.0–24.8) after PPV. The nuclear and posterior subcapsular forms of cataract progressed significantly starting at 6 months after PPV. Older age at the time of PPV, silicone oil tamponade and RRD without macular involvement were significantly and independently associated with an earlier indication for CES.

Conclusions: Patient age and the use of silicone oil tamponade must be taken into consideration when evaluating the risk of cataract development after PPV.

Introduction

In the phakic eye, pars plana vitrectomy (PPV) often results in cataract formation. [1, 2] The incidence of visually significant cataract development, referring to the nuclear sclerotic (N) and posterior subcapsular (PSC) forms, varies widely. [3, 4] Lens-sparing PPV is widely used in the management of phakic rhegmatogenous retinal detachment (RRD). A recent study reported similar results, in terms of the retinal reattachment rate and recovery of vision, after PPV with preservation of the crystalline lens or combined with phacoemulsification. [5] Due to the potential for cataract progression and difficulty of performing phacoemulsification in vitrectomized eyes, identifying potentially general and technical prognostic factors is important to guide the treatment approach when PPV is required. These essentially refers to: the patient age; the risk of postoperative refractive errors, especially in macula-off cases; the iatrogenic anisometropia in myopic subjects; the removal of a largely healthy organ in cases of no/mild cataract with residual accommodative function.

The present study analysed a cohort of patients prospectively followed up after lens-sparing PPV for RRD. We used objective criteria to determine when cataract extraction should be indicated.

Patients And Methods

This prospective study was conducted at the Ophthalmology Unit of the University Hospital of Parma (Parma, Italy) and included patients undergoing PPV for RRD with preservation of the lens. The cohort also included a subgroup of patients who had participated in a previous trial. [5] The study was approved by the Area Vasta Emilia Nord Ethics Committee (protocol numbers 569/2018 and 7489/2019) and adhered to the tenets of the Declaration of Helsinki. Written informed consent was obtained from all participants. The inclusion criteria were an age of 18–65 years and prior lens-sparing PPV for RRD, with a lens opacity not exceeding the first grade for each category of the Lens Opacities Classification System III (LOCS III). [6] The exclusion criteria were any intraoperative complication involving the lens during PPV and postoperative complications, such as endophthalmitis or recurrence of RRD. In addition, diabetic retinopathy, inherited or age-related maculopathy or optic nerve disease.

The participants were examined 3, 6 and 12 months after PPV, and then on patient request due to perceived visual impairment or at the end of the follow-up period (May 2021). Each evaluation included assessment of the best-corrected visual acuity (BCVA) using Early Treatment for Diabetic Retinopathy Study (ETDRS) charts, intraocular pressure (IOP; by applanation tonometry), slit lamp examination under mydriasis (for lens opacity grading according to the LOCS III), and fundoscopy.

Follow-up ended when cataract extraction surgery (CES), performed by two surgeons (PM and ST), was clinically indicated. CES was indicated when the BCVA decreased by ≥ 15 letters on the ETDRS charts relative to the number at the 3-month follow-up visit, or when the spherical equivalent (SE) varied by ± 2.5 D compared to that measured 3 months after PPV. The primary study outcome was the time between PPV and the indication for CES. Secondary outcomes were the grade of cataract that developed during follow-up according to the LOCS III, and any correlations of CES with gender, age at the time of PPV, the calliper used (23–25-gauge), type of tamponade, macular status (on/off), axial length (AL) of the eye (evaluated on a flattened retina using the IOL Master instrument; Carl Zeiss Meditec) and the median IOP (of all values measured during follow-up). CES was performed using a standard phacoemulsification technique.

Statistical analysis

The normality of the data distribution was checked using the Kolmogorov–Smirnov test. The mean and standard deviation (SD) were calculated for continuous variables with a normal distribution, and the median with interquartile range (IQR) for continuous variables with a non-normal distribution. The Friedman test was used for analysing ordinal variables. Factors potentially related to the indication for CES were examined by Kaplan–Meier survival analysis and the log-rank test. The Cox proportional hazards model was used to determine the development of CES indication, according to the above-mentioned refractive criteria (i.e., the study event). Multivariable analysis of prognostic factors was also performed. All variables considered possibly relevant on a clinical basis were included in the multivariate models. The significance threshold was set at $P < 0.05$. All analyses were performed using SPSS software (version 27.0; SPSS Inc.).

Results

Thirty-six eyes of 36 patients (24 males, 12 females) were included in the study. Patient demographics and baseline ocular findings are presented in Table 1. Tamponade was performed after PPV with octafluoropropane (C_3F_8, 18%) in 33 eyes, and with polydimethylsiloxane (PDMS-1000) in 3 eyes. Nineteen eyes (53%) underwent CES. The median time from PPV to CES indication was 14.5 months (IQR: 12.0–24.8 months) and the mean preoperative BCVA was 0.62 ± 0.29 logMAR. The distribution of events over the follow-up period is shown in Figure 1. As complications of subsequent phacoemulsification surgeries, one case of capsule rupture and one of sectorial zonular dialysis occurred. In nine among the operated eyes (42%), including those with intraoperative complications, the surgeons observed wide fluctuations of the anterior chamber depth, which led to marked lowering of the infusion bottle and injection of larger amounts of viscoelastic material into the eye.

Progression of the various types of cataract, according to the LOCS III, is shown in Figure 2. Relative to the pre-PPV levels, cataract progressed significantly starting from 6 months after PPV for the N and PSC forms ($P < 0.001$ and $P < 0.005$, respectively). For these two types, a further significant increase was noted between 6 months after PPV and the end of the follow-up period ($P < 0.001$ and $P = 0.010$, respectively). No such variation was observed for the cortical (C) form over the follow-up period (Table 2).

In multivariate analysis, three prognostic factors tested significant: a) patient age at the time of PPV ($P = 0.002$); b) tamponade ($P = 0.013$); c) macular involvement by the RRD ($P = 0.043$). In particular, the hazard ratio for CES indication increased 1.173 times with every additional year of age; PDMS and RRD without macular involvement (macula-ON) were related to a significantly earlier onset of lens opacification, as an indication for CES.

Discussion

The present study prospectively analysed cataract progression, using the LOCS III grading system, in a cohort of eyes treated with PPV for RRD. The potential influence of various demographic, clinical and surgical characteristics was also evaluated. Factors related to cataract progression after vitrectomy have been extensively discussed in the literature. To date, most studies have been retrospective, including large samples but with low homogeneity in terms of the study populations, timing of follow-up visits, surgeons and investigators. [7, 8] The present study was unique in calculating the time to CES indication following PPV. The novelty is chiefly methodological, consisting in the “ex ante” definition of the level of lens opacification and/or refractive variation required to indicate CES. This way to collect data on the parameters possibly influencing cataract development ensures minimal biases of correlation. The median time between PPV and CES (14.5 months) was similar to that in a prospective series, [9] but longer than the means reported in other studies examining similar characteristics, such as small-gauge PPV or RRD treated with gas tamponade. [7, 10, 11] Regarding the type of cataract, the N form progressed significantly according to the LOCS III starting from 6 months after PPV, as did the PSC type. In contrast, the C type showed no significant progression during the whole follow-up period, in line with previous

observations. [10, 11, 12, 13] Progression of the N and PSC forms supported the concept that noxa mainly affected the posterior surface of the lens. These forms may result from increased exposure to oxygen via the retinal vasculature due to an absence of vitreous gel, prolonged liquid flow from the pars plana and the use of steroids as vitreal stainer during vitrectomy. [14, 15] Unlike the N and SCP forms, C cataracts are associated with extensive disruption of cell structure beginning near the equator of the lens. [16]

Three parameters in this study were significantly correlated with cataract progression: patient age, the use of PDMS tamponade and macula-on RRD.

In older patients (at the time of PPV), the CES indication was earlier, with the hazard ratio approximately doubling for every 5-year increase in age. This supports the preference for lens-sparing PPV to treat RRD in younger patients, considering also the increased technical difficulty of phacoemulsification in vitrectomized eyes. Certainly, the lens-sparing technique implies some differences as compared to the PPV combined with cataract extraction (i.e. phacovitrectomy, PCV). These essentially concern the enhanced retinal visualization during posterior segment surgery; the better access to the vitreous base allowing for a more extensive vitrectomy and endolaser treatment (thereby ensuring more extensive gas filling and better tamponade of retinal breaks) when the lens removal occurs before the PPV. However, a recent prospective trial reported that the preservation of the crystalline lens at the time of PPV ensured similar outcomes to those obtained with PCV, in terms of the retinal reattachment rate and safety during postoperative management.[5]

The correlation between cataract development and presence of PDMS identified in the present study was in line with the literature. [7, 11] The statistically significant results obtained in the small number of eyes with PDMS in this study confirms the appropriateness of the design.

The apparently more rapid progression of cataract when the macula is not detached is an original finding whose mechanism remains quite difficult to assess. We think this issue in particular needs a confirmation through the enlargement of the sample size, which represents the major limitation of this study. However, the study benefitted from a highly homogeneous cohort in terms of: pre-surgery disease, the technical approach and post-PPV follow-up duration. Through prospective observation, visual and refractive conditions that indicate CES were clearly identified and located in time.

Declarations

Acknowledgements: The English in this document has been checked by at least two professional editors, both native speakers of English. For a certificate, please see:
http://www.textcheck.com/certificate/i3GGz6

Authors' contribution: all authors contributed to the study conception and design. Material preparation and data collection was performed by C.B., L.B., A.C. and P.M., statistical analysis was performed by M.R..

Surgery was performed by P.M. and S.A.T. S.G. was a major contributor in writing and revising the manuscript. All authors read and approved the final manuscript

Availability of data and material: all data and material are available from the corresponding author.

Competing interest and Funding: the authors declare that they have no conflict of interest and that they have not received any funding for this article.

References

1. de Bustros, S. *et al.* Nuclear sclerosis after vitrectomy for idiopathic epiretinal membranes. *Am J Ophthalmol*, **105**, 160–4 (1988).
2. Melberg, N. S. & Thomas, M. A. Nuclear sclerotic cataract after vitrectomy in patients younger than 50 years of age. *Ophthalmology*, **102**, 1466–71 (1995).
3. Novak, M. A., Rice, T. A., Michels, R. G. & Auer, C. The crystalline lens after vitrectomy for diabetic retinopathy. *Ophthalmology*, **91**, 1480–4 (1984).
4. Hutton, W. L., Pesicka, G. A. & Fuller, D. G. Cataract extraction in the diabetic eye after vitrectomy. *Am J Ophthalmol*, **104**, 1–4 (1987).
5. Mora, P. *et al.* Parsplana vitrectomy alone versus parsplana vitrectomy combined with phacoemulsification for the treatment of rhegmatogenous retinal detachment: a randomized study. *BMC Ophthalmol*, **21**, 196 (2021).
6. Chylack, L. T. Jr *et al.* The Lens Opacities Classification System III. The Longitudinal Study of Cataract Study Group. *Arch Ophthalmol*, **111**, 831–6 (1993).
7. Soliman, M. K. *et al.* A Database Study of Visual Outcomes and Intraoperative Complications of Postvitrectomy Cataract Surgery. *Ophthalmology*, **125**, 1683–1691 (2018).
8. Do, D. V., Gichuhi, S., Vedula, S. S. & Hawkins, B. S. Surgery for post-vitrectomy cataract. *Cochrane Database Syst Rev*. **12**, CD006366 (2013). Update in: *Cochrane Database Syst Rev*. **10** (2018)
9. Ahfat, F. G., Yuen, C. H. & Groenewald, C. P. Phacoemulsification and intraocular lens implantation following pars plana vitrectomy: a prospective study.. *Eye (Lond)*, **17**, 16–20 (2003).
10. Feng, H. & Adelman, R. A. Cataract formation following vitreoretinal procedures. *Clin Ophthalmol*, **8**, 1957–65 (2014).
11. Titiyal, J. S., Agarwal, E., Angmo, D., Sharma, N. & Kumar, A. Comparative evaluation of outcomes of phacoemulsification in vitrectomized eyes: silicone oil versus air/gas group. *Int Ophthalmol*, **37**, 565–574 (2017).
12. Kataria, A. S. & Thompson, J. T. Cataract Formation and Progression in Patients Less Than 50 Years of Age after Vitrectomy. *Ophthalmol Retina*, **1**, 149–153 (2017).
13. Reibaldi, M. *et al.* Transconjunctival nonvitrectomizing vitreous surgery versus 25-gauge vitrectomy in patients with epiretinal membrane: a prospective randomized study. *Retina*, **35**, 873–9 (2015).

14. Petermeier, K., Szurman, P., Bartz-Schmidt, U. K. & Gekeler, F. Pathophysiologie der Katarakt-Entwicklung nach Vitrektomie [Pathophysiology of cataract formation after vitrectomy]. *Klin Monbl Augenheilkd*, **227**, 175–80 (2010). German.
15. Holekamp, N. M., Shui, Y. B. & Beebe, D. C. Vitrectomy surgery increases oxygen exposure to the lens: a possible mechanism for nuclear cataract formation. *Am J Ophthalmol*, **139**, 302–10 (2005).
16. Beebe, D. C., Holekamp, N. M. & Shui, Y. B. Oxidative damage and the prevention of age-related cataracts. *Ophthalmic Res*, **44**, 155–65 (2010).

Tables

TABLE 1: Patients' demographics and ocular findings at baseline.

M/F	24/12
AGE (years)	51.8 ± 9.5
EYE (RE/LE)	20/16
AL (mm)	26.09 ± 2.09
IOP AVERAGE (mmHg)	16 ± 2.8
MACULAR INVOLVEMENT (ON/OFF)	15/21
GAUGE (23/25)	28/8
PPV DURATION (minutes)	79 ± 24.5
END FOLLOW UP (months)	20 ± 13

M=males; F= females, AL= axial length; IOP= intraocular pressure; PPV= pars plana vitrectomy.

TABLE 2: Cataract development for each LOCS III type over the main follow up timepoints.

	pre-PPv vs 1 Month	**pre-PPv vs 3 months**	**pre-PPv vs 6 months**	**pre-PPv vs end fu**	**6 months vs end fu**
N	0.320	0.083	< 0.000*	< 0.000*	< 0.000*
C	0.320	0.324	0.083	0.056	0.373
P	0.080	0.018	0.005*	<0.000*	0.010

* = statistical significance achieved; PPV= pars plana vitrectomy; FU= follow up; N= nuclear cataract; C= cortical cataract; P= posterior subcapsular cataract.

Figures

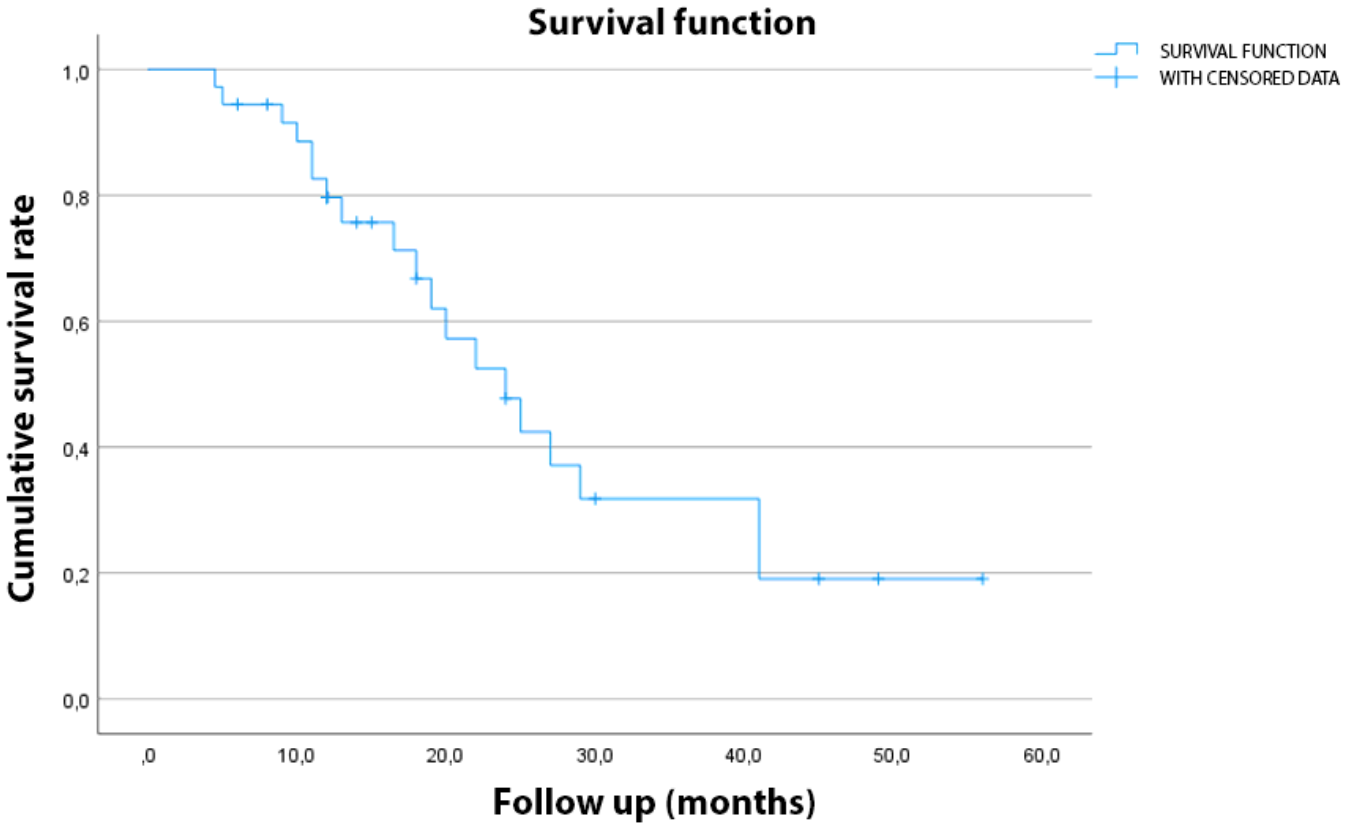

Figure 1

Timing of events, in terms of indication for cataract extraction surgery, over the follow-up period.

Figure 2

Progression of the various types of cataract according to the LOCS III grading system.