Clinical Outcomes in Soft Tissue Repair Surgery With and Without Femoral Derotation Osteotomy for Patellar Dislocation: A Retrospective Study

Chongyi Fan
Hebei Medical University Third Affiliated Hospital
Guangmin Yang
Hebei Medical University Third Affiliated Hospital
Yingzhen Niu
Hebei Medical University Third Affiliated Hospital
Yirong Xu
Hebei Medical University Third Affiliated Hospital
Ming Li
Hebei Medical University Third Affiliated Hospital
Xunkai Feng
Hebei Medical University Third Affiliated Hospital
Fei Wang (doctorwf@yeah.net)
Third Hospital of Hebei Medical University, Shijiazhuang 050051, Hebei, China

---

Research article

Keywords: patellar dislocation, Medial patellofemoral ligament, femoral derotation osteotomy, Femoral anteversion

Posted Date: November 24th, 2020

DOI: https://doi.org/10.21203/rs.3.rs-112206/v1

Abstract

Background: The purpose of our study was to report the clinical outcomes of isolated soft tissue repair or combined femoral derotation osteotomy (DFO) in patients with patellar dislocation with increased femoral anteversion angle (FAA).

Methods: A total of 63 patients with patellar dislocation were retrospectively reviewed in this study. 33 patients received isolated soft tissue repair (group 1) and 30 patients were a combination with a femoral deroration osteotomy (group 2). CT were used to assess the correction of the femoral anteversion angle, the tibia tuberosity-trochlear groove (TT-TG) distance, patellar tilt (PTA), and the congruence angle (CA) following the two surgical programs. Subjective scores, such as Kujala, International Knee Documentation Committee (IKDC), Lysholm ,Tegner, and visual analogue scale (VAS) scores, were used to evaluate knee function.

Results: In group 2, the mean of the FAA was corrected to15.76 ±2.02° postoperatively compared with 29.16± 2.87° preoperatively (P < 0.001). The TT-TG distance was decreased from 19.03 ±2.52 mm before surgery to 17.80 ±2.24 mm after surgery (< 0.001). Besides, Postoperative PTA and CA were corrected in both groups (P < 0.001). Kujala, IKDC, Lysholm and VAS scores of between groups were significantly improved after operation (P < 0.001). Furthermore, Compared with the isolated soft tissue repair surgery, the combined surgery achieve better postoperative outcomes in Kujala, (IKDC), Lysholm and VAS scores (P < 0.001).

Conclusion: Although DFO can be used in combination with DFO to achieve better results, it should also be tailored to the individual and reduce patient suffering.

Introduction

Patella instability is an important factor affecting the athletic ability of young people, and this problem is now of increasing concern [1,2]. The etiology, diagnosis, and surgical treatment of patellar dislocation have improved in recent years, but there are still many uncertain anatomical factors that influence the outcome of treatment after patellar dislocation.

Many surgical techniques have been described to address patellar instability. Some of these techniques involve soft tissue, while others mainly correct bone malformation [3]. The objective of surgery is to stabilize the patella, restore normal kinematics, and optimize load transfer through the joint in the event of failure of conservative treatment.

Anatomical factors now recognized as contributing factors to patellar dislocation include 1. trochlear dysplasia 2. greater distance TT-TG 3. soft tissue incompetence 4. patella Alta (Caton–Deschamps index higher than or equal to 1.2). In general, the etiology of patellar instability is multifactorial [4].

In recent years, it has been found that the internal rotation of the distal femur is the main cause of poor rotation alignment of the patellofemoral joint, which may affect the trajectory of the patella in the trochlear[5]. Diederichs et al and Francois et al. found in patients with a history of patellar dislocation that a greater femoral anteversion and greater femoral internal rotation have been shown to have a negative impact on the clinical outcome of patellar stabilization surgery[5,6].Therefore, in recent years, for patients with patellar dislocation with greater femoral anteversion(FA), some doctors have performed femoral derotation osteotomy(DFO) to correct the alignment and achieved good therapeutic effect[7,8,9]. However, since this operation requires the patient's femur to be broken and then rotated for reconstruction, it leads to greater surgical trauma and may have more complications, such as prolonged bone healing time [10,11]. At present, there is no clear consensus on the need for surgical correction of the torsion threshold. This operation is mostly based on the personal preference of the operator, while the medium and long-term efficacy is unknown, further follow-up, and study by peers is required [12].

The medial patellofemoral ligament (MPFL) is the main passive restraint of lateral patellar force during early flexion to prevent lateral patellar dislocation [13]. The MPFL reconstruction(MPFLR) has been proved to have the effect of restoring stability, which has attracted more and more attention in recent years[14,15].MPFLR is the gold standard treatment for patellar dislocation, which can be used alone or in combination with tibial tubercle transfer, trochlear plasty, or derotational femoral osteotomy[16]. Similarly, our previous study reported that medial retinaculum plasty (MRP) can achieve the similar efficacy as MPFLR during short term follow-up[17], and can also be used as a reliable soft tissue repair surgery to stabilize patella trajectory. Although many recent reports have confirmed that patella dislocation with increased FAA has a negative effect on the outcome of soft tissue repair surgery, in order to deal with this situation, the application of DFO in combination is more effective. But the obvious advantages of a joint DFO remain to be explored.

The purpose of this study is to investigate the clinical outcome after soft tissue repair surgery (MPFLR or MRP) as an isolated procedure or in association with DFO surgery in patients with increased femoral anteversion. We hypothesized that the clinical outcome of soft tissue surgery combined with DFO is superior to that of soft tissue repair surgery alone. To date, there is limited evidence for clinical outcomes between the two surgical regimens. No studies have examined the difference in clinical outcomes between patients with an isolated soft tissue repair surgery [MPFLR or MRP] (group 1) versus patients with a concomitant operation [MPFLR or MRP + DFO (group 2).

Materials And Methods

Patients

From January 2015 to March 2019, 106 patients with patellar dislocation in the Third Hospital of Hebei Medical University were retrospectively reviewed. All patients had a history of patellar dislocation. Patients who underwent isolated soft tissue repair surgery (MRP or MPFLR) to restore patella stability were defined as group 1. Patients who underwent soft tissue repair surgery combined with DFO (DFO +

MRP or DFO + MPFLR) to correct osseous and soft tissue abnormalities were defined as group 2. This study and detailed surgical procedures were approved by the ethical committee of the hospital.

Patient selection was based on the following inclusion criteria: (i) patellar dislocation with Dejour type A or B trochlear dysplasia; (ii) femoral anteversion angle (FAA) > 25°; (iii) failure of non-operative treatments. The exclusion criteria were: (i) body mass index (BMI) > 30 kg/m2; (ii) severe osteoarthritis of patellofemoral joint; (iii) the femoral epiphyseal plate is not closed; (iv) there was a history of hip and knee surgery and trauma; and (v) Dejour type C or D trochlear dysplasia. 43 patients were excluded according to the following exclusion criteria: body mass index (BMI) > 30 kg/m2(5 patients); severe osteoarthritis of patellofemoral joint (4 patients); The femoral epiphyseal plate is not closed (18 patients); there was a history of hip and knee surgery and trauma (12 patients); Dejour type C or D trochlear dysplasia(4 patients). (Figure.1)

A totally of 63 patients with recurrent patellar dislocation were retrospectively reviewed in this study. 33 patients underwent isolated soft tissue repair surgery (MRP 20 cases, MPFLR, 13 cases). The average follow-up time was 21.1 ± 7.4 months (range from 12 to 35). 30 patients underwent soft tissue repair combined with DFO (DFO + MRP 20 cases, DFO + MPFLR 10 cases). The average follow-up time was 23.9 ± 6.8 months (range from 13 to 35). The demographic characteristics of the two groups were shown in Table 1.

Surgical Technique

All operations were performed by the same group. The patient was anesthetized in a supine position. Attach a tourniquet to the proximal thigh, set at 280 mmHg. The sterile operation area was prepared with iodine (2%) and medical alcohol (70%).

Osteotomy and Reconstruction

Two Kirschner wires were inserted into the supracondylar osteotomy line parallel to the knee joint line under fluoroscopy during the operation. A schematic of the DFO is shown in Figure.2. Two Kirschner pins were inserted on both sides of the osteotomy line to mark the degree of rotation. The femoral shaft was transversely cut with a pendulum saw and a bone chisel. According to the preoperative evaluation, the distal femur was rotated outward and the rotation direction of the patellofemoral joint was adjusted. The two terminals of the transverse femoral shat were temporarily fixed by a Kirschner wire obliquely penetrating the femoral shaft. Fluoroscopy was performed to ensure the reduction of the femoral shaft. A lateral femoral plate was then placed to ensure the fixation of the femoral shaft (Figure.3) [11,18].

Medial Retinaculum Plasty

A longitudinal incision was made along the medial edge of the patella to separate the vastus medialis and medial retinaculum from the patella, and a transverse incision along the junction of the vastus medialis oblique and the medial patellar retinaculum to the medial femoral condyle. The separated medial retinaculum (including the MPFL) was proximally and laterally sutured near the upper pole of the

patella temporarily. The vastus medialis was pulled distally and laterally to the medial edge of the patella and overlapped on the medial retinaculum with temporary fixation. The patella activity was evaluated by hand and the track of the patella was observed when the knee joint was fully extended and flexed. Finally, the overlapping tissues were sutured together with a No.1 PDS suture (Ethicon, Somerville, NJ)[17]. A schematic of the MRP is shown in Figure.4

Medial Patellofemoral Ligament Reconstruction.

The MPFL was reconstructed using a semitendinosus tendon autograft. The femoral tunnel was positioned under intraoperative fluoroscopy using the method described by Ma LF et al [17]. The femoral tunnel was positioned under intraoperative fluoroscopy. The free end of the graft was pulled into the femoral tunnel and fixed with 7-millimeter absorbable screws. 2 double-loaded suture anchors were inserted into the medial edge of the patella and were placed into the proximal one-third and equator of the patella, respectively. The two free end grafts were pulled from the medial femoral epicondyle to the medial edge of the patella through the subcutaneous fascia layer.

Postoperative rehabilitation program and follow-up

A restrictive lower limb brace was used immediately after surgery. Postoperatively, partial weight-bearing using crutches was allowed. Straight leg-raise exercises and active and passive flexion and extension exercises are recommended in the hospital. Partial weight-bearing exercises were recommended and gradually increased at 6 weeks after the surgery. After 12 weeks, patients were advised to stop using crutches and resume normal daily activities. For patients combined with DFO, gentle exercise is recommended based on the healing of the osteotomy line. The lower extremities were evaluated preoperatively and postoperatively in detail by radiology, including weight-bearing X-rays and CT scans. A visual analog scale(VAS) was used to evaluate postoperative pain relief. Subjective function score [including Tegner sports score, Kujala score, Lysholm score, and International Knee Documentation Committee score (IKDC)] was used to evaluate the improvement of knee joint function [19,20]. In the final follow-up, clinical evaluation was collected and compared with preoperative evaluation. At the same time, the results of patients satisfaction were divided into satisfied, partially satisfied and unsatisfied.

CT measurements

All subjects were examined with axial CT (Somatom Sensation, Siemens Medical Solutions, Erlangen, Germany) on bilaterally knees the knee in or near full extension. All measurements were performed on the PACS (Picture Archiving and Communications System; General Electrics, Chicago, IL) using a mouse cursor with automated distance or angle calculation,and 4values (Figure.5), including FAA, patella tilt angle(PTA), congruence angle (CA), tibia tuberosity-trochlear groove distance (TT-TG), were measured both in two groups preoperative and postoperative.

Statistical Analysis

All analyses were performed using SPSS software (Version 21.0, IL, USA). The radiological variables and clinical scores are shown as mean and SD values. A paired student T-test was used to analyze the significance of preoperative and postoperative radiological variables and clinical scores of the two surgical methods. An Independent t-test was used to analyze the significance of radiological variables and clinical scores between the two surgical regimens. All measurements were made by a single physician. A P-value of less than 0.05 was considered statistically significant.

Results

Surgery and Complications

None of the patients had incision infection or related nerve injury. The dislocation of the patella did not recur at the last follow-up. In the group 1, Two patients (2 in the MPFLR) had a limited knee flexion 2 weeks after surgery. However, after 8 to 10 weeks, muscle strength was recovered and all symptoms disappeared. In group 2, Two patients (DFO + MRP) had occasional clicking of the knee joint during flexion, and no pain or limitation was found during follow-up. 5 patients ((2 in the DFO + MRP, 3 in the DFO + MPFLR) had a limited knee flexion 8 weeks after surgery. We assisted the patients with active functional exercise, such as passive knee flexion and extension. During the treatment, the patients were given NSAIDs to relieve the pain symptoms of the patients, and the range of motion of the knee joints was significantly improved after 2 weeks of treatment.

Radiographic Outcomes

In group 1, the average PTA decreased from 31.36 ± 4.68°preoperatively to 15.78 ± 1.47° postoperatively($P < 0.001$).The average CA decreased from 38.51 ± 4.59 ° preoperatively to 17.06 ± 2.30 ° postoperatively ($P < 0.001$). Postoperative PTA and CA was significantly improved in the surgical program.

In group 2, The average FAA decreased from 29.16 ± 2.87° preoperatively to 15.76 ± 2.02° postoperatively. Compared with preoperatively, the FAA was significantly improved after combined operations ($P < 0.001$), and the risk of patella dislocation caused by abnormal torsion of the lower limb line was reduced. The average TT-TG distance decreased from 19.03 ± 2.52 mm preoperatively to 17.80 ± 2.24 mm postoperatively. Compared with preoperatively, the postoperative average TT-TG was corrected by 1.23 mm. There was a significant improvement ($P < 0.001$). the average PTA decreased from 30.96 ± 4.39° preoperatively to 14.40 ± 1.89° postoperatively ($P < 0.001$) and CA decreased from 37.96 ± 5.22 ° preoperatively to 15.43 ± 2.19 ° postoperatively. Postoperative PTA and CA was significantly improved in the surgical program.(Table 2).

There was a statistically significant difference between the two groups postoperatively ($P < 0.001$). (Table 4).(Figure.6)

Clinical Outcomes

In terms of clinical outcomes, postoperative knee pain and function were significantly improved in patients with both surgical programs. (Table 3).

In the group 1, the VAS score decreased from 4.00 ± 1.08 before the operation to 2.39 ± 0.86 after the operation (P < 0.001). The mean Kujala score was significantly increased from 61.45 ± 9.15 preoperatively to 77.09 ± 3.94 postoperatively (P < 0.001). The mean IKDC score was significantly increased from 61.18 ± 7.17 before surgery to 75.03 ± 4.56 after surgery (P < 0.001). The mean Lysholm score was significantly increased from 59.96 ± 6.94 preoperatively to 73.69 ± 5.38 postoperatively (P < 0.001). No significant difference in the Tegner score (3.93 ± 1.17 vs 4.09 ± 0.94) was found before and after the surgery. The results of patient satisfaction were as follows: 23 (70%) patients were satisfied results, 6 (18%) were partially satisfied, and 4(12%) was dissatisfied at the final follow-up.

In the group 2, the VAS score decreased from 3.77 ± 1.25 before surgery to 2.43 ± 1.07 after surgery (P < 0.001). The average Kujala score was significantly increased from 63.57 ± 8.94 preoperatively to 82.40 ± 5.60 postoperatively (P < 0.001). The mean IKDC score was significantly increased from 62.76 ± 6.91 preoperatively to 81.20 ± 6.27 postoperatively (P < 0.001). The mean Lysholm score was significantly increased from 62.20 ± 5.73 preoperatively to 79.26 ± 6.61 postoperatively (P < 0.001). No significant difference in the Tegner Score (4.10 ± 1.37 vs 4.16 ± 1.26) was found before and after the surgery. The results of patient satisfaction were as follows: 27 (90%) patients were satisfied results, 2 (7%) were partially satisfied, and 1(3%) was dissatisfied at the final follow-up.

The postoperative Kujala score, Lysholm score, and IKDC score of the group 2 were significantly better than the group 1 (P < 0.001).(Table 4).

Discussion

Our results demonstrated that the isolated soft tissue repair surgery (MRP or MPFLR) and the soft tissue repair combined with DFO surgery (DFO + MRP or DFO + MPFLR) for the treatment of RPD with increased femoral anteversion has good clinical outcomes. The VAS score, Kujala score, Lysholm score and IKDC score of 63 patients were significantly improved. No serious patellar shift occurred in all patients during follow-up. A further finding is that this delivers significantly better results in the Lysholm score, Kujala score, IKDC score, CA, and PTA due to combined with DFO. Besides, the FAA, as an independent risk factor for patellar dislocation [7], has been significantly improved and the FAA has been significantly reduced after combined operations.

Many authors have emphasized that rotational malalignment is a risk factor for patellar instability [4,21,22]. Diederichs et al. suggest that increased femoral torsion may be the currently underestimated major risk factor for patellar dislocation. The mechanical basis for the increased risk may be the increased Q angle due to a greater tendency for genu valgum, which increases the lateral directional force of the patella [5]. Increased FAA results in an abnormal internal rotation gait with the knee joint axis pointing inwards during the forwarding movement of the body. This results in greater internal rotation of the knee axis during the standing position, resulting in excessive lateral force vector of the patella that

may favor patellar instability or dislocation [5,23]. For these patients, combined DFO surgery can reduce the FAA of patients and adjust the patella trajectory by improving the rotational malalignment, which can achieve good clinical outcomes. However, there is no uniform standard for FAA threshold for DFO surgery. At least, Our results show that better efficacy is achieved in patients with FAA over 25° for patellar dislocation. For patients with FAA 20° to 25°, as satisfactory results of soft tissue surgery have been achieved, whether combined DFO surgery is still necessary still needs to be further explored.

the postoperative Tegner score of the patients showed no significant improvement in both groups, which was consistent with previous studies [11,18]. We considered that this might be due to the patient's previous patella dislocation, which led to the patient's fear of high-intensity activities and their unwillingness to engage in too many intense activities. In the end, the patients are only willing to exercise similar to those before the operation. However, Our study found that the group 2 patients had significantly higher satisfaction than group 1 patients. In group1, the dissatisfied patients expressed that they still felt a small amount of pain during the postoperative activities, and they still felt fear for a large amount of activities after the operation. In group 2, the only unsatisfied patient was due to excessive difficulty in postoperative rehabilitation and excessive pain during the kneeling process. Therefore, we believe that combined surgery will yield better results during long term follow-up.

In this study, we did not undertake tibial tubercle transfer correction of tibial tuberous position in patients with combined surgery, but TT-TG was significantly reduced postoperatively. We consider that this may be due to the rotation of the DFO leading to the outward rotation of the femoral trochlear, which in turn leads to the reduction of the TT-TG distance. In previous studies, the normal range of FAA in the population was stated as around 15°[24,25].However, patients with an increased FAA increase the internal rotation of the femur, which may increase the TT-TG distance theoretically. After soft tissue repair combined with DFO surgery, the TT-TG distance of the patients may be reduced, which has also been preliminarily confirmed in our study. This result is interesting, suggesting that DFO surgery alone may be able to achieve good results in patellar dislocation with increased TT-TG and FAA. Recent studies have also reported that tibial tubercle transfer may have significant effects only in specific patients [26]. Therefore, whether the increase of TT-TG is caused by the internal rotation of the femur or by the external placement of tibial tubercle can be further discussed.

In the past 15 years, the medial patellofemoral ligament reconstruction and medial support for the treatment of patellar dislocation by soft tissue repair has achieved good results [15–17,27]. The medial patellofemoral ligament and the medial retinaculum are important soft tissues that constrain the displacement of the patella, providing considerable medial tension and limiting the displacement of the patella to dislocation of the patella. At the same time, our previous research showed that MRP could yield similar results to MPFLR for recurrent patellar instability in adults [17]. Because DFO + MPFLR has more interference during the operation, DFO + MRP has more obvious surgical advantages. The advantage of MRP is to repair the medial femoral soft tissue directly instead of preparing a tendon graft. Also, the MRP avoids potential interference between the femoral tunnel during the reconstruction of the MPFL and the femoral plate screw. Previous studies have also confirmed that DFO + MRP is effective in patients with

increased FAA [18]. Therefore, our surgical team increased the number of operations DFO + MRP surgeries in the treatment process, which not only reduced the difficulty of surgery but also reduced the surgical costs of patients.

However, compared with the isolated soft tissue surgery, the combined operation is more traumatic, the recovery period of patients is longer, and the recovery process is more difficult. In our study, we found that some patients were reluctant to take active functional exercise after combined surgery because of the postoperative pain. In five patients, knee joint activity was still deficient within 8 weeks after the operation. Although it was finally well resolved, the problem of rehabilitation still needs to be paid attention to. In addition, the level of DFO osteotomy performed by various scholars is not consistent. Our recent study found that there is a relationship between the morphology of distal femur and FAA[28], and we believe that the surgical method of intraosseous osteotomy is also safer and more effectives. Therefore, whether future surgeries can be more minimally invasive and precise needs to be further explored.

In summary, the causes of patella dislocation are multifactorial. Although for patients with patellar dislocation with increased FAA, both isolated soft tissue repair surgery and combined with DFO surgery have good outcomes for patellar dislocation patients with rotational malalignments. Both surgical programs can improve knee function, relieve pain, and adjust the patella trajectory. However, the combined surgical approach can address the major risk factors of patients, correct excessive internal rotation of femur, adjust the rotation line of lower limbs and achieve better postoperative outcomes, which may reduce the recurrence rate of postoperative patellar dislocation in patients. Combination surgery may be an ideal surgical strategy to treat patellar dislocation patients with increased FAA, but individualized strategies should be developed to accurately treat patellar dislocation.

Limitations

There are some limitations to our study. First, MRP and MPFLR are regarded as soft tissue surgeries that can achieve the same effect. There is a large difference in the number of surgical samples of the two types of soft tissues, and they are not subgroup analyzed, which may lead to the deviation of the results. On the other hand, patients with severe trochlear dysplasia were excluded from our study. Since trochlear dysplasia is an important factor limiting patella dislocation, it remains to be further studied whether the degree of severe trochlear dysplasia is restricted by the two soft tissue surgeries. However, our previous studies have shown that MRP and MPFLR can achieve similar effects, which can increase the reliability of our study. Second, our patient sample size is small and the follow-up time is short. But our study confirms the efficacy of combined DFO surgery, even if further studies are needed.

Abbreviation

Definition	Abbreviation
femoral derotation osteotomy	DFO
medial patellofemoral ligament	MPFL
medial patellofemoral ligament reconstruction	MPFLR
medial retinaculum plasty	MRP
tibia tuberosity-trochlear groove distance	TT-TG
femoral anteversion angle	FAA
congruence angle	CA
patella tilt angle	PTA
International Knee Documentation Committee	IKDC
visual analogue scale	VAS

Declarations

Ethical review statement:

All protocols in this study were approved by the ethics committee of the Third Hospital of Hebei Medical University, Hebei, China.

Funding statement:

No benefits in any form have been received or will be received from a commercial party related directly or indirectly to the subject of this article.

Conflict:

The authors declare that they have no conflict of interest.

Author contributions:

Chongyi Fan: Designed the study, Follow-up visit, Analyzed the data, Wrote the article.

Guangmin Yang: Designed the study, Edited the manuscript.

Yingzhen Niu: Designed the study,

Yirong Xu: Design illustrations

Ming Li: Edited the manuscript.

Xunkai Feng: Edited the manuscript.

Fei Wang: Designed the study, Wrote the article.

References

1. Fithian DC, Paxton EW, Stone ML, et al. Epidemiology and natural history of acute patellar dislocation. Am J Sports Med. 2004;32(5):1114-1121. doi:10.1177/0363546503260788
2. Atkin DM, Fithian DC, Marangi KS, Stone ML, Dobson BE, Mendelsohn C. Characteristics of patients with primary acute lateral patellar dislocation and their recovery within the first 6 months of injury. Am J Sports Med. 2000;28(4):472-479. doi:10.1177/03635465000280040601
3. Servien E, Verdonk PC, Neyret P. Tibial tuberosity transfer for episodic patellar dislocation. Sports Med Arthrosc Rev. 2007;15(2):61-67. doi:10.1097/JSA.0b013e3180479464
4. Dejour H, Walch G, Nove-Josserand L, Guier C. Factors of patellar instability: an anatomic radiographic study. Knee Surg Sports Traumatol Arthrosc. 1994;2(1):19-26. doi:10.1007/BF01552649
5. Diederichs G, Köhlitz T, Kornaropoulos E, Heller MO, Vollnberg B, Scheffler S. Magnetic resonance imaging analysis of rotational alignment in patients with patellar dislocations. Am J Sports Med. 2013;41(1):51-57. doi:10.1177/0363546512464691
6. Franciozi CE, Ambra LF, Albertoni LJ, et al. Increased Femoral Anteversion Influence Over Surgically Treated Recurrent Patellar Instability Patients. Arthroscopy. 2017;33(3):633-640. doi:10.1016/j.arthro.2016.09.015
7. Ateschrang A, Freude T, Grünwald L, Schäffler A, Stöckle U, Schröter S. Patellaluxation: Diagnostik- und Behandlungsalgorithmus unter Berücksichtigung der Torsion [Patella dislocation: an algorithm for diagnostic and treatment considering the rotation]. Z Orthop Unfall. 2014;152(1):59-67. doi:10.1055/s-0033-1360303
8. Delgado ED, Schoenecker PL, Rich MM, Capelli AM. Treatment of severe torsional malalignment syndrome. J Pediatr Orthop. 1996;16(4):484-488. doi:10.1097/00004694-199607000-00012
9. Strecker W, Dickschas J. Die Torsionsosteotomie : Behandlung des patellofemoralen Maltracking [Torsional osteotomy : Operative treatment of patellofemoral maltracking]. Oper Orthop Traumatol. 2015;27(6):505-524. doi:10.1007/s00064-015-0430-8
10. Imhoff FB, Coptic M, Liska F, et al. Derotational osteotomy at the distal femur is effective to treat patients with patellar instability. Knee Surg Sports Traumatol Arthrosc, 2019, 27: 652–658.
11. Nelitz M, Dreyhaupt J, Williams SR, et al. Combined supracondylar femoral derotation osteotomy and patellofemoral ligament reconstruction for recurrent patellar dislocation and severe femoral anteversion syndrome: surgical technique and clinical outcome. Int Orthop, 2015, 39: 2355–2362.
12. Zhang Z, Zhang H, Song G, Zheng T, Ni Q, Feng H. Increased femoral anteversion is associated with inferior clinical outcomes after MPFL reconstruction and combined tibial tubercle osteotomy for the

treatment of recurrent patellar instability. Knee Surg Sports Traumatol Arthrosc. 2020;28(7):2261-2269. doi:10.1007/s00167-019-05818-3

13. Weber AE, Nathani A, Dines JS, et al. An Algorithmic Approach to the Management of Recurrent Lateral Patellar Dislocation [published correction appears in J Bone Joint Surg Am. 2016 Jun 15;98(12):e54]. J Bone Joint Surg Am. 2016;98(5):417-427. doi:10.2106/JBJS.O.00354
14. Deie M, Ochi M, Sumen Y, Adachi N, Kobayashi K, Yasumoto M. A long-term follow-up study after medial patellofemoral ligament reconstruction using the transferred semitendinosus tendon for patellar dislocation. Knee Surg Sports Traumatol Arthrosc. 2005;13(7):522-528. doi:10.1007/s00167-005-0641-x
15. Drez D Jr, Edwards TB, Williams CS. Results of medial patellofemoral ligament reconstruction in the treatment of patellar dislocation. Arthroscopy. 2001;17(3):298-306. doi:10.1053/jars.2001.21490
16. Mulliez A, Lambrecht D, Verbruggen D, Van Der Straeten C, Verdonk P, Victor J. Clinical outcome in MPFL reconstruction with and without tuberositas transposition. Knee Surg Sports Traumatol Arthrosc. 2017;25(9):2708-2714. doi:10.1007/s00167-015-3654-0
17. Ma LF, Wang F, Chen BC, Wang CH, Zhou JW, Wang HY. Medial retinaculum plasty versus medial patellofemoral ligament reconstruction for recurrent patellar instability in adults: a randomized controlled trial. Arthroscopy. 2013;29(5):891-897. doi:10.1016/j.arthro.2013.01.030
18. Yang GM, Wang YY, Zuo LX, Li FQ, Dai YK, Wang F. Good Outcomes of Combined Femoral Derotation Osteotomy and Medial Retinaculum Plasty in Patients with Recurrent Patellar Dislocation. Orthop Surg. 2019;11(4):578-585. doi:10.1111/os.12500
19. Shams K, DiCesare CA, Grawe BM, et al. Biomechanical and Functional Outcomes After Medial Patellofemoral Ligament Reconstruction: A Pilot Study. Orthop J Sports Med. 2019;7(2):2325967119825854. Published 2019 Feb 15. doi:10.1177/2325967119825854
20. van Jonbergen HP, Boeddha AV, M van Raaij JJ. Patient Satisfaction and Functional Outcomes Following Secondary Patellar Resurfacing. Orthopedics. 2016;39(5):e850-e856. doi:10.3928/01477447-20160509-05
21. Hawkins RJ, Bell RH, Anisette G. Acute patellar dislocations. The natural history. Am J Sports Med. 1986;14(2):117-120. doi:10.1177/036354658601400204
22. Parikh S, Noyes FR. Patellofemoral disorders: role of computed tomography and magnetic resonance imaging in defining abnormal rotational lower limb alignment. Sports Health. 2011;3(2):158-169. doi:10.1177/1941738111399372
23. Fithian DC, Paxton EW, Cohen AB. Indications in the treatment of patellar instability. J Knee Surg. 2004;17(1):47-56. doi:10.1055/s-0030-1247149
24. Decker S, Suero EM, Hawi N, Müller CW, Krettek C, Citak M. The physiological range of femoral antetorsion. Skeletal Radiol. 2013;42(11):1501-1505. doi:10.1007/s00256-013-1687-3
25. Kaiser P, Attal R, Kammerer M, et al. Significant differences in femoral torsion values depending on the CT measurement technique. Arch Orthop Trauma Surg. 2016;136(9):1259-1264. doi:10.1007/s00402-016-2536-3

26. Mulliez A, Lambrecht D, Verbruggen D, Van Der Straeten C, Verdonk P, Victor J. Clinical outcome in MPFL reconstruction with and without tuberositas transposition. Knee Surg Sports Traumatol Arthrosc. 2017 Sep;25(9):2708-2714. doi: 10.1007/s00167-015-3654-0. Epub 2015 Jun 2. PMID: 26032604.
27. Baumann CA, Pratte EL, Sherman SL, Arendt EA, Hinckel BB. Reconstruction of the medial patellotibial ligament results in favorable clinical outcomes: a systematic review. Knee Surg Sports Traumatol Arthrosc. 2018;26(10):2920-2933. doi:10.1007/s00167-018-4833-6
28. Yang G, Dai Y, Dong C, Kang H, Niu J, Lin W, Wang F. Distal femoral morphological dysplasia is correlated with increased femoral torsion in patients with trochlear dysplasia and patellar instability. Bone Joint J. 2020 Jul;102-B(7):868-873. doi: 10.1302/0301-620X.102B7.BJJ-2019-1331.R1. PMID: 32600137.

Tables

Table 1. Characteristics of the two groups.

	Group 1	Group 2	P
Age, y	20.9 ± 2.97	20.7 ± 3.38	0.769
Sex, n			
Female	24	21	
Male	9	9	
BMI, kg/m^2	25.1 ± 2.19	24.6 ± 1.91	0.420
Follow-up time, mo	21.1±7.4	23.9±6.8	0.217
Preoperative			
FAA (°)	29.64±2.63	29.16± 2.87	0.500
TT-TG (mm)	18.06±2.54	19.03 ±2.52	0.147
CA (°)	38.51±4.59	37.96 ± 5.22	0.659
PTA (°)	31.36±4.68	30.96 ±4.39	0.730
Kujala	61.45±9.15	63.57±8.94	0.359
Lysholm	59.96± 6.94	62.20±5.73	0.172
IKDC	61.18±7.17	62.76 ±6.91	0.377
Tegner	3.93 ±1.17	4.10±1.37	0.618
VAS	4.00±1.08	3.77±1.25	0.432

Values are presented as mean± SD score. FAA: femoral anteversion angle; TT-TG: tibia tuberosity-trochlear groove distance; CA: congruence angle PTA: patella tilt angle; IKDC, International Knee Documentation Committee; VAS, visual analogue scale.

Table 2. Preoperative and postoperative radiological parameters according to both groups

	Group 1			Group 2		
	Pre	Post	P	Pre	Post	P
FAA(°)	29.64±2.63	-	-	29.16± 2.87	15.76 ±2.02	< 0.001
TT-TG (mm)	18.06±2.54	-	-	19.03 ±2.52	17.80 ±2.24	< 0.001
CA(°)	38.51±4.59	17.06 ± 2.30	< 0.001	37.96 ± 5.22	15.43 ± 2.19	< 0.001
PTA(°)	31.36±4.68	15.78 ± 1.47	< 0.001	30.96 ±4.39	14.40 ± 1.89	< 0.001

Values are presented as mean± SD score. FAA: femoral anteversion angle; TT-TG: tibia tuberosity-trochlear groove distance; CA: congruence angle PTA: patella tilt angle.

Table 3. Patient-Reported Outcomes of All Patients.

	Group 1			Group 2		
	Pre	Post	P	Pre	Post	P
Kujala	61.45±9.15	77.09±3.94 -	< 0.001-	63.57±8.94	82.40±5.60	< 0.001
Lysholm	59.96± 6.94	73.69±5.38	< 0.001	62.20±5.73	79.26 ±6.61	< 0.001
IKDC	61.18±7.17	75.03 ±4.56	< 0.001	62.76 ±6.91	81.20 ±6.27	< 0.001
Tegner	3.93 ±1.17	4.09 ± 0.94	0.169	4.10±1.37	4.16±1.26	< 0.001
VAS	4.00±1.08	2.39 ± 0.86	< 0.001	3.77±1.25	2.43±1.07	0.489

Values are presented as mean± SD score. IKDC, International Knee Documentation Committee; VAS, visual analogue scale.

Table 4. Postoperative outcomes were compared between both groups.

	Group 1	Group 2	P
CA(°)	17.06 ± 2.30	15.43 ± 2.19	0.006
PTA(°)	15.78 ± 1.47	14.40 ± 1.89	0.002
Kujala	77.09±3.94	82.40±5.60	< 0.001
Lysholm	73.69±5.38	79.26 ±6.61	< 0.001
IKDC	75.03 ±4.56	81.20 ±6.27	< 0.001
Tegner	4.09 ± 0.94	4.16±1.26	0.787
VAS	2.39 ± 0.86	2.43±1.07	0.872

Values are presented as mean± SD score. CA: congruence angle PTA: patella tilt angle; IKDC, International Knee Documentation Committee; VAS, visual analogue scale.

Figures

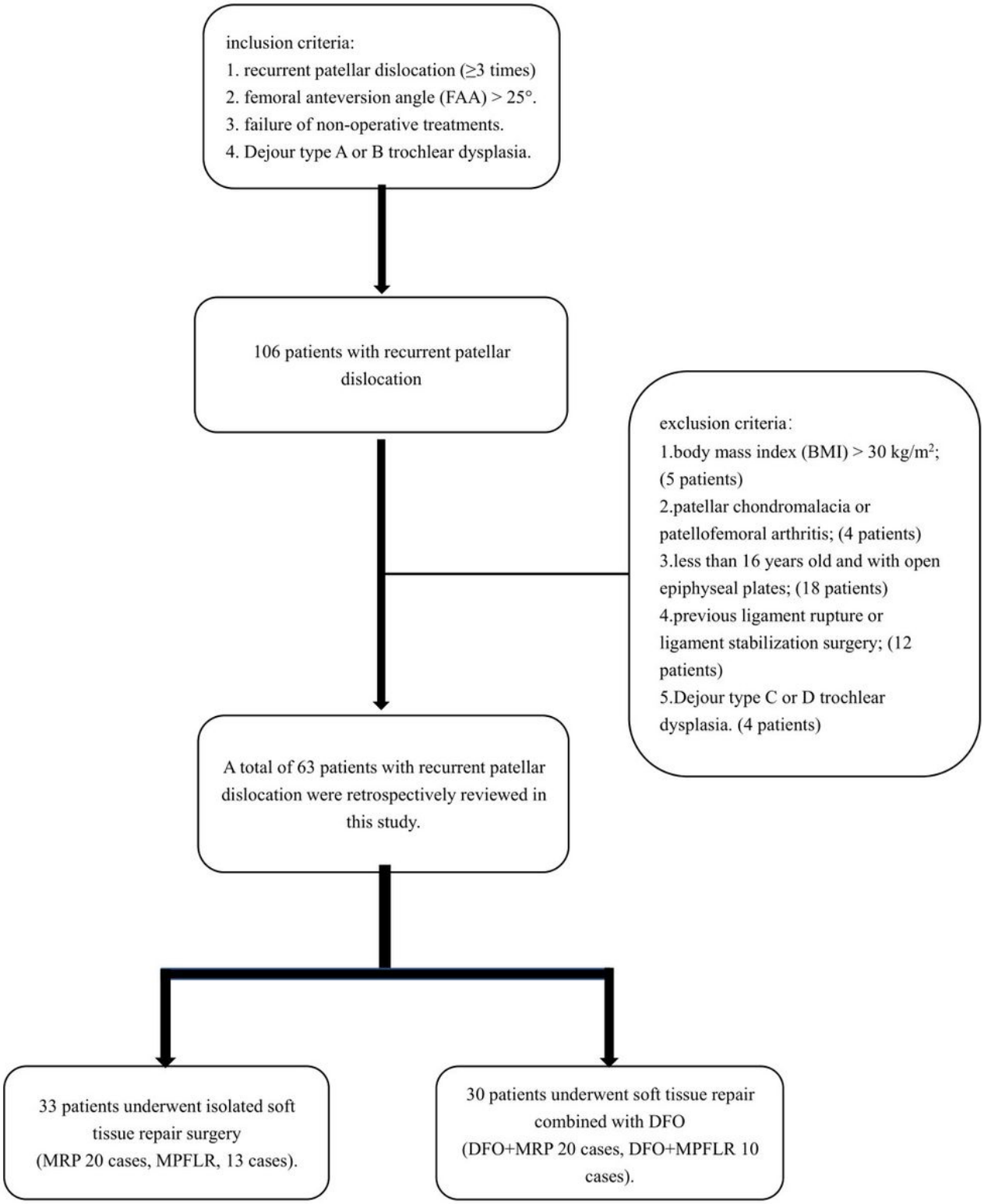

Figure 1

Flow diagram.

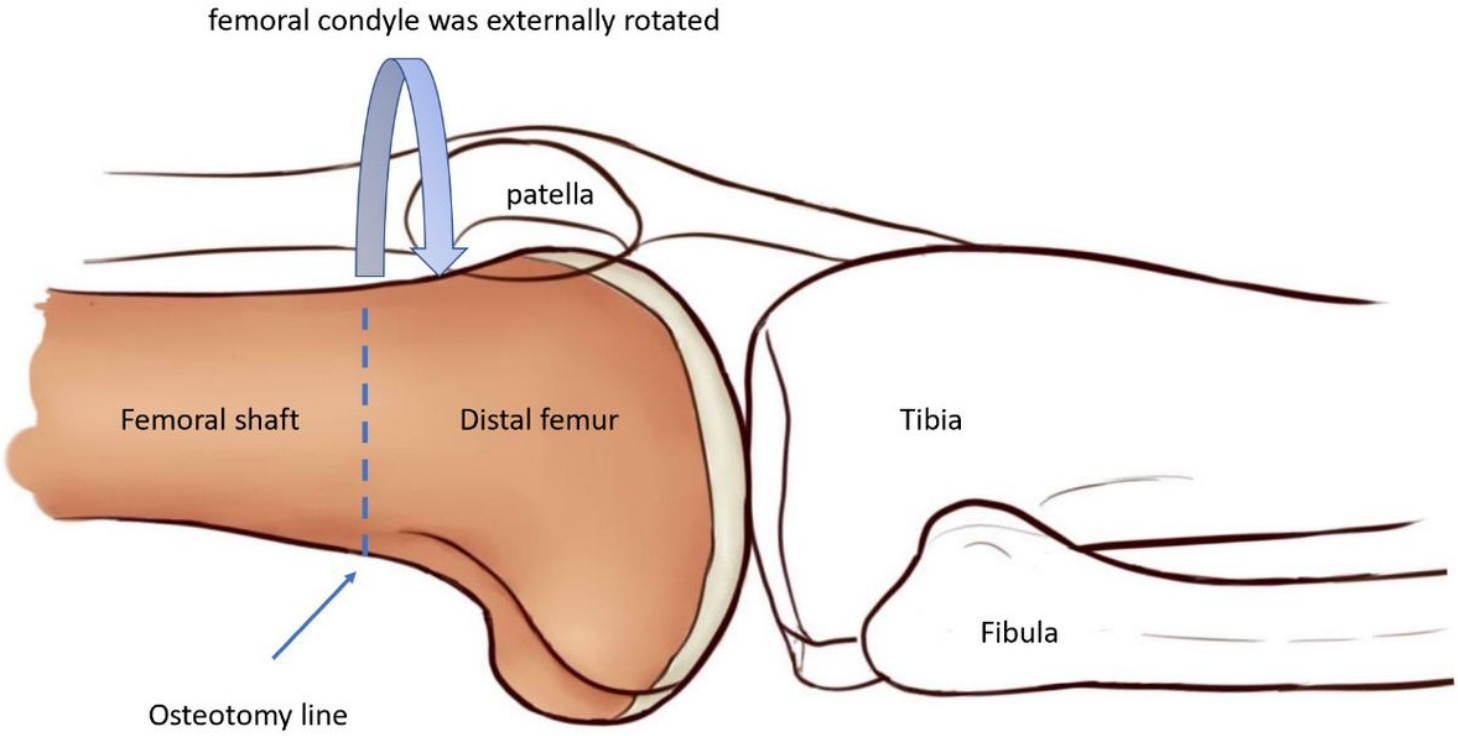

Figure 2

Make an osteotomy line parallel to the tibiofemoral joint line above the femoral condyle. Then, the femoral condyle was externally rotated to eliminate the increased FAA.

Figure 3

Intraoperative fluoroscopy ensures that the distal femoral locking plate in a normal position. The red arrow is the osteotomy line.

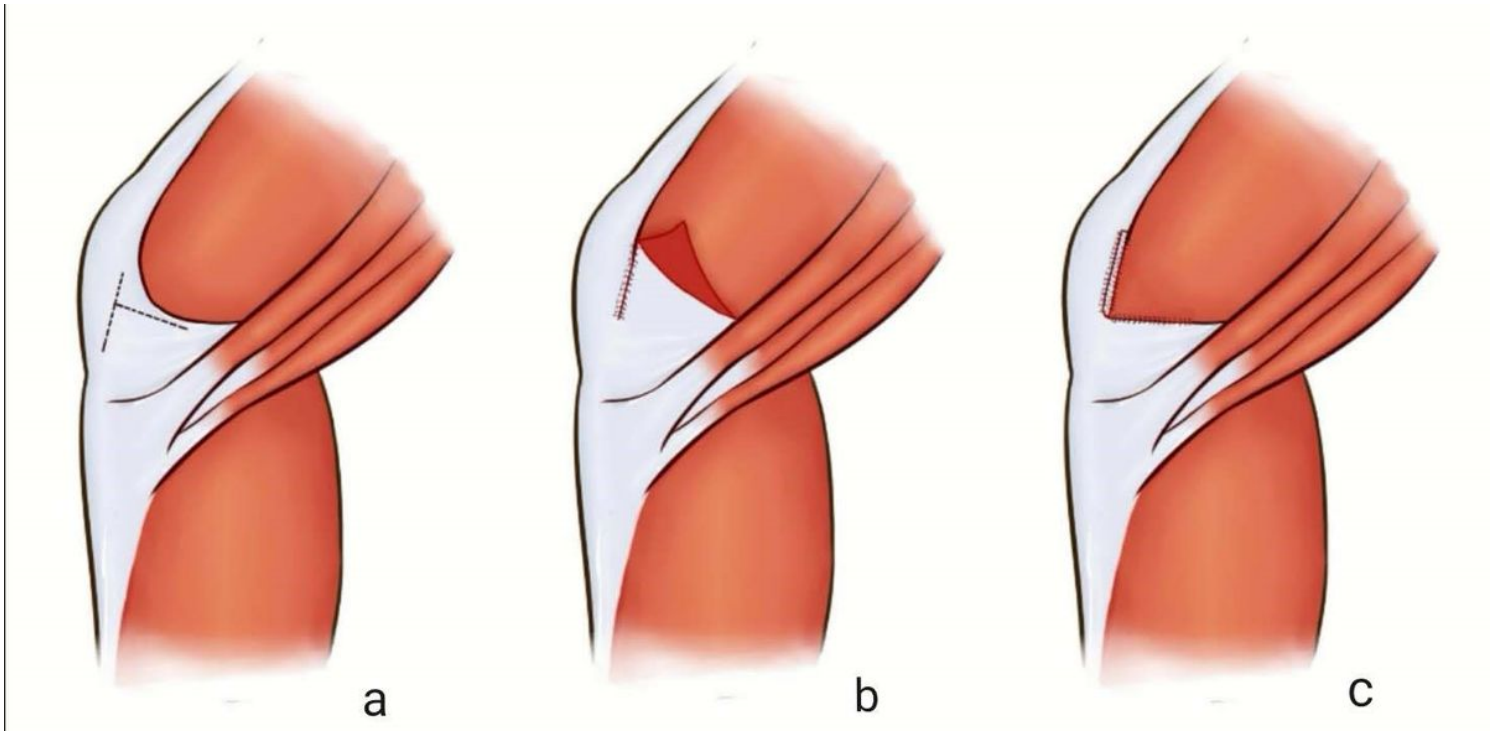

Figure 4

Medial Retinaculum Plasty. a. A longitudinal incision and a transverse incision separate the vastus medialis oblique (VMO) and the medial patellar retinaculum (MPR); b. the MPR was pulled proximally to the upper pole of the patella for fixation; c. the VMO was fixed to the medial edge of the patella and the overlapping parts of the two tissues were sutured together.

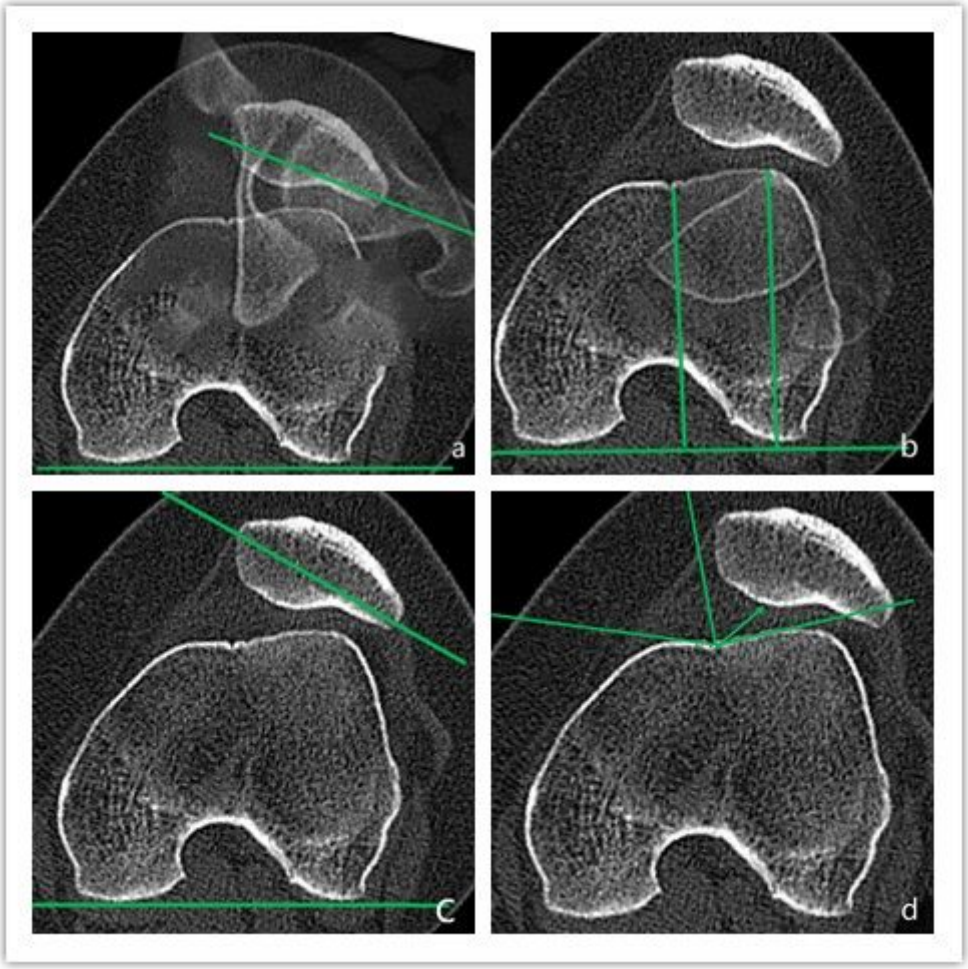

Figure 5

The picture showed a measurement of 4 values. a. FAA: femoral anteversion angle b.TT-TG: tibia tuberosity-trochlear groove distance c.PTA: patella tilt angle d. CA: congruence angle

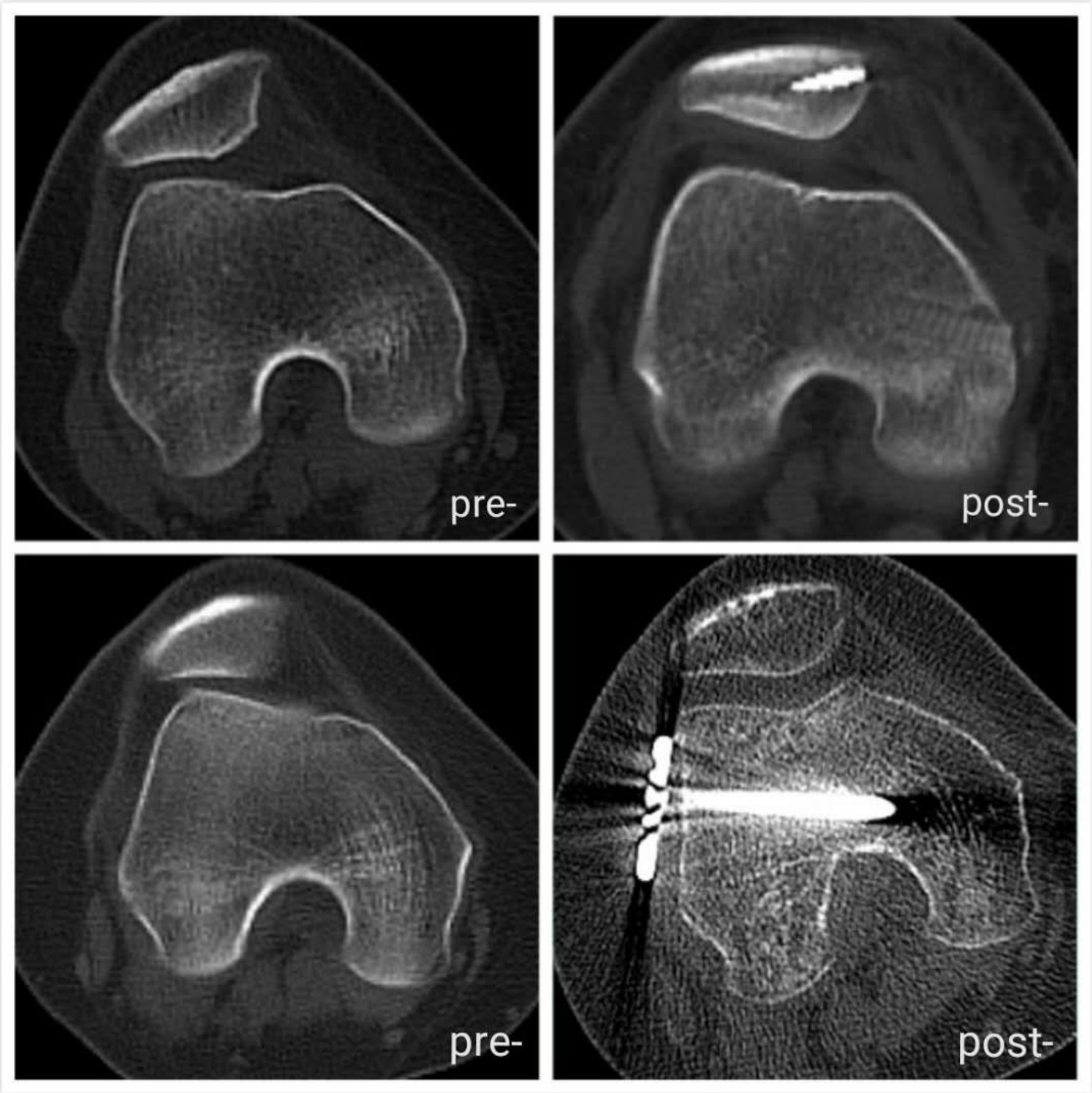

Figure 6

The preoperative and postoperative radiological images showed the improved patellofemoral congruence in both groups.