Severe Leg Length Discrepancy after Total Hip Arthroplasty: Where is the Problem- Cup or Stem? A Retrospective Controlled Study

Jimin Ma
Yijishan Hospital of Wannan Medical College https://orcid.org/0000-0003-0610-2086
Hanli Lu
Yijishan Hospital of Wannan Medical College
Xinxing Chen
Yijishan Hospital of Wannan Medical College
Dasai Wang
Yijishan Hospital of Wannan Medical College
Qiang Wang (13909636163@126.com)
Yijishan Hospital of Wannan Medical College

Research article

Keywords: severe leg length discrepancy, leg length equality, stem height, total hip arthroplasty

Posted Date: November 24th, 2020

DOI: https://doi.org/10.21203/rs.3.rs-112209/v1

Abstract

Background: The factors that contribute to the severe leg length discrepancy (LLD) after total hip arthroplasty (THA) are presently unclear. In the current study, we investigated whether the acetabular cup position and femoral stem are related to the patients with severe LLD by comparing with patients who had the leg length equality.

Materials and Methods: Between June 2013 and July 2019, patients undergoing unilateral primary THA in the Department of Orthopaedics at our institution were screened. According to the postoperative leg length difference, a total of 178 patients were included in the study. A group of 107 patients had leg length equality (LLD≤3 mm) and the other group of 71 patients had severe LLD (LLD≥15 mm). A standardized protocol for evaluation of anteroposterior hip radiographs was used to measure the postoperative LLD. The difference of acetabular cup position (vertical centre of rotation (VCR), horizontal centre of rotation (HCR)) and the femoral stem(stem height; stem size; femoral neck osteotomy level) between the two groups. We also assessed whether there was a difference in proximal femur morphology between the two groups.

Results: On the femoral side, the mean stem height of (70.82±5.49) mm in the severe LLD group was significantly different from the (67.35±6.88) mm mean discrepancy in the leg length equality group ($P < .001$). Stem size and femoral neck osteotomy level showed no statistically differences between the two groups ($P>0.05$). On the acetabular side, there was no significant difference between the two groups in the VCR and HCR ($P>0.05$) . There was also no statistical difference in proximal femur morphology between the two groups ($P>0.05$).

Conclusion: The main reason for the occurrence of severe LLD may be due to improper treatment of the femur side. Although preoperative template could choose a better stem size and femoral neck osteotomy level, surgeons need to pay more attention to the whole operation process of the femur stem.

Introduction

Leg length discrepancy (LLD) is a common complication after total hip arthroplasty (THA)[1–3], especially severe LLD, may result in patients' decreased satisfaction and serious consequences. Such as gait asymmetry, lower back pain ,nerve injury and prosthesis loosening[2, 4, 5]. There are many factors that may affect the occurrence of postoperative LLD[6, 7].However, few studies have reported that the main causes of severe LLD in patients after THA.

The our aim was to investigate the factors that contribute to postoperative severe LLD. We analyzed the factors from two aspects. One is the acetabular cup side, such as vertical centre of rotation (VCR) and horizontal centre of rotation (HCR). And the other is femoral stem side, such as stem height, stem size and femoral neck osteotomy level. Proximal femur morphology was also evaluated by femoral cortical index (FCI).

Materials And Methods

Inclusion and Exclusion Criteria

Inclusion Criteria included: (□) Patients who underwent unilateral primary THA in the Department of Orthopaedics at our institution between June 2013 and July 2019; (□) meet the diagnostic criteria for osteoarthritis□osteonecrosis or femoral neck fracture,and have definite indications for surgery; (□) the related outcomes of patients were completely recorded.

Exclusion criteria included: (□) Acetabular dysplasia or defect; (□) contralateral hip space stenosis or fusion; (□) history of hip surgery; (□) proximal femoral deformity; (□) preoperative LLD was greater than 2 cm in patients with osteoarthritis and osteonecrosis;

Group Allocations

Two groups of patients were included in this study: 107 consecutive patients with LLD no more than 3 mm, who underwent THA during June 2013 and July 2019 were defined as leg length equality group; whereas 71 consecutive patients with LLD of 15 mm or grater were defined as severe LLD group, who underwent THA during the same time period. Our cohort was subdivided by LLD: ≥15 mm were severe LLD: ≤3 mm were leg length equality.

Perioperative treatments

Preoperative template measurements were taken for all patients, and all operations were completed by the senior surgeons. In each operation, the rotation center and the lower limb length were restored anatomically as much as possible. Implants used were the M/L Taper (Zimmer Biomet, Warsaw, Indiana) and the LCU (Link, Hanburg, Germany).

Radiological measurement

All measurements were taken with Picture Archiving and Communication Systems (PACS). FCI was measured on the basis of anteroposterior hip radiographs taken before surgery, and other radiological data were taken at least four weeks after operation. We only measured intra-observer reliability (not inter-observer reliability), and the intra-observer reliability of LLD, VCR, HCR, stem height, femoral neck osteotomy, FCI level were 0.905, 0.865, 0.872, 0.870, 0.885, 0.875.

Leg Length Discrepancy

The leg length discrepancy (LLD) refers to the difference of bilateral lower limb length after THA. LLD was defined as the perpendicular distance between the lesser trochanters and a horizontal reference line connecting the inferioraspect of the acetabular teardrops (Figure 1).

Vertical Centre of Rotation

Vertical centre of rotation (VCR) refers to the height at which the rotational center moves up or down after THA. After surgery, VCR was measured as the distance from the rotational center to the teardrop line (Figure 1).

Horizontal Centre of Rotation

Horizontal centre of rotation (HCR) is the distance that the acetabular cup moves horizontally inward. It was defined as the horizontal distance between a perpendicular line through the teardrop and the hip rotational center (Figure 1).

Stem Height

Stem height is the height of the femur stem relative to the femur after surgery. Stem height was measured as the distance from the rotational center to the lesser trochanters (Figure 2).

Femoral Neck Osteotomy Level

Femoral neck osteotomy level refers to the osteotomy height at the neck of the femur. Scholars usually define the distance between the medial side of the femoral neck osteotomy and the superior level of the lesser trochanter as femoral neck osteotomy level (Figure 2).

Femoral Cortical Index

Femoral cortical index (FCI) refers to the proximal morphology of the femur, which was defined as the ratio of cortical width minus endosteal width to the cortical width at a level of 10 cm below the tip of the lesser trochanter on the AP radiograph (Figure 3)[8].

Statistical Analysis

Statistical analyses were performed using SPSS Version 21 (IBM Corp., Armonk, New York, USA). All continuous variables are reported as mean and standard deviation, and an independent t-test was used to

detect differences between two groups. All categorical variables are reported as number and percent, and the chi-squared test or Fisher's exact test was used. All significance levels were set at P =0.05.

Results

There was no difference in general results between patients with severe LLD group (N = 107) and leg length equality group (N = 71). Proximal femur morphology showed no statistical difference between the two groups(P = 0.252). (Table 1)

Table 1
Patients Demographics

	LLE Group (N = 107)	SLLD Group (N = 71)	P
Sex (Male:Female, %)	51(48): 56(52)	31(44): 40(56)	0.600
Age (years)	62.70±7.16	64.15±5.69	0.153
Diagnosis(OA:ON:FNF,%)	27 (25):44 (41):36 (34)	20 (28):37 (52):14 (20)	0.121
FCI	0.56±0.08	0.55±0.07	0.252
Stem Type (Link: Zimmer,%)	55(51): 52(49)	38(54): 33(46)	0.782

LLE Group : leg length equality group; SLLD Group : severe leg length discrepancy group; OA: osteoarthritis, ON: osteonecrosis, FNF: femoral neck fracture

On the side of the femur, the mean stem height of (70.82±5.49) mm in the severe LLD group was significantly different from the (67.35±6.88) mm mean discrepancy in the leg length equality group (P < .001). Femoral neck osteotomy level showed no significant difference between the two groups (P = 0.157). On the side of the acetabulum, there was no significant difference between the two groups in the VCR and HCR (P = 0.130;P = 0.308) (Table 2). And stem size showed no statistical difference in between the two groups (Table 3).

Table 2
Measurement of anteroposterior radiographs between the two groups (mean±SD)

	LLE Group (N = 107)	SLLD Group (N = 71)	P
VCR (mm)	21.25±3.64	20.37±3.95	0.130
HCR (mm)	33.97±3.13	34.48±3.57	0.308
Stem Height (mm)	67.35±6.88	70.82±5.49	< 0.001
Femoral Neck Osteotomy Level (mm)	9.50±3.22	10.29±4.12	0.157

VCR: vertical centre of rotation ; HCR: horizontal centre of rotation; LLE Group : leg length equality group; SLLD Group : severe leg length discrepancy group;

Table 3
Stem size data (mean±SD)

	Zimmer Stem (N = 85)	Link Stem (N = 93)
LLE Group	10.32±2.44	10.69±1.36
SLLD Group	10.15±2.27	10.26±1.35
P	0.755	0.138
LLE Group : leg length equality group; SLLD Group : severe leg length discrepancy group;		

Discussion

The LLD may lead to low back pain, joint stiffness or dislocation, nerve injury and prosthesis loosening and other complications after THA[1, 9]. And this leads to patient satisfaction decreased and medical litigation [10, 11]. Renkawitz et al. [12]conducted a 3D gait analysis of 60 patients undergoing THA, and found that the gait kinematics of the patients was abnormal when the postoperative LLD larger than 5 mm. Austin et al. [13]reported that it was acceptable when the difference length of lower limbs was no more than 7 mm. Friberg et al. [14] found that the occurrence of complications after THA in 1157 patients was highly correlated with the unequal length of lower limbs, and 79% of sciatica and 89% of unilateral hip symptoms occurred on the longer side of the lower limbs. The occurrence of severe leg inequality is a problem that every surgeon tries to avoid. And we should pay attention to what could avoid this situation as much as possible in the THA.

In this study, we found no significant difference in the surgical treatment of the acetabular side between patients with severe LLD and leg length equaity. However, in the femur side, the severe LLD patients showed the greater stem height after THA. A retrospective study involving 172 THA by Al-Amiry et al.[15] showed that the leg lengthening is mostly related to the position of femoral stem, while the reduction of global femoral offset is mostly related to the inaccurate positions of the femoral stem and the acetabular cup. And Konyves et al.[16] also found appropriate placement of the femoral component could significantly reduce a patient's perception of discrepancy of length. These results indicate that cup positioning has less contribution to LLD after THA.

For the femoral side, stem height difference may be due to the excessive pursuit of hip joint stability by surgeons to avoid postoperative dislocation, larger stem and oversize prosthetic heads were selected to increase the offset, resulting in the severe LLD. However, it was found in this study that all patients were able to select a better prosthesis size by preoperative template measurement, inappropriate treatment of the whole femur side may lead to severe LLD. Although some studies[17, 18] have pointed out that there may be a correlation between proximal femur morphology and lower extremity inequality, in our study, there was no significant difference in proximal femur morphology between patients with severe LLD and leg length equality. Severe LLD is mostly associated with improper management of the whole femur side.

Limitations

There are several limitations of this study. First, this study was designed retrospectively, but it involved a relatively large sample and was highly persuasive to support the observations. Second, we only selected patients without acetabular dysplasia or defect to prevent the acetabular variability. In order to ensure the accuracy of postoperative LLD results, patients with osteoarthritis and osteonecrosis whose preoperative LLD was greater than 2 cm were excluded.

Conclusion

The main reason for the occurrence of severe LLD may be due to improper treatment of the femur side. Although preoperative template could choose a better stem size and femoral neck osteotomy level, surgeons need to pay more attention to the whole operation process of the femur stem.

Abbreviations

LLD: Leg length discrepancy; THA: Total hip arthroplasty; VCR: Vertical centre of rotation ; HCR: Horizontal centre of rotation; SD: Standard Deviation.

Declarations

Acknowledgements

None

Authors’ contributions

JM and QW contributed to the study design.JM and QW drafted the manuscript and searched the articles. HL and XX accomplished the statistical analyses. JM, HL and DS revised the manuscript. All authors read and approved the manuscript.

Funding

There is no funding source.

Availability of data and materials

All data are fully available without restriction.

Ethics approval and consent to participate

Ethical approval for this study was obtained through Yijishan Hospital.

Consent for publication

Not applicable.

Competing interests

The authors declare that they have no competing interests.

References

1. Clark CR, Huddleston HD, Schoch EP 3rd and Thomas BJ. Leg-length discrepancy after total hip arthroplasty. J Am Acad Orthop Surg. 2006;14:38–45.
2. Maloney WJ, Keeney JA. Leg length discrepancy after total hip arthroplasty. J Arthroplasty. 2004;19:108–10.
3. Papadopoulos DV, Koulouvaris P, Aggelidakis GC, Tsantes AG, Lykissas MG, Mavrodontidis A. Intraoperative measurement of limb lengthening during total hip arthroplasty. Indian J Orthop. 2017;51:162–7.
4. Kaufman KR, Miller LS, Sutherland DH. Gait asymmetry in patients with limb-length inequality. J Pediatr Orthop. 1996;16:144–50.
5. McWilliams AB, Grainger AJ, O'Connor PJ, Redmond AC, Stewart TD, Stone MH. A review of symptomatic leg length inequality following total hip arthroplasty. Hip Int. 2013;23:6–14.
6. Kayani B, Pietrzak J, Hossain FS, Konan S, Haddad FS. Prevention of limb length discrepancy in total hip arthroplasty. Br J Hosp Med (Lond). 2017;78:385–90.
7. Halai M, Gupta S, Gilmour A, Bharadwaj R, Khan A, Holt G. The Exeter technique can lead to a lower incidence of leg-length discrepancy after total hip arthroplasty. Bone Joint J. 2015;97-b:154–9.
8. Dorr LD, Faugere MC, Mackel AM, Gruen TA, Bognar B, Malluche HH. Structural and cellular assessment of bone quality of proximal femur. Bone. 1993;14:231–42.
9. Ranawat CS. The pants too short, the leg too long! Orthopedics. 1999;22:845–6.
10. Flecher X, Ollivier M, Argenson JN. Lower limb length and offset in total hip arthroplasty. Orthop Traumatol Surg Res. 2016;102:9–20.
11. Herman KA, Highcock AJ, Moorehead JD, Scott SJ. A comparison of leg length and femoral offset discrepancies in hip resurfacing, large head metal-on- metal and conventional total hip replacement: a case series. J Orthop Surg Res. 2011;6:65.
12. Renkawitz T, Weber T, Dullien S, Woerner M, Dendorfer S, Grifka J, Weber M. Leg length and offset differences above 5 mm after total hip arthroplasty are associated with altered gait kinematics. Gait Posture. 2016;49:196–201.

13. Austin MS, Hozack WJ, Sharkey PF, Rothman RH. Stability and leg length equality in total hip arthroplasty. J Arthroplasty. 2003;18:88–90.
14. Friberg O. Clinical symptoms and biomechanics of lumbar spine and hip joint in leg length inequality. Spine (Phila Pa 1976). 1983;8:643–51.
15. Al-Amiry B, Mahmood S, Krupic F, Sayed-Noor A. Leg lengthening and femoral-offset reduction after total hip arthroplasty: where is the problem - stem or cup positioning? Acta Radiol. 2017;58:1125–31.
16. Konyves A, Bannister GC. The importance of leg length discrepancy after total hip arthroplasty. J Bone Joint Surg Br. 2005;87:155–157.
17. Lim YW, Huddleston JI 3rd, Goodman SB, Maloney WJ, Amanatullah DF. Proximal Femoral Shape Changes the Risk of a Leg Length Discrepancy After Primary Total Hip Arthroplasty. J Arthroplasty. 2018;33:3699–3703.
18. Brumat P, Pompe B, Antolič V, Mavčič B. The impact of canal flare index on leg length discrepancy after total hip arthroplasty. Arch Orthop Trauma Surg. 2018;138:123–129.

Figures

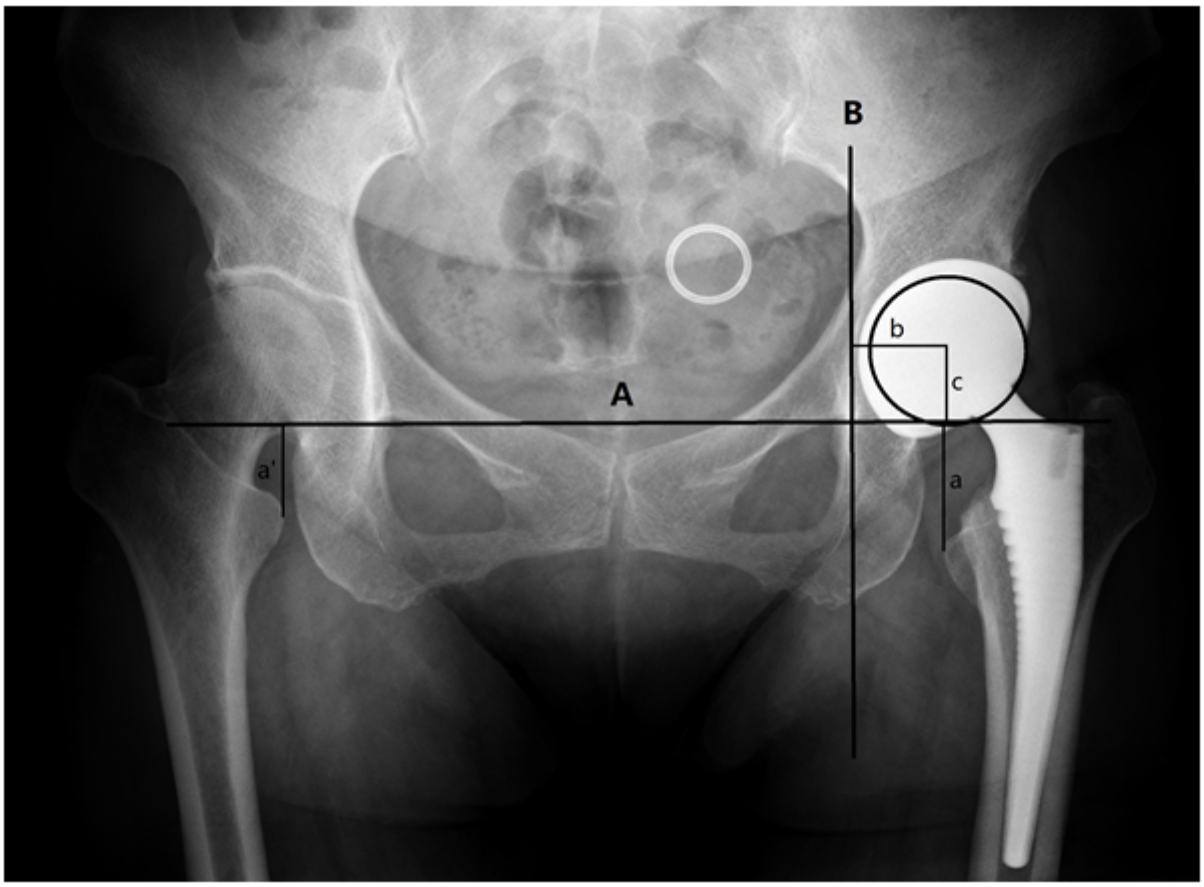

Figure 1

A = inter-teardrop line; B = line passing through the teardrop.; a/a’ = perpendicular distance from the lesser trochanters to Line A; b (horizontal centre of rotation)= perpendicular distance from the centre of rotation to Line B; c (vertical centre of rotation)= perpendicular distance from the centre of rotation to Line A. Leg length discrepancy = a - a’.

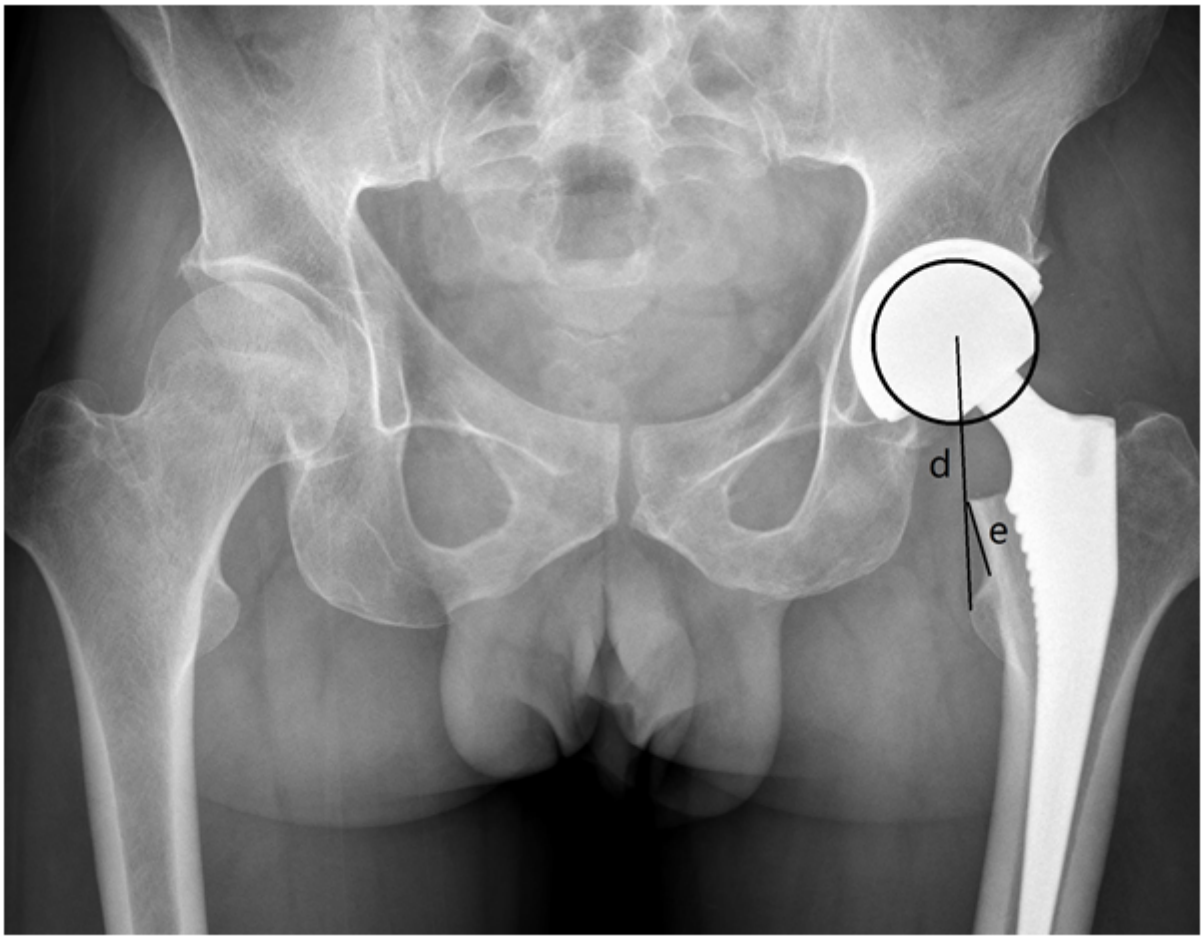

Figure 2

d (stem height) = distance from the centre of rotation to the lesser trochanters; e = femoral neck osteotomy level.

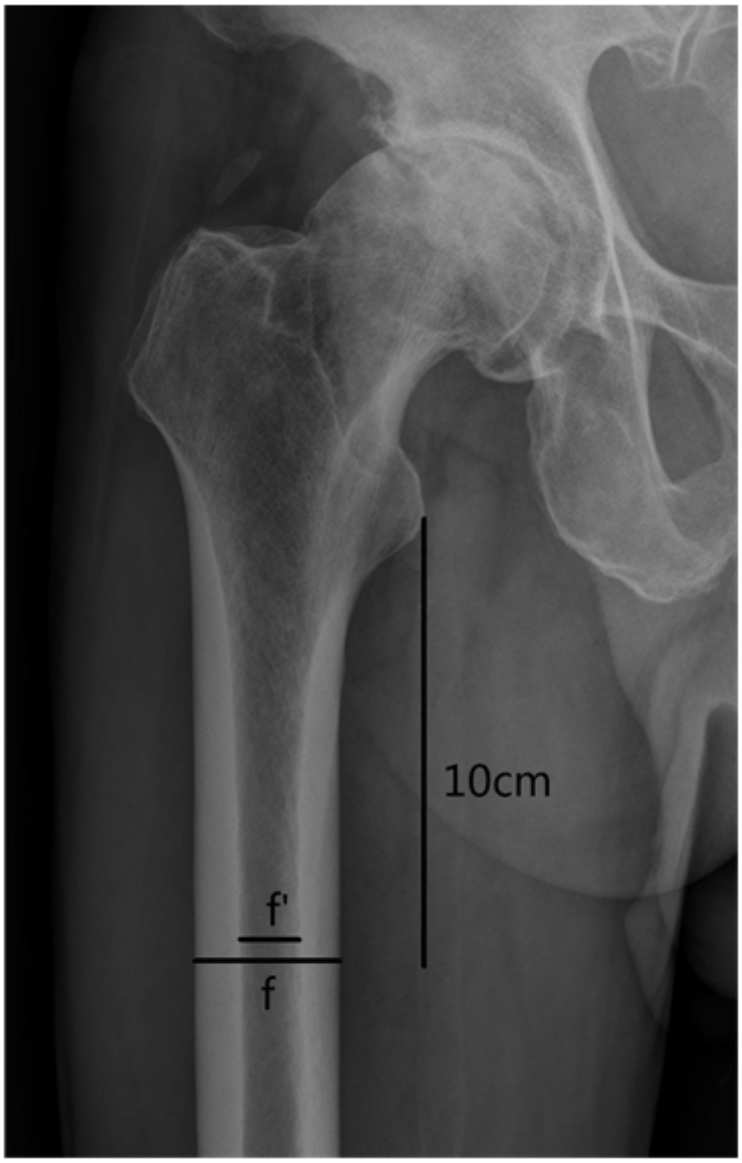

Figure 3

f = cortical width at a level of 10cm below the tip of the lesser trochanter; f'= endosteal width at a level of 10cm below the tip of the lesser trochanter. Femoral cortical index (FCI) = (f-f')/f