Analysis of Corneal Refractive Surgery in Soldiers from a Specific Region, China

Wei-Yang Shao
Chinese PLA General Hospital https://orcid.org/0000-0003-3032-4498

Hong-Zhen Jia
Chinese PLA General Hospital

Bei Cui
Chinese PLA General Hospital

Li-Qun Cao
Chinese PLA General Hospital

Li-Wei Qin
Chinese PLA General Hospital

Gui-Ming Zang
Sixth Medical Center of PLA General Hospital

Chun-Yu Tian (piscestcy@hotmail.com)
Chinese PLA General Hospital https://orcid.org/0000-0002-2909-1773

Research

Keywords: corneal refractive surgery in soldiers, complications, physical examination in soldiers

Posted Date: November 24th, 2020

DOI: https://doi.org/10.21203/rs.3.rs-112890/v1

Abstract

Background: Increasing numbers of young people of the appropriate age are joining the army after vision improvement by refractive surgery. However, there is little research on the long-term influence of this population and the potential impact on mission capability.

Methods: A cluster sampling survey was conducted. The respondents were soldiers who planned to apply for military academies in a specific region of China in 2020. According to the *Physical Examination Standards for Citizens Eligible for Enlistment* and the *Physical Examination Law for Citizens Eligible for Enlistment*, a medical history inquiry, vision examination, color vision examination, slit-lamp examination, and personal interview were performed to obtain information regarding the patients' preoperative myopia, corneal refractive surgery method used, operation time, and symptoms of postoperative discomfort.

Results: Among the 1263 soldiers who underwent the physical examination, 435 soldiers (862 eyes) had a history of corneal refractive surgery, accounting for 34.44%. Among the soldiers with a history of corneal refractive surgery, the treatment of preoperative low-grade myopia accounted for 41.61%, moderate-grade myopia accounted for 43.68%, and high-grade myopia accounted for 14.71%. Regarding the surgical methods used, small incision lenticule extraction (SMILE) accounted for 23.44%, excimer laser in situ keratomileusis (LASIK) accounted for 66.67%, and trans-epithelial photorefractive keratectomy (PRK) accounted for 9.89%. The postoperative time was 2.76 ± 1.01 years. Soldiers with uncorrected visual acuity (UCVA) ≤ 4.9 accounted for 3.94%, and soldiers with UCVA > 4.9 accounted for 96.06%. Slit-lamp examination found no surgical complications affecting visual function, such as dry eye syndrome, corneal infection, corneal haze (above grade 3), and corneal epithelial implantation.

Conclusion: The proportion of soldiers who have undergone corneal refractive surgery has significantly increased, and LASIK is the main surgical method used. The impact of complications related to corneal refractive surgery on the army should be emphasized, and health education and reasonable training should be strengthened to avoid eye-related diseases.

Background

With the increasing proportion of myopia among young people in China and the development of corneal refractive surgery, increasing numbers of people are choosing to undergo corneal refractive surgery to improve their vision. Many young people with poor vision join the army after undergoing vision improvement through surgery. Previous studies reported on the complications of soldiers in a short period of time after corneal refractive surgery. However, there are few reports on the long-term visual function and complication of soldiers. Soldiers especially for who are about to hold special positions in the army and receive more professional training, comprise a special professional group that requires high visual ability, and they face a significantly higher probability of eye injuries than other people. Research on the status of corneal refractive surgery in these soldiers and targeted eye health education and differentiated management are of practical significance for reducing surgery-related training injuries. In this paper, a

survey of corneal refractive surgery was conducted among soldiers in a specific region of China, and the analysis results are reported.

Materials And Methods

Clinical data: The respondents were soldiers who applied to enter military academies from various military units in a specific region in China in 2020. Cluster sampling collected 1263 respondents, including 1122 males and 141 females, with an age range of 19–25 years (average 22.0) and an average enlistment time of 3.20 years.

Methods: This study was conducted in accordance with the relevant contents of the *Physical Examination Standards of Citizens Eligible for Enlistment* and the *Physical Examination Law for Citizens Eligible for Enlistment* issued by the Ministry of National Defense. A standard logarithmic visual acuity chart (2.5 m, 5-point recording method) was used to examine distance vision; a color blindness checklist (fifth edition, People's Medical Publishing House, painted by Yu Ziping et al.) was employed for the color vision examination; a slit-lamp was used to examine the cornea, iris, and lens; and inquiry was employed to obtain information on the participants' medical history and ocular surgery history. Spherical equivalent (SE) was calculated as follows: SE = diopter of spherical power (DS) + 1/2 diopter of cylindrical power (DC). According to the surgical mechanism and potential complications, this study divided corneal refractive surgeries into three groups: 1. small incision lenticule extraction (SMILE); 2. laser keratomileusis, including excimer laser in situ keratomileusis (LASIK) and femtosecond excimer laser in situ keratomileusis (Fs-LASIK); 3. epithelial photorefractive keratectomy (PRK), including trans-epithelial photorefractive keratectomy (Trans-PRK). The study mainly used slit-lamp examination to observe postoperative changes in corneal characteristics and the medical history inquiry method to determine the surgery method.

Results

The proportion of respondents who had undergone corneal refractive surgery and their vision information are shown in Table 1. A total of 1263 soldiers underwent physical examination (1122 males and 141 females), and 435 soldiers (862 eyes, 34.44%) had a history of corneal refractive surgery, including 386 males (34.40% of all males) and 49 females (34.75% of all females). The postoperative time was 3.00 ± 1.03 years for males, 2.75 ± 0.82 years for females, and 2.80 ± 1.02 years for all soldiers. Regarding uncorrected visual acuity (UCVA), 34 eyes were ≤ 4.9 (4.6, 4.7, 4.8, 4.9 in 1, 3, 8, 22 eyes, respectively,) accounting for 3.94%, and 828 eyes were ≥ 5.0, accounting for 96.04%. Among the 34 eyes with UCVA ≤ 4.9, 6 eyes had low diopter power (SE > -3.0D), 15 eyes had moderate diopter power (-6.0D < SE ≤ -3.0D), and 13 eyes had high diopter power (SE ≤ -6.0D) before surgery.

Table 1
General of 435 soldiers had a history of corneal refractive surgery

Sex	Total	Surgical	Ratio	Postoperative Time (years)	UCVA ≤ 4.9(eyes)	UCVA>4.9 (eyes)
Male	1122	386	34.40%	3.00 ± 1.03	29	737
Female	141	49	34.75%	2.75 ± 0.82	5	91

The surgical methods used for different diopters are shown in Table 2. Among the 435 soldiers, SMILE accounted for 23.44%, LASIK accounted for 66.67%, and PRK accounted for 9.89%. A total of 181 soldiers (41.61%) had low-grade preoperative SE (SE >-3.0D), and SMILE, LASIK and PRK accounted for 10.11%, 26.89% and 4.60% of these soldiers, respectively; 190 soldiers (43.68%) had moderate-grade preoperative SE (-6.0D < SE ≤ -3.0D), and SMILE, LASIK and PRK accounted for 9.65%, 29.44% and 4.6% of these soldiers, respectively; 64 soldiers had high-grade preoperative SE (SE ≤-6.0D), and the SMILE, LASIK and PRK accounted for 3.68%, 10.34% and 0.69%, respectively. Five soldiers had Implantable Collamer Lens (ICL) implantation, which was not considered corneal refractive surgery, and 19 soldiers had hypochromatopsia with normal ability to recognize single colors. The slit-lamp examination found no complications affecting visual function, such as dry eye syndrome, corneal infection, corneal haze (above grade 3), and corneal epithelial implantation.

Table 2
Different refractive surgery style of 435 soldiers

SE Interval	Quantity	Ratio	Refractive surgery		
			SMILE	LASIK	PRK
total	435	100%	102(23.44%)	290(66.67%)	43(9.89%)
>- 3.0D	181	41.61%	44(10.11%)	117(26.89%)	20(4.60%)
-3.0D ~ − 6.0D	190	43.68%	42(9.65%)	128(29.44%)	20(4.60%)
≤ − 6.0D	64	14.71%	16(3.68%)	45(10.34%)	3(0.69%)

SE: Spherical Equivalent; **SMILE**: Small Incision Lenticule Extraction; **LASIK**: Laser in Situ Keratomileusis; **PRK**: PhotoRefractive Keratectomy.

Discussion

The proportion of soldiers who have undergone corneal refractive surgery has increased significantly. According to the 2018 national survey of myopia in children and adolescents in China, the overall myopia rate in adolescents is 53.6%; 81% of those affected are high school students, and 21.9% of senior high school students have hypermyopia (SE ≤ -6.0D), indicating that myopia has become a critical issue affecting eye health. To meet the vision requirements in the *Physical Examination Standards for Citizens Eligible for Enlistment*, many young people choose to undergo corneal refractive surgery before joining

the army. In 2008, a re-examination of eye diseases in 20320 recruits in the field forces found that 3.24% of recruits underwent refractive surgery before enlistment [1]. A survey of 4579 recruits who enlisted in the army in 2013 found that 12.3% underwent refractive surgery [2]. In 2015, the proportion of recruits who had undergone corneal refractive surgery was 15.32% [3]. Another survey of 526 recruits in 2015 found that 13.1% of them underwent corneal refractive surgery before enlistment, and those with low- and moderate-grade myopia accounted for 61.6% [4]. This study found that among the soldiers who had an average time since enlistment of 3.20 years and had undergone corneal refractive surgery, 34.40% were male, and 34.75% were female. The shortest postoperative time was 1 year, and the longest was 6 years, with an average of 2.76 years. An analysis of recruits' physical examinations over the years showed that the proportion of soldiers who had undergone corneal refractive surgery increased gradually (Fig. 1). With the development of refractive surgery, the proportion of soldiers undergoing corneal refractive surgery could become even higher in the future. Compared with the no surgery group, the soldiers who had undergone refractive surgery showed differences in corneal thickness, corneal curvature, and biomechanics. At present, there is still a lack of large sample size studies on the impact of corneal refractive surgery on military officers and soldiers. Regarding physical examinations, the available eye examination items and indicators can no longer fully reflect the visual functioning of officers and soldiers. Regarding military training, daily management, and health education, it is necessary to further clarify whether differentiated management is needed for soldiers who have undergone corneal refractive surgery. In particular, the safety of corneal refractive surgery and the impact of its complications on the functions of military officers and soldiers should be emphasized.

Although corneal refractive surgery can significantly improve the UCVA, it is also associated with visual regression and other complications. This study found that among the 862 eyes that underwent corneal refractive surgery, 34 (3.94%) showed visual deterioration, with UCVA < 5.0; furthermore, among these 34 eyes, 82.35% had moderate and high diopters preoperatively. The increased proportion of people undergoing corneal refractive surgery has led to an increase in common complications, such as xerophthalmia, glare, poor contrast sensitivity, and night vision disorders [3, 5, 6]. Among soldiers who have undergone corneal refractive surgery, 28% have experienced xerophthalmia compared to 6% of soldiers who have not undergone refractive surgery, indicating that the surgery group has more than 4 times the rate of xeropthalmia that the non-surgery group [7]. Soldiers often work in special environments for long periods, and their irregular rest times both during the day and at night can easily worsen xerophthalmia and asthenopia. The medical team should strengthen health education, pay attention to the healthy use of eyes, and arrange for reasonable tasks. Artificial tears medicine and other reserved drugs can be appropriately used if there is a high incidence of such complications.

With the emergence of new surgical techniques, such as SMILE and Trans-PRK, the methods of corneal refractive surgery have become diversified in recent years. This study found that among 435 surgeries, LASIK was the main surgical method for low-, moderate-, and high-grade myopia, accounting for 66.67%; SMILE was a widely used method for low- and moderate-grade myopia, accounting for 23.44%; PRK accounted for only 9.9%, and although it was mainly used for low- and moderate-grade myopia, a small

number of soldiers with high-grade myopia did use it. Different surgical methods have different complications and postoperative risk factors. Studies have found that the proportion of glare and night vision disorders after corneal refractive surgery is 23%; LASIK results in the highest rate of these disorders, at 33% [8]. Dennis et al. [9] found that after PRK, slight haze can cause decreased visual acuity under complex light interference and can decrease contrast sensitivity under normal conditions and complex light interference, which directly influences performance capacity. This study did not find haze (above grade 3), which can negatively impact vision, in the soldiers; however, haze (grade 1–2) was common among the soldiers on slit-lamp examination. Soldiers who have undergone corneal refractive surgery often have a high risk for potential ocular trauma, especially those who have undergone LASIK. An investigation of 1131 hospitalized soldiers with ocular trauma at 27 military hospitals from January 2006 to December 2010 found that among 3 soldiers who had undergone radial keratotomy (RK), 2 soldiers had eyeball ruptures; among 72 eyes that had undergone LASIK, 69 eyes had mechanical ocular trauma, and 29 eyes had corneal flap dislocation [2]. LASIK is a surgical method that uses excimer lasers to perform refractive cutting of the stromal layer of the corneal flap to correct refractive errors. It has advantages of safety, reliability, predictable vision, and strong stability [10]. However, this surgery affects the corneal stroma flap. Even after many years, the tissue healing of the corneal flap and corneal stroma might not achieve a normal state since the postoperative healing reaction of the two is negligible; therefore, corneal flap displacement and wrinkles are more likely to occur [11]. Soldiers are often involved in vigorous exercises and fights, so the eye injury rate in soldiers is significantly higher than that normal people, making a weakly healed corneal flap more vulnerable to injury [12]. Corneal flap displacement and wrinkles are more likely to occur after trauma and impacts and can result in impaired vision due to complications such as keratitis and epithelial implantation. In addition, the treatment effect is poor because the lack of obvious early symptoms means these complications cannot be diagnosed and treated in a timely manner [13]. This study found that a soldier had accidentally injured his eyes during training 1 year after undergoing LASIK and had suffered corneal epithelial implantation (Fig. 2). Because of the negligible impact on the UCVA in the early stage, the patient did not seek medical care until 1 year after the onset, which caused great difficulty in treatment. SMILE can avoid the complication of corneal flap displacement, has faster postoperative vision recovery and less incidence of xerophthalmia than LASIK, and has become very popular in recent years [14, 15]. The complications are different for different surgical methods, and their influences on performance capacity are different due to different surgical mechanisms. Therefore, hierarchical management should be considered for different corneal refractive surgeries to effectively reduce the influence of such surgeries on military operations and complications related to corneal refractive surgery, thereby avoiding military training injuries.

For patients with hypermyopia, corneal refractive surgery cannot improve fundus lesions. At present, there are no clear requirements regarding the degree of myopia required in soldiers before corneal refractive surgery during military physical examination. In this study, preoperative high-grade myopia (SE ≤ -6.0D) was present in 14.71% of the soldiers who had undergone refractive surgery. Some studies pointed out that there was a high probability of retinal degeneration, lattice degeneration, and retinal detachment after surgery [16]. A study reported that 658 soldiers who had undergone refractive surgery experienced a

significant increase in visual deterioration, retinal detachment, and retinal tears after 2 years of enlistment [1]. Therefore, hierarchical management should be performed in response to the different corneal refractive surgery methods and the collected information regarding the preoperative diopter and eye disease history. Especially for those with a high degree of myopia before surgery, special attention should be paid to the fundus; regular dilatation examinations should be performed for the early detection and intervention of retinopathy so that serious complications, such as retinal tear and retinal detachment, can be avoided.

Although implantable contact lenses (ICLs) can significantly improve vision and have obvious advantages in the treatment of high-grade myopia, there are relatively high risks of postoperative cataracts, glaucoma, corneal endothelial decompensation, lens dislocation, and decreased visual quality [17]. Therefore, applicants who have undergone ICL implantation are considered “unqualified” in the physical examination for citizens eligible for enlistment, and aspiring soldiers should think twice before choosing this refractive surgery method. This study found that 5 soldiers had hypochromatopsia with normal single-color recognition ability, and they all had a history of corneal refractive surgery. Li et al. reported that intraocular scattering can be changed after LASIK, causing symptoms such as halo, starburst, decreased contrast sensitivity and impaired color vision recognition ability [18]. Whether corneal refractive surgery can impair color vision and cause other changes in binocular visual function must be clarified in further systematic studies.

Conclusion

Corneal refractive surgery is an essential treatment for myopia, and refractive surgery methods are continuously being developed. Soldiers who have undergone corneal refractive surgery accounted a considerable proportion in the army. We surveyed the corneal situation of soldiers who postoperative time was about 3 years and found some interesting results, while which need to be further studied and longer-term observation. Individualized requirements for corneal refractive surgery should be defined in the physical examination for citizens eligible for enlistment and standardized inspection items to ensure that the army recruits high-quality soldiers. At the same time, differentiated and refined management and training in the army is also a topic that needs further discussion and attention.

Abbreviations

SMILE: Small incision lenticule extraction；LASIK: Laser in situ keratomileusis；PRK: Photorefractive keratectomy；UCVA: Uncorrected visual acuity；SE: Spherical equivalent；DS: Diopter of spherical；DC: diopter of cylindrical；ICL: Implantable collamer lens；RK: Radial keratotomy.

Declarations

Ethics approval and consent to participate

The study was approved by the Ethics Committee of the 6th Medical Centre of Chinese People's Liberation Army General Hospital. All patients gave informed consent and agreed to participate in the study.

Consent for publication

Not applicable.

Availability of data and materials

The data and materials used in the current study are all available from the corresponding author upon reasonable request.

Conflicts of Interest

All authors declare no financial conflict of interests.

Funding

Foundation: This study was supported by the Innovation Cultivating Foundation of 6th Medical Centre of PLA General Hospital (no. CXPY2017020) and clinical special application research of capital of China (No. Z171100001017172).

Authors’ contributions

Authors' Contributions: WYS, CYT contributed to data analysis, manuscripts preparation and revised version. WYS, HZJ and BC contributed the data colleting. LQC, LWQ, GMZ given some good advices in project design and manuscripts revision.

Acknowledgments

The authors thank all colleagues of Health Management Center for their assistance.

References

1. Ma C, Li XY, Huang JC, Tang LP, Zhang XW, Wei SH. Survey and Analysis of Oculopathy in Recruits of Field Troops. J Clin Med. 2008; (04):631–632.
2. Xiao JH, Jiang H, Li SY, Huang X, Ma KF, Hui J. A survey of laser corneal refractive surgery for recruits enlisted in a certain department in 2013. People Mil Surg. 2014;57(12):1282–4.
3. Du GP, Li Z, Song MX, Liu XC, Huang YF. Survey and analysis of the situation of refractive surgery in navy recruits. Chin J Naut Med ï¼ Hyperbar Med. 2017;24(02):97–9 + 126.
4. Liu YT, Wu ZH, Qin XY, Du FF, Han B, Wu HQ, Wang P. Analysis of the eye reexamination of recruits enlisted in a certain unit in 2015. People Mil Surg. 2016;59(12):1228–30.

5. Xu MY, Hu Q. Analysis of visual quality after LASIK operation in myopia patients. Chinese Journal of Strabismus Pediatric Ophthalmology. 2020;28(01):47–8.
6. Xiao JH, Zhang MN, Jiang CH, Zhang Y, Qiu HY. Laser in situ keratomileusis surgery is not safe for military personnel. Chin J Traumatol. 2012;15(2):77–80.
7. Lu SZ, Fan M, Zhang CM, Huang HY. An investigation of dry eye syndrome after excimer laser corneal refractive surgery in recruits of a certain armed police force. Med J Chin Peop Arm Pol For. 2012;23(12):1078–9 + 1082.
8. Zhong MR, Tang XW, Liu Y, Li J, Liu X, Liu SS. Survey and analysis of corneal refractive surgery of air force maintenance officers and soldiers in western theater. Medical Journal of National Defending Forces in Southwest China. 2019;29(10):1088–90.
9. Dennis RJ, Beer JM, Baldwin JB, Ivan DJ, Lorusso FJ, Thompson WT. Using the Freiburg Acuity and Contrast Test to measure visual performance in USAF personnel after PRK. Optom Vis Sci. 2004;81(7):516–24.
10. Wen D, McAlinden C, Flitcroft I, et al. Postoperative Efficacy, Predictability, Safety, and Visual Quality of Laser Corneal Refractive Surgery: A Network Meta-analysis. Am J Ophthalmol. 2017;178:65–78.
11. Khoueir Z, Haddad NM, Saad A, et al. Traumatic flap dislocation 10 years after LASIK. Case report and literature review. J Fr Ophtalmol. 2013;36(1):82–6.
12. Gao HR, Jiang H, Lu M, Guo Q, Xu XY. Treatment of mid- and long-term corneal flap displacement after LASIK. Proceedings of the 17th Ophthalmology Conference of Shandong Province. 2013:271.
13. Qin J, Wang YL, Song BJ. Efficacy of reduction treatment after LASIK corneal flap displacement. Chin J Pract Ophthalmol. 2016;34(10):1106–8.
14. Tang H, Wang SJ. Effects of SMILE and FS-LASIK on the stability of cornea and tear film in the treatment of high myopia. Chin J Pract Med. 2019; (22):78–80.
15. Zheng Y, Zhou YH, Zhang J, Zhang L, Zhai CB, Hu YB, Liu J, Wang Y. Comparison of visual quality after FS-LASIK, WF-LASIK and SMILE. Chin J Ophthalmol. 2020; (02): 118–125.
16. Liu H, Zhao HX, Li SR. Research progress of pathological changes in posterior segment of eye after LASIK. Journal of Diseases Monitor Control. 2009;3(05):304–6.
17. Liu H, Li PH. Complications related research progress refractive lens can be implanted posterior chamber. Medical Recapitulate. 2015;21(19):3539–41.
18. Li J, Wang Y, Xie LL, Xue C, Wang YL, Geng WL, Jin Y, Yang XY. Scattering characteristics before and after excimer laser subelastomeric keratomileusis and analysis of related factors. Chin J Optom Ophthalmol Vis Sci. 2012; (01): 12–15.

Figures

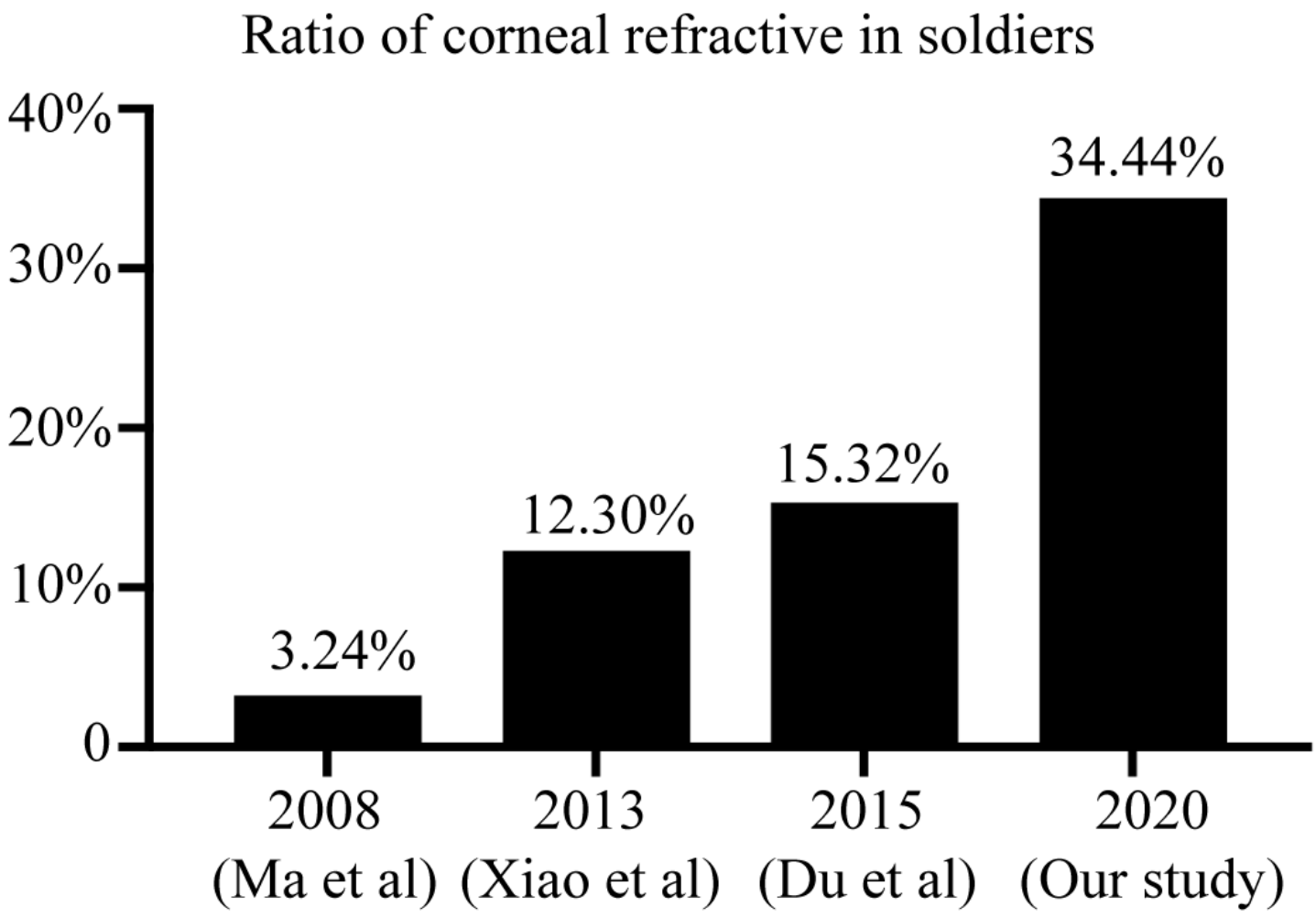

Figure 1

The change of ratio of corneal refractive in soldiers.

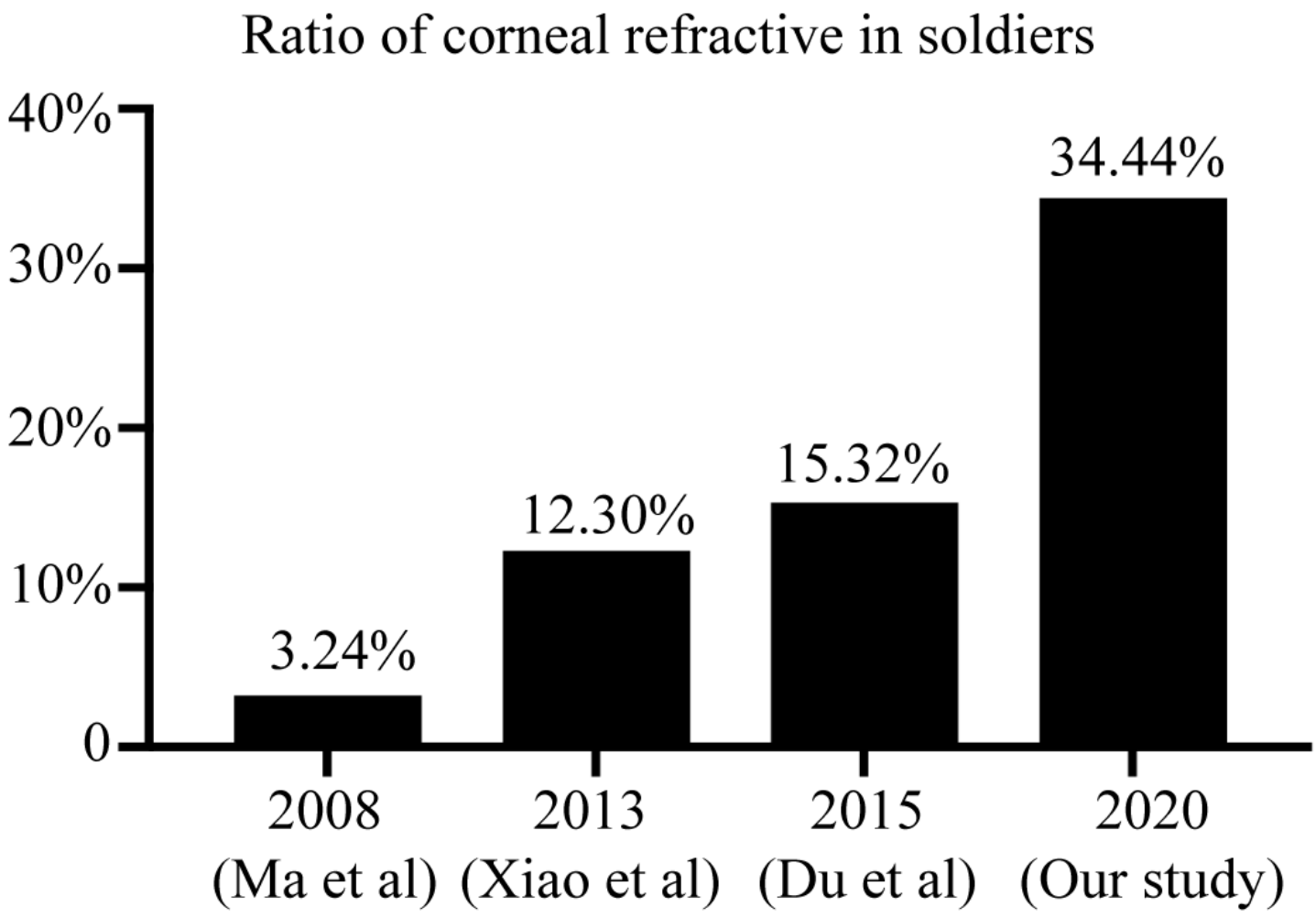

Figure 1

The change of ratio of corneal refractive in soldiers.

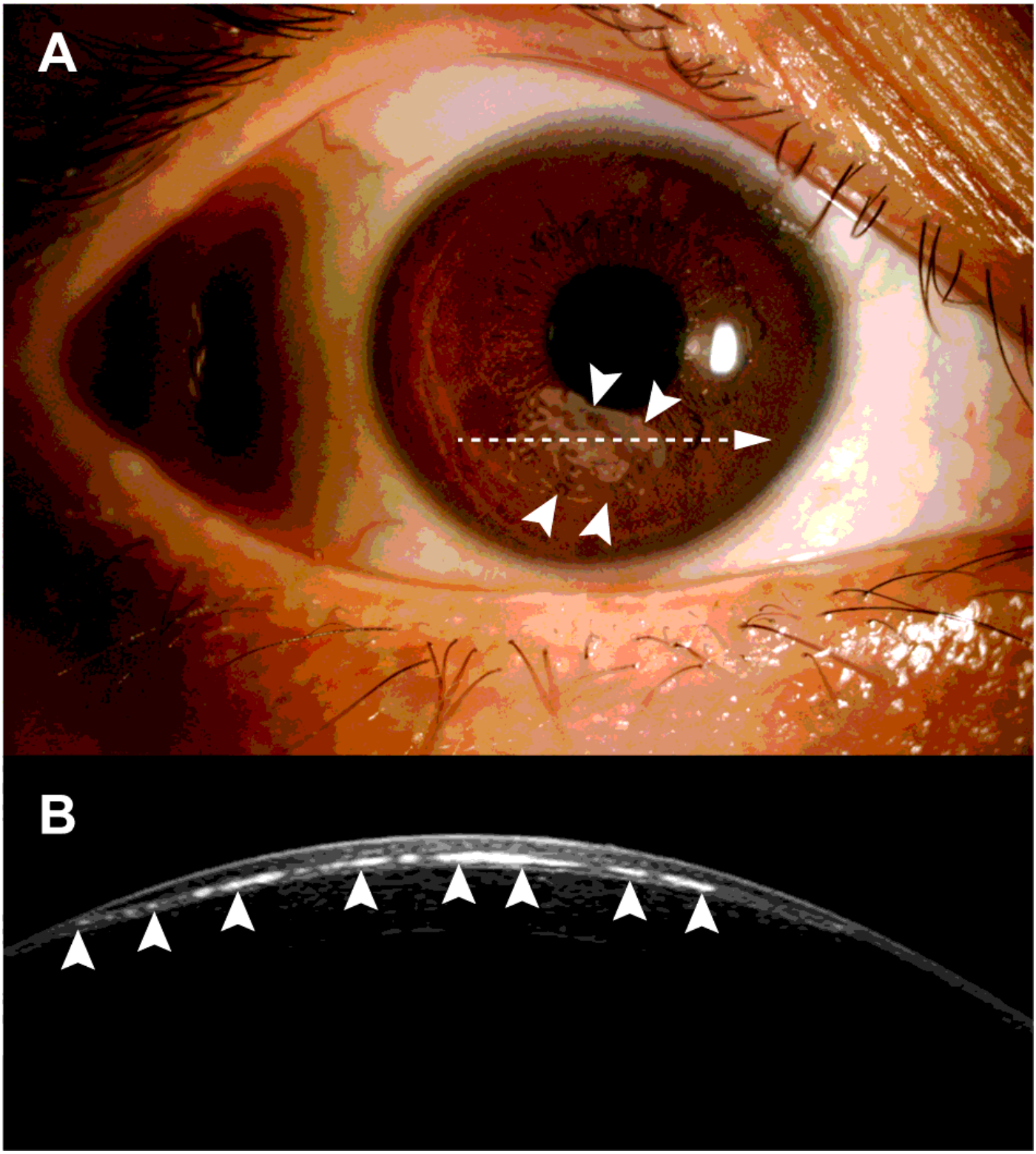

Figure 2

Epithelial implantation after corneal refractive surgery. A: Color photo of the ocular surface; the horizontal arrow and dotted line is the position shown in B. B: Optical coherence tomography of the cornea; the white arrow indicates the implanted epithelial area.

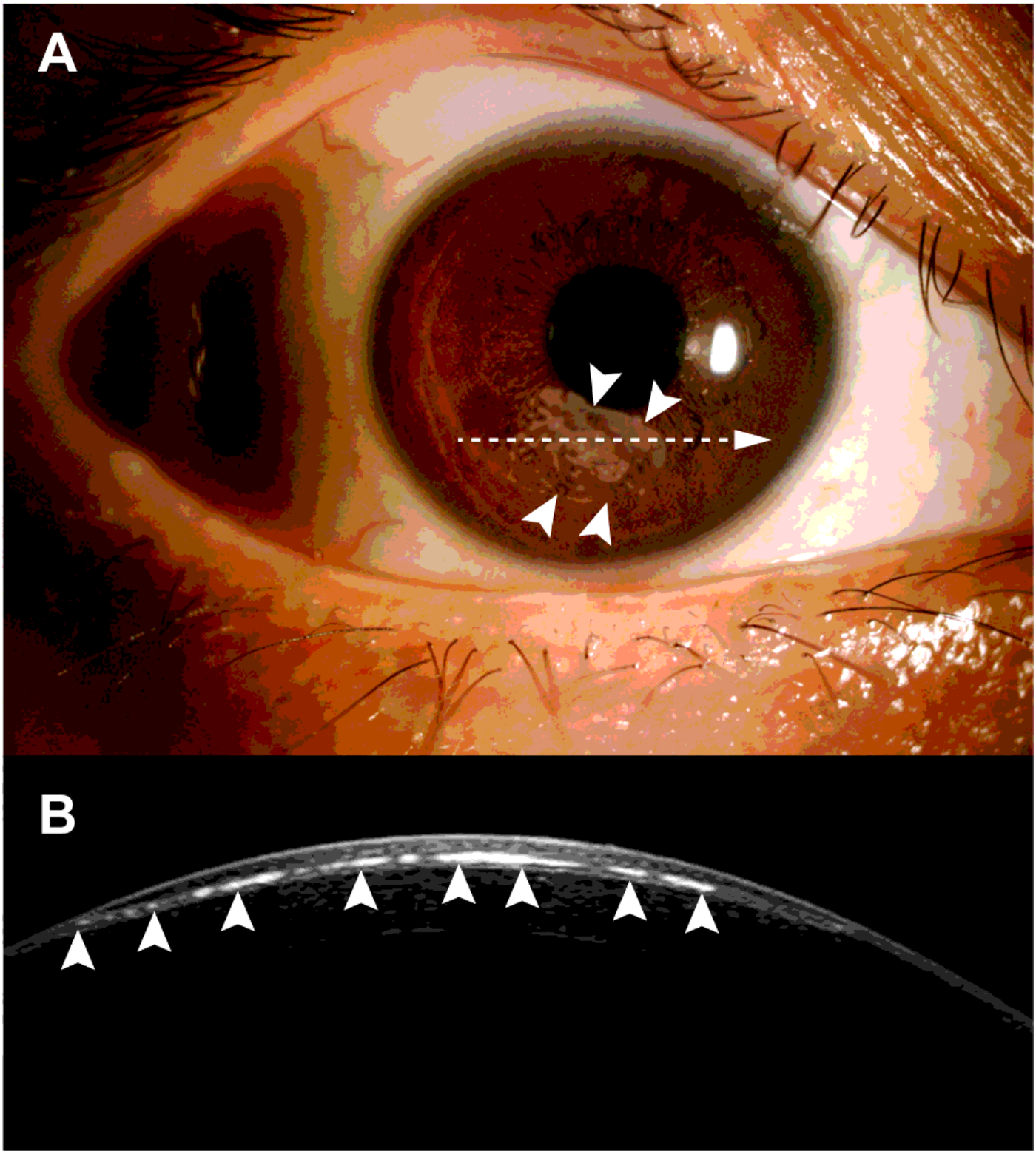

Figure 2

Epithelial implantation after corneal refractive surgery. A: Color photo of the ocular surface; the horizontal arrow and dotted line is the position shown in B. B: Optical coherence tomography of the cornea; the white arrow indicates the implanted epithelial area.