# Distal Insertion Rupture of Lateral Ankle Ligament as a Predictor of Weakened and Delayed Sports Recovery after Acute Ligament Repair: Mid- to Long-Term Outcomes of 148 Cases

**Mingze Du**
Peking University Third Hospital. Institute of Sports Medicine of Peking University
**Jun Li**
Tai'an Central Hospital of Shandong Province
**Chen Jiao**
Peking University Third Hospital. Institute of Sports Medicine of Peking University
**Qinwei Guo**
Peking University Third Hospital. Institute of Sports Medicine of Peking University
**Yuelin Hu**
Peking University Third Hospital. Institute of Sports Medicine of Peking University
**Dong Jiang** ( bysyjiangdong@126.com )
Peking University Third Hospital. Institute of Sports Medicine of Peking University

**Research Article**

**Keywords:** acute ankle sprain, lateral ankle ligament, anatomic ligament repair, return to play, arthroscopy.

**Posted Date:** December 16th, 2021

**DOI:** https://doi.org/10.21203/rs.3.rs-1130309/v1

## Abstract

# Background

Surgical repair has been considered for ankle sprain patients with high sports demanding to achieve stronger ankle stability and allow for an earlier return to sports. However, there is a lack of systematic research regarding arthroscopic treatment followed by ligament repair for severe acute ankle sprain. The purpose of this study was to analyze the mid- to long-term outcome of arthroscopy followed by open anatomic lateral ankle ligament repair surgery for acute lateral ankle sprain and the impact of ligament rupture site on the outcome.

# Methods

166 professional or semi-professional athletes with clinically- and radiologically-confirmed grade III acute lateral ankle ligament injuries underwent ankle arthroscopy followed by open anatomic ligament repair. Intra-articular lesions and rupture site of the lateral ankle ligament were treated and explored under arthroscopy. Simple suture repair was performed for mid- substance ligament rupture (middle group), while suture repair with anchors were used for the ruptures near the ligament attachment site on the fibular (proximal group), talar or the calcaneal side (distal group). The evaluation parameters included VAS score, AOFAS score, Tegner score, time to return to sports and resumption of pre-injury sports level at final follow-up, sprain recurrence and range of motion (ROM).

# Results

The mean follow-up duration was 64.5 (range, 37–132 months) months and 148 (89.2%) patients were evaluated at final follow-up. Intra-articular lesions were treated under arthroscopy in 63 (43%) patients. The average time to return to pre-injury sports activity was 4.37 ± 1.10 months and 17 (11.5%) patients complaint sprain recurrence after operation. There were 71 (48%) cases in the proximal group, 46 (31%) cases in the middle group and 31 (21%) cases in the distal group respectively. The proximal group achieved shortest time to return to sports (4.14 ± 1.09 months) and highest resumption proportion of pre-injury sports level (94% ± 11%) at final follow-up, followed by middle group (89% ± 15%, 4.61 ± 0.93 months, respectively) and distal group (87% ± 13%, 4.53 ± 1.29 months, respectively) ($p$ =0.008, $p$ =0.04, respectively). At final follow-up, all of the VAS score, AOFAS score and the Tegner score were significantly improved from the pre-operative level ($p < 0.001$). 18 (12%) patients reported mild ROM restriction and 7 (4.7%) patients experienced transient skin numbness.

# Conclusions

Ankle arthroscopy followed by open anatomic ligament repair is a reliable procedure for patients with high sports demands after severe acute ankle sprains. Rupture near the talar or calcaneal side weakened the sports resumption and delayed about 2 weeks of sports recovery.

# Introduction

Ankle sprain is one of the most common sports injuries[1]. It is estimated that ankle varus injury occurs in 10 000 people per day[2], and ankle sprains accounted for 7–10% of the number of attendances in an emergency department[3]. Improper management of ankle sprains can increase the risk of developing chronic ankle instability. During the last decade, rehabilitation with optimal loading in a brace was advocated for most ankle sprains[4]; however, treatment for grade III injuries is controversial. Surgical repair has been considered for patients with high sports demanding [5] to achieve stronger ankle stability and allow for an earlier return to sports after repair compared with non-operative treatment.

Previous studies using open surgery reported a high rate (10–30%) of complications after acute lateral ankle ligament repair, such as range of motion (ROM) restriction, wound problems, and nerve injuries[6]. However, most of these reports were studies performed before the advent of arthroscopy, and the long-term outcomes were limited[7]. Recently, ankle arthroscopy has been recommended for better evaluation and management of associated intra-articular injuries. In addition, for acute ankle sprains, the ligament rupture site can be observed under arthroscopy to guide the choice of incision and then reduce the length of the incision and its complications[8]. However, there is a lack of mid- to long-term outcome follow-up regarding arthroscopic treatment followed by ligament repair for severe acute ankle sprain.

The most involved structure of acute lateral ankle sprain are anterior talofibular ligament (ATFL) and calcaneofibular ligament (CFL)[9]. The tear of the ligament may occur on the mid- substance or near the insertion site of the fibula, talus, or calcaneus. Due to differences in anatomy and blood supply, there are differences in the healing time and healing ability of different injured parts[10], which may affect the postoperative rehabilitation and outcome, especially the time and degree of return to sports. However, so far there is no research on the impact of the rupture site on the long-term outcomes of the operation.

In the present study, patients with grade III acute lateral ankle ligament injuries underwent arthroscopic management of intra-articular lesions followed by open anatomic ligament repair. The purpose of this study was to evaluate the mid- to long-term outcome of the procedure for acute lateral ankle sprain and the impact of ligament rupture site on the outcome. It was hypothesized that concurrent arthroscopy and open ligament repair would achieve overall good mid- to long-term results and the outcomes might differ at different rupture sites. The study could also provide a reference for postoperative rehabilitation after acute lateral ankle ligament repair.

# Materials And Methods

# Patients recruitment

Most of the lateral ankle sprain patients accepted conservative treatment (rest, icing, compression, elevation, etc) and rehabilitation exercise. Those professional or semi-professional athletes with grade III lateral ankle ligament rupture (interval from trauma to surgery less than 2 weeks) were informed that they had the option of surgery. After thoroughly informed of the risks of surgery, the patients choosing surgery underwent arthroscopy and open anatomic ligament repair. Those accepting surgeries between June 2007 and May 2017 were enrolled. Patients were excluded if: (1) the sprain was accompanied by a fracture requiring internal fixation, (2) osteochondral lesions (OCL) requiring tissue transplantation rather than debridement or microfracture were present, (3) they had a history of previous operations to the index ankle, and (4) they had a sprained ankle on the opposite side. The research was approved by the IRB Medical Committee (IRB00006761-2016011), and written informed consents were obtained from the subjects.

# Surgical technique

All patients were operated by the same surgeon (JD). Under general or spinal lumbar anesthesia, all patients underwent arthroscopic exploration and necessary management of intraarticular lesions before ligament repair. Suture repair was performed for patients with mid- substance ligament ruptures, and suture repair with anchor was performed for patients with ruptures near the ligament attachment. OCLs were carefully measured with a marked probe and classified according to Ferkel and Cheng's classification[11]. Debridement of rough or fibrillated cartilage was performed in patients with stage B–C lesions using a mechanical shaver (Dyonics Power Shaver System; Smith & Nephew, Andover, MA). For stage D–F lesions, bone marrow stimulation consisting of abrasion, curettage, drilling, and microfracture was performed in addition to debriding the flapped cartilage. Other lesions (synovial hyperplasia, impingement, loose bodies) were also treated under arthroscopy. The ligament tear site was then assessed to guide the incision location.

After ankle arthroscopy, a slightly curved longitudinal incision was made 3–4 cm above the distal tip of the fibula, which was guided by the ligament tear site observed under arthroscopy. The incision for talar tears of the ATFL was more prone to anterior, and the incision for calcaneal tears of the CFL was more prone to distal. Care was taken to avoid the intermediate branch of the superficial peroneal nerve and sural nerve (**Fig. 1**). The ATFL and CFL were exposed to evaluate the injured site. Mid- substance ligament ruptures were sutured using a 2-0 polyester braided wire. Ruptures near the ligament attachment were repaired using 1.8-mm diameter suture anchors (Mitek Mini–GII, Johnson & Johnson, NJ), which were positioned at the anatomic insertion site in the distal fibula, anterolateral talus, or calcaneus. For tears on the calcaneal side, a suture anchor was inserted at the insertion site, then the ligament was braided and pulled underneath the peroneal tendon and fixed with the anchor wire (**Fig. 2**). For < 1 cm diameter avulsion fractures, we carefully peeled the ligaments from the surface and resected the fracture fragment, then sutured the ligament tissue to the bone surface with anchors (**Fig. 3**). The extensor retinaculum was then sutured to the fibular periosteum. ROM, anterior drawer, and talus tilt were assessed, and finally, the ankle joint was immobilized with a splint in slight dorsiflexion and eversion.

According to the rupture site, patients were classified into a proximal group (rupture at the fibular end), mid-substance group (rupture of the mid-substance), and distal group (rupture near the talar or calcaneal insertion site). When two or more sites were injured, the classification criteria were as follows: ruptures involving the fibular side and the mid-substance were classified as the proximal group; ruptures at the talar or calcaneal side and mid-substance were classified as the distal group; and ruptures involving the talus or calcaneus and the fibular side were grouped according to the most severely injured site.

# Postoperative rehabilitation

A splint was applied for the first 3 weeks postoperatively, without weight-bearing. The splint was then replaced with an ankle brace, which remained in place until 8 weeks postoperatively. Passive flexion–extension ROM exercises were started from week 3, and varus traction exercise was allowed from week 5. Full weight-bearing was allowed between weeks 3–5, and patients were advised to return to sports 2–3 months postoperatively. For patients with OCLs, the splint or brace was removed twice a day for full-range continuous passive motion (CPM) exercise from weeks 2–6. Partial weight-bearing was allowed 6–8 weeks postoperatively, with full weight-bearing 8–12 weeks postoperatively.

# Clinical outcomes evaluation

All patients came to the outpatient clinic for regular review in the early postoperative period, and the outcomes were recorded including sports recovery and complications. In the follow-up, if the exercise returns to more than 85% of the pre-injury level, it is recorded as returning to pre-injury sports. The evaluation at final follow-up included a pain visual analog scale (VAS)[12], American Orthopaedic Foot & Ankle Society (AOFAS) score[13], Tegner activity score[14], sprain recurrence, ROM, resumption of pre-injury sports level, patient satisfaction, areas of skin numbness and other complications.

# Statistical analysis

Data were analyzed using SPSS Statistics version 23.0 (IBM Corp., Armonk, NY). The chi-square test or Fisher's exact probability test was used for categorical outcomes, while the paired samples t-test and nonparametric test were used to determine the subjective scores of preoperative and follow-up endpoints and the site of ligament injury on postoperative outcomes. Differences were considered significant at $p < 0.05$. PASS 11.0 (NCSS, US) was used to calculate the sample size.

## Results

Of the 166 patients who met the study inclusion criteria, 148 patients (89.2%) were available for the final follow-up. All eligible patients were included. Post-hoc power analysis revealed that a sample size of 135 could achieve 95% power to detect the observed group difference in recovery of sports. Suture repair was performed for 61 (41%) patients with mid-substance ligament ruptures, and suture repair with anchor was performed for 87 (59%) patients with ruptures near the ligament attachment. Among the 87 cases of injury near the ligament insertion, 71 cases were near the fibular end (including 8 cases of ruptures involving the fibular side and the mid-substance) and 31 cases were near the talus or calcaneus insertion

site (including 16 cases of ruptures at the talar or calcaneal side and mid-substance). 16 (10.8%) patients were professional athletes, namely 7 football players, 4 judo players, 1 tennis player, 1 decathlete, 1 volleyball player, and 1 hockey player. The other 132 patients included college team athletes, semi-professional athletes and coaches.. Under arthroscopy, the intra-articular lesions were treated for 43 (29%) patients with OCLs, 21 (14%) with avulsion fractures, and 15 (10%) with osteophytes (Table 1).

Table 1
Demographic data and characteristics of the 148 patients

| Characteristics | Patient cohort |
|---|---|
| Sex, *n* (%) | |
| Male | 102 (69) |
| Female | 46 (31) |
| Age, years | 27.2 ± 10.3 |
| BMI, kg/m$^2$ | 23.9 ± 3.5 |
| Injury time, days | 7.4 ± 3.7 |
| Follow-up time, months | 46.1 ± 14.3 |
| OCL, *n* (%) | |
| B-C | 22 (15) |
| D-F | 21 (14) |
| Avulsion fracture, *n* (%) | |
| Fibular | 16 (11) |
| Talus | 3 (2) |
| Calcaneus | 2 (1) |
| Medial ligament, *n* (%) | 5 (3) |
| Osteophyte, *n* (%) | 15 (10) |
| Types of ligaments injury, *n* (%) | |
| Isolated ATFL | 29 (19) |
| Isolated CF | 2 (1) |
| ATFL+CF | 117 (80) |
| Ligament tear site, *n* (%) | 71 (48) |
| Proximal group | |
| Middle group | 46 (31) |
| Distal group | 31 (21) |
| Fixation method, *n* (%) | |
| Suture anchor | 81 (55) |

| Characteristics | Patient cohort |
|---|---|
| Simple suture | 67 (45) |

The average time to return to sports activity was 4.37 ± 1.10 months after surgery. Fourteen (88%) of the 16 professional athletes fully resumed their pre-injury competitive levels and participated in national and international competitions. A total of 18 (12%) patients reported mild ROM restriction (<10°), of which two-thirds were plantar flexion limitation; 7 (4.7%) patients experienced transient numbness on the lateral side of the foot related to superficial peroneal nerve irritation, which resolved in 5 patients after 6 months. At final follow-up, all the subjective scores were significantly improved from the pre-operative level ($p < 0.001$). The postoperative VAS, AOFAS and Tegner scores were 0.34 ± 0.88, 98.74 ± 3.15 and 5.04 ± 0.67, respectively (Table 2).

Table 2
Comparison of the pre-operative and the final subjective scores

| | pre-operation | post-operation | *p* value |
|---|---|---|---|
| VAS | 6.14 ± 1.36 | 0.34 ± 0.88 | <0.001* |
| AOFAS | 24.48 ± 8.08 | 98.74 ± 3.15 | <0.001* |
| Tegner | 0.80 ± 0.59 | 5.04 ± 0.67 | <0.001* |
| *Statistically significant difference ($p < 0.05$) | | | |

When comparing the outcome between the three groups by ligament rupture site, significant differences were found for the time of return to sport and the resumption of pre-injury sport level at the final follow-up. The patients in the proximal group showed the best resumption of pre-injury sports level (94% ± 11%, range,50–100%), followed by the mid-substance group (89% ± 15%, range, 50–100%) and the distal group (87% ± 13% range, 50–100%) ($p = 0.008$). Similarly, patients with proximal ligament injuries experienced the shortest time to return to pre-injury exercise, followed by those with mid-substance injury and distal group and those with distal ligament injuries ($p = 0.040$). The distal group returned to sport about 2 weeks later than the proximal group. The proximal group showed the highest ROM restriction occurrence and the distal group showed the highest sprain recurrence but with no significant difference ($p > 0.05$). There was no significant difference in VAS, AOFAS, or Tegner scores between the three groups. (Table 3).

Table 3
Effect of the ligament tear site on postoperative outcomes

| | Proximal group | Middle group | Distal group | *p* Value |
|---|---|---|---|---|
| | (*n* = 71) | (*n* = 46) | (*n* = 31) | |
| Recovery of sports | | | | |
| Percentage (%) | 94 ± 11 | 89 ± 15 | 87 ± 13 | 0.008* |
| Time, months | 4.14 ± 1.09 | 4.61 ± 0.93 | 4.53 ± 1.29 | 0.040* |
| ROM restriction, *n* (%) | 8 (47) | 6 (28) | 4 (25) | 0.966 |
| Sprain recurrence, *n* (%) | 7 (10) | 5 (9) | 5 (17) | 0.539 |
| Satisfaction (%) | 83 ± 9 | 84 ± 8 | 83 ± 11 | 0.996 |
| VAS | | | | |
| pre-operation | 6.17 ± 1.13 | 5.98 ± 1.44 | 6.32 ± 1.70 | 0.656 |
| post-operation | 0.28 ± 0.81 | 0.24 ± 0.67 | 0.61 ± 1.20 | 0.267 |
| AOFAS | | | | |
| pre-operation | 25.38 ± 8.34 | 24.17 ± 7.79 | 22.87 ± 7.76 | 0.286 |
| post-operation | 99.42 ± 1.96 | 98.48 ± 3.79 | 97.58 ± 3.93 | 0.062 |
| Tegner | | | | |
| pre-injury | 5.34 ± 0.61 | 5.52 ± 0.62 | 5.39 ± 0.56 | 0.264 |
| post-operation | 5.00 ± 0.56 | 5.22 ± 0.70 | 4.87 ± 0.81 | 0.074 |
| *Statistically significant difference ($p < 0.05$) | | | | |

# Discussion

The most important finding of this study was that ankle arthroscopic treatment followed by anatomic ligament repair achieved good mid- to long-term results and could be a reliable procedure for patients with high sports demands after severe acute ankle sprains. Rupture near the talar or calcaneal side weakened and delayed sports recovery. The distal rupture returned to sport about 2 weeks later than the proximal rupture.

The results showed the favorable mid- to long-term results of the procedure with good ankle stability and sports recovery for most patients. The results were consistent to most studies of the ligament repair for acute ankle sprain[15]. Although conservative treatment is often performed for grade I & II acute ankle ligament injury[16], the benefit of surgery is gaining evidence for grade III lateral ligament injuries and patients with requirements to return to highly intensive sports. White et al[17] followed up 42 players

undergoing acute lateral ankle ligament repair and the results showed that lateral ligament reconstruction with the modified Broström method was a safe and effective treatment for acute severe ruptures, providing a stable ankle and expected return to sports at approximately 10 weeks. The surgery was more preferred for those with combined ATFL and CFL rupture[17]. Samoto et al[18] assessed the results of nonoperative treatment of acute lateral ligament injury according to its severity, and the result was unsatisfactory in those with combined injuries of the ATFL and CFL. In the present study, 117(79%) patients had both ATFL and CFL ruptures with high demanding of sports recovery, which could be a good indication for this procedure.

Another reason of the favorable results might be due to the arthroscopy, which could explore and treat the intra-articular lesions, especially for the OCLs. In the present study, OCLs were found in 43 (29%) patients, of which there were 15 free osteochondral fragments. The OCLs have been widely recognized as a negative predictor on clinical outcomes of the lateral ankle ligament repair[19–21].

The results of this study suggested that the location of the ligament rupture will affect the recovery of sports and the distal group showed the relatively lower resumption rate of the pre-injury sports activity and showed about 2 weeks delayed return to sport than the proximal group. One of the reasons of the results might be attributed to more involved CFL ruptures in the distal group. Our results showed that proximal injuries were mainly in the ATFL, while distal injuries were mainly in the CFL. Notably, some studies indicated that the recovery after CFL injury was worse than that of ATFL injury[21]. Regarding anatomy, the ATFL that is a flat quadrilateral ligament and incorporated in the joint capsule while the CFL is a cylindrical ligament, and difficulties in recovery relate to its anatomical location beneath the peroneal tendons[22]. Therefore, the ATFL is located more superficially, and is flatter might be easier to heal compared with the CFL[9]. Regarding blood supply, the lateral talar body has worse vascularization than other parts of the talar body, and the lateral blood vessel density is lower than for other parts, which may explain why recovery of ruptures to the end of the talus is not as good[23]. However, there is no direct evidence to prove that the blood supply changes with the ligament rupture site and further research is needed.

It was also founded that 14% (21/148) of the patients had avulsion fractures, and the results showed that removing avulsion fragments with a diameter of < 1 cm did not affect ligament stability. Lateral ankle avulsion fracture was reported to have a potential negative impact on postoperative rehabilitation[24], and patients with avulsion fracture should be informed of the risk of recurrent sprain and subsequent ankle instability; careful follow-up is needed for these patients[25]. Fixing or removing the avulsed fragment is determined by the size of fragment[26]; fragments can be removed for small avulsion fractures[27].

To our knowledge, this is the first study to report the mid- to long-term follow-up study of the concurrent arthroscopy and open lateral ankle ligament repair for the acute ankle sprain analyze the impact of the rupture site on the outcome. The relatively large sample size could provide a reliable conclusion on the effectiveness of the operation and the potential problems. The results of the impact of the rupture site

provided a reference for an optimal and personalized postoperative rehabilitation. Patients with proximal injuries might be encouraged to perform more aggressive rehabilitation. Those with ligament rupture near the calcaneal or talus site could return to sport at about 14 weeks while the rupture near the fibular site at about 12 weeks. It should be also noted that the surgery prefers to be used in those with severe ligament injury and high sports demanding in spite of the excellent postoperative outcome. Most ankle sprains were recommended conservative treatment and rehabilitation training, and satisfactory results could be obtained.

There are still some limitations about this research. First, it was retrospective rather than prospective research with no comparative groups undergoing conservative treatment or isolated ligament repair without arthroscopy. In addition, patients were divided into three groups according to the rupture sites, which was not absolutely strict, because the tear of the ligament was usually reported as a cauda equina rather than a simple avulsion from the insertion site. Therefore, the groups in the present study were determined according to the location of the most severe tear, which basically reflected the area of the main injury.

# Conclusions

Ankle arthroscopy followed by open anatomic ligament repair is a reliable procedure for patients with high sports demands after severe acute ankle sprain. Rupture near the talar or calcaneal side weakened and delayed sports recovery. The distal rupture returned to sports about 2 weeks later than the proximal rupture.

# Declarations

- **Funding**

The authors report funding from National Key Research and Development Program of china (Grant No. 2019YFB1706900), National Natural Science Foundation of China (82072428), and Natural Science Foundation of Beijing Municipality (7212132).

- **Competing interests**

The authors declare that they have no competing interests.

- **Ethics approval and consent to participate**

The research was approved by the IRB Medical Ethics Committee of Peking University Third Hospital (IRB00006761-2016011), and all methods were performed in accordance with the relevant guidelines and regulations. Written informed consent was obtained for all participants.

- **Acknowledgements**

Not applicable.

- **Consent for publication**

Not applicable.

- **Availability of data and materials**

All data generated or analyzed during this study are included in this article.

- **Authors' contributions**

Mingze Du and Jun Li contributed equally to this work

1. Conception and design of the study: Dong Jiang. Acquisition of data: Mingze Du and Jun Li. Analysis, or interpretation of data: Mingze Du and Jun Li.
2. Drafting the work: Mingze Du and Jun Li. Revising it critically for important intellectual content: Chen Jiao, Qinwei Guo, Yuelin Hu and Dong Jiang.
3. Final approval of the version to be published: Mingze Du, Jun Li, Chen Jiao, Qinwei Guo, Yuelin Hu and Dong Jiang.
4. Agreement to be accountable for all aspects of the work in ensuring that questions related to the accuracy or integrity of any part of the work are appropriately investigated and resolved: Mingze Du, Jun Li, Chen Jiao, Qinwei Guo, Yuelin Hu and Dong Jiang.

# References


1. Wang Z-G, Wu C. Efficacy of repair and reconstruction therapy for the treatment of lateral ankle ligament injury: A protocol of systematic review and meta-analysis. Medicine (Baltimore). 2020;99:e20344.
2. Van den Bekerom MPJ, Kerkhoffs GMMJ, McCollum GA, Calder JDF, van Dijk CN. Management of acute lateral ankle ligament injury in the athlete. Knee Surg Sports Traumatol Arthrosc. 2013;21:1390–5.
3. Verhagen E, van der Beek A, Twisk J, Bouter L, Bahr R, van Mechelen W. The effect of a proprioceptive balance board training program for the prevention of ankle sprains: a prospective controlled trial. Am J Sports Med. 2004;32:1385–93.
4. Kerkhoffs GM, Rowe BH, Assendelft WJ, Kelly KD, Struijs PA, van Dijk CN. Immobilisation for acute ankle sprain. A systematic review. Arch Orthop Trauma Surg. 2001;121:462–71.
5. Kerkhoffs GMMJ, Van Dijk CN. Acute lateral ankle ligament ruptures in the athlete: the role of surgery. Foot Ankle Clin. 2013;18:215–8.
6. Lynch SA, Renström PA. Treatment of acute lateral ankle ligament rupture in the athlete. Conservative versus surgical treatment. Sports Med. 1999;27:61–71.

7. Shakked R, Sheskier S. Acute and Chronic Lateral Ankle Instability Diagnosis, Management, and New Concepts. Bull Hosp Jt Dis (2013). 2017;75:71–80.
8. Hepple S, Guha A. The role of ankle arthroscopy in acute ankle injuries of the athlete. Foot Ankle Clin. 2013;18:185–94.
9. Van den Bekerom MPJ, Oostra RJ, Golanó P, Alvarez PG, van Dijk CN. The anatomy in relation to injury of the lateral collateral ligaments of the ankle: a current concepts review. Clin Anat. 2008;21:619–26.
10. Ebraheim NA, Taser F, Shafiq Q, Yeasting RA. Anatomical evaluation and clinical importance of the tibiofibular syndesmosis ligaments. Surg Radiol Anat. 2006;28:142–9.
11. Ferkel E, Nguyen S, Kwong C. Chronic Lateral Ankle Instability: Surgical Management. Clin Sports Med. 2020;39:829–43.
12. Bond MR, Pilowsky I. Subjective assessment of pain and its relationship to the administration of analgesics in patients with advanced cancer. J Psychosom Res. 1966;10:203–8.
13. Kitaoka HB, Alexander IJ, Adelaar RS, Nunley JA, Myerson MS, Sanders M. Clinical rating systems for the ankle-hindfoot, midfoot, hallux, and lesser toes. Foot Ankle Int. 1994;15:349–53.
14. Odensten M, Tegner Y, Lysholm J, Gillquist J. Knee function and muscle strength following distal ileotibial band transfer for antero-lateral rotatory instability. Acta Orthop Scand. 1983;54:924–8.
15. Pijnenburg ACM, Bogaard K, Krips R, Marti RK, Bossuyt PMM, van Dijk CN. Operative and functional treatment of rupture of the lateral ligament of the ankle. A randomised, prospective trial. J Bone Joint Surg Br. 2003;85:525–30.
16. Brison RJ, Day AG, Pelland L, Pickett W, Johnson AP, Aiken A, et al. Effect of early supervised physiotherapy on recovery from acute ankle sprain: randomised controlled trial. BMJ. 2016;355:i5650.
17. White WJ, McCollum GA, Calder JDF. Return to sport following acute lateral ligament repair of the ankle in professional athletes. Knee Surg Sports Traumatol Arthrosc. 2016;24:1124–9.
18. Samoto N, Sugimoto K, Takaoka T, Fujita T, Kitada C, Takakura Y. Comparative results of conservative treatments for isolated anterior talofibular ligament (ATFL) injury and injury to both the ATFL and calcaneofibular ligament of the ankle as assessed by subtalar arthrography. J Orthop Sci. 2007;12:49–54.
19. Gregush RV, Ferkel RD. Treatment of the unstable ankle with an osteochondral lesion: results and long-term follow-up. Am J Sports Med. 2010;38:782–90.
20. Hua Y, Chen S, Li Y, Chen J, Li H. Combination of modified Broström procedure with ankle arthroscopy for chronic ankle instability accompanied by intra-articular symptoms. Arthroscopy. 2010;26:524–8.
21. Matsui K, Takao M, Tochigi Y, Ozeki S, Glazebrook M. Anatomy of anterior talofibular ligament and calcaneofibular ligament for minimally invasive surgery: a systematic review. Knee Surg Sports Traumatol Arthrosc. 2017;25:1892–902.

22. Golanó P, Vega J, de Leeuw PAJ, Malagelada F, Manzanares MC, Götzens V, et al. Anatomy of the ankle ligaments: a pictorial essay. Knee Surg Sports Traumatol Arthrosc. 2010;18:557–69.
23. Wang D, Shen Z, Fang X, Jiao C, Guo Q, Hu Y, et al. Vascular Compromising Effect of Drilling for Osteochondral Lesions of the Talus: A Three-Dimensional Micro-Computed Tomography Study. Arthroscopy. 2019;35:2930–7.
24. Diallo J, Wagener J, Schweizer C, Lang TH, Ruiz R, Hintermann B. Intraoperative Findings of Lateral Ligament Avulsion Fractures and Outcome After Refixation to the Fibula. Foot Ankle Int. 2018;39:669–73.
25. Yamaguchi S, Akagi R, Kimura S, Sadamasu A, Nakagawa R, Sato Y, et al. Avulsion fracture of the distal fibula is associated with recurrent sprain after ankle sprain in children. Knee Surg Sports Traumatol Arthrosc. 2019;27:2774–80.
26. Birnie MFN, van Schilt KLJ, Sanders FRK, Kloen P, Schepers T. Anterior inferior tibiofibular ligament avulsion fractures in operatively treated ankle fractures: a retrospective analysis. Arch Orthop Trauma Surg. 2019;139:787–93.
27. Danielsson LG. Avulsion fracture of the lateral malleolus in children. Injury. 1980;12:165–7.

# Figures

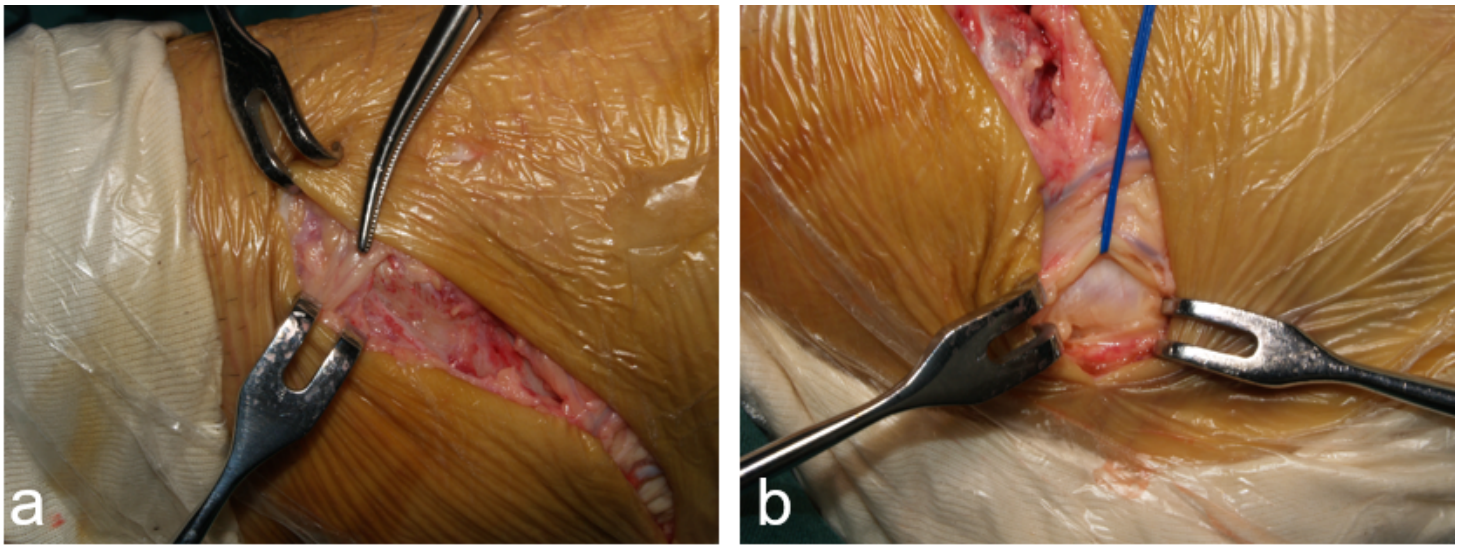


**Figure 1**

Care was taken to avoid the intermediate branch of the superficial peroneal nerve (a) and sural nerve (b)

**Figure 2**

A patient with an anterior talofibular ligament (ATFL) tear at the talar site (a) and a calcaneofibular ligament (CFL) tear at the calcaneal site (b), which were identified in magnetic resonance images (MRI). The end of the ruptured ATFL was identified under arthroscopy (c). The ruptured ends were isolated (d), and the suture anchor was inserted into the insertion site (e,f). The ligament was then braided and pulled underneath the peroneal tendon (blue arrow) and fixed with the anchor wire (g, h). The extensor retinaculum was then sutured to the fibular periosteum (i).

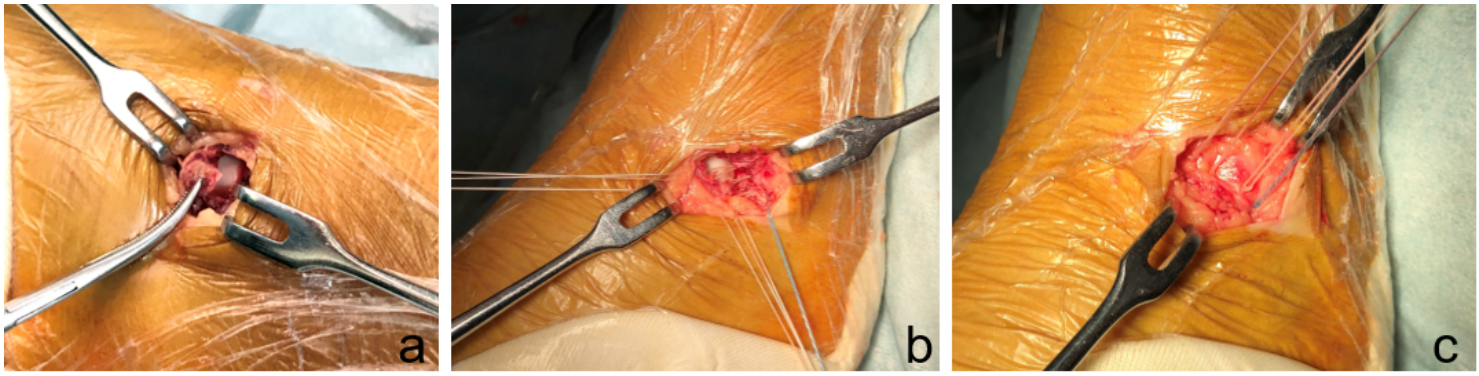


**Figure 3**

A patient with avulsion fractures with a diameter of < 1 cm. We carefully peeled the ligaments from the surface and resected the fracture fragment then sutured the ligament tissue to the bone surface with anchors.