Clinical Outcomes of Single Excision Versus Kidner Procedure for Type II Accessory Navicular Associated With Flatfoot in Adults: Does Accessory Navicular Induce Flexible Flatfoot?

Xu Tao
Army Medical University

Qian dong Yang (478866593@qq.com)
army medical university https://orcid.org/0000-0002-7927-3997

Zhenyu Wang
Army Medical University

Wei Wang
Army Medical University

Kang Lai Tang
Army Medical University

Research Article

Keywords: accessory navicular, flexible flatfoot, Posterior tibia tendon, Clinical outcomes, radiographic change

Posted Date: February 28th, 2022

DOI: https://doi.org/10.21203/rs.3.rs-1131260/v2

Abstract

Background: Patients with type II accessory navicular (AN) originally complain of the medial pain of foot. With increasing frequency, some of them has been recognized flexible flatfoot (FFF) at the first weightbearing radiographic examination. Posterior tibial tendon (PTT) dysfunction is widely accepted as a significant contributor to FFF. However, the PTT was not affected in these patients. The relationship between AN and FFF remains controversial. The contribution of AN to FFF was designed in this study.

Methods: Adult patients who complained of medial pain and bone eminence between January 2014 and January 2020 were included. 61 patients were confirmed to have the AN with flatfoot and randomly divided into two operative groups. The AN was excised in Group A, and the PTT was reconstructed to the navicular region with an anchor in Group B. Preoperative and postoperative evaluations were performed, including clinical evaluations, the American Orthopedic Foot and Ankle Society (AOFAS) mid-foot scale, a visual analog scale (VAS) and radiographic assessments of Meary's angle, Pitch angle, talonavicular coverage, Kite's angle and naviculocuboid overlap. PTT decline angle (PDA) and AN-Navicular joint inclination angle (ANJCA) in the lateral view were designed to evaluate the effect of AN on FFF.

Results: Fifty-six patients (56 feet) were included in this study because 5 patients were excluded. The mean follow-up period was 22.29 months with single excision (Group A) and 20.86 months with Kidner procedure (Group B). The AOFAS mid-foot score improved from 70.39±7.78 pre-operationally to 89.46±7.06 at the last follow-up in Group A and from 67.14±8.14 pre-operationally to 89.64±6.88 at the last follow-up in Group B. The VAS score decreased from 2.82±0.39 and 2.86±0.36 to 0.89±0.31 and 0.79±0.42, respectively. The radiographic results representing flatfoot significantly increased in the two groups. In the lateral view, PDA significantly increased after the operation, and the effect of PTT on the arch upward was induced by pull angulations and shorter distances.

Conclusion: The FFF with AN may be induced by AN and its synchondrosis. The weakened plantar ligament of synchondrosis was impaired under chronic tension and shear forces may be implicated as the etiologic biomechanical mechanism. AN excision or it with PTT reconstruction could release the pain and benefit the PTT pulling sufficiency.

Level of evidence: Level IV, comparative serial cases.

Introduction

The accessory navicular (AN) is a common accessory ossicle of the foot. Type II is most popular type of AN problem. Once the patients with AN became symptomatic, they mostly complained of mid-foot pain and bony eminence, which occurred recurrently after sports or sprain. However, some of them was recognized with a flexible flatfoot (FFF) at their first weightbearing radiographic examination. Whether the AN induced in FFF is controversial[1]. The AN is reported up to 21% of population, which are found in patients who have flat foot (19%)[2]. Some doctors believe the posterior tibial tendon (PTT) disfunction in this type of FFF. However, without PTT interruption, AN osteosynthesis was reported to gain good

outcome[3]. But few articles have reported the rate of FFF after osteosynthesis. We believe that single osteosynthesis may not resolve all biomechanical problems of AN with FFF.

As well known, PTT and various medial ligaments, were noted to be dynamic and static contributors[4]. The AN involved in FFF as an anatomic variant. When the AN present, the PTT stops at the final insertion in the internal cuneiform and lesser metatarsals instead of at the plantar surface of the navicular tubercle. Instead of pulling directly from the turbucle of navicular, the PTT contracts the lower end of AN and multiple insertions at tarsus as an adductor rather than as a supinator. In very earlier research, Kidner[5] described the term as prehallux, due to the theory that it is a degenerated evolutionary remnant and a progressive evolutionary effort of nature to re-enforce a weakening and pronating foot arch. The relationship between AN and PTT may be essential to reconstruct of medial arch, and how to treat PTT resumption after resection determines the principal theme of this paper. After single excision of AN without PTT reconstruction, foot arch was not collapsed. It is proved that the PTT was not only resources of maintain the arch. We designed this study to compare the clinical changes in FFF after AN resection and analyze the contribution of AN to FFF.

Method And Methods

The study included all adult patients from January 2014 to January 2020, who originally complained the pain and bony prominence at the medially to the navicular tubercle. 61 adult patients were confirmed type II AN with flatfoot by radiographic examination and separated into two group randomly. Group A consisted of 30 patients who underwent single AN resection, and Group B consisted of 31 patients who underwent the Kidner procedure with an anchor. The exclusion criteria were patients had other types of AN but type II, a history of a local steroid injection, local infection, or underlying diseases such as uncontrolled diabetic mellitus, rheumatoid arthritis, or seronegative spondyloarthropathy.

All patients was palpated before surgery at medial side of foot, especially at the synchondrosis, posterior edge of medial prominence, along and insertion of PTT course.

Prior to the surgical treatment and at the final follow-up, clinical evaluations were made in all patients using the American Orthopedic Foot and Ankle Society (AOFAS) mid-foot score, visual analog scale (VAS) for pain, and radiographic assessments performed by anteroposterior (AP) and lateral radiographs.

All radiographs were digitally obtained through the Picture Archiving Communication System (PACS; Infinitt, Seoul, Korea). Traditional radiographic data about flatfoot were measured, including talonavicular coverage angle, first talometatarsal angle, talocalcanueus angle (kite angle) on anteroposterior (AP) radiographs, first talometatarsal angle (Meary’s angle), naviculocuboid overlap[6–7] (Fig. 1D) and calcaneal pitch angle on the lateral view[8].

Other data were designed for this research (Fig. 1A-C). The points that define the inclination of PTT are described as follows: the posterior border of posterior malleolus is taken as point P; the tangent point at the scaphoid tubercle or end of AN is point E; the lowest end of AN is point N; the base of the first

metatarsal bone is point M; the PTT declination angle (PDA) is formed by the lines PE and MN, which is measured as the projection line of PTT at lateral view. The reason for choosing the first metatarsal base is considered for the enormous changes after the operation. The AN-N joint inclination angle (ANJCA) is formed by the joint line (SQ) and the weight bearing surface. The AN size includes the length and height in the lateral view and the length and width in the AP view.

Surgical Technique

An incision is made along the course of PTT, with its center at the AN. The AN was found to carry the main attachment of the PTT. With a thin osteotome and a rongeur, the prominence, which includes the whole AN and part of the corresponding amount of the navicular, was removed. Then, an additional naviculoplasty was performed(9).

In Group A, AN resection and naviculoplasty were performed, the fibrocartilaginous margin was sutured to the engulfed ligamenum by 2–0 Ethibond polyester sutures (Ethicon, New Brunswick, NJ, USA). In Group B, the tendon was inferiosuperiorly transplanted by an anchor (DePuty, New Brunswick, NJ, USA) so that it could heal with the fresh stump of the tarsal scaphoid. The position of the anchor is located at the center of the surface and direction points at the Cuboid/Metatarsal$_4$ joint. It is strengthened by sutures through the adjacent ligamentous tissues, fixed with the foot in mild supination. The tibiospring ligament or soft tissue was strengthened to the PTT by 2–0 Ethibond polyester sutures (Ethicon, New Brunswick, NJ, USA). Finally, the wound was routinely closed.

Postoperative management

The patient was maintained for the first two weeks. The rehabilitation began at the third week, including physiotherapy and splinting, with gradual return to weight bearing in a shoe until six weeks. The patients started full weight bearing and returned to normal life at three months.

Statistical analysis

All statistical analysis was performed using SPSS software (version 12.0; SPSS, Chicago, IL). A chi-square test and one-way analysis of variance (ANOVA) was performed to assess the difference of baseline characteristics between the group A and group B. A one-way analysis of variance (ANOVA) was performed to assess the outcome of clinical and radiologic in the preoperative and postoperative between group A and group B. A P value less than 0.05 was considered significant.

Results

All patients underwent surgery by three senior doctors in a single institution. In such cases, patients whose lateral column lengthening (LCL) osteotomy was added to the correct forefoot adduction were

excluded. Two cases in Group A and three cases in Group B were combined LCL procedures. In total, 56 patients (56 feet) were included in this study. The mean follow-up period was 22.29 and 20.86 months (range: 6-60 months). Informed consent was obtained from all patients. The demographics of the patients are shown in Table 1.

Table 1

Demographic and data before operation. Group A: patients who underwent single resection; Group B: patients who underwent Kidner procedure; BMI: body mass index; ANJCA: Accessory navicular joint inclination angle. The values are expressed as the number *values as the means ± SD, # values measured over 1.5 mm are calculated at either medial-lateral view or anteroposterior view, otherwise are indicated.

	Group A (n=28)	Group B (n=28)	P
Sex			$\chi^2 = 0.265$
Male	12	8	
Female	16	20	
Age, mean (range) (y)	28.61 (18–49)	35.36 (18–59)	$P_{ANOVA}=0.033$
			$\chi^2 = 0.217$
<40 y	23	19	
≥40 y	5	9	
BMI* (%)	22.20±4.32	23.06±4.94	$P_{ANOVA}=0.490$
			$\chi^2 = 1.00$
<24%	21	21	
>24%	7	7	
Size#			$\chi^2 = 0.114$
<1.5 cm	9	4	
>1.5 cm	19	24	
ANJCA* (deg.)	63.01±10.25	61.22±8.28	$P_{ANOVA}=0.475$
			$\chi^2 = 0.114$
<70 deg.	19	24	
>70 deg.	9	4	
Subtype			$\chi^2 = 0.365$
IIA	9	6	
IIB	19	22	
Follow up, mean (range) (m)	22.29(6–60)	20.86(6–60)	$\chi^2 = 0.725$

Some ANs were so large, but only palpation was located at the inner ends of the navicular without other symptoms. The normal leverage of the PTT was maintained, and there were mild flat feet. For these patients, palpation was at the synchondrosis and bony prominence; for the others, whose foot collapsed markedly, the pain was at the inferior edge of the insertion, not at the course of PTT.

Hypertrophic AN inferomedially extends the scaphoid tubercle, and PTT distributes complexity more than normal. The principal fibers of PTT stop on the AN, partial fibers bypass through the dorsal mid-foot, and the slender medial part reverses and joins into the tibionavicular ligament, which strengthens the medial capsule of the TN joint (Fig. 2). In all observed cases where the AN was dissected off the considerable size, the PTT was displaced forward by its attachment to the stump of the navicular.

Radiographic and clinical results were separately tabulated for each group (Tables 2 and 3).

Table 2
Radiographic results between the two methods pre-operation and at the final follow-up. PDA Posterior tibia tendon Decline Angle. Values are expressed as means ± SD; P>0.05; NS indicates not significant.

	Group A		**Group B**		
	Pre	Post	Pre	Post	P
PDA (deg.)	140.63±9.57	156.46±9.43	134.39±8.68	152.89±9.07	0.260
Midfoot					
Overlap (%)	0.52±0.21	0.34±0.16	0.58±0.12	0.38±0.16	0.593
Coverage (deg.)	7.83±5.87	4.73±4.50	13.15±7.50	5.34±4.28	0.014
Hindfoot					
Pitch (deg.)	18.93±4.56	21.02±3.60	18.77±3.79	20.77±4.34	0.917
Kite (deg.)	27.75±6.92	23.06±5.10	29.52±7.54	26.19±7.10	0.459
Forefoot					
Lateral Meary (deg.)	10.93±7.47	6.64±7.64	15.50±9.62	8.35±6.37	0.125
A-P Meary (deg.)	10.29±6.95	6.99±5.35	14.58±8.10	7.50±5.62	0.011

Table 3
Comparative outcome of treatment on the AOFAS-midfoot score and VAS score. The values are expressed as means ± SD; P>0.05; NS indicates not significant.

	Group A		**Group B**		
	Pre	Post	Pre	Post	P
AOFAS (Total)	70.39±7.78	89.46±7.06	67.14±8.14	89.64±6.88	0.127
Pain	21.79±3.90	30.71±3.78	21.43±3.56	32.14±4.18	0.203
Function	37.86±3.46	44.25±2.63	35.46±5.75	44.00±1.87	0.073
Alignment	10.75±3.48	14.50±1.84	10.25±3.33	13.50±2.92	0.601
VAS	2.82±0.39	0.89±0.31	2.86±0.36	0.79±0.42	0.294

According to the pre-operative view, patients with ANJCA above 70 degrees described the location of pain at the lower edge of the AN, and the others with ANJCA below 70 degrees described the location at the AN-N joint and bony prominence. While the bypassed fibers were scattered to the plantar tarus, the gross PTT extended the AN and pulled the arch indirectly inward and upward. The impingement between the AN-N joint leads to the intensity of AN in MRI in patients with ANJCA below 70 degrees. We hypothesize that the reason is that the contraction of PTT is erected to the AN-N joint. The tenderness of the PTT engulfs was obvious in the other patients with a larger ANJCA. We believed that the force of PTT did not affect the AN-N joint, especially the dorsal side. The force arm of the PTT increased after detouring, which was easily damaged. The size of the hypertrophic AN was defined in this study as a length of more than 1.5 cm in either lateral view or AP view, with an ANJCA angle inclined to less than 70 degrees. Meanwhile, in the group with AN less than 1.5 cm and a larger ANJCA angle over 70 degrees, the FFF was severe. We believe that the theory in this type is more likely caused by dorsal ligament dysfunction.

After the AN resection and naviculoplasty, the PDA was significantly increased. The inferior partial tubercle of the navicular was removed, and the PTT was re-stumped navicular or reconnected to the resumption. The radiographic indices of the midfoot significantly decreased in both groups, and the forefoot and hindfoot data significantly changed in Group B. According to anatomy[9], the middle component and tarsometatarsal component of the PTT inserts on the cuneiforms, cuboid and peroneal canal. In Group A, PTT forced itself on the forefoot. The medial arch was reconstructed in Group B because the midfoot was directly forced by PTT reattachment. The hindfoot was not significantly changed in either group.

Two groups of patients were satisfied with the pain release, gaining increasing AOFAS midfoot scores and decreasing VAS scores. However, all patients in Group A felt that the strength decreased after 3 months and improved after 6 months.

Fore patients in Group B felt popping at the level of the medial malleolus while running at 6 months. These patients have larger AN than 2.0 cm. The patient whose AN was less than 2.0 cm did not feel popping after the operation. Scar pain could be provoked by resisting the action of the PTT or heavily tapping the incision.

Discussion

AN has been recognized in patients who suffered FFF, with increasing frequency. However, the relationship between AN and FFF remains controversial[11]. PTT dysfunction is widely accepted as a significant contributor to this deformity. Chronic tension and shear forces by the PTT at increasing pronation have been implicated as the etiologic biomechanical mechanism[12–13]. The abnormal anatomy of FFF typically starts at the PTT, but dysfunction in this tendon by itself is not enough to cause substantial deformity. The cumulative damage of remaining structures causes the typical mal-alignment of FFF. We believe that the uique anatomy around AN is the alternative reason for FFF, instead of an indirect factor.

According to the literature, the broad insertion of PTT that engulfs the tuberosity of the navicular and reaches the first cuneiform similar to a cuff[14]. In type II, the principal dynamic stabilizer of the longitudinal medial arch, which is the posterior tibialis muscle, is attached to the AN instead of directly at the keystone of the triple arch complex. This engulfed part can be defined as a ligament, i.e., accessory navicular cuneiform ligament (ANCL), which is the fibrous connective tissue that connects the AN and the medial cuneiform. We hypothesize that the relationship between ANCL and PTT is identical to that between patellar ligament and quadriceps tendon[15].

Like spring ligament, ANCL gradually strain causes FFF. Therefore, the pain of FFF derived from AN, the pain locates at inferior of AN-N joint rather than the course of PTT. This leads to the decreasing strength in Group A. However, they cannot retain their original shape when extended beyond their characteristically viscoelastic for a prolonged period of time. The ANCL becomes prone to future injury. Finally, flatfoot occurs with forefoot adduction. The patients in this study had got high AOFAS-midfoot score because there was no strength evaluation of AOFAS scores and all patients paid attention to the rehabilitation postoperatively.

Park’s radiologic results showed that the hindfoot was more in equinus, the midfoot was more pronated and abducted, and the forefoot was more abducted and pronated in patients with AN than the normal control group[16]. We agreed with it that the suspend force at arch was medialized. Therefore, PTT reconstruction could correct flat deformity. The midfoot indicates, such as naviculocuboid overlap and talonavicular coverage angle, has decreasing more significiently in Group B.

The various surgical options are used to treat the flatfoot with AN, including simple resection[17]; extended excision with reconstruction of PTT[18–19]; percutaneous drilling[20]; and fusion between the supernumerary bone and the main navicular[21–22]. However, these treatment is still controversial. Many doctors believe AN fixed on the navicular by removing the cartilage parts between them. The function of

PTT was backed at the keystone. However, the fixation has a lot of disadvantage. First, the fixer irritates the attachment of PTT where it passes through[3, 23], moreover, it has been an approximately 20% rate of nonunion[21]. Chung[24]was reported that near 20% (7/34) patients was not satisfied the results. Second, the expanded tubercle could impact the dorsal TN joint anteriomedially. Tabionavicular part of the deltoid ligament attaches at the dorsal side of the AN, where is crowding of soft tissue, leads to discomfort at the position of supration. Once the flatfoot formed gradually, this part of ligament was felt complaint by hypertension at pronation of foot. And the function of PTT is impaired by the close approach of the AN to the medial malleolus.

With AN, PTT forces harder to maintain the medial arch, due to the major fibers insert at the navicular indirectly. At the lateral view, PDA increased significantly after operation, the effect of PTT on the arch upward has been induced by the angulation of pull and the shorter distance through which the PTT produced. The inward contraction approach more lineally, which it increases the sufficiency of PTT.

There is no doult without deficiency. First, the naviculoplasty may have an effect on the result of PDA, naviculocuboid overlap at lateral view and talonavicolar coverage angle at AP view. Second, the AOFAS midfoot score has no part to evaluate the strength, PROMIS evaluation may be the alternative. Third, we had measured the length of shortening of PTT, however, it was abandoned because the measurement at the AP view may have an error due to foot supination/pronation.

The FFF with AN may be induced by AN and its synchondrosis. The weakened plantar ligament of synchondrosis was impaired under chronic tension and shear forces may be implicated as the etiologic biomechanical mechanism. AN excision or it with PTT reconstruction could release the pain and benefit the PTT pulling sufficiency.

Abbreviations

Not available

Declarations

Declaration

Not available

Acknowledgements

Not available

Conflict of Interest

The authors affirm that human research participants provided informed consent for publication of the images

References

1. Sullivan J A., Miller W A.(1979). The relationship of the accessory navicular to the development of the flat foot. Clin Orthop Relat Res, undefined(144), 233-7.
2. Miller T T., Staron R B., Feldman F., Parisien M., Glucksman W J., Gandolfo L H.(1995). The symptomatic accessory tarsal navicular bone: assessment with MR imaging. Radiology, 195(3), 849-53. doi:10.1148/radiology.195.3.7754020
3. Jang Ho-Seong., Park Kwang-Hee., Park Hyun-Woo.(2017). Comparison of outcomes of osteosynthesis in type II accessory navicular by variable fixation methods. Foot Ankle Surg, 23(4), 243-249. doi:10.1016/j.fas.2016.07.004
4. Deland Jonathan T., de Asla Richard J., Sung Il-Hoon., Ernberg Lauren A., Potter Hollis G.(2005). Posterior tibial tendon insufficiency: which ligaments are involved? Foot Ankle Int, 26(6), 427-35. doi:10.1177/107110070502600601
5. Kidner FC. The prehallux (accessory scaphoid) in its relation to flatfoot. The Journal of bone and joint surgery American volume. 1929;11:831-7.
6. Davids Jon R., Gibson T Whitney., Pugh Linda I.(2005). Quantitative segmental analysis of weight-bearing radiographs of the foot and ankle for children: normal alignment. J Pediatr Orthop, 25(6), 769-76. doi:10.1097/01.bpo.0000173244.74065.e4
7. Davids Jon R., Gibson T Whitney., Pugh Linda I.(2005). Quantitative segmental analysis of weight-bearing radiographs of the foot and ankle for children: normal alignment. J Pediatr Orthop, 25(6), 769-76. doi:10.1097/01.bpo.0000173244.74065.e4
8. Lamm Bradley M., Stasko Paul A., Gesheff Martin G., Bhave Anil.(2016). Normal Foot and Ankle Radiographic Angles, Measurements, and Reference Points. J Foot Ankle Surg, 55(5), 991-8. doi:10.1053/j.jfas.2016.05.005
9. Seehausen Derek A., Harris Liam R., Kay Robert M., Pace J Lee.(2016). Accessory Navicular is Associated With Wider and More Prominent Navicular Bone in Pediatric Patients by Radiographic Measurement. J Pediatr Orthop, 36(5), 521-5. doi:10.1097/BPO.0000000000000489
10. Kelikian AS. Sarrafian's Anatomy of the Foot and Ankle: Descriptive, Topographic, Functional. Philadelphia, PA: Wolters Kluwer; 2011.
11. Sullivan J A., Miller W A.(1979). The relationship of the accessory navicular to the development of the flat foot. Clin Orthop Relat Res, undefined(144), 233-7.
12. Sella E J., Lawson J P.(1987). Biomechanics of the accessory navicular synchondrosis. Foot Ankle, 8(3), 156-63. doi:10.1177/107110078700800310
13. Grogan D P., Gasser S I., Ogden J A.(1989). The painful accessory navicular: a clinical and histopathological study. Foot Ankle, 10(3), 164-9. doi:10.1177/107110078901000310
14. Kelikian AS. Sarrafian's anatomy of the foot and ankle. 2011;Third Edition.
15. Dalen-Lorentsen Torstein., Andersen Thor Einar., Bjørneboe John., Vagle Markus., Martin Kevin Nordanger., Kleppen Michael., Fagerland Morten Wang., Clarsen Benjamin.(2021). A Cherry, Ripe for

Picking: The Relationship Between the Acute-Chronic Workload Ratio and Health Problems. J Orthop Sports Phys Ther, 51(4), 162-173. doi:10.2519/jospt.2021.9893

16. Park Hoon., Hwang Jin Ho., Seo Joon Oh., Kim Hyun Woo.(2015). The Relationship Between Accessory Navicular and Flat Foot: A Radiologic Study. J Pediatr Orthop, 35(7), 739-45. doi:10.1097/BPO.0000000000000359
17. Rietveld A B M Boni., Diemer Willemijn M.(2016). Surgical Treatment of the Accessory Navicular (Os Tibiale Externum) in Dancers: A Retrospective Case Series. J Dance Med Sci, 20(3), 103-8. doi:10.12678/1089-313X.20.3.103
18. Micheli Lyle J., Nielson Jason H., Ascani Claudio., Matanky Bryan K., Gerbino Peter G.(2008). Treatment of painful accessory navicular: a modification to simple excision. Foot Ankle Spec, 1(4), 214-7. doi:10.1177/1938640008321405
19. Jasiewicz Barbara., Potaczek Tomasz., Kacki Wojciech., Tesiorowski Maciej., Lipik Ewa.(2008). Results of simple excision technique in the surgical treatment of symptomatic accessory navicular bones. Foot Ankle Surg, 14(2), 57-61. doi:10.1016/j.fas.2007.12.002
20. Nakayama Shoichiro., Sugimoto Kazuya., Takakura Yoshinori., Tanaka Yasuhito., Kasanami Ryoji. (2005). Percutaneous drilling of symptomatic accessory navicular in young athletes. Am J Sports Med, 33(4), 531-5. doi:10.1177/0363546504270564
21. Miyamoto Wataru., Takao Masato., Yamada Kazuaki., Yasui Youichi., Matsushita Takashi.(2012). Reconstructive surgery using interference screw fixation for painful accessory navicular in adult athletes. Arch Orthop Trauma Surg, 132(10), 1423-7. doi:10.1007/s00402-012-1574-8
22. Lui Tun Hing.(2016). Endoscopic Accessory Navicular Synchondrosis Fusion. Arthrosc Tech, 5(6), e1267-e1272. doi:10.1016/j.eats.2016.07.018
23. Vaughan Philip., Singh Dishan.(2014). Ongoing pain and deformity after an excision of the accessory navicular. Foot Ankle Clin, 19(3), 541-53. doi:10.1016/j.fcl.2014.06.010
24. Chung Jin-Wa., Chu In-Tak.(2009). Outcome of fusion of a painful accessory navicular to the primary navicular. Foot Ankle Int, 30(2), 106-9. doi:10.3113/FAI-2009-0106

Figures

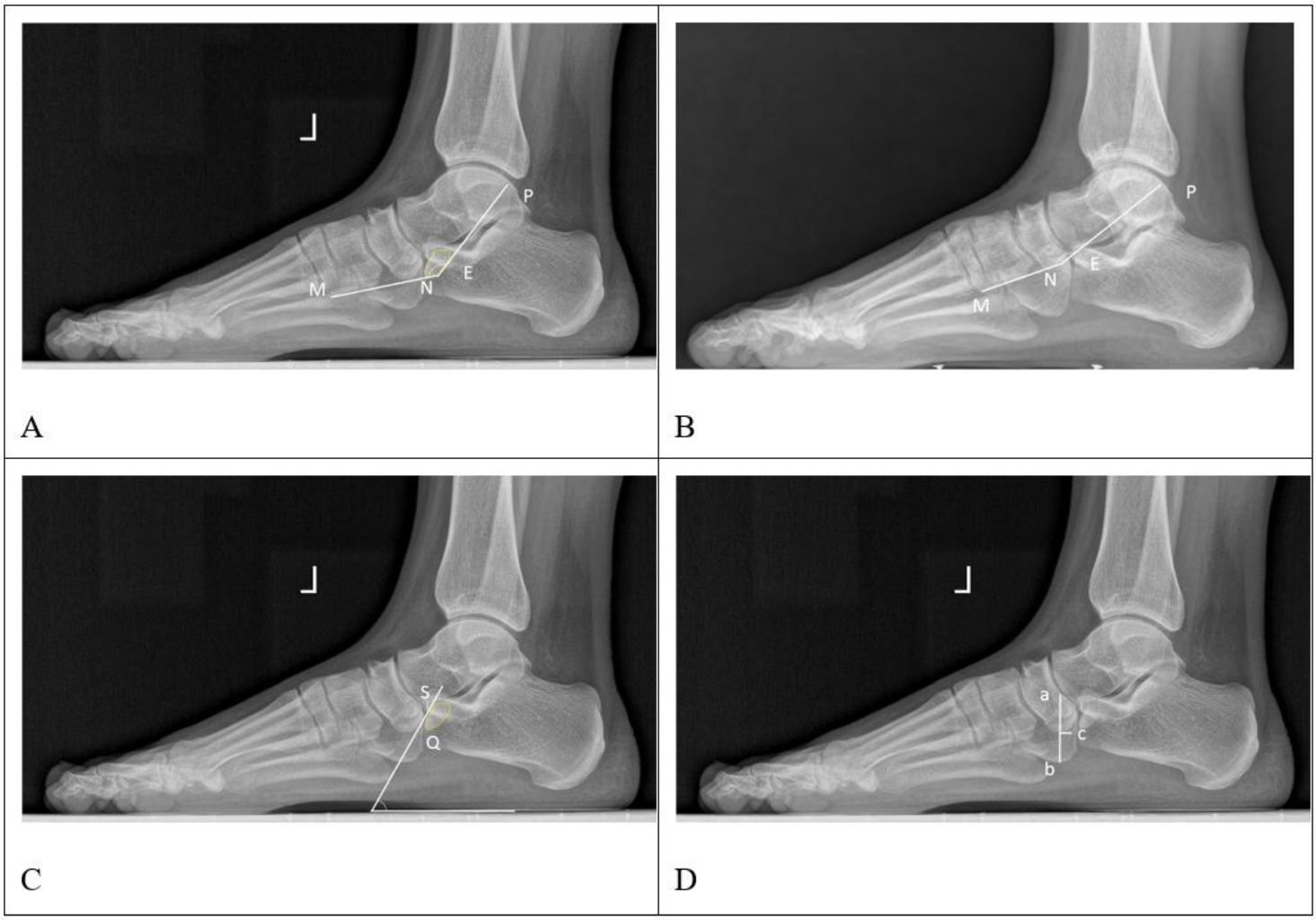

Figure 1

The demostrate of radiographic measure at lateral view. A, C and D: preoperative images; B: postoperative image. A, B, Posterior tibia tendon declination angle (PDA): Point *P* = posterior border of posterior malleolus, Point *E* = tangent point at the scaphoid tubercle or end of AN, Point *N* = lowest end of AN, Point *M* = base of the second metatarsal bone; PDA is formed by the lines *PE* and *MN*; C, Accessory navicular-Navicular joint inclination angle (ANJCA), formed by the joint line (SQ) and weight bearing surface; D, Naviculocuboid overlap: *ac*/ *ab*×100. Points *a*, *b* = superior and inferior margins of the cuboid. Point *c* = inferior margin of the navicular.

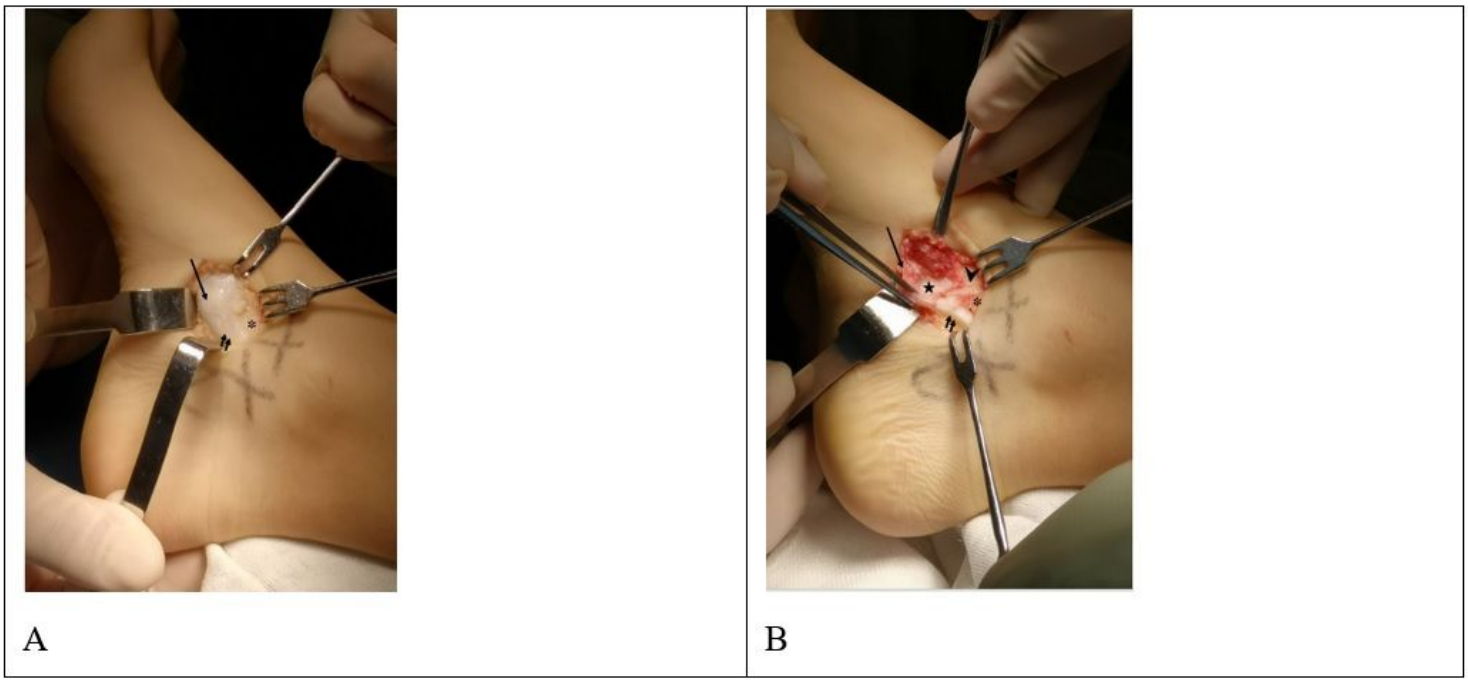

Figure 2

In the operation, the anatomy of the peri-navicular in the operation. A: before resection; B: after resection. The arrowhead shows the sling tissue; the long arrow is the cuff of the PTT; the snow stars are the fat tissue between the tibiospring ligament and the PTT; the double-short arrow is the PTT; the five star is the stump of the PTT.