Research Square

Preprints are preliminary reports that have not undergone peer review. They should not be considered conclusive, used to inform clinical practice, or referenced by the media as validated information.

Impact of a clinical pharmacist in ultrasound-guided venous thromboembolism screening in hospitalized COVID-19 patients: a pilot prospective study.

Laura Gillespie
Saint Joseph Regional Medical Center
Rashid Z. Khan
Michiana Hematology Oncology
John E. Stillson
Indiana University School of Medicine-South Bend
Connor M. Bunch
Indiana University School of Medicine-South Bend
Faisal Salim Shariff
Indiana University School of Medicine-South Bend
Jacob Speybroeck
Indiana University School of Medicine-South Bend
Anne Grisoli
Indiana University School of Medicine-South Bend
Meredith Wireman Schmidt
Saint Joseph Regional Medical Center
Htay Phyu
Saint Joseph Regional Medical Center
Jason Jablonski
Saint Joseph Regional Medical Center
Byars Wells
Saint Joseph Regional Medical Center
Dan H. Fulkerson
Saint Joseph Regional Medical Center
Lyndsay Oancea
Saint Joseph Regional Medical Center
Abraham Leiser
Indiana University School of Medicine-South Bend
Mark Walsh (markwalshmd@gmail.com)
Saint Joseph Regional Medical Center

Research Article

Keywords: COVID-19, anticoagulation, venous thromboembolism, hypercoagulable, clinical pharmacist, ultrasound

Posted Date: November 24th, 2020

DOI: https://doi.org/10.21203/rs.3.rs-113407/v1

License: This work is licensed under a Creative Commons Attribution 4.0 International License.
Read Full License

Impact of a clinical pharmacist in ultrasound-guided venous thromboembolism screening in hospitalized COVID-19 patients: a pilot prospective study.

Laura Gillespie[1] PharmD, Rashid Z. Khan[2] MD, John E. Stillson[3], Connor M. Bunch[3], Faisal Salim Shariff[3], Jacob Speybroeck[3], Anne Grisoli[3], Meredith Wiremen Schmidt[4] MD, Htay Phyu [4]MD, Jason Jablonski[1] PharmD, Byars Wells[5] MD, Dan H. Fulkerson[6] MD, Lyndsay Oancea[7] MD, Abraham Leiser[3], Mark Walsh[5,8] MD*

[1]Department of Pharmacy. Saint Joseph Regional Medical Center, Mishawaka, Indiana, USA. Email: gillesla@sjrmc.com (LG), jablonskij@sjrmc.com (JJ)

[2]Department of Hematology. Michiana Hematology Oncology, Mishawaka, Indiana, USA. Email: rkhan@mhopc.com (RK)

[3]Indiana University School of Medicine-South Bend, South Bend, Indiana, USA. Email: jstills@iu.edu (JES), cmbunch@iu.edu (CB), fshariff@iu.edu (FS), jspeybro@iu.edu (JS), agrisoli87@gmail.com (AG), markwalshmd@gmail.com (MW), aleiser@iu.edu (AL)

[4]Saint Joseph Infectious Diseases. Saint Joseph Regional Medical Center, Mishawaka, Indiana, USA. Email: meredithkatherine@yahoo.com (MWS), htay.phyu@sjrmc.com (HP),

[5]Department of Emergency of Medicine, St. Joseph Regional Medical Center, Mishawaka, Indiana, USA. Email: byarswells@gmail.com (BW), markwalshmd@gmail.com (MW)

[6]Department of Neurosurgery, St. Joseph Regional Medical Center, Mishawaka, Indiana, USA. Email: dfulkers1@gmail.com (DF)

[7]Department of Radiology, St. Joseph Regional Medical Center, Mishawaka, Indiana, USA. Email: loancea@xrcmi.com (LO)

[8]Department of Internal Medicine, St. Joseph Regional Medical Center, Mishawaka, Indiana, USA. Email: markwalshmd@gmail.com (MW)

26 *Corresponding Author:
27 Mark Walsh MD, FACEP
28 St. Joseph Regional Medical Center
29 5215 Holy Cross Pkwy, Mishawaka, IN 46545
30 Fax: 574-339-1111
31 Telephone: 574-339-3268
32 Email: markwalshmd@gmail.com
33
34
35
36

Abstract

Background: The recognition, prevention and treatment of venous thromboembolism (VTE) remains a major challenge in the face of the recent SARS-COV-2 pandemic which has been associated with significant cardiovascular, renal, respiratory and hematologic complications related to hypercoagulability. There has been little literature thus far on the utility of screening ultrasound and role of the clinical pharmacist in treating these patients.

Methods: We present a prospective pilot program of thirty-one consecutive SARS-CoV-2 patients who were provided four extremity screening ultrasounds for VTE on admission. This was coordinated by a clinical pharmacist as part of a multidisciplinary approach. Quantitative and qualitative data were recorded with the goal of describing the utility of the clinical pharmacist in ultrasound screening. Data collected include: demographics, information on clinical symptoms or signs at presentation, and laboratory and radiologic results during the hospitalization from each individual electronic medical record.

Results: Nine of the thirty-one patients presented with venous thrombosis. Of the nine patients, there were twenty-two total clotted vessels, all of which were asymptomatic. The clinical pharmacist, as the coordinator for a multidisciplinary COVID-19 associated coagulopathy management team, drafted a screening and treatment protocol for anticoagulation prophylaxis and therapy of VTE after ultrasound findings.

Conclusion: VTE screening of hospitalized SARS-CoV-2 patients reveals a significant number of asymptomatic VTEs and justifies diagnostic, prophylactic, and treatment measures coordinated by a clinical pharmacist.

Keywords: COVID-19, anticoagulation, venous thromboembolism, hypercoagulable, clinical pharmacist, ultrasound

Background

Patients hospitalized due to an acute illness have an elevated risk of venous thromboembolism (VTE) while in-hospital and for up to 45 days after hospitalization.[1-9] Patient survival is reduced significantly among patients with VTE, especially after a pulmonary embolism.[10] The risk of VTE in a patient with an acute infectious disease rises up to 32 times that of the general hospitalized patients in some reports.[4,5,11] This risk is elevated in patients hospitalized due to COVID-19, yet the level of risk is not clearly defined. Current laboratory parameters--such as prothrombin time/international normalized ratio, partial thromboplastin time, Clauss Fibrinogen, and D-Dimer--lack sensitivity and specificity for predicting VTE in COVID-19 patients.[12-17] We hypothesize that not only severely ill COVID-19 patients in the intensive care unit (ICU) are at risk of VTE, but also that COVID-19 patients hospitalized to the general floor can develop VTE without clinical signs or symptoms. To date, there is scant literature regarding the screening of extremities for VTE in COVID-19 patients admitted to an ICU.[12-17] Moreover, there is no current consensus regarding the criteria to predict those patients who require standard, high-dose prophylactic, or full anticoagulation treatment.

Therefore, it was decided to embark on a program of four extremity screening ultrasound for all patients admitted to the hospital with documented COVID-19. The coordination, collection, and presentation of data was the responsibility of the clinical pharmacist. The template for this multidisciplinary team in addressing anticoagulation was derived from trauma system models. In such models, the clinical pharmacist's duties include medication stewardship in addition to the screening, diagnosis, and monitoring of prophylactic and full anticoagulation treatment.[18-21] Since the start of the COVID-19 pandemic, experience from China, Europe and the United States has revealed that clinical pharmacists are essential for providing event-driven pharmaceutical care which goes beyond routine activities such as medication review, prescription support, and patient counselling.[13,14,22-25] Here, the coordination of four-extremity screening ultrasound for all admitted COVID-19 patients was added to the workload of the clinical pharmacist. In addition, the clinical pharmacist was tasked with assisting in the composition, editing and distribution of off-label anticoagulation protocols for prophylaxis and treatment.

Under the supervision of the clinical pharmacist thirty-one consecutive patients admitted to the general floor and the ICU were screened with four-extremity ultrasound for VTE. Simultaneously the clinical pharmacist, along with a

multidisciplinary team, defined the incidence of VTE in our cohort of COVID-19 patients, evaluated clinical and laboratory risk factors, and developed a treatment protocol. A similar screening and treatment protocol development process, headed by their respective clinical pharmacist, may be adopted by all hospitals to provide comprehensive care for the COVID-19 patient.

Methods

This study included patients with laboratory-confirmed COVID-19 infection who were admitted between April 28, 2020 and May 20, 2020. Clinical specimens were collected from a nasopharyngeal swab, sputum or bronchial aspirate. Diagnosis of COVID-19 infection was made with the reverse-transcriptase–polymerase-chain-reaction assay based on the World Health Organization standard that targets the SARS-CoV-2 E gene and RdRp gene.[26] Thirty-one adults (18 years of age or older) were identified. There were no pregnant women or children admitted to the ICU during the study period. The study protocol was in accordance with the Declaration of Helsinki, and approved by the local ethics committee (2020-00856). Data collected includes: demographics, information on clinical symptoms or signs at presentation, and laboratory and radiologic results during the hospitalization from each individual electronic medical record. All laboratory tests and additional radiologic assessments were performed at the discretion of the attending physician.

A clinical pharmacist was appointed by a multidisciplinary team to coordinate their efforts in identifying and treating COVID-19 patients with VTE. In concert with the infectious disease specialist and hematologist, the clinical pharmacist designed protocols for the ordering of salient laboratory parameters for anticoagulation, as well as criteria for extremity ultrasounds. The clinical pharmacist ordered all ultrasounds of the extremities, initiated and monitored anticoagulation agents, and also assured that all coagulation tests were ordered for each patient according to the defined protocol. Furthermore, the clinical pharmacist, utilizing laboratory and ultrasound findings, made anticoagulant adjustment recommendations.

Upper and lower limb venous compression ultrasound (CUS) was systematically performed in all patients by independent vascular specialists within the first two days of admission. The systematic CUS assessed proximal veins. The criterion for establishing the diagnosis of VTE was the lack of compressibility on B-mode ultrasound.[27]

Results

117 Thirty-one patients were screened during the initial phase from 28 April until 20 May 2020. No patient in whom
118 screening ultrasound detected VTE had overt symptoms defined as edema, erythema, or pain. VTE was identified in
119 nine (29%) patients. All nine (100%) patients with identifiable VTE were asymptomatic. In these nine patients, a
120 total of twenty-two clotted vessels were diagnosed (See Table 1). The clinical outcomes of patients and the anatomic
121 locations of vessel occlusion are also shown in Table 1. There were nine VTEs noted in the upper extremities. None
122 of these patients had a peripherally inserted central catheter (PICC). Of these nine patients with asymptomatic clots,
123 five were admitted to the ICU and all five were intubated. Demographic analysis of the patients is listed in Tables 1
124 and 2.

125 Table 1: Characteristics of screened COVID-19 patients positive for VTE on CUS

Characteristics and clinical data on admission*	Patients N = 9
Mean Age (SD =14.5)	59.5
Female (#)	33.3% (3)
Male (#)	66.7% (6)
BMI (SD)	32.68 (9.13)
Comorbidities no. (%)	
Hypertension	2 (22.2%)
Cardiovascular disease	4 (44.4%)
COPD	3 (33.3%)
OSA	1 (11.1%)
Hepatitis	1 (11.1%)
Peripheral Vascular Disease	1 (11.1%)
Malignancy	1 (11.1%)
Diabetes	1 (11.1%)
Renal Failure	4 (44.4%)
Paraplegia	1 (11.1%)
Singulitis	1 (11.1%)
Anatomic localization of clot	
Upper Extremity	15 (68.2%)
Axillary	2 (22.2%)
Basillic	6 (66.7%)
Brachial	3 (33.3%)
Cephallic	4 (44.4%)
Lower Extremity	4 (18.2%)
Perineal	1 (11.1%)
Common Femoral	1 (11.1%)
Posterior Tibial	2 (22.2%)
Other	3 (13.6%)
Subclavian	1 (11.1%)
Internal Jugular	1 (11.1%)
Common Iliac	1 (11.1%)
Total Number of Clotted Vessels	22
Disposition	
ICU no. (%)	5 (55.6%)
Intubation no. (%)	5 (55.6%)
Death no. (%)	1 (11.1%)

126

127 * For gender and comorbidities, percentage of patients is based on a total of 9 VTE positive patients. For anatomic
128 localization of clotted vessels, percentage is calculated based on a total of twenty-two clotted vessels.

129 Table 2: Characteristics of screened COVID-19 testing negative for VTE on CUS.

Characteristics and clinical data on admission*	Patients N = 22
Mean Age (SD =17.2)	59.0
Female (#)	31.8% (7)
Male (#)	68.2% (15)
BMI (SD)	31.3 (9.05)
Comorbidities no. (%)	
Hypertension	11 (50.0%)
Cardiovascular disease	0 (0.00%)
COPD	2 (9.09%)
OSA	1 (4.55%)
Hepatitis	0 (0.00%)
Peripheral Vascular Disease	1 (4.55%)
Malignancy	1 (4.55%)
Diabetes	9 (40.9%)
Renal Failure	1 (4.55%)
Paraplegia	0 (0.00%)
Singulitis	0 (0.00%)
Disposition	
ICU no. (%)	0 (0.00%
Intubation no. (%)	0 (0.00%
Death no. (%)	0 (0.00%

130

131 *For Gender and comorbidities, percentage of patients is based on a total of 22 VTE negative patients

132

133 A protocol for prophylactic and therapeutic anticoagulation was evaluated and revised on a weekly basis by the
134 clinical pharmacist in accordance with guidelines published by the International Society of Hemostasis and
135 Thrombosis. A summary of the current protocol for evaluation and treatment is shown in Fig. 1.

136

137 Figure 1: Outline of Saint Joseph Hospital System (SJHS) Recommended VTE Prophylaxis and Treatment for
138 COVID-19 patients.[1,13,14]

139

140 All medication administration was coordinated by the clinical pharmacist. Patients in our study received VTE
141 prophylaxis with daily weight-based subcutaneous enoxaparin or with unfractionated subcutaneous heparin in daily
142 or divided doses. Patients with anatomically proven VTE were treated with weight based subcutaneous enoxaparin
143 or with intravenous (IV) unfractionated heparin. Finally, patients admitted to the ICU without anatomic evidence of

144 VTE were treated with either intermediate doses of weight based enoxaparin or with therapeutic weight based doses
145 of IV unfractionated heparin.

146 **Discussion**

147 Recent evidence suggests that trauma-induced coagulopathy may be comparable to the hypercoagulable nature of
148 COVID-19 patients.[28,29] Post-resuscitation trauma patients are at high risk for developing VTE and multiorgan
149 failure due to a shock-induced endotheliopathy and fibrinolytic shutdown. Similar to trauma patients, the mortality
150 and outcome for COVID-19 patients may improve with higher intensity VTE prophylaxis or full anticoagulation to
151 prevent the formation of micro thromboemboli in the pulmonary vasculature.[30-44] COVID-19 coagulopathy, like
152 trauma induced coagulopathy, is characterized by a spectrum of hyper- to hypo-coagulable states in the same
153 patient. Selection and intensity of anticoagulation in these patients requires a dynamic means of evaluation involving
154 screening, prophylaxis, and treatment for VTE.[13,14,45] In light of the similar coagulopathies of COVID-19 and trauma
155 patients, it is logical that both patient groups benefit from the expert management of a clinical pharmacist. In our
156 hospital, the clinical pharmacist already coordinated the administration of therapies such as antivirals, convalescent
157 plasma, targeted immunotherapy, and IV antibiotics. The responsibilities of the clinical pharmacist were expanded
158 to include screening and treatment of COVID-19 coagulopathies, including four extremity screening ultrasound for
159 VTE.

160 Nine patients (29%) who received screening ultrasound were found to have asymptomatic VTE despite no
161 PICC line, one of the strongest risk factors for upper extremity clots. Significantly, this supports the
162 hypercoagulopathic state associated with COVID-19 and the need for an evidence-based pharmacologic treatment
163 protocol.[8-10,13,15,16,30,46] Recent literature from China, Europe, and the United States has revealed an expanding role
164 for the clinical pharmacist given the evolving nature of guidelines for treating COVID-19 patients.[13,14,22-25] Here, the
165 clinical pharmacist drafted guidelines employing ultrasound screening for VTEs to guide anticoagulation therapy;
166 the pharmacist's role is particularly important with increased off-label use of medications during the COVID-19
167 pandemic.

168 Among patients with a negative ultrasound screening for VTE, none were admitted to the ICU or intubated
169 (See Table 2). Five of the nine VTE positive patients diagnosed by ultrasound screening were later admitted to the
170 ICU and each of those five patients was also intubated. A high incidence of VTE in COVID-19 patients admitted to
171 the ICU has recently been reported.[17] Significantly, this demonstrates the importance of having a clinical pharmacist

172 guide screening and therapy for the complex coagulopathy found in COVID-19 patients. With the findings in this
173 study, the authors hope to prompt similar utilization of pharmacists to prevent clotting or bleeding complications in
174 COVID-19 patients.

175 **Conclusions**

176 We present a pilot experience of a prospective evaluation protocol for COVID-19 associated VTE
177 coordinated by a clinical pharmacist. This clinical pharmacist facilitated COVID-19 patients' ultrasound screening,
178 diagnosis, and monitoring of prophylactic and full anticoagulation treatment. [18-21,47] This multidisciplinary team was
179 adapted from previous programs that utilized a similar dynamic for management of trauma-related anticoagulation
180 prophylaxis and treatment. (46,47) Nine of thirty-one (29%) COVID-19 patients had radiographic evidence of VTE
181 despite no clinical symptoms on initial presentation. These results confirm the recent emphasis on aggressive VTE
182 prophylaxis and treatment due to the relatively high risk of VTE in COVID-19.[13,14] Moreover, these results support
183 the importance of having a clinical pharmacist coordinate screening ultrasound for VTE in COVID-19 patients and
184 management of their anticoagulation. This study demonstrates the dynamic and foundational role the clinical
185 pharmacist can play in the management of coagulopathies in the COVID-19 patient.

186

187 List of abbreviations: venous thromboembolism (VTE); intensive care unit (ICU); compression ultrasound (CUS);
188 peripherally inserted central catheter (PICC); intravenous (IV)

189

Declarations

Ethics approval and consent to participate

- The study protocol was in accordance with the Declaration of Helsinki, and approved by the local ethics committee of Saint Joseph Regional Medical Center (2020-00856)

Consent for publication

- Not applicable

Availability of data and materials

- The datasets used and/or analysed during the current study are available from the corresponding author on reasonable request.

Competing interests

- MW receives research grants from Haemonetics Incorporated, Boston, MA and is on the speaker's bureau for Portola Incorporated San Francisco, CA. All other authors have no conflicts to report.

Funding

- No funding to declare

Authors' contributions

- LG, RK, FS, JS, AG, MWS, HP, JJ, BW, LO, MW contributed to the collection and interpretation of data. JES, CB, RK, MW, FS, JS, RK, MW contributed to the literature review. LG, RK, JES, CB, FS, JS, MW contributed to writing the paper. All authors contributed to critical review and revision of the paper.

Acknowledgements

- None

1. Spyropoulos AC, Anderson Jr FA, FitzGerald G, et al. Predictive and associative models to identify hospitalized medical patients at risk for VTE. Chest. 2011;140:706-14.
2. Amin AN, Varker H, Princic N, Lin J, Thompson S, Johnston S. Duration of venous thromboembolism risk across a continuum in medically ill hospitalized patients. J Hosp Med. 2012;7:231-8.
3. Cohoon KP, Ashrani AA, Crusan DJ, Petterson TM, Bailey KR, Heit JA. Is infection an independent risk factor for venous thromboembolism? A population-based, case-control study. Am J Med. 2018;131:307-16. e2.
4. Smeeth L, Cook C, Thomas S, Hall AJ, Hubbard R, Vallance P. Risk of deep vein thrombosis and pulmonary embolism after acute infection in a community setting. Lancet. 2006;367:1075-9.
5. Schmidt M, Horvath-Puho E, Thomsen RW, Smeeth L, Sørensen HT. Acute infections and venous thromboembolism. J Intern Med. 2012;271:608-18.
6. Konstantinides SV, Meyer G, Becattini C, et al. 2019 ESC Guidelines for the diagnosis and management of acute pulmonary embolism developed in collaboration with the European Respiratory Society (ERS). Eur Heart J. 2020;41:543-603.
7. Wang L, Sengupta N, Baser O. Risk of venous thromboembolism and benefits of prophylaxis use in hospitalized medically ill US patients up to 180 days post-hospital discharge. Thromb J. 2011;9:15.
8. Danzi GB, Loffi M, Galeazzi G, Gherbesi E. Acute pulmonary embolism and COVID-19 pneumonia: a random association? Eur Heart J. 2020;41:1858.
9. Xie Y, Wang X, Yang P, Zhang S. COVID-19 complicated by acute pulmonary embolism. Radiol Cardiothorac Imaging. 2020;2:e200067.
10. Heit JA, Silverstein MD, Mohr DN, Petterson TM, O'Fallon WM, Melton LJ. Predictors of survival after deep vein thrombosis and pulmonary embolism: a population-based, cohort study. Arch Intern Med. 1999;159:445-53.
11. Rogers MA, Levine DA, Blumberg N, Flanders SA, Chopra V, Langa KM. Triggers of hospitalization for venous thromboembolism. Circulation. 2012;125:2092-9.
12. Longchamp A, Longchamp J, Manzocchi-Besson S, et al. Venous thromboembolism in critically ill patients with COVID-19: results of a screening study for deep vein thrombosis. Res Pract Thromb Haemost. 2020.

247 13. Cohoon KP, Mahé G, Tafur AJ, Spyropoulos AC. Emergence of institutional antithrombotic protocols for
248 coronavirus 2019. Res Pract Thromb Haemost. 2020.
249 14. Thachil J, Tang N, Gando S, et al. ISTH interim guidance on recognition and management of coagulopathy
250 in COVID-19. J Thromb Haemost. 2020;18:1023-6.
251 15. Zhou F, Yu T, Du R, et al. Clinical course and risk factors for mortality of adult inpatients with COVID-19
252 in Wuhan, China: a retrospective cohort study. Lancet. 2020.
253 16. Panigada M, Bottino N, Tagliabue P, et al. Hypercoagulability of COVID-19 patients in Intensive Care
254 Unit. A Report of Thromboelastography Findings and other Parameters of Hemostasis. J Thromb Haemost.
255 2020.
256 17. Llitjos JF, Leclerc M, Chochois C, et al. High incidence of venous thromboembolic events in
257 anticoagulated severe COVID-19 patients. J Thromb Haemost. 2020.
258 18. Anderegg SV, DeMik DE, Carter BL, et al. Acceptance of Recommendations by Inpatient Pharmacy Case
259 Managers: Unintended Consequences of Hospitalist and Specialist Care. Pharmacotherapy. 2013;33:11-21.
260 19. Scrimenti A, Seabury RW, Miller CD, et al. Pharmacist recommendations for prophylactic enoxaparin
261 monitoring and dose adjustment in trauma patients admitted to a surgical intensive care unit. Pharm Pract
262 (Granada). 2019;17:1541.
263 20. Devlin JW, Tyburski JG, Moed B. Implementation and evaluation of guidelines for use of enoxaparin as
264 deep vein thrombosis prophylaxis after major trauma. Pharmacotherapy. 2001;21:740-7.
265 21. Walker CK, Sandmann EA, Horyna TJ, Gales MA. Increased enoxaparin dosing for venous
266 thromboembolism prophylaxis in general trauma patients. Ann Pharmacother. 2017;51:323-31
267 22. Cadogan CA, Hughes CM. On the frontline against COVID-19: Community pharmacists' contribution
268 during a public health crisis. Res Social Adm Pharm. 2020.
269 23. Li H, Zheng S, Liu F, Liu W, Zhao R. Fighting against COVID-19: Innovative strategies for clinical
270 pharmacists. Res Social Adm Pharm. 2020.
271 24. Liu S, Luo P, Tang M, et al. Providing pharmacy services during the coronavirus pandemic. Int J Clin
272 Pharm. 2020;42:299-304.

25. Zheng S-q, Yang L, Zhou P-x, Li H-b, Liu F, Zhao R-s. Recommendations and guidance for providing pharmaceutical care services during COVID-19 pandemic: A China perspective. Res Social Adm Pharm. 2020.
26. Corman VM, Landt O, Kaiser M, et al. Detection of 2019 novel coronavirus (2019-nCoV) by real-time RT-PCR. Eurosurveillance. 2020;25:2000045.
27. Lensing AW, Prandoni P, Brandjes D, et al. Detection of deep-vein thrombosis by real-time B-mode ultrasonography. New Engl J Med. 1989;320:342-5.
28. Moore HB, Moore EE, Neal MD, et al. Fibrinolysis shutdown in trauma: historical review and clinical implications. Anesth Analg. 2019;129(3):762-773.
29. Meizoso JP, Karcutskie CA, Ray JJ, Namias N, Schulman CI, Proctor KG. Persistent fibrinolysis shutdown is associated with increased mortality in severely injured trauma patients. J Am Coll Surgeons. 2017;224(4):575-582.
30. Moore HB, Barrett CD, Moore EE, et al. Is there a role for tissue plasminogen activator as a novel treatment for refractory COVID-19 associated acute respiratory distress syndrome?. J Trauma Acute Care. 2020;88(6):1.
31. Brill JB, Badiee J, Zander AL, et al. The rate of deep vein thrombosis doubles in trauma patients with hypercoagulable thromboelastography. J Trauma Acute Care. 2017;83:413-9.
32. Coleman JR, Kay AB, Moore EE, et al. It's sooner than you think: Blunt solid organ injury patients are already hypercoagulable upon hospital admission-Results of a bi-institutional, prospective study. Am J Surg. 2019;218:1065-73.
33. Cotton BA, Minei KM, Radwan ZA, et al. Admission rapid thrombelastography predicts development of pulmonary embolism in trauma patients. J Trauma Acute Care. 2012;72:1470-7.
34. McCrath DJ, Cerboni E, Frumento RJ, Hirsh AL, Bennett-Guerrero E. Thromboelastography maximum amplitude predicts postoperative thrombotic complications including myocardial infarction. Anesth Analg. 2005;100:1576-83.
35. Harahsheh Y, Duff OC, Ho KM. Thromboelastography predicts thromboembolism in critically ill coagulopathic patients. Crit Care Med. 2019;47:826-32.

300 36. Myers SP, Kutcher ME, Rosengart MR, et al. Tranexamic acid administration is associated with an
301 increased risk of posttraumatic venous thromboembolism. J Trauma Acute Care. 2019;86:20-7.
302 37. Moore HB, Moore EE, Neal MD, et al. Fibrinolysis shutdown in trauma: historical review and clinical
303 implications. Anesth Analg. 2019;129(3):762-73.
304 38. Moore H, Moore E, Gonzalez E, et al. Hyperfibrinolysis, physiologic fibrinolysis, and fibrinolysis
305 shutdown: the spectrum of postinjury fibrinolysis and relevance to antifibrinolytic therapy. J Trauma Acute
306 Care. 2014;77:811-7; Discussion 7.
307 39. Moore HB, Moore EE, Liras IN, et al. Acute fibrinolysis shutdown after injury occurs frequently and
308 increases mortality: A Multicenter Evaluation of 2,540 Severely Injured Patients. J Am Coll Surg.
309 2016;222:347-55.
310 40. Leeper CM, Neal MD, McKenna CJ, Gaines BA. Trending fibrinolytic dysregulation: fibrinolysis
311 shutdown in the days after injury is associated with poor outcome in severely injured children. Ann Surg.
312 2017;266:508-15.
313 41. Meizoso JP, Karcutskie CA, Ray JJ, Namias N, Schulman CI, Proctor KG. Persistent fibrinolysis shutdown
314 is associated with increased mortality in severely injured trauma patients. J Am Coll Surg. 2017;224:575-
315 82.
316 42. Roberts DJ, Kalkwarf KJ, Moore HB, et al. Time course and outcomes associated with transient versus
317 persistent fibrinolytic phenotypes after injury: a nested, prospective, multicenter cohort study. J Trauma
318 Acute Care. 2019;86:206-13.
319 43. Hardaway RM, Harke H, Tyroch AH, Williams CH, Vazquez Y, Krause GF. Treatment of severe acute
320 respiratory distress syndrome: a final report on a phase I study. Am Surg. 2001;67:377-82.
321 44. Wang J, Hajizadeh N, Moore EE, et al. Tissue plasminogen activator (tPA) treatment for COVID-19
322 associated acute respiratory distress syndrome (ARDS): A case series. J Thromb Haemost. 2020.
323 45. Wright FL, Vogler TO, Moore EE, et al. Fibrinolysis Shutdown Correlates to Thromboembolic Events in
324 Severe COVID-19 Infection. J Am Coll Surg. 2020.
325 46. Yao XH, Li TY, He ZC, et al. A pathological report of three COVID-19 cases by minimal invasive
326 autopsies. Zhonghua Bing Li Xue Za Zhi. 2020;49:411-7.

327 47. Walker CB, Moore EE, Kam A, et al. Clot activators do not expedite the time to predict massive
328 transfusion in trauma patients analyzed with tissue plasminogen activator thrombelastography. Surgery.
329 2019;166(3):408-15.
330
331
332

Figures

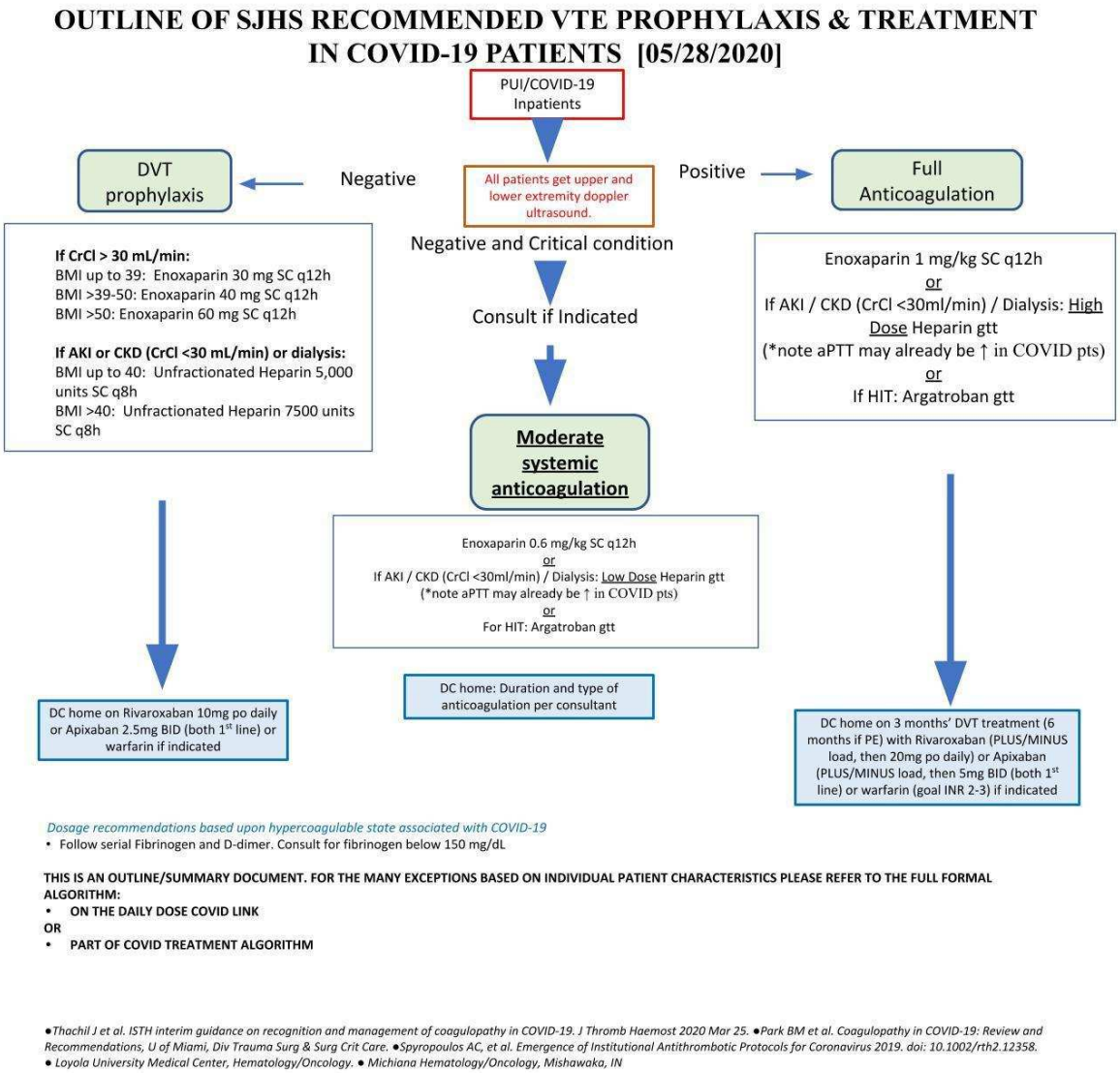

Figure 1

Outline of SJHS Recommended VTE Prophylaxis & Treatment IN COVID-19 Patients