Concomitant Surgical Transatrial And Transapical Approach For CRT-D Implantation In A Patient With Severe Chest Burn Skin Injury: Case Report

Adam Riba (adam8804@gmail.com)
Zala County St. Rafael Hospital https://orcid.org/0000-0002-1985-4503

Roland Toth
Zala County St. Rafael Hospital

Aref Rashed
Zala County St. Rafael Hospital

Barnabás Németh
Zala County St. Rafael Hospital

Ferenc Árvai
Zala County St. Rafael Hospital

Géza Lupkovics
Zala County St. Rafael Hospital

Karoly Gombócz
Zala County St. Rafael Hospital

Tamas Tahin
Zala County St. Rafael Hospital

Research Article

Keywords: CRT-D, minimally invasive, transatrial-transapical approach

Posted Date: February 22nd, 2022

DOI: https://doi.org/10.21203/rs.3.rs-1135892/v1

Abstract

Introduction: According to the current clinical guidelines, CRT-D implantation is indicated for patients with history of malignant ventricular arrhythmias, symptomatic heart failure, wide QRS or high-degree AV block.

Case presentation: A patient with DCM received a CRT-D with the conventional method but 1 month later skin necrosis was diagnosed above the device. We believed, that the 40 years old burn injury was the reason for the necrosis, resulted from the altered microcirculation of the skin. The complete system was extracted from the patient and we utilized negative pressure wound therapy for the treatment of the remaining tissue. We decided to perform surgical reimplantation of the device using mini thoracotomy: right atrial and right ventricular leads were introduced through the right atrial appendage and the left ventricular lead was inserted transapically. The device was implanted under the less scabby abdominal skin. 6 weeks later there was no sign of other complications and the surgical wounds were healed completely.

Conclusions: We successfully applied the combination of trans-atrial and trans-apical lead placement, which has not been reported in the literature yet. It serves as an alternative method, if the standard approach is not feasible.

Introduction:

According to the current clinical guidelines, cardiac resynchonisationy therapy device with defibrillator (CRT-D) implantation is indicated for patients with history of malignant ventricular arrhythmias, symptomatic heart failure, wide QRS or high-degree AV block [1]. However, there are certain conditions where the standard implantation approach is not applicable due to congenital or acquired conditions.

Case Report:

A patient with dilated cardiomyopathy (DCM) underwent conventional CRT-D implantation using left subclavian vein access following a successful resuscitation due to ventricular tachycardia. One month later skin necrosis was detected above the device. Our hypothesis was, that burn injury - which he suffered fourty years prior - has damaged the microcirculation of the skin and was accountable for the necrosis. The complete system was explanted, and we utilized negative pressure wound therapy for the treatment of the remaining tissue.

Figure 1. A: 3 weeks after the implantation. B: The complete system was removed, and a large tissue gap remained. C: Negative pressure of 125 Hgmm was applied, to cover the tissue defect and facilitate tissue regrowth D: 3 weeks after the device explantation. With continuous negative pressure wound therapy the absence of skin tissue was almost completely closed.

We decided to perform surgical reimplantation of the device using mini thoracotomy: right atrial and right ventricular leads were introduced through the right atrial appendage and the left ventricular lead was inserted transapically.

Surgical Technique:

For mini-thoracotomy, a vertical right lateral 5.5 cm long skin incision was made over the fourth right intercostal space just anterior to the midaxillary line. Single-lung ventilation was initiated, and the right lung was retracted posteriorly. The pericardium was carefully opened.

A guidewire was inserted with Seldinger's technique through the puncture of right appendage into the right atrium. The wire was then exchanged to a sheath and a right ventricular shock electrode was introduced. Eventually it was positioned and secured to the right ventricular apex under fluoroscopy guidance with good electrode parameters. The right atrial lead was also introduced with the same method and positioned with a J-shaped stylet into the anterior part of the right auricle. Bleeding was controlled and the electrodes were secured with purse-string sutures around the puncture points Fig 2.A).

Next, the ideal site for the incision to reach the apex of the left ventricle was identified and marked by transthoracic echocardiography guidance at the corresponding intercostal space. A second mini thoracotomy was performed on the left side of thorax. A guidewire was inserted with Seldinger's technique through the puncture of the apex into the left ventricle. After removal of the guide wire, the pacing electrode was inserted into the LV cavity through the sheath and peel-off sheath was removed. Bleeding from the LV was controlled with purse-string sutures around the puncture point (Fig. 2.B). Fluoroscopy was utilized for the endocardial fixation of the electrode at the lateral wall of the left ventricle (Fig. 2.E).

The device was implanted in the abdominal area, where the skin was almost intact, below the diaphragm and the electrodes were tunneled (Fig. 2.C). Anticoagulation was initiated becouse of the foreign body in the left ventricle. 6 months later there was no sign of complications, and the surgical wounds healed completely.

Figure 2. Surgical CRT-D implantation. A: Right lateral mini thoracotomy. The right ventricular and right atrial leads are positioned and fixed with purse-string sutures. B: Left lateral mini thoracotomy. The left ventricular lead was introduced through the apex of the left ventricle. C: The leads were pulled through tunnels into the abdominal part and attached to the CRT-D device. D: Positioning of the leads was carried out with fluoroscopy guidance. E: Good parameters were recorded at the end of the procedure. F: 6 months after the surgery

Discussion:

CRT is a well-established therapy for patients with HF and ventricular dissynchrony. The side branches of the coronary sinus are the first choice of sites for left ventricular lead implantation. However, BiVP does

have some challenges, including high pacing threshold, unavoidable phrenic nerve stimulation, the rate of non-responders and rarely, chest deformities and the rate of unsuccessful implantation. Several minimally invasive alterative implantation techniques have been developed [2, 3]. Tehniques, involving transvenous approach can not be obtained in our case becouse the reimplantation of the device in the conventional subclavicular region was not possible. Several authors recommend pocket change and subpectoral placement, but the skin could not been sutured properly as a result of the previous burn injury. Transfemoral lead insertion with CRT-P implantation was also reported but this technique can not adopted for a patinent requiring an ICD [4]. Therefore, we chose a surgical, but minimal invasive approach for implanting the leads. With our approach, some similarly challenging cases of complex device implantations can be successful.

Life-long anticoagulation was initiated after the procedure with a target INR level equivalent to mitral prosthetic valves (2.5-3.5). This approach is not an option for patients with contraindication to anticoagulation. For them the only possible solution is the epicardial implantation (if the conventional transvenous also failed).

We successfully applied the combination of trans-atrial and trans-apical lead placement in a CRT-D device, which has not been reported in the literature yet. It serves as an alternative method in selected cases, where the standard approach is not feasible.

List Of Abbrevations:

AV: atrio-ventricular; CRT-D: Cardiac resynchronisation therapy with defibrillator; DCM: dilated cardiomyopathy, ICD: implantable cardiac defibrillator; LV: left ventricle; RV: right ventricle; RA: right atrium; HF: heart failure;

Declarations:

Funding: the study did not receive any financial support.

Conflict of interest: None decleared.

Ethics approval: Ethics approval was granted by the Ethics Review Committee of the Zala County St. Raphael Hospital, Zalaegerszeg, Hungary (Approval number: IKEB-2019/1).

Consent to participate: Need for informed consent to participate was waived by the Ethics Review Committee of the Zala County St. Raphael Hospital as the study was retrospective.

Consent for publication: Written informed consent was obtained from the patient for publication.

Code availability: Data available upon reasonable request from the corresponding author.

Authors' contributions TT, AR, ArR and RT contributed to the study design, data analysis and drafting of the manuscript. AR and BN performed the first CRT implantation. ArR, RT and KG performed the surgery. TT, FA and GL reviewed the manuscript. All authors read and approved the final manuscript.

Acknowledgements: Not applicable.

References:

[1] M. Glikson *et al.*, "2021 ESC Guidelines on cardiac pacing and cardiac resynchronization therapy," (in eng), *Eur Heart J,* vol. 42, no. 35, pp. 3427-3520, Sep 14 2021, doi: 10.1093/eurheartj/ehab364.

[2] I. Kassai *et al.*, "Transapical approach to optimize left ventricular resynchronization in patients with dilated cardiomyopathy," (in eng), *Multimed Man Cardiothorac Surg,* vol. 2017, Apr 26 2017, doi: 10.1510/mmcts.2017.005.

[3] L. Gellér *et al.*, "Long-term single-centre large volume experience with transseptal endocardial left ventricular lead implantation," (in eng), *Europace,* vol. 21, no. 8, pp. 1237-1245, Aug 01 2019, doi: 10.1093/europace/euz116.

[4] P. S. Chaggar, C. Skene, and S. G. Williams, "The transfemoral approach for cardiac resynchronization therapy," (in eng), *Europace,* vol. 17, no. 2, p. 173, Feb 2015, doi: 10.1093/europace/euu340.

Figures

Figure 1

A: 3 weeks after the implantation. B: The complete system was removed, and a large tissue gap remained. C: Negative pressure of 125 Hgmm was applied, to cover the tissue defect and facilitate tissue regrowth D: 3 weeks after the device explantation. With continuous negative pressure wound therapy the absence of skin tissue was almost completely closed.

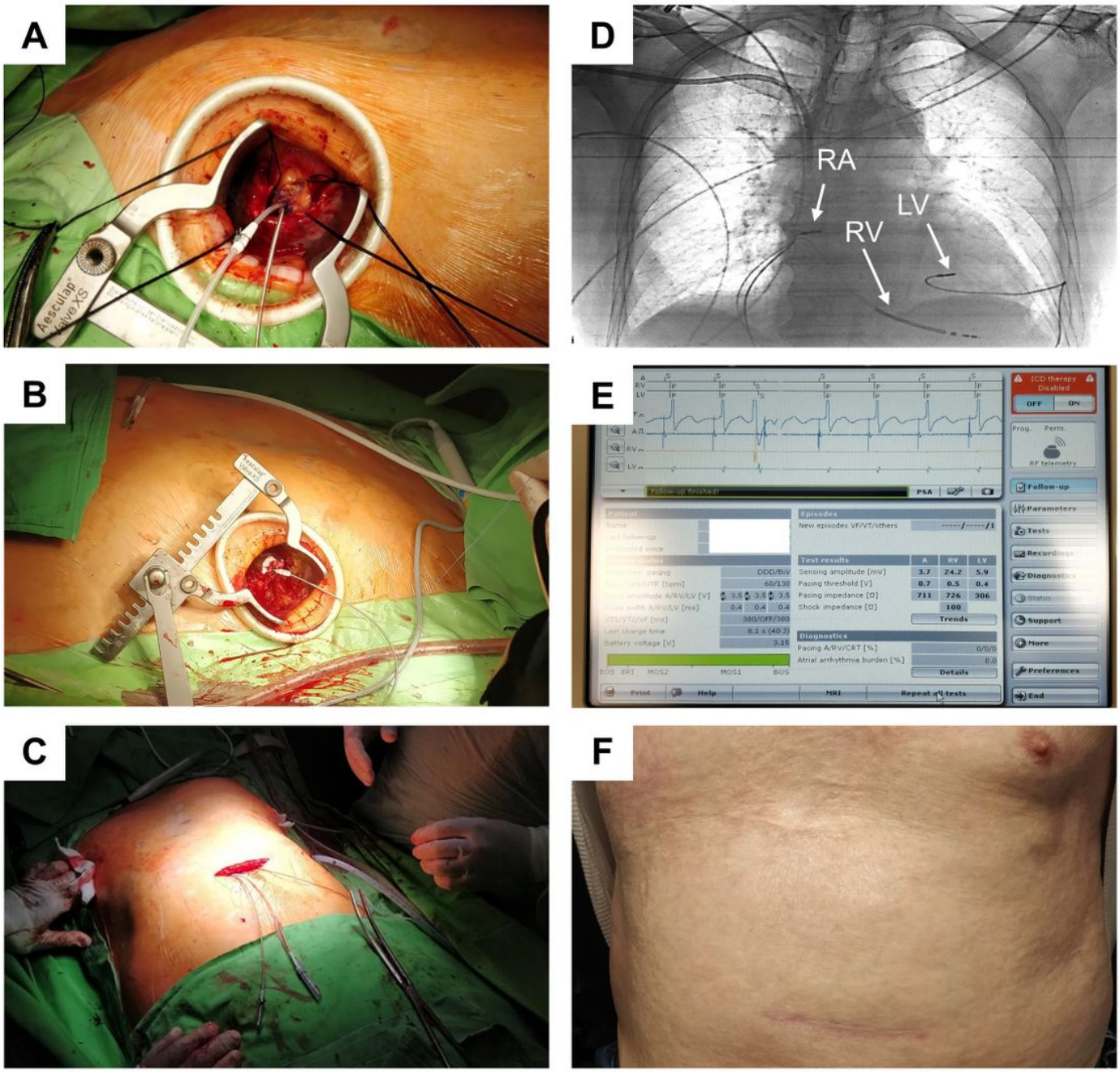

Figure 2

Surgical CRT-D implantation. A: Right lateral mini thoracotomy. The right ventricular and right atrial leads are positioned and fixed with purse-string sutures. B: Left lateral mini thoracotomy. The left ventricular lead was introduced through the apex of the left ventricle. C: The leads were pulled through tunnels into the abdominal part and attached to the CRT-D device. D: Positioning of the leads was carried out with fluoroscopy guidance. E: Good parameters were recorded at the end of the procedure. F: 6 months after the surgery

Supplementary Files

This is a list of supplementary files associated with this preprint. Click to download.

- carechecklistfilledout.pdf
- video1.mp4