Scleral Buckling Surgery in the Treatment of Retinal Detachment in Children – Own Results

Dorota Barchanowska (dbarchanowska@sum.edu.pl)
UCK im. Prof. Kornela Gibińskiego, Hospital https://orcid.org/0000-0001-7764-6174

Erita Filipek
Prof Kornel Gibiński Independent Public Central Clinical Hospital Medical University of Silesia in Katowice: Uniwersyteckie Centrum Kliniczne im prof K Gibinskiego Slaskiego Uniwersytetu Medycznego w Katowicach

---

Research article

Keywords: retinal detachment, scleral buckling, visual function, children

Posted Date: December 1st, 2020

DOI: https://doi.org/10.21203/rs.3.rs-114233/v1

Abstract

Background:

Retinal detachment it is a condition in which there is a disconnection between neuronal layer and choroidal layer of the retina, which is the pigment epithelium.

The aim of our work was to evaluate the changes of visual acuity to the distance and to the nearest before and after surgery, and during the observation period, the assessment of anatomical length changes of the eyeball , the assessment of the intraocular pressure in the eyes after the procedure, the assessment of changes of the anatomical success to the retina using ultrasound in the projection (B).

Methods:

An 5- year retrospective study involved 73 children aged 5-17 years (average age 11 years), who were operated due to retinal detachment. Patients were treated in the years 2013-2018 (June) in Pediatric Department of Ophthalmology in Katowice.

The obtained results were subjected to statistical analysis using the STATISTICA 13.3 software program. We used the non- parametric Mann- Whitney U- test.

Results:

Among a group of operated children in 39% of retinal detachment due to head trauma or orbital area. About 29% children had average or high myopia due to the value-14.0 Dsph. 14% of children had retinal detachment due to retinopathy of prematurity, which had the vitrectomy at the end of the therapy. 18% of retinal detachment are caused by other factors-for example: infection of Toxocara or recurrent uveitis.

The effect of application of the retina managed to get in 71% of eyes in the test group. 28% of eyes in this group require additional application of laser retinal as a complement to the residual retinal detachment. So obtained secondary effect of application of retinal eye surgery. While 29% of the eyes needed vitrectomy with vitreoproliferation and in the course of the retinopathy of prematurity.

Conclusion:

Retinal detachment is a very serious ophthalmologic condition that requires rapid surgical intervention.The latitudinal enlacement treatment is a treatment that does not disturb the proper development of the eyeball. The effect of the treatment is not predictable.

The anatomical condition described as the retinal application does not always lead to a functional effect.

Background

Retinal detachment is a condition in which the retinal nervous system is detached from the functionally layer associated with the choroidal layer, in other words the epithelial epithelium.

The traditional division of retinal detachments is distinguished by three types: rhegmatogenous, traction and exudative. Rhegmatogenous retinal detachment occurs in the world with a frequency of 6.5-18 cases per 100,000 inhabitants.

In children, rhegmatogenous retinal detachment occurs on average at the age of 13 years and more often in boys.(1)

According to some reports, it occurs more often in warm months - June or July. It may be related to dehydration of the vitreous body and greater production of free oxygen radicals. (2)

The risk factor is accelerated and rapid detachment of the vitreous, which can occur in myopic eyes, after injuries or surgery. Also the eyes with the inflammatory process predispose to retinal detachment.

Patophysiology:

Retinal detachment results from the posterior detachment of the vitreous body as a result of changes in its morphology and as a result of the existence of traction in a place more prone to tear, which facilitates the passage of fluid under the retina.

The process of the posterior detachment of the vitreous body, i.e. its liquefaction, is a natural aging process, but in predisposed eyes it may proceed in a pathological way. Premature aging of the vitreous body occurs in myopic eyes or in eyes with an inflammatory process such as uveitis, after injuries or other surgical procedures. Accelerated flow of the vitreous also occurs in the course of general diseases in which there is disturbed metabolism of II type of collagen - Marfan's syndrome, Ehlers-Danlos and Stickler’s syndrome. The aging mechanism of the vitreous body is not fully understood. According to various theories, it may start with the gradual degradation of glycosaminoglycans, secondarily it causes a change in interaction with II, IX and XI type of collagen. In addition, the role of free oxygen radicals and metalloproteinase enzymes is important(3).

Retinal photoreceptors are metabolically dependent on pigmented epithelial cells, after losing this contact, they gradually degenerate. These changes occur several hours after the separation of both layers.

According to studies on an animal model, apoptosis of photoreceptors may start as early as 8 hours after the detachment, and 90% of cells die within the first 3 days.(5) As a response of retinal cells to the new anatomical situation, the hyperplasia of astrocytes mediated by Muller cells and vimentin protein occurs. In the future, inhibition of vimentin protein expression may prevent the retinal proliferation.

Risk factors for retinal detachment:

1. symptomatic posterior detachment of the vitreous,

2. high myopia with biometrics > 26.00 mm, which corresponds to - 6.0 Dsph. It is believed that 55% of retinal detachment is not related to trauma myopic eyes. (2.4)
3. Injury - 10% of all retinal detachments are associated with an eye injury. The time from the injury to the detachment can vary from minutes up to 40 years, but 80% of the detachments are diagnosed within 1 year of the injury.
4. Checkered degeneration - risk in 30-40% retinal detachment.

Treatment:

Retinal surgery is based on two basic principles:

- tamponade of the hole,
- restoration of retinal adhesion.

In order to resume the function of the pigment epithelium as a photoreceptor nourishing pump. There are two surgical techniques: conventional surgery- epidural implant or cerclage with a puncture or intraocular procedures - PPV.

Indications for conventional surgery include:

- a single hole,
- a small number of peripheral degenerations,
- primary and local delamination,
- low traction,
- lack of PVR,
- young age.

In publications created since 1990, the percentage of primary application ranges from 85% to 90%, and the final 95%. If the spot before the procedure is applied, the chance of visual acuity above 0.4 is 80%, , if the layer is delaminated the chance is 30%.(6) Already in 1923 Jules Gonin- presented the results of his work in the surgery of retinal detachment at the meeting of the French Society of Ophthalmology and he was named the "father" of the retinal detachment surgery. Ernst Custodis has earned a role in retinal detachment surgery by introducing scleral malformations treatment. Charles Schepens, in 1953, introduced a scleral enlacement technique.

In the case of traction retinal detachment, the most common cause is proliferative diabetic retinopathy, trauma that frequently penetrates the presence of a foreign body and retinopathy of premature babies. Treatment of traction retinal detachment is usually a vitrectomy procedure through the flat part of the ciliary body.

The causes of exudative retinal detachment include:

- idiopathic causes - Coats' disease,
- congenital- nodular developmental n II, gladiola flower syndrome,
- Postoperative - panfotocoagulation, in hemorrhagic choroid disconecction,
- associated with inflammation - sinusitis, secondary to uveitis,
- proliferative diseases - choroidal melanoma, retinoblastoma, lymphomas.

Exudative retinal detachment may also occur in the course of hypertensive retinopathy, preeclampsia, eclampsia, leukemia. Treatment of exudative retinal detachment depends on pathomechanism and etiology.

Methods

The aim of our work was to assess changes in visual acuity to distance and nearest vision before and after surgery, and during the observation period, assessment of changes in the length of the eye's anatomy axis, assessment of changes in intraocular pressure in the eyes after surgery, assessment of changes in retinal application in USG in B projection.

Patients were children treated in 2013-2018 (June) at the Children's Ophthalmology Clinic in Katowice.

There were 73 children between the ages of 5 and 17 years, average age of 11 years, in which 73 were operated due to retinal detachment. Among the group of examined children, 39% of retinal detachment was caused by injury to the head or orbital area. 29% of the children had a medium or high degree of myopia to the value of -14.0 Dsph. In 14% of the children, the detachment was caused by retinopathy of prematurity, which had the vitrectomy at the end of the therapy. 18% of the detachments are other causes - e.g. Toxocara or recurrent uveitis.

The children were qualified for the latitudinal cerclage procedure based on a slit lamp examination, based on changes in visual acuity, ultrasound examination results and ERG and visual potential (VEP) tests. In all children before the surgery, the ultrasound examination showed retinal detachment, most often in the lower and upper temporal quadrants. Some children showed complete retinal detachment with an open funnel up to a height of 1.5-2.0 mm. The children were operated under general anesthesia. After the treatment were applied: local treatment with antibiotic, mydriatic and anti-inflammatory non-steroidal.

The following were assessed: changes in visual acuity for distance and nearest vision, changes in the length of the anatomical axis of the eyeball, intraocular pressure, configuration of the retina in ultrasonography in B projection before surgery, after surgery and during the observation period.

The obtained results were subjected to statistical analysis using the STATISTICA 13.3 software program. We used the non- parametric Mann- Whitney U- test.

Results

In the examined patients the visual acuity of distant was on average 0.28 on admission. After the surgery, it was on the level of 0.31, and subsequent periods of observation are presented in Table I and Figure 1. The average value of visual acuity before surgery was 0.3. In the distant observation period 0.4.

In the examined patients the visual acuity of nearest was on average 1,13 on admission. After the surgery, it was on the level of 1,21 and subsequent periods of observation are presented in Table II and Figure 2. The average value of visual acuity before surgery was 1,0. In the distant observation period 0,6.

The latitudinal cerclage procedure did not cause significant changes in intraocular pressure in the eyes assessed.

Observation are presented in Table III and Figure 3.

Another analyzed parameter: change in the length of the anatomical axis of the eyeball before and after the surgery. Observation are presented in Table IV and Figure 4. There were no significant changes in the length of the anatomical axis of the eyeballs in the operated children.

Discussion

Retinal reattachment was achieved in 71% of eyes with the studied group. In the case of 28%, additional applications of the retinal laser were required as a complement to residual detachment. A secondary effect of retinal operation of the operated eyes was obtained. However, in 29% of cases, a pars plana vitrectomy was required through the most often in cases with vitreoproliferation and in the course of retinopathy of premature babies.zMany researchers also addressed the subject of analyzing the results of treatment of children after eye cerclage procedure.

Butler and co-authors (7) examined 15 children with an average age of 12.4 years who underwent a latitudinal enlacement treatment. In 40% of children, the detachment was caused by injury, in 15% of children myopia (greater than -6.0), lenghtenedness in 10% of children, in other children, the detachment occurred in the eyes with retinopathy of premature babies. Anatomical retina application was obtained in 86.5% of children - 13 children. The average visual acuity after surgery was 0.5, it was 26.6% of children. in our case, the average visual acuity of operated patients was 0.4.

Read and co-authors (8) analysis an analysis of the results of children operated on due to retinal detachment. There were 206 patients (231 eyes), 25 children had retinal detachment on both sides, which required surgical supply. 67 children had traction retinal detachment (premature babies, PHPV), 51 children of retinal detachment was caused by the aperture (dissection related to chromosome X, myopia), 60 children had retinal detachment due to injury. The best corrected visual acuity achieved by the authors was 0.1. Anatomical retinal application was best achieved in children with hole derivative retinal detachment and it was 78%. In our studies we obtained the effect of the primary retinal application in 71% of eyes.

In the work of Pieczara (9) and co-authors, retinal detachment was mainly caused by blunt injuries (57.1%). In our case, injuries accounted for 39% of retinal detachment. When analyzing surgical techniques, there have been reports on the use of Endo tools during latitudinal cerclage. Jo J (10) and Shanmugam (11) used conventional chandelier's lighting and scleral sclerosis to facilitate banding. As new techniques require refinement and a wider introduction to surgery.

Meier (12) in his work he emphasizes that retinal detachment in children represent a small percentage, it is only 3.2 -6.6% of total detachment. Unfortunately, the percentage of successes, that is, functional and anatomical application are worse than in adults.

It is also worth paying attention to the possibility of retinal detachment in the second eye, it is about 15%. Therefore, it is important to apply preventive treatment - retinal laser retraction, avoiding unnecessary and dangerous efforts.

Conclusions

Retinal detachment is a very serious ophthalmologic condition that requires rapid surgical intervention.

The latitudinal enlacement treatment is a treatment that does not disturb the proper development of the eyeball.

The effect of the treatment is not predictable.

The anatomical condition described as the retinal application does not always lead to a functional effect.

Abbreviations

PPV- pars plana vitrectomy

PVR- proliferation vitreous- retinal

VEP- visual evoked potential

ERG- electroretinogram

Declarations

Acknowledgments

Not aplicable.

Authors' contributions

Concept and design: DB, EF. Material preparation, data collection: DB. Statistical analysis: DB.

Drafting of the manuscript: DB. Critical revision of the manuscript for important intellectual content: DB, EF. Supervision: EF, DB.

All authors confirmed that this manuscript has not been published, either in whole or in part, and is not in press or under review elsewhere. All authors approved the final manuscript and agreed with its submission to BMC Ophthalmologhy.

Funding

Not applicable.

Availability of data and materials

The data that support the findings of this study are available on request from the corresponding author DB.

Ethics approval and consent to participate

The study has been approved by the medical ethics committee of the Medical University of Silesia in Katowice. Written informed consent was obtained from the parents of each participant.

Consent for publication

Not applicable.

Competing interests

The authors declare no competing financial or non- financial interests.

References

1. Basic and Clinical Science Course, część 12, Siatkówka i ciało szkliste. Str:293-300,Wyd.1polskie pod red. K. Pecold , Wydawnictwo Medyczne Elsevier Urban&Partner, Wrocław 2007.
2. Caputo G, Metge F,Arndt C, Conrath J: Decollements de Retnie. Societe Francaise d'Ophthalmologie et Masson, Paris 2011.
3. Siwiec- Prościńska J, Rospond- Kubiak I: Okulistyka- program edukacyjny „ Kompendium Okulistyki", Odwarstwienie siatkówki, str 4-5, Zeszyt 2,2012.
4. Heimann H: Netzhautablosung,Teil 1: Vorstufen, Sympoamatik Und diagnstisches Vorgehen. Augenheilkunde up2date 2012.
5. Lewis G, Mervin K, Valter K, Maslim J, Kappel PJ, Stone J, Fisher S: Limiting the proliferation and reactivity of retinal Muller cells during experimenatal retinal detachment: the vale of oxygen supplemantation. Am J Ophthalmol 1999, 128, 165-172.

6. Hoerauf H, Heimann H, Hansen L, Laqua H: Skleraeindellende Ablatio-chirurgie Und pneumatische Retinopexie Techniken, Indikationen Und Ergebnisse. Ohpthalmologe 2008,105,7-18.
7. Butler TKH, Kiel AW, Orr GM: Anatomical and Visual outcome of retinal detachment surgery In children.Br. J. Ophthalmol 2001;85:1437-1439.
8. Read SP, Aziz HA, Kuiryan A, Kothari N, Davis JL, Smiddy WE at All: Retinal Detachment burgery In a pediatric population: Visual and Anatomical Outcomes. Retina 2018.Jul;38(7):1393-1402.
9. Pieczara E, Formińska- Kapuścik M, Filipek E, Nawrocka L, Wójcik- Niklewska B: Opierścienienie twardówki w leczeniu odwarstwień siatkówki u dzieci i młodzieży. Magazyn Lekarza okulisty 4 (5) 2010, 238-243.
10. Jo J, Moon BG, Lee JY: Scleral Buckling using a non-contact wide angle viewing system with a 25-Gauge Chndelier endoilluminatior.Korean J Ophthalmol.2017 Dec;31(6):533-537.
11. Shanmugam PM, Ramanjulu R, Mishra KCD, Sagar P: Novel techniques In scleral buc kling. Indian J Ophthalmol.2018 Jul;66(7): 909-915.
12. Meier P. Retinal detachment In children : differentia diagnosis and current therapy. Klin Monbl Augenheilkd. 2008 Sep;225 (9):779-90.

Tables

Due to technical limitations, table 1-4 is only available as a download in the Supplemental Files section.

Figures

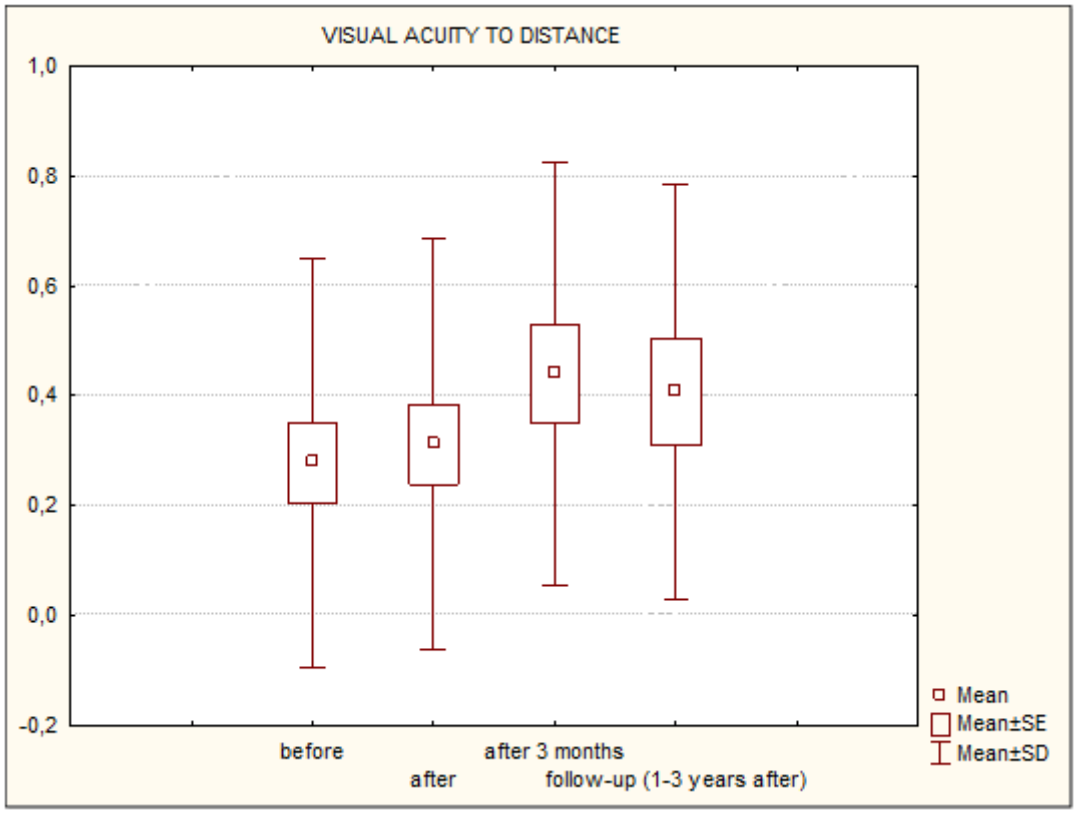

Figure 1

After the surgery, it was on the level of 0.31, and subsequent periods of observation are presented in Table I and Figure 1.

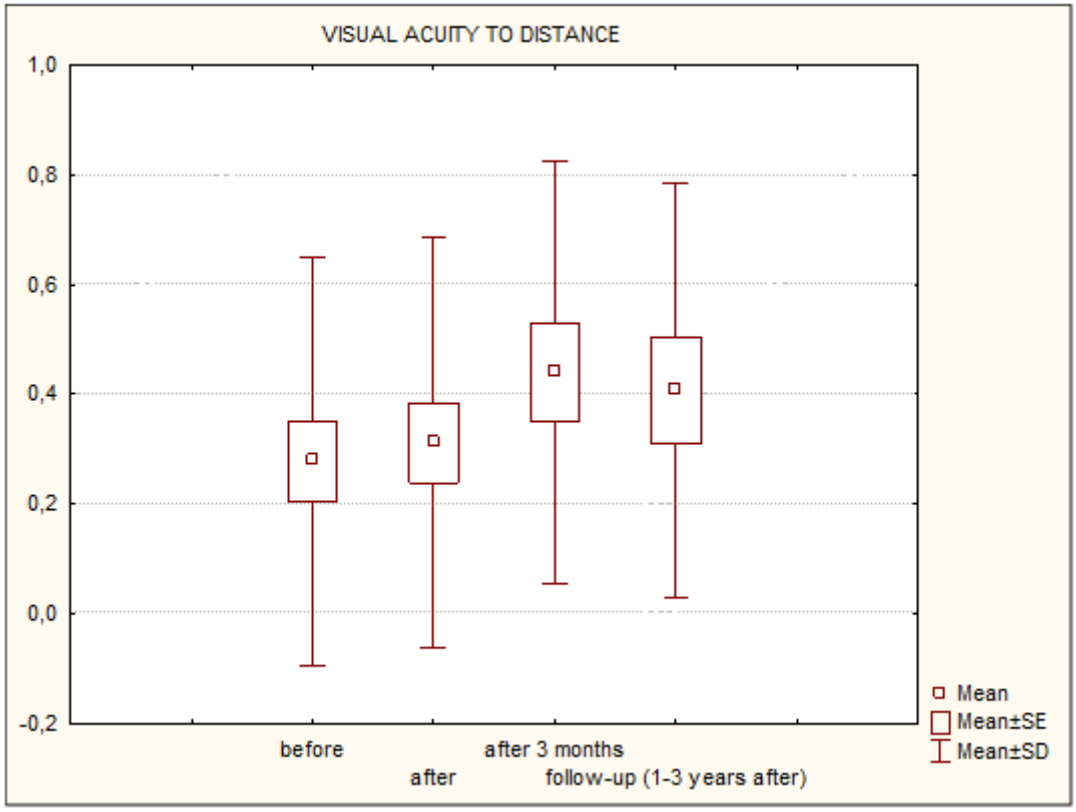

Figure 1

After the surgery, it was on the level of 0.31, and subsequent periods of observation are presented in Table I and Figure 1.

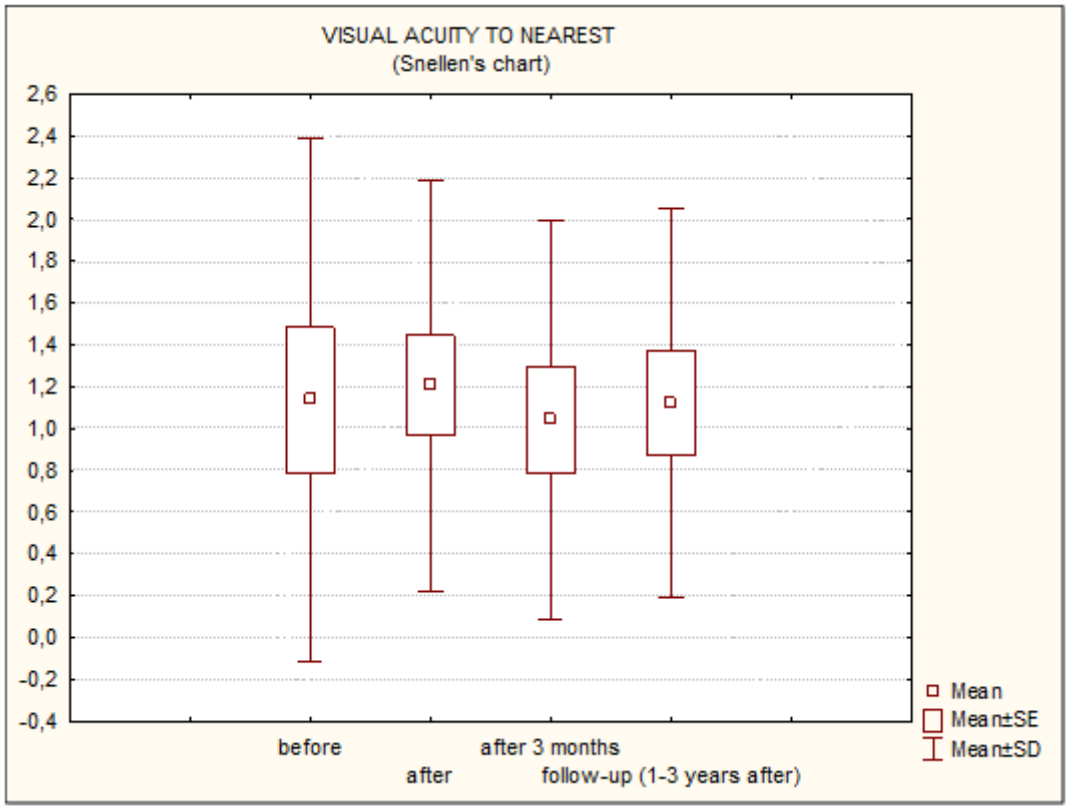

Figure 2

After the surgery, it was on the level of 1,21 and subsequent periods of observation are presented in Table II and Figure 2.

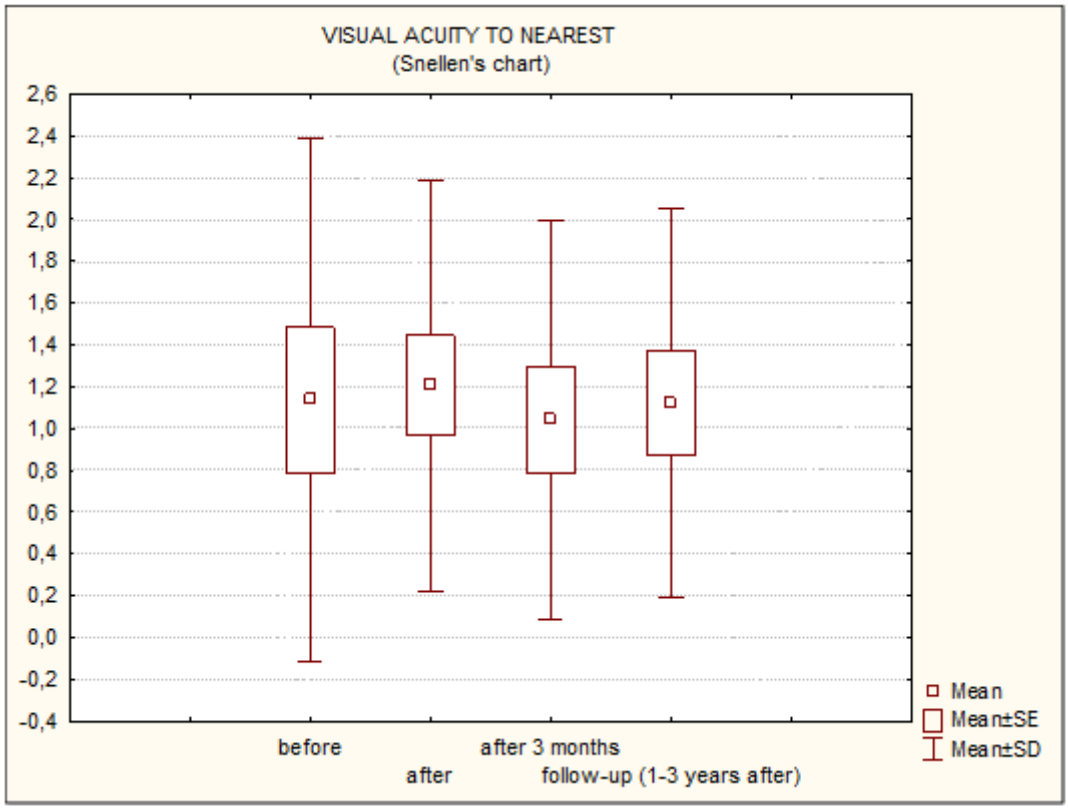

Figure 2

After the surgery, it was on the level of 1,21 and subsequent periods of observation are presented in Table II and Figure 2.

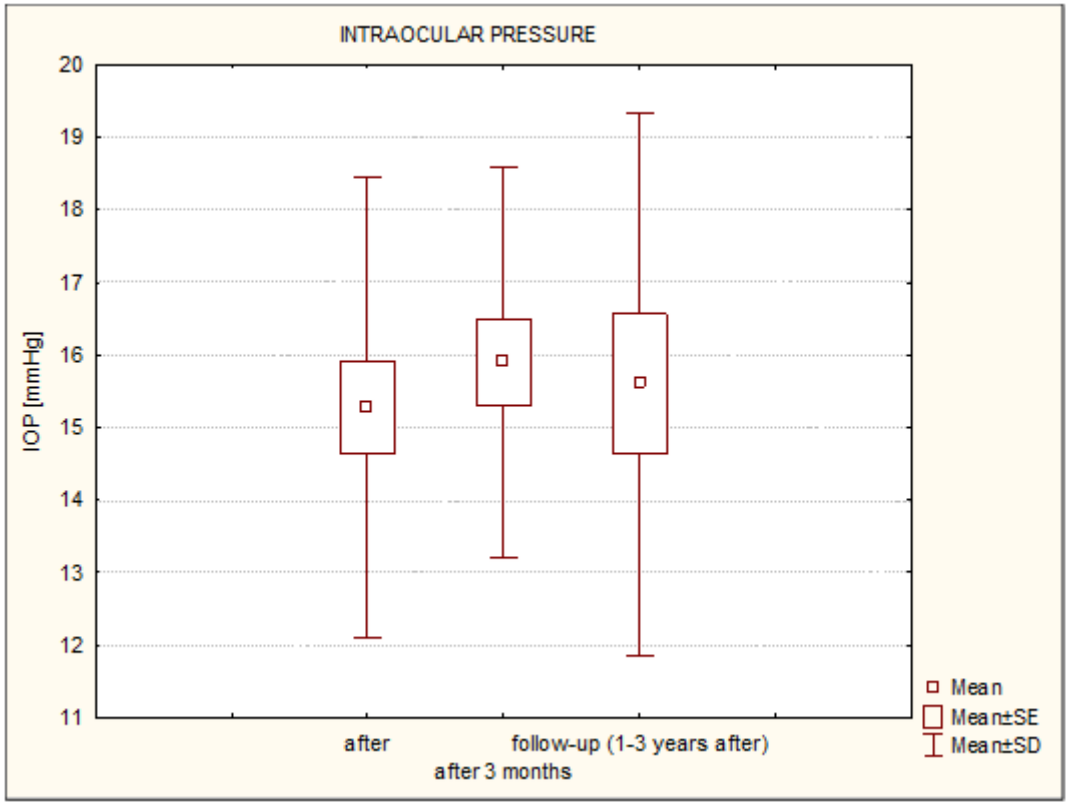

Figure 3

Observation are presented in Table III and Figure 3.

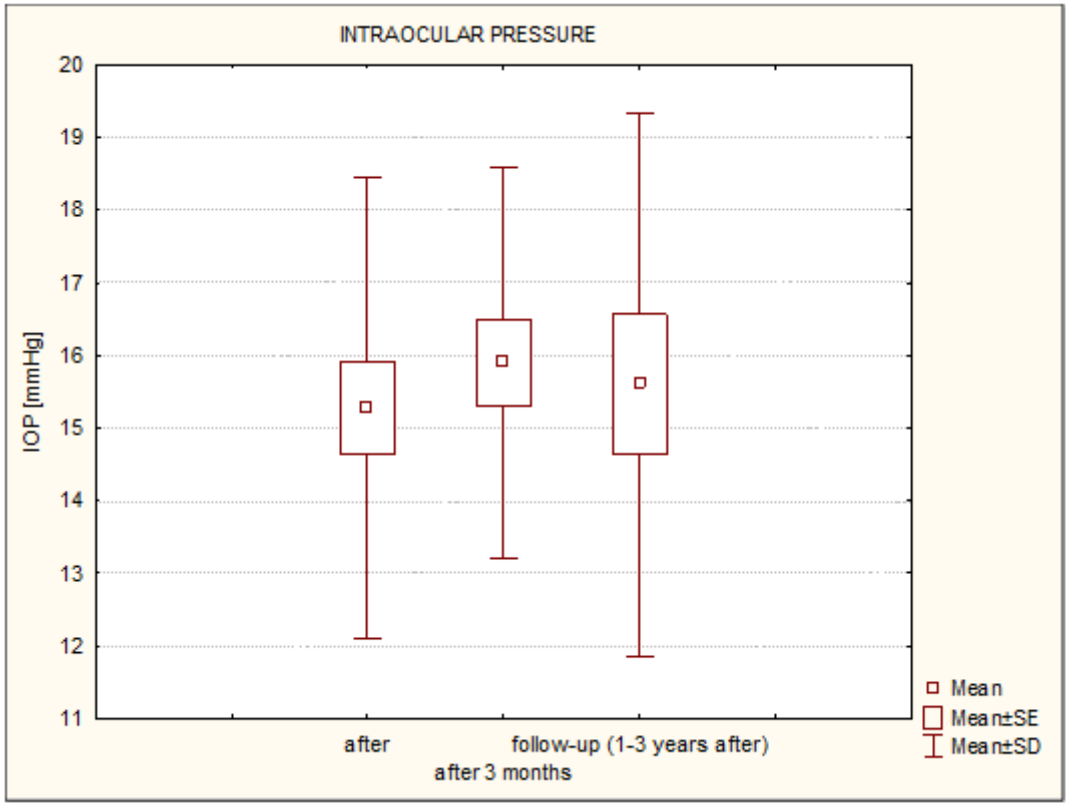

Figure 3

Observation are presented in Table III and Figure 3.

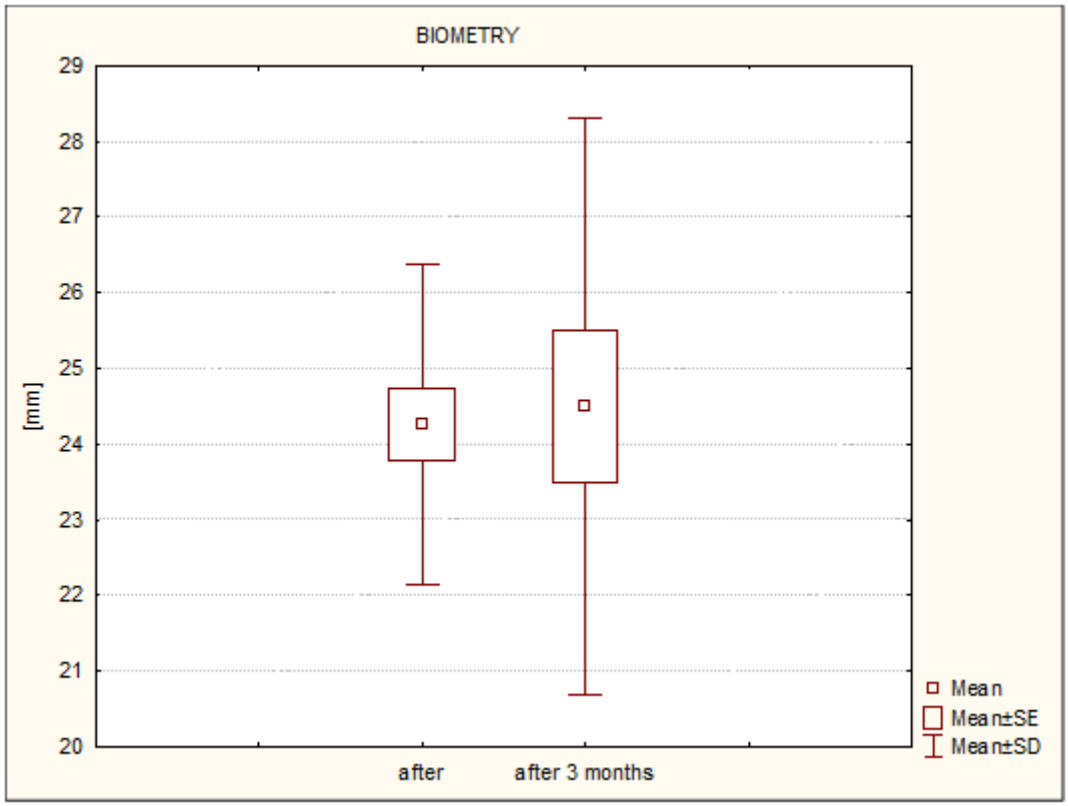

Figure 4

Another analyzed parameter: change in the length of the anatomical axis of the eyeball before and after the surgery. Observation are presented in Table IV and Figure 4.

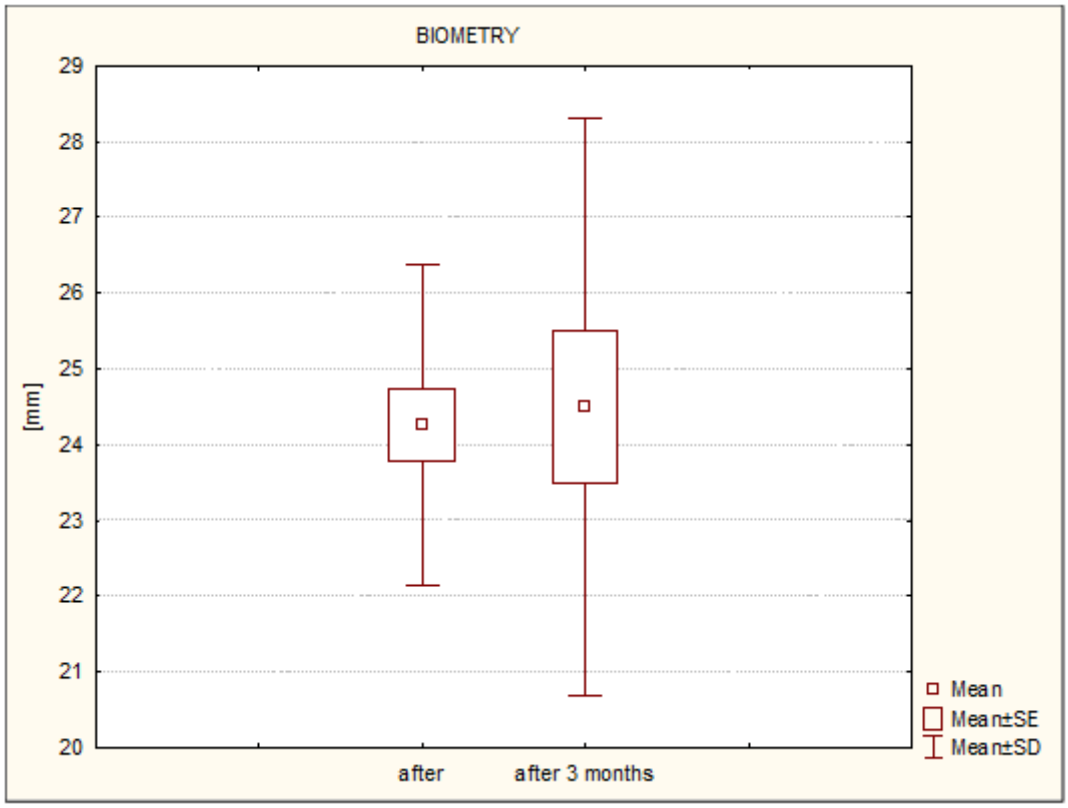

Figure 4

Another analyzed parameter: change in the length of the anatomical axis of the eyeball before and after the surgery. Observation are presented in Table IV and Figure 4.

Supplementary Files

This is a list of supplementary files associated with this preprint. Click to download.

- Tab1.png
- Tab1.png
- Tab2.png
- Tab2.png
- Tab3.png
- Tab3.png
- Tab4.png
- Tab4.png