The influence of different hook tip depths on the treatment of acromioclavicular joint dislocation with clavicular hook plate – a retrospective study

ding xu (xuding831129@126.com)
shangyu people's hospital,shaoxing city,china https://orcid.org/0000-0002-7634-4315

Peng Luo
Wenzhou Medical University

Yulong Shi
Rheinisch-Westfalische Technische Hochschule Aachen

Weikang Wang
Rheinisch-Westfalische Technische Hochschule Aachen

Weijun Guo
Wenzhou Medical University

Jianming Chen Chen
Ningbo No 6 Hospital

Research article

Keywords: hook tip depth, acromioclavicular joint dislocation, hook plate, efficacy, complication

Posted Date: January 15th, 2020

DOI: https://doi.org/10.21203/rs.2.20880/v1

Version of Record: A version of this preprint was published at Asian Journal of Surgery on August 1st, 2021. See the published version at https://doi.org/10.1016/j.asjsur.2021.07.050.

Abstract

Background

The purpose of this study was to research the effect of different hook depths on the efficacy and complications of AC dislocation treatment with hook plate, and to provide valuable reference for clinical treatment.

Method

We retrospectively analyzed the prospectively collected data from 305 consecutive patients with AC joint dislocation between April 2013 and May 2017 at our institute. We defined hook tip depth as the position of the hook tip relative to the acromion at the coronal plane. According to the division where the tip of the hook was located, the cases were divided into Group A, Group B, Group C, and D group. All patients were required to conform to regular follow up postoperatively. Dislocation and implant maintenance are assessed by routine shoulder imaging. Functional results were evaluated using Constant-Murley criteria.

Results

A total of 305 cases were included in follow-up and 27 cases were lost. We used Constant-Murley criteria to evaluate functional results. The score of Group B was significantly higher than group A and group C ($P<0.01$). For evaluation of acromioclavicular joint reduction, we used CCD in imaging to evaluate. There was significant difference between the three groups. Joint reduction was obtained in all patients. Postoperative infection and hardware failure did not present. There were no fractures of acromion and coracoids process. There were 83 cases of shoulder pain, 93 cases of SIS and 124 cases of subacromial erosion. The incidence of complications in group A was significantly higher than group B and group C.

Conclusions

The relative position of the hook tip and acromion can significantly affect the efficacy and complications of the clavicular hook plate in the treatment of acromioclavicular joint dislocation. During surgery, we should control the depth of hook tip and try our best to put the tip of the hook into the area of group B to achieve an ideal postoperative effect and avoid the occurrence of various complications.

Background

Acromioclavicular joint (AC) dislocation was a common trauma, accounting for about 9% of shoulder injury (1). It was mainly caused by direct violence. When the shoulder joint was in the adduction position, the violence acted on the acromion and shifted it inwards and downwards. The transmission of force could make the acromioclavicular ligament, coracoclavicular ligament, deltoid muscle and trapezius muscle damage at the clavicular stop (2). At present, there were more than 75 kinds of surgical treatment of acromioclavicular joint dislocation in the literature (2, 3), but there was still controversy about the "gold standard" surgical technique. The treatment of acromioclavicular joint dislocation with clavicular hook

plate was currently a widely used surgical method. It was screwed on the distal end of the clavicle, and the cross-hook was placed under the acromion. The clavicular hook under the acromion and the steel plate fixed to the clavicle formed leverage and provided stable pressure on the distal end of the clavicle to maintain the position after dislocation reset. At the same time, it allowed the acromioclavicular joint to move slightly and provided similar motion to the normal acromioclavicular joint. This surgical treatment could be used to treat acute injuries and could be combined with ligament reconstruction to treat chronic injuries with good short-term results. Kienast (4) et al used clavicular hook plate to treat 225 cases of type III-V acute acromioclavicular joint dislocation. According to the Constant score (average of 92.4 points), 84% of patients achieved excellent clinical efficacy, but the complication rate was 10.6%. However, with the promotion and application of this technology, potential complications had surfaced, such as subacromial osteolysis, acromioclavicular fractures, hook plate bending, AC joint arthritis, hook displacement and subacromial impingement syndrome (SIS) etc (4–8). With regard to the causes of these complications and how to prevent them, a large number of scholars conducted research. Some of them analyzed from the perspective of biomechanics, and some scholars studied from the anatomical matching (9–11). However, these studies lacked the validation of large sample of clinical follow-up. Our research reviewed the cases of more than 300 who treated by hook plate from a unique perspective of hook depth to study the effect of different hook depths on the efficacy and complications of AC dislocation treatment with hook plate, and to provide valuable reference for clinical treatment.

Methods

Patients

We retrospectively analyzed the prospectively collected data from 305 consecutive patients with AC joint dislocation between April 2013 and May 2017 at our institute. Acromioclavicular joint dislocation was classified using the method described by Rockwood et al (12).

The inclusion criteria for the research were as follows: (1) acute, AC joint dislocation (grade III, IV, V, and VI) determined according to the classification described by Rockwood et al; (2) no more than 14 days of trauma; (3) signed informed consent; (4) no history of AC joint dislocation or other shoulder trauma; (5) no previous surgery on the shoulder. The exclusion criteria were as follows: (1) other types (grade I, II) of AC joint dislocation; (2) no signed informed consent.

We defined hook tip depth as the position of the hook tip relative to the acromion at the coronal plane. Firstly, we divided the acromion into four equal parts along the midline which were represented by A, B, C, and D (Figure 1). Then according to the division where the tip of the hook was located, the cases were divided into Group A, Group B, Group C, and D group (Figure 2).

The research protocol was approved by the Institutional Review Board of the authors' institute. Written informed consent was obtained from all of the participants, and the research methods were carried out in accordance with approved guidelines. The entire process was shown in Figure 3.

Operation

Anesthesia was performed with brachial plexus anesthesia or general anesthesia. An incision of approximately 6 cm in length was made at the distal end of the clavicle, its distal end stopped at about 1cm of acromioclavicular joint distal. After that, we revealed the distal clavicle and acromioclavicular joint, reset acromioclavicular joint dislocation and temporarily maintained the reset state. In order to reduce the soft tissue embedding between the clavicle hook and the acromion, we inserted the clavicle hook to the subacromial periosteum and fixed it. Then we pressed the medial end of the clavicular hook plate against the upper surface of the clavicle and fixed it on the clavicle with screws. Injured limb was suspended by bandages for 2 weeks, passive exercise was performed within 2 weeks, active exercise was started 2 weeks later, and load training was began 3 months later.

Clinical Evaluation

All cases were regularly followed up after surgery as required. Anteroposterior and lateral radiographs were required to be photographed to assess the condition of acromioclavicular joint reduction and the loss of coracoclavicular distance (CCD) on preoperative, postoperative, and final follow-up. Constant-Murley criteria was used to evaluate the postoperative functional status of patients, including 4 items (13). Hardware removal was carried out at 6 to 12 months postoperatively, and the functionality was reevaluated when patients got recovered. At the same time, radiograph was repeated to evaluate the situation of AC joint.

Statistics

Means and standard deviations (SDs) were used to describe all numerical data. One-way ANOVA tests were used to compare the means of numerical data. The $\chi 2$ test was used for non-numerical data. Values of 0.05 represent a statistically significant difference. Analyses were performed using SPSS version 21 (IBM).

Results

General results

A total of 305 cases were included in follow-up and 27 cases were lost. The overall follow-up rate was 91.1%. Group A included a total of 88 cases with an average age of 41.534±10.340 years, 47 cases were males and 41 cases were females. There were 10 cases lost to follow-up. According to Rockwood classification, 73 cases belonged to Rockwood III, 2 cases were included in Rockwood IV and Rockwood V was in 13 cases. According to the type of injury, there were 24 cases of Car accident injury, 19 cases of

Falling injury, 41 cases of Fell and hurt and 4 cases of other injuries. The ratio of the left and right shoulders was 33/55. A total of 109 cases were in Group B with an average age of 42.440±10.263 years, 60 cases were males and 49 cases were females. 9 cases lost follow-up. According to Rockwood classification, 93 cases belonged to Rockwood III, 5 cases were included in Rockwood IV and Rockwood V was in 11 cases. According to the type of injury, there were 24 cases of Car accident injury, 22 cases of Falling injury, 56 cases of Fell and hurt and 7 cases of other injuries. The ratio of the left and right shoulders was 47/62. 77 cases were included in group C with an average age of 43.389±9.976 years, 47 cases were males and 30 cases were females. 8 cases lost follow-up. According to Rockwood classification, 74 cases belonged to Rockwood III, 7 cases were included in Rockwood IV and Rockwood V was in 6 cases. According to the type of injury, there were 19 cases of Car accident injury, 17 cases of Falling injury, 38 cases of Fell and hurt and 3 cases of other injuries. The ratio of the left and right shoulders was 29/48. Only 4 cases were included in the D group, and it was excluded to analysis because the sample size was too small. All the above mentioned basic case data was not statistically significant different between the three groups (P>0.05). The operation time for the three groups was 44.977±8.529, 45.945±8.694 and 43.779±8.271min. Injury-to-surgery interval was 4.738±1.878, 4.899±1.943 and 4.870±1.866 days respectively. There was also no difference between the three groups (P>0.05). Before removal of hook plate, the follow-up time was 8.125±2.021, 8.477±2.167 and 7.948±1.870 months in Group A, Group B and Group C. After removal of hook plate, the follow-up time was 9.545±2.238, 9.238±2.090 and 9.792±2.148 months in three groups. Similarly, there was no statistical difference between them (Table 1).

Functional evaluation results

For evaluation of postoperative patient function, we evaluated it in two stages. One was “Before removal of hook plate” and another was “After removal of hook plate”. We used Constant-Murley criteria to evaluate. The scoring system had 4 items that were pain, ADL, strength and Rom respectively. Before removal of hook plate, the Constant scores were 63.386±8.271, 74.348±6.889 and 70.493±7.456 in three groups. In statistical analysis, the score of Group B was significantly higher than group A and group C (P<0.01). In detail, the three groups were 6.704±3.781, 10.504±3.596 and 9.220±4.141 respectively in terms of pain. In ADL, Group A was 13.215±2.692, Group B was 15.733±1.888, and Group C was 14.467±2.578. Group B and Group C were significantly higher than Group A. At the same time, Group B was also significantly higher than Group C (P<0.01). In terms of strength, there was no significant difference between the three groups. In terms of Rom, there were 22.613±4.686, 26.412±4.635 and25.571±4.228 in three groups. Group B and Group C were significantly higher than Group A. However, there was no significant difference between Group B and Group C. After removal of hook plate, the Constant scores were78.988±6.592, 87.064±4.286 and 84.090±4.837 in three groups. The score of Group B was significantly higher than group A and group C (P<0.01). In terms of pain, Group B was significantly higher than group A. In ADL, Group A was 14.613±2.365, Group B was 17.467±1.878, and Group C was 16.259±1.901. Group B and Group C were significantly higher than Group A. In terms of strength, Group B

was also significantly higher than group A. There were 30.340± 2.896, 33.724±2.873 and 33.220±2.495 in three groups about Rom. Group B and Group C were significantly higher than Group A (Table 2).

Radiographic results

For evaluation of acromioclavicular joint reduction, we used CCD in imaging to evaluate. Joint reduction was obtained in all patients. Before surgery, the CCD of the three groups was 2.094±0.437, 2.173±0.429 and 2.158±0.475. There was no significant difference between the three groups. Before removal of hook plate, Group A was 0.969±0.042, Group B was 1.080±0.045, and Group C was 1.055±0.042. There was significant difference between the three groups ($P<0.01$). After removal of hook plate, the CCD of the three groups was 0.989±0.043, 1.082±0.041 and 1.071±0.035. There was significant difference between the three groups (Table 3).

Complications

Postoperative infection and hardware failure did not present. There were no fractures of acromion and coracoids process. There were 83 cases of shoulder pain, accounting for 30.2% of the total. Among them, Group A had 33 cases, Group B had 24 cases, and Group C had 26 cases. In statistical analysis, the incidence of group A was significantly higher than group B and group C ($p<0.05$). In this study, there were 93 cases of SIS. 39 cases were included in group A, 33 cases were included in group B and 21 cases were included in group C. The incidence of SIS in group A was significantly higher than group B and group C. Regarding Subacromial erosion, there were 51cases in group A, 44cases in group B and 29 cases in group C. The incidence of subacromial erosion in group A was significantly higher than group B and group C (Table 4).

Discussion

The acromioclavicular joint surface was a 50-degree inclined surface from the outside to the inside. The degree of its physiological activity was 5 to 8 degrees. Its stability was mainly provided by the resistance of the acromioclavicular ligament to move forward and backward, the resistance to the elevation by the coracoclavicular ligament, and the anti-gravity effect which trapezius muscle and the sternomastoid muscle provided. The clavicular hook plate made leverage through a plate fixed at the distal end of the clavicle and a hook through the acromion. The continuous and stable pressure was generated at the distal clavicle to provide a stable tension-free healing environment for the acromioclavicular joint, the coracoclavicular joint and the surrounding soft tissue, and also retained a certain micromotion of the acromioclavicular joint, which was consistent with the anatomy of the acromioclavicular joint(14). However, the position of the hook plate was often varied in the actual clinical practice, and it was impossible to achieve a completely uniform specification. Therefore, it also brought different clinical results and various clinical complications. For this reason, many scholars have conducted relevant studies in different directions from the length of the steel plate body, the angle of the hook, and the

distance from the hook to the acromioclavicular joint etc (9,15–17). In our long-term clinical practice, we found that the positional relationship between the hook tip and the acromion seems to have a certain influence on the postoperative clinical effect. To this end, we retrospectively analyzed the cases of acromioclavicular joint dislocation treated with clavicular hook plate in the past few years. According to the position of the hook and acromion, they were divided into four categories to comparative analysis. The D group was excluded due to too few cases. From the results of the study, it also validated our initial hypothesis that the position of the hook tip and the acromion had a very large impact on postoperative clinical efficacy and complications. The postoperative effect of group B was significantly better than that of group A and C. Compared with the A and C group, the C group was better than the A group. So in general, the efficacy of group A is the worst and should be avoided in the clinical surgery. Analyzing the reasons, the tip of the hook in group A was closest to the outer edge of the acromion in terms of the positional relationship between the hook tip and the acromion. If the hook tip was too deep, it will make the clavicle too low after reset, and there was the possibility of wearing the rotator cuff. The hook of the hook plate we were using was generally parallel to the main board. However, the studies of cadaveric bone specimen had found that the lower edge of the acromion had 35 to 45 degrees of anteroposterior tilt and 20 to 30 degrees of internal and external tilt. Therefore, if you did not pre-bend the clavicular hook, the hook tip wound come into contact with the acromion at an angle. If the hook tip was too deep, combined with the reduced contact area and the clavicle upward pressure caused by clavicular overpressure will significantly increase wear and cause complications such as pain. The results of imaging studies also confirmed this point. The average value of CCD in group A was 0.969 ± 0.042 before removal of hook plate and 0.989 ± 0.043 after removal, which was smaller than that of the normal CCD on the opposite side. However, the mean value of the CCDs in group B and group C before and after removal of hook plate was greater than 1, and there was a statistically significant difference from group A. This showed that the excessive depression of the clavicle in group A was very obvious because of the hook tip was too deep. Regarding complications, serious complications such as fractures and recurrent joint dislocations did not appear. We mainly counted three types of complications, shoulder pain, subacromial impingement syndrome, and subacromial erosion. Regarding shoulder pain, group A was the highest with 33 cases. Compared with group B and group C, it was significantly increased. The subacromial impingement syndrome of group A was also the most, a total of 39 cases, and it was significant different with the B and C groups. The same applied to subacromial erosion. Overall, complications in group A were significantly higher than those in the other two groups due to deep hook tips. IMaraghy et al (9) placed clavicular hook plate on fresh cadavers to study the position of the hook tip under the acromion. They found that the proximal end of the hook was located above the head of the humerus, and the deeper hook tip was bound to increase the chance of hitting the greater tuberosity of humerus when the shoulder joint abducted. Lee KW et al (18) believed that the deeper hook tip and excessive stress reduction will cause the stress to concentrate on the tip of the hook, which may lead to the further development of the subacromial erosion, and even the formation of acromion fractures and hook cuts. Therefore, it was very important to control the relative position of the hook and acromion in clinical surgery.

This study also had some limitations.

1. The radiographic data of this study were taken from the positive X-ray film. A slight change in the projection angle could cause differences in results.

2. The position of the hook tip should be a three-dimensional concept, and this article was only studied from the coronal position, so the changes in the positions of the horizontal and sagittal would have a certain impact on the results of this study.

Conclusions

The relative position of the hook tip and acromion can significantly affect the efficacy and complications of the clavicular hook plate in the treatment of acromioclavicular joint dislocation. During surgery, we should control the depth of hook tip and try our best to put the tip of the hook into the area of group B to achieve an ideal postoperative effect and avoid the occurrence of various complications.

Abbreviations

CCD: coracoclavicular distance

AC: acromioclavicular

SIS: subacromial impingement syndrome

Declarations

Ethics approval and consent to participate

Written informed consent was obtained from all subjects. The study was approved by the Ethics Committee of the Shangyu people's hospital of shaoxing city, China (20180506).

Consent for publication

All authors give their consent to publish this manuscript.

Availability of data and material

The datasets analyzed during the current study are available as a supporting file or from the corresponding author on reasonable request.

Competing interests

All the authors do not have any possible conflicts of interest.

Funding

Not applicable

Authors' contributions

All authors made considerable contributions to constitute authorship for this study as defined in the journal’s criteria for authorship. DX drafted the manuscript and interpreted the data. DX and PL designed the project, acquired, and analyzed the data. WKW acquired and analyzed the data.WJG assisted with project design, data interpretation, and manuscript review. JMC assisted with project design and data interpretation. YLS assisted with project design, data analysis and interpretation, and manuscript revision. All authors read and approved the final manuscript and have agreed to be personally accountable for their own contributions.

Acknowledgements

Not applicable

References

1. Shaw MB，Melnemey JJ，Dias JJ，et a1，Acromioclavicular joint sprains，the post—injury recovery interval[J]，Injury，2003，34(6)，438—442，DOI，10，1016/S0020-1383(02)00l87-0，
2. Simovitch R，Sanders B，Ozbaydar M，et a1，Acromioclavicular joint injuries，diagnosis and management[J]，J Am Acad Orthop Surg，2009，17(4)，207—219，DOI，10，5435/00124635-200904000-00002，
3. Fraser-Moodie JA，Shortt NL，Robinson CM， Injuries to the acromioclavicular joint[J]，J Bone Joint Surg Br，2008，90(6)，697-707，D0I，10，1302/0301，9086，20704，
4. Kienast B，Thietje R，Queitsch C，et al，Mid-term results after operative treatment of roekwood grade，-V acromioclavicular joint dislocations with an AC，Hook-plate[J]，Eur J Med Res，201 1，16(2)，52，56，DOI，10，1 186/2047-783X-16-2-52，
5. Chiang CL，Yang SW，Tsai MY，et al，Acromion osteolysis and fracture after hook plate fixation for acromioclavicular joint dislocation，a case report[J]，J Shoulder Elbow Surg，2010，19(4)，e13-e15，DOI，10，1016/j，jse，2009，12，005，
6. Flinkkil T，Ristiniemi J，Lakovaara M，et a1，Hook—plate fixation of unstable lateral clavicle fractures，a report on 63 patients，Aeta Orthop，2006，77，64—649，
7. Gstettner C，Tauber M，Hitzl W，et a1，Rockwood type III aeromio-clavicular dislocation， surgical versus conservative treatment， J Shoulder Elbow Surg，2008，17，220—225，
8. Nasca RJ，Salter EG，Weil CE，Current concepts review，Subacromial impingement syndrome，J Bone Joint Surg Am，1998，80，1852-1 853.
9. ElMaraghy AW, Devereaux MW, Ravichandiran K, Agur AM. Subacromial morphometric assessment of the clavicle hook plate. Injury. 2010;41:613-619.

10. Shih CM, Huang KC, Pan CC, Lee CH, Su KC. Biomechanical analysis of acromioclavicular joint dislocation treated with clavicle hook plates in different lengths. Int Orthop. 2015;39:2239-2244.
11. Kim YS, Yoo YS, Vijayachandran N, Jin H, Song HS. In vivo analysis of acromioclavicular joint motion after hook plate fixation using three-dimensional computed tomography. J Shoulder Elb Surg. 2015;24:1106-1111.
12. Rockwood CJ, Williams G, Yound D. Disorders of the acromioclavicular joint. In: Rockwood CJ, Matsen F, eds. The Shoulder. Vol. I. Philadelphia, PA: WB Saunders; 1998:483–553.
13. Constant CR, Murley AH. A clinical method of functional assessment of the shoulder. Clin Orthop Relat Res. 1987;214:160–4.
14. Gstettner C, Tauber M, Hitzl W, et al. Rockwood type Ⅲ acromioclavicular dislocation : surgical versus conservative treatment. J Shoulder Elbow Surg , 2008, 17:220-225.
15. Petersson CJ，Redlund johnell I，The subacmmial space in normal shoulder radiographs，Acta Orthop Scand，1984，55(1)，57-58，
16. Mayerhoefer ME, Breitenseher MJ, Roposch A, et al，Comparison of MRI and conventional radiography for assessment of acromial shape. AJR Am J Roentgenol. 2005, 184(2):671-5.
17. 17. Xu D, Luo P, Chen J,et al. Outcomes of surgery for acromioclavicular joint dislocation using different angled hook plates: a prospective study. Int Orthop. 2017;(12):2605-2611.
18. Lee KW，Lee SK，Kim KJ，et al，Arthroscopic-assisted locking compression plate clavicular hook fixation for unstable fractures of thelateral end of the clavicle-a prospective study，Int Orthop，201 0，34(6)，839-845，

Tables

Table 1 Characteristics of the patients of AC joint dislocation

Characteristics	A group	B group	C group	Value
ge (years)	41.534±10.340	42.440±10.263	43.389±9.976	F=0.679 P=0.508
ex, male/ female (n)	47/41	60/49	47/30	X^2=1.070 P=0.586
ockwood Classification(n)				X^2=5.823 P=0.213
Rockwood	73	93	64	
Rockwood	2	5	7	
Rockwood	13	11	6	
Rockwood	0	0	0	
ype of injury(n)				X^2=1.510 P=0.959
Car accident injury	24	24	19	
Falling injury	19	22	17	
Fell and hurt	41	56	38	
Other injuries	4	7	3	
te of injury (right/left), n	55/33	62/47	48/29	X^2=0.842 P=0.656
peration time (minutes)	44.977±8.529	45.945±8.694	43.779±8.271	F=1.458 P=0.234
jury-to-surgery interval (days)	4.738±1.878	4.899±1.943	4.870±1.866	F=0.187 P=0.829
ollow-up (months)				
efore removal of hook plate	8.125±2.021	8.477±2.167	7.948±1.870	F=1.643 P=0.195
ter removal of hook plate	9.545±2.238	9.238±2.090	9.792±2.148	F=1.528 P=0.219

Table 2 Functional evaluation results

	A group	B group	C group	Value
Before removal of hook plate				
Pain	6.704±3.781	10.504±3.596[a]	9.220±4.141[ab]	F=24.476 P<0.001
ADL	13.215±2.692	15.733±1.888[a]	14.467±2.578[ab]	F=27.595 P<0.001
Strength	20.852±3.323	21.697±3.059	21.295±3.182	F=1.746 P=0.176
ROM	22.613±4.686	26.412±4.635[a]	25.571±4.228[a]	F=18.018 P<0.001
Constant score	63.386±8.271	74.348±6.889[a]	70.493±7.456[ab]	F=52.335 P<0.001
After removal of hook plate				
Pain	11.875±2.966	12.935±2.473[a]	12.337±2.511	F=3.957 P=0.02
ADL	14.613±2.365	17.467±1.878[a]	16.259±1.901[ab]	F=47.061 P<0.001
Strength	22.159±2.490	22.935±2.473[a]	22.272±2.505	F=2.819 P=0.061
ROM	30.340±2.896	33.724±2.873[a]	33.220±2.495[a]	F=39.699 P<0.001
Constant score	78.988±6.592	87.064±4.286[a]	84.090±4.837[ab]	F=57.434 P<0.001

"a": $P < 0.05$ when the other two groups were compared with A group

"b": $P < 0.05$ when the C group was compared with the B group

Table 3 Coracoclavicular distance

	A group	B group	C group	Value
Pre-operative	2.094±0.437	2.173±0.429	2.158±0.475	F=0.820 P=0.441
Before removal of hook plate	0.969±0.042[c]	1.080±0.045[ac]	1.055±0.042[abc]	F=164.378 P<0.001
After removal of hook plate	0.989±0.043[c]	1.082±0.041[c]	1.071±0.035[c]	F=145.054 P<0.001
Value	F=561.089 P<0.001	F=691.214 P<0.001	F=402.043 P<0.001	

Coracoclavicular distance (CCD): height in percent to the contralateral shoulder between the upper border of the coracoid process and the inferior cortex of the clavicle

[a] P < 0.05 when the other two groups were compared with the A group, respectively

[b] P < 0.05 when the C group B group was compared with the C group

[c] P < 0.05 when the other two groups were compared with the “Pre-operative”, respectively

[d] P < 0.05 when the “Before removal of hook plate” was compared with the “After removal of hook plate

Table 4 Analysis of complications

Complications	A group	B group	C group	Value
Shoulder pain	33	24	26	X^2=6.139 P=0.046
SIS	39	33	21	X^2=6.407 P=0.041
Subacromial erosion	51	44	29	X^2=8.571 P=0.014

Figures

Figure 1

Partition diagram of the acromion A midline was made at the acromion, and the midline was divided into four equal parts which were represented by A, B, C, and D.

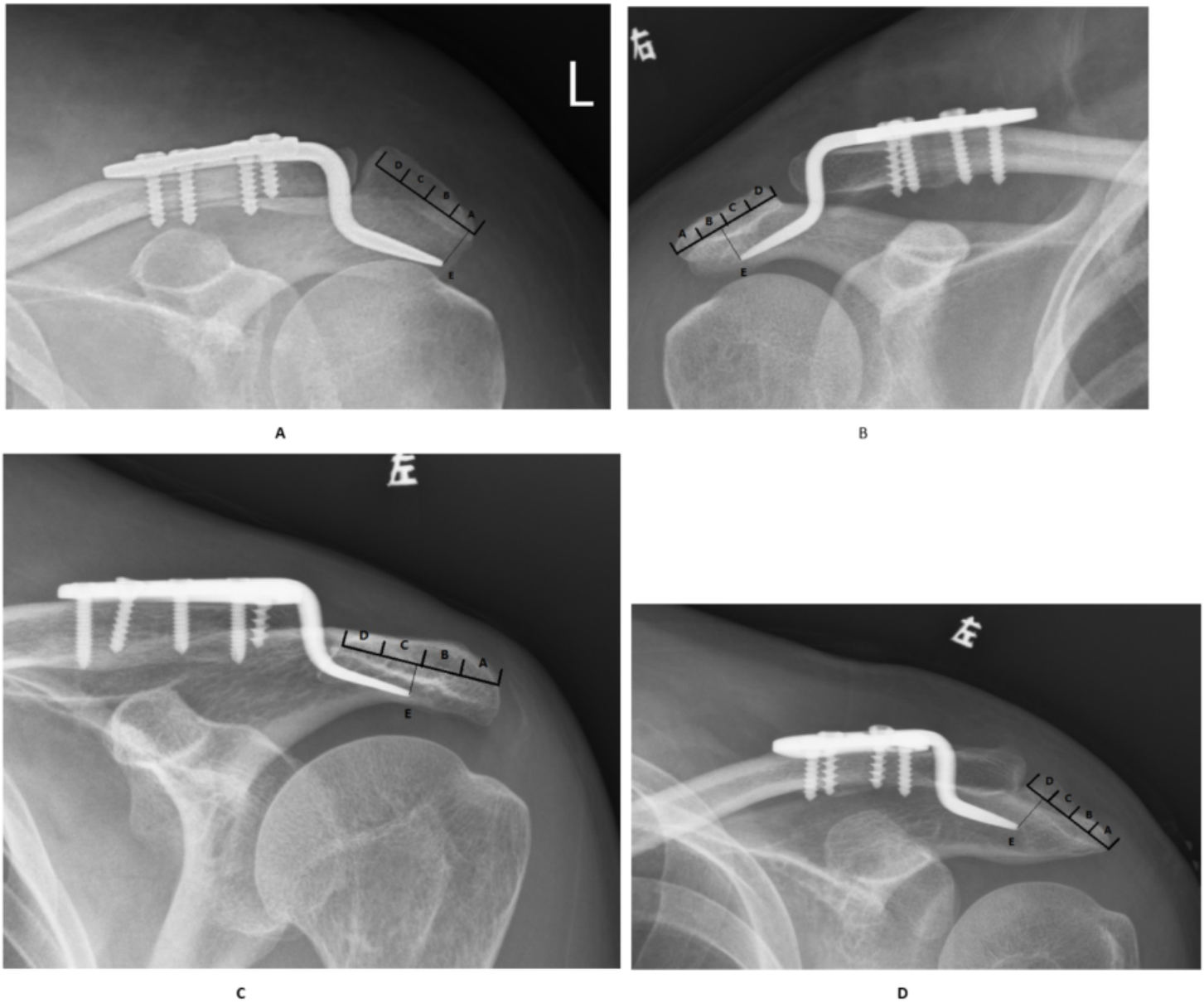

Figure 2

2a Schematic diagram of case grouping. Take the hook point to make a vertical line to the midline of the acromion, and group the cases according to the partition where they intersected. 2b Schematic diagram of case grouping. Take the hook point to make a vertical line to the midline of the acromion, and group the cases according to the partition where they intersected. 2c Schematic diagram of case grouping. Take the hook point to make a vertical line to the midline of the acromion, and group the cases according to the partition where they intersected. 2d Schematic diagram of case grouping. Take the hook point to make a vertical line to the midline of the acromion, and group the cases according to the partition where they intersected.

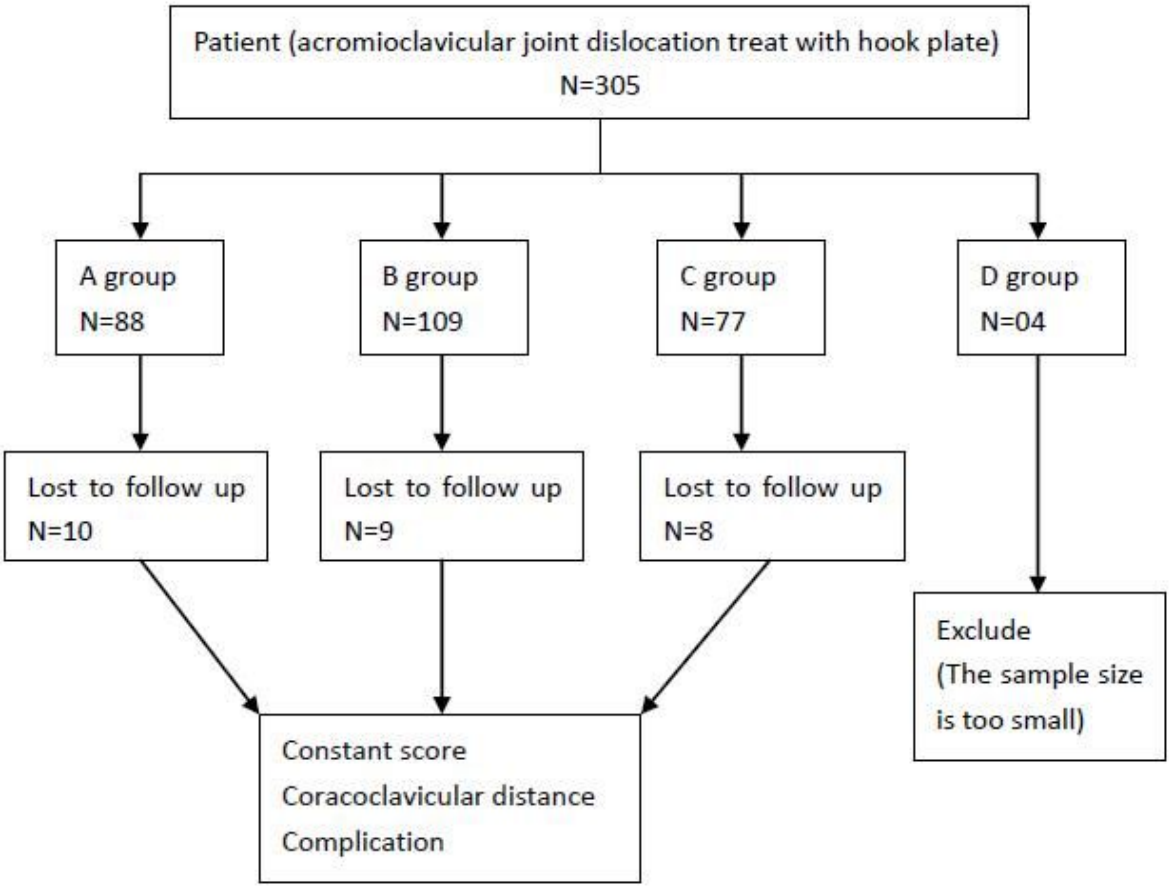

Figure 3

The entire process diagram