Postoperative proximal junctional kyphosis in Lenke 5C adolescent idiopathic scoliosis following posterior surgery: extending fusion versus thoracolumbar/lumbar fusion

Bowen Hu
Sichuan University West China Hospital
Linnan Wang
Sichuan University West China Hospital
Xin He
Sichuan University West China Hospital
Yueming Song
Sichuan University West China Hospital
Xi Yang (formosa88@163.com)
Sichuan University West China Hospital
Limin Liu
Sichuan University West China Hospital
Chunguang Zhou
Sichuan University West China Hospital

Research article

Keywords: proximal junctional kyphosis, cervical kyphosis, thoracic inlet angle, adolescent idiopathic scoliosis, sagittal alignment, thoracolumbar/lumbar curve

Posted Date: January 15th, 2020

DOI: https://doi.org/10.21203/rs.2.20882/v1

Abstract

Background: Proximal junctional kyphosis is a common complication after posterior fusion in adolescent idiopathic scoliosis patients, and was correlated with postoperative change of thoracic kyphosis. However, no previous literature has evaluated the correlation of PJK with thoracervical parameters in the AIS patients.

Methods: Data from 61 patients who underwent posterior fusion for Lenke 5C AIS and had 2 years of follow-up were retrospectively reviewed. Patients were fused higher than two levels above the upper-end-vertebra in the extended fusion group (n=32), whereas they were fused below or at UEV+2 in the TL/L fusion group (n=29).

Results: During an average follow-up of 32.5 months, 14/61 patients had PJK. The extended fusion group had a greater incidence of PJK than the TL/L fusion group did (11/32 vs. 3/29,P = 0.03) and a significant more decrease of TK than the TL/L group(p<0.01). Patients with PJK had a significantly larger Thoracic inlet angle(TIA) than those without PJK (P <0.01). Multivariate analysis revealed a greater preoperative TIA to be a positive predictor for PJK (p = 0.015). TIA >72° with extended fusion was a risk factor for PJK at final follow-up. The SRS-22 score did not significantly differ between the extended fusion and TL/L fusion groups.

Conclusions: TIA could be a predictor of PJK. In Lenke 5C AIS patients, those with TIA >72° were more likely to develop PJK. And extended fusion in patients with Lenke 5C adolescent idiopathic scoliosis may be at an increased risk of proximal junctional kyphosis.

Background

PJK is a common complication after posterior fusion in patients with Lenke 5C adolescent idiopathic scoliosis (AIS) [1–4]. Multiple studies have reported that the risk factors for PJK are a large lumbar lordosis (LL) angle, large sagittal vertical axis (SVA), and low pelvic incidence (PI) [1–4]. Other factors strongly associated with PJK are a large preoperative TK and large immediately postoperative TK in AIS [2,4,5]. Previous study indicated that the thoracic inlet angle (TIA) was strongly associated with TK, global TK, and cervical kyphosis in AIS patients[6–8], and that the TIA is a constant morphological parameter that is not changed by the patient's position or any other conditions. And these correlations are maintained at 2 years after corrective surgery in patients with Lenke type 1 AIS patients[8]. Hence, the TIA is an ideal parameter that can be used to evaluate the sagittal balance of the proximal thoracic area and may could be a predictor of PJK .

The choose of upper instrumented vertebra may also be associated with the incidence of PJK in Lenke 5c patients[4]. Posterior thoracolumbar/lumbar (TL/L) fusion is commonly used for Lenke 5C (AIS) [9, 10]. To avoid the progression of the unfused thoracic curve after thoracolumbar/lumbar (TL/L) fusion, experienced surgeons may choose to perform extended fusion in patients with Lenke 5C AIS with a bending thoracic Cobb angle of more than 20°[11.12.13.15].Furthermore, Kwan et al.[14] suggested

extended fusion with a bending thoracic curve of more than 15°. However, the extended fusion may strongly reduce the thoracic kyphosis (TK) in the sagittal profile [14, 15], and the reduction of TK is a proven risk factor for proximal junctional kyphosis (PJK) and may also result in great change in thoracervical parameters in AIS patients[2.4.5.16-20].

The present study focused on analysis of the radiological features of Lenke 5C patients to identify the correlations among TIA, PJK and other sagittal parameters. Our study also aimed to evaluate the relationship between the choice of upper instrumented vertebra and PJK in patients with Lenke 5C AIS.

Methods

The present retrospective study included 61 patients with Lenke 5 AIS who underwent posterior-only surgery in our department between January 2010 and January 2016. All included patients had follow-up for more than 2 years with complete radiographic data. The present study was approved by the local ethics committee. Patients were fused higher than two levels above the upper-end-vertebra in the extended fusion group, whereas they were fused below or at UEV + 2 in the TL/L fusion group. Patients with a Cobb angle of the thoracic curve of > 40° or a bending thoracic curve of > 15° generally underwent extended fusion; however, a few patients with a rigid thoracic curve chose to undergo TL/L fusion to preserve the flexibility of the thoracic spine after acknowledging complete understanding of the benefits and risks of these two procedures. The Legacy or CD Horizon M8 screw-rod system (Medtronic Sofamor Danek, Inc., Memphis, TN) was used for fixation.

Standing full-length posteroanterior and lateral radiographs were routinely taken using the multi-purpose Digital R/F System (Sonial Vision Safire 17, Shimadzu Corporation, Kyoto, Japan) preoperatively, at 3 months postoperatively, and at final follow-up. Radiologic parameters were independently measured and documented on an electronic system by two surgeons who were not involved in the surgeries, and the average values were calculated to increase the accuracy of the measurement of the upper thoracic region[19].

The coronal parameters measured were the main TL/L Cobb angle, thoracic Cobb angle, reduced bending angle, and correction rate of the two curves. The sagittal parameters measured were the PI, sacral slope (SS), pelvic tilt (PT), LL, PI-LL, TK, GTK, T1 tilt, CL, TIA, proximal junctional angle (PJA), and SVA. TK, GTK, TK, LL, PI, SS and PT were measured using previously described standard methods (Fig. 1). The TIA was defined as the angle between the vertical line of the T1 superior endplate and the line passing through the midpoint of T1. CL was measured as the Cobb angle between the lower endplates of C2 and C7. CK was defined as a CL angle of less than 0°.

The proximal junctional angle (PJA) was defined as the Cobb angle between the lower endplates of the uppermost instrumented vertebra (UIV) and the upper endplates of the two supra-adjacent vertebrae. Proximal junctional kyphosis (PJK) was defined by 2 criteria with at least a two-year follow-up time: (1) final proximal junction angle (PJA) greater than or equal to 10° and (2) final proximal junction angle (PJA) at least 10° greater than the preoperative measurement. The presence of both criteria was necessary for

considering PJK. Increasing the PJK angle was defined as the increase of the proximal junctional angle from the preoperative time to the last follow-up time. Clinical assessments were made using the Scoliosis Research Society (SRS)-22 scores.

Statistical analysis

Students' t-tests were performed to analyze the postoperative changes in the Cobb angle of the thoracic and TL/L curves, PI, PT, SS, SVA, TK, GTK, PI-LL, CL, TIA, and T1 tilt. Bivariate correlation tests, Students' t-tests, chi-squared tests, and receiver operating characteristic (ROC) curve estimations were performed to determine the changes in sagittal balance from preoperatively to final follow-up. Data was analyzed using SPSS 21.0 statistical software (SPSS Inc., Chicago, IL). To investigate the influence of preoperative measurements on postoperative outcomes, certain variables were selected to be included in the multivariate analysis based on the results of correlation analysis and clinical knowledge. Significance was defined as $p < 0.05$.

Result

The age of 61 Lenke 5 AIS patients in this study was 15.1 ± 2.0 years. There were 45 females and 16 males, and the mean Risser sign was 2.8 ± 1.5. The mean follow-up of these patients was 33.2 months (range from 22 to 81 months). The main TL/L curve Cobb angle on average was 53.0 ± 8.4° before surgery and 6.8 ± 6.7° at final follow-up.

Extended fusion versus TL/L fusion

Twenty-nine patients had TL/L fusion, and 32 patients chose extended fusion. Both groups had an excellent correction rate for the main TL/L curve at final follow-up time (85.4% in the extended fusion group and 86.9% in the TL/L fusion group). The correction rate of the thoracic curve in the extended fusion group (70.2%) was significantly greater than that in the TL/L fusion group (57.3%, $p < 0.01$) (Table 1).

PI and TIA kept stable after surgery and through the follow-up time in both the extended fusion and TL/L fusion groups. A significant difference was found in the immediate change of TK (−3.7 ± 9.7 vs. 3.8 ± 6.0, $p < 0.01$) and increasing PJK angle (7.1 ± 8.6 vs. 3.6 ± 4.8, $p = 0.04$) between the extended fusion and TL/L fusion groups (Table 1). No significant difference was found between extended fusion and TL/L fusion in the preoperative or final SRS-22 scores for function/activity, pain, self-image, mental health, and satisfaction with treatment. (Table 4a)

Proximal junctional kyphosis

According to our PJK criteria, 14/61 (23.0%) patients were considered PJK at final follow-up time. We found no significant difference exists in PI, PT, SS, LL, PI-LL, or even SVA distance preoperatively, at three months, and final follow-up time. In addition, PJA did not differ between the two groups preoperatively.

However, the mean preoperative TIA, GTK, and CL value in PJK patients were significantly larger than that in non-PJK patients (Table 2). After surgery, the extended fusion group exhibited much more PJK than the TL/L fusion one (11/32 vs. 3/29, $p < 0.01$). At final follow-up time, lower TK, GTK, and CL were found in the PJK group. The preoperative TIA of patients with PJK at the latest follow-up was larger than that of patients with non-PJK (73.2 ± 5.6 vs. 66.6 ± 7.4, $p < 0.01$), and the ROC curve showed that the cutoff value was 72°. None of the 27 CK patients had PJK, which is significantly lower than 14/34 in the CL group ($p < 0.01$). No significant difference was found between post-op PJK and non-PJK patients in the preoperative or final SRS-22 scores (Table 4B).

Bivariate correlation and curve estimations for PJK and TIA

The correlation analysis was done between the sagittal parameters with the increasing PJK angle (Fig. 2). Bivariate correlation tests of the following radiographic parameters showed preoperative TIA ($r = 0.51$, $p < 0.001$), preoperative TK ($r = 0.43$, $p = 0.001$), final TK ($r = 0.47$, $p < 0.001$), and final global TK ($r = 0.43$, $p = 0.001$) showed strong correlation with increasing PJK angle. Final C2–7 lordosis showed moderate correlation ($r = 0.35$, $p = 0.006$), and preoperative global TK showed weak correlation ($r = 0.29$, $p = 0.025$) with increasing PJK. No marked correlation was found in PI, PT, SS, SVA, T1tilt, and PI-LL.

As for preoperative TIA, we also found its correlation with the final C2–7 lordosis ($r = 0.67$, $p < 0.001$), final T1 tilt ($r = 0.63$, $p < 0.001$), final TK ($r = 0.42$, $p = 0.001$), final GTK ($r = 0.62$, $p < 0.001$), increasing PJK angle ($r = 0.51$, $p < 0.001$), and final LL ($r = 0.33$, $p = 0.01$). Preoperative and final PI, PT, SS, and PI-LL had no significant correlation with preoperative TIA.

Multivariate analysis

Multivariate logistic regression results for predictors of PJK is presented in Table 3. It revealed a greater preoperative TIA to be a positive predictor for PJK ($p = 0.015$, log odds 0.212). Greater preoperative PJA was a negative predictor for PJK ($p = 0.045$, log odds − 0.355).

Discussion

Proximal junctional kyphosis and extendned fusion

Kim[1]and Wang [2] defined PJK in AIS patients as both an increase of > 10° in kyphosis between the UIV and the UIV + 2 and the final PJA greater than or equal to 10°, which was widely used in AIS patients[1,2,4,5] and was chosen in our study. Previous studies have reported incidences of PJK after surgery for Lenke 5C AIS of 8.49% [4]. Sun et al. [3] reported that an increase of PJK larger than 10° occurred after selective fusion in 17.1% of patients with Lenke 5C AIS at 2 years postoperatively, which is comparable to the PJK incidence found in the present study (23.0%). To reduce the incidence of PJK, it is critical to restore and maintain normal TK [1,2,3,5]. Important risk factors for PJK in AIS include reduction of TK and large preoperative TK [2,4, 5].

Patients with PJK had a greater GTK than those without PJK in our study. The immediately postoperative change in TK is reportedly a risk factor for PJK [2,4,5]. Similarly, the present study revealed a correlation between the immediately postoperative change in TK and the increasing PJK angle. However, PJK resulted from either a large immediately postoperative decrease or increase in TK. Patients with an immediately postoperative decrease in TK need to restore the GTK to attain sagittal balance; the kyphosis would increase at the proximal part of the fusion level and thus lead to PJK. In patients with an immediately postoperative increase in TK, the greater risk of PJK may be due to the overcorrection of LL[3]. Hence, the larger postoperative LL could lead to an immediate increase in TK, and the spontaneous change to attain sagittal balance may lead to greater PJK to obtain much larger TK to match the overcorrected LL. However, the present study did not find a correlation between PJK and LL.

Extended fusion had more correction in the coronal plane with less restoration of TK [14, 15]. In our study, the extended fusion group had a significantly immediate, larger reduction in TK. This immediate decrease in TK meant that the extended fusion group had a significantly greater incidence of PJK than the TL/L fusion group did. A previous study showed that placement of the UIV cephalad to the upper-end vertebra was associated with an increased risk of PJK in Lenke 5 curves [4]. Similarly, extending the fusion to the thoracic curve in the present study resulted in higher rate of PJK.

Thoracic inlet angle and Proximal junctional kyphosis

Preoperative TK, LL and global TK are alternate parameters that could potentially be used to predict postoperative change of the Sagittal balance of the thoracic spine. However, these parameters are easily influenced by posture, because it is difficult to ensure that every patient has a horizontal vision line and is standing perfectly straight during radiography. So they are not ideal predictors of the increasing PJK angle.In contrast, the TIA is a constant morphological parameter that is not influenced by the posture under any conditions, similarly to the PI of the spinopelvic unit [6–8]. Recent studies found significant correlations between preoperative TIA and TK and Global TK angle [6–8]. Preoperative global kyphosis is a key parameter influencing the postoperative thoracic and thoracervical spinal sagittal balance [20]; In our study, the TIA could predict the GTK at final follow-up, which was also strongly correlated with the final increasing PJK angles. The TIA did not change after surgery or during two years of follow-up and could be an appropriate predictor for proximal junctional kyphosis.

In patients with a reduction in TK, which is a reported risk factor for PJK [2.5], the occurrence of the proximal junctional kyphosis is mainly determined by the variation in the TIA (Fig. 5A-B).This may explain the role of the TIA in predicting PJK. A larger preoperative TIA, which predicts larger final GTK, makes it easier for the proximal junction to become more kyphotic during follow-up. In the patients who underwent extended fusion of the main thoracic curve, this increase in sagittal kyphosis could only be obtained at the proximal junctional area, so the PJK angle increased. However, patients with a lower TIA, which indicated lower final GTK and T1 tilt, were much more likely to have final CK[8].

In the extended fusion group, the TK decreased immediately after surgery. However, the GTK needed to stay stable from the preoperative one, which made it easier for PJK to occur in the proximal thoracic

region. According to the ROC curve, a TIA of > 72° was the cutoff point for the occurrence of PJK. Hence, extended fusion should be avoided in patients with Lenke 5C AIS with a TIA of > 72°. These patients with large preoperative TIA and GTK should be carefully evaluated prior to extended fusion, especially when the surgeon tried to correct the preoperative hyperkyphosis.

However some patients with large TIA had relatively small TK and GTK because of the rotation of the thoracic curve, these patients developed an immediate increase of TK after surgery, and the large TIA also meant that they needed a large GTK at the final follow-up. The increasing TK and GTK immediately after surgery were not enough for these patients; the TK and GTK continued to increase during follow-up and led to PJK at the final follow-up. This mechanism could explain why some of the PJK patients had an immediate increase of TK.

Patients who develop PJK following surgical correction of adult spinal deformity reportedly tend to have increased pre- and postoperative T1 slopes and C2–7 angles [21.22]. Increased progression of CL was associated with the development of PJK in these studies [21.22]. In present study, none of the 27 CK patients had Proximal junctional kyphosis at the final follow-up. This result suggests the incidence of PJK could be correlated with the cervicothoracic parameters.

Clinical outcome

The mean SRS-22 score was satisfactory in both the extended fusion and TL/L fusion groups. Furthermore, the domain values for pain, self-image, function, mental health, and satisfaction were good or excellent in both groups. No significant difference was found in the clinical outcome between the PJK and non-PJK groups with at least a 2-year follow-up time. This result was similar to the recent study[5]. We also believe a longer follow-up time is needed to evaluate the degeneration and back pain from the PJK.

The present study had several limitations. First, the number of patients was relatively small with at least 2 years of follow-up, and there might not have been enough patients with preoperative abnormal sagittal profile to detect whether this made a difference in postoperative PJK. Second, the TL/L fusion may less accurately reflect the thoracic kyphosis than the extended fusion might, due to the unfused thoracic curve. However, the final Cobb angle of thoracic curve was not significantly different between the two groups. Third, the accuracy of parameter measurement in PJK patients is still a large problem[19]. Although we had already measured and documented on an electronic system the patients' conditions by two surgeons and calculated the average values, it was still difficult to get a high rate of accuracy.

Conclusion

Patients with Lenke 5C AIS who underwent posterior TL/L fusion with additional thoracic fusion had a greater incidence of PJK than those who underwent TL/L fusion alone, although the extended fusion or PJK had no influence on the SRS-22 scores. We found that no patient with CK had PJK postoperatively. In patients with an immediate reduction of TK and a TIA of > 72° carried a greater risk of PJK. Extended

fusion should be performed with greater caution in patients with a TIA of > 72°, because they are at an increased risk of PJK.

Abbreviations

AIS adolescent idiopathic scoliosis

CB Coronal balance

CIB Coronal imbalance

LEV Lower end vertebra

UEV Upper end vertebra

LIV Lowest instrumented vertebra

CSVL Central sacral vertical line

C7PL C7 plumb line

TL/L Thoracolumbar/lumbar curve

T Thoracic curve

TK Thoracic kyphosis

GTK Global thoraicic kyphosis

TIA Thoracic inlet angle

PJA Proximal junctional angle

PJK proximal junctional kyphosis

CL Cervical lordosis

LL Lumbar lordosis

PI Pelvic incidence

PT Pelvic tilt

SS Sacral slope. SVA means Sagittal vertical axis.

L Lumbar vertebra

S Sacral vertebra

C Cervical vertebra

SRS-22 Scoliosis research society–22 questionnaire

Declarations

Ethics approval and consent to participate: This study was approved by the ethics committee of Sichuan University West China hospital and informed consent was obtained from the patients and their parents.

Consent for publication: All patients and their parents gave written consent for publication of their anonymized data.

Availability of data and material: Data will be available upon request to the Corresponding author XY.

Competing Interest: On behalf of all authors, the corresponding author states that there is no conflict of interest.

Funding Soures/Benefits received: This study was supported in part by the Projects of the Science & Technology Department of Sichuan Province: NO.2017SZDZX0021(Recipient Limin Liu) & NO.2017SZ0046(Recipient Xi Yang). XY conceptualized and designed the study, drafted the initial manuscript. LL revised the manuscript for important intellectual content. The founder helped the follow-up survey for the patients and covered the cost of transport and photograph for some patients.

Device Status: My manuscript does not discuss any drugs or devices requiring FDA approval.

Author Contributions: BH and XY conceptualized and designed the study, drafted the initial manuscript. BH and CZ carried out the initial analyses, reviewed and revised the manuscript. XH and LW analyzed and interpreted the data, reviewed and revised the manuscript. LL and YS coordinated and supervised data collection, critically reviewed and revised the manuscript for important intellectual content. All authors approved the final manuscript as submitted and agree to be accountable for all aspects of the work.

Acknowledgments: Not applicable.

References

[1].Kim YJ, Bridwell KH, Lenke LG, et al. Proximal junctional kyphosis in adolescent idiopathic scoliosis following segmental posterior spinal instrumentation and fusion: minimum 5-year follow-up. Spine (Phila Pa 1976).2005;30(18):2045–50.

[2]. Wang J, Zhao Y, Shen B, et al. Risk factor analysis of proximal junctional kyphosis after posterior fusion inpatients with idiopathic scoliosis. Injury. 2010;41(4):415-20.

[3]. Sun Z, Qiu G, Zhao Y, et al. Risk factors of proximal junctional angle increase after selective posterior thoracolumbar/lumbar fusion in patients with adolescent idiopathic scoliosis. Eur Spine J. 2015;24(2):290-7.

[4]. Lonner BS, Ren Y, Newton PO, et al. Risk factors of proximal junctional kyphosis in adolescent idiopathic scoliosis- the pelvis and other considerations.Spine Deformity.2017;5(3):181-188.

[5]. Kim YJ, Lenke LG, Bridwell KH, Junghoon K, Cho SK, Cheh G, et al. Proximal junctional kyphosis in adolescent idiopathic scoliosis after 3 different types of posterior segmental spinal instrumentation and fusions: incidence and risk factor analysis of 410 cases. Spine.2007;32:2731–8

[6]. Lee SH, Kim KT, Seo EM, et al. The influence of thoracic inlet alignment on the craniocervical sagittal balance in asymptomatic adults. J Spinal Disord Tech. 2012;25(2):E41-7.

[7]. Lee SH, Son ES, Seo EM, et al. Factors determining cervical spine sagittal balance in asymptomatic adults: correlation with spinopelvic balance and thoracic inlet alignment. Spine J. 2015;15(4):705-12.

[8]. Zhu C, Yang X, Zhou B, et al. Cervical kyphosis in patients with Lenke type 1 adolescent idiopathic scoliosis: the prediction of thoracic inlet angle. BMC Musculoskelet Disord. 2017;18(1):220.

[9].Lenke LG, Betz RR, Harms J, et al. Adolescent idiopathic scoliosis: a new classification to determine extent of spinal arthrodesis. J Bone Joint SurgAm. 2001;83-A(8):1169-81.

[10]. Shufflebarger HL, Geck MJ, Clark CE, et al. The posterior approach for lumbar and thoracolumbar adolescent idiopathic scoliosis: posterior shortening and pedicle screws. Spine (Phila Pa 1976).2004;29:269–76.

[11]. Liu Y, Li M, Zhu XD, et al. Retrospective analysis of anterior correction and fusion for adolescent idiopathic thoracolumbar/lumbar scoliosis: the relationship between preserving mobile segments and trunk balance. Int Orthop. 2009;33(1):191-6.

[12]. Wang T, Zeng B, Xu J, et al. Radiographic evaluation of selective anterior thoracolumbar or lumbar fusion for adolescent idiopathic scoliosis. Eur Spine J. 2008;17:1012–8.

[13]. Sanders AE, Baumann R, Brown H, et al. Selective anterior fusion of thoracolumbar/lumbar curves in adolescents: when can the associated thoracic curve be left unfused? Spine (Phila Pa 1976). 2003;28(7):706-13; discussion 714.

[14]. Kwan MK, Chiu CK, Chan TS, et al. Flexibility assessment of the unfused thoracic segments above the "potential upper instrumented vertebrae" using the supine side bending radiographs in Lenke 5 and 6 curves for adolescent idiopathic scoliosis patients. Spine J. 2018;18(1):53-62.

[15]. Lark RK,Yaszay B, Bastrom TP, Newton PO. Adding thoracic fusion levels in Lenke 5 curves: risks and benefits.Spine (Phila Pa 1976). 2013;38(2):195-200.

[16].Yanik HS, Ketenci IE, Erdem S, Cervical sagittal alignment in extensive fusions for lenke 3C and 6C scoliosis: the effect of upper instrumented vertebra. Spine (Phila Pa 1976). 2017;42(6):E355-E362.

[17].Hwang SW, Samdani AF, Tantorski M, et al. Cervical sagittal plane decompensation after surgery for adolescent idiopathicscoliosis: an effect imparted by postoperative thoracic hypokyphosis. J Neurosurg Spine. 2011;15(5):491-6.

[18].Hiyama A, Sakai D, Watanabe M, et al. Sagittal alignment of the cervical spine in adolescent idiopathicscoliosis: a comparative study of 42 adolescents with idiopathicscoliosis and 24 normal adolescents. Eur Spine J. 2016; 25(10):3226–3233.

[19].Basques BA, Long WD 3rd, Golinvaux NS, et al. Poor visualization limits diagnosis of proximal junctional kyphosis in adolescent idiopathic scoliosis. Spine J. 2017 Jun;17(6):784-789.

[20].Wang F, Zhou XY, Xu XM, et al. Cervical sagittal alignment limited adjustment after selective posterior thoracolumbar/lumbar curve correction in patients with Lenke type 5C adolescent idiopathic scoliosis.Spine (Phila Pa 1976). 2017;42(9):E539-E546.

[21]. Passias PG, Horn SR, Jalai CM, et al.Cervical alignment changes in patients developing proximal junctional kyphosis following surgical correction of adult spinal deformity. Neurosurgery. 2018 Oct 1;83(4):675-682

[22]. Protopsaltis T, Bronsard N, Soroceanu A, et al. Cervical sagittal deformity develops after PJK in adult thoracolumbar deformity correction: radiographic analysis utilizing a novel global sagittal angular parameter, the CTPA. Eur Spine J. 2017;26(4):1111-1120.

Figures

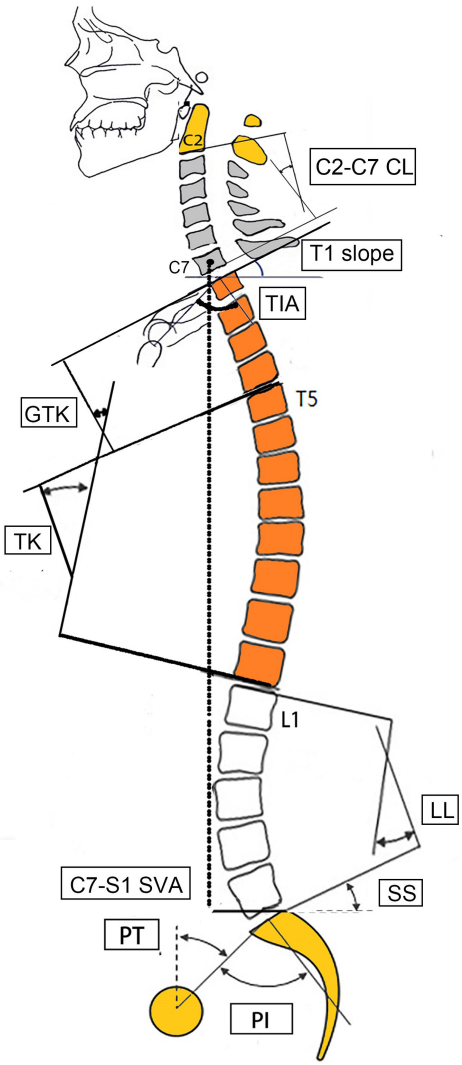

Figure 1

Spinal parameters in standing lateral radiographs CL means Cervical lordosis. C means Cervical vertebra. T means Thoracic vertebra. TIA means Thoracic inlet angle. LL means Lumbar lordosis. TK means thoracic kyphosis. GTK means global thoraicic kyphosis. PI means Pelvic incidence. PT means Pelvic tilt. SS means Sacral slope. SVA means Sagittal vertical axis.

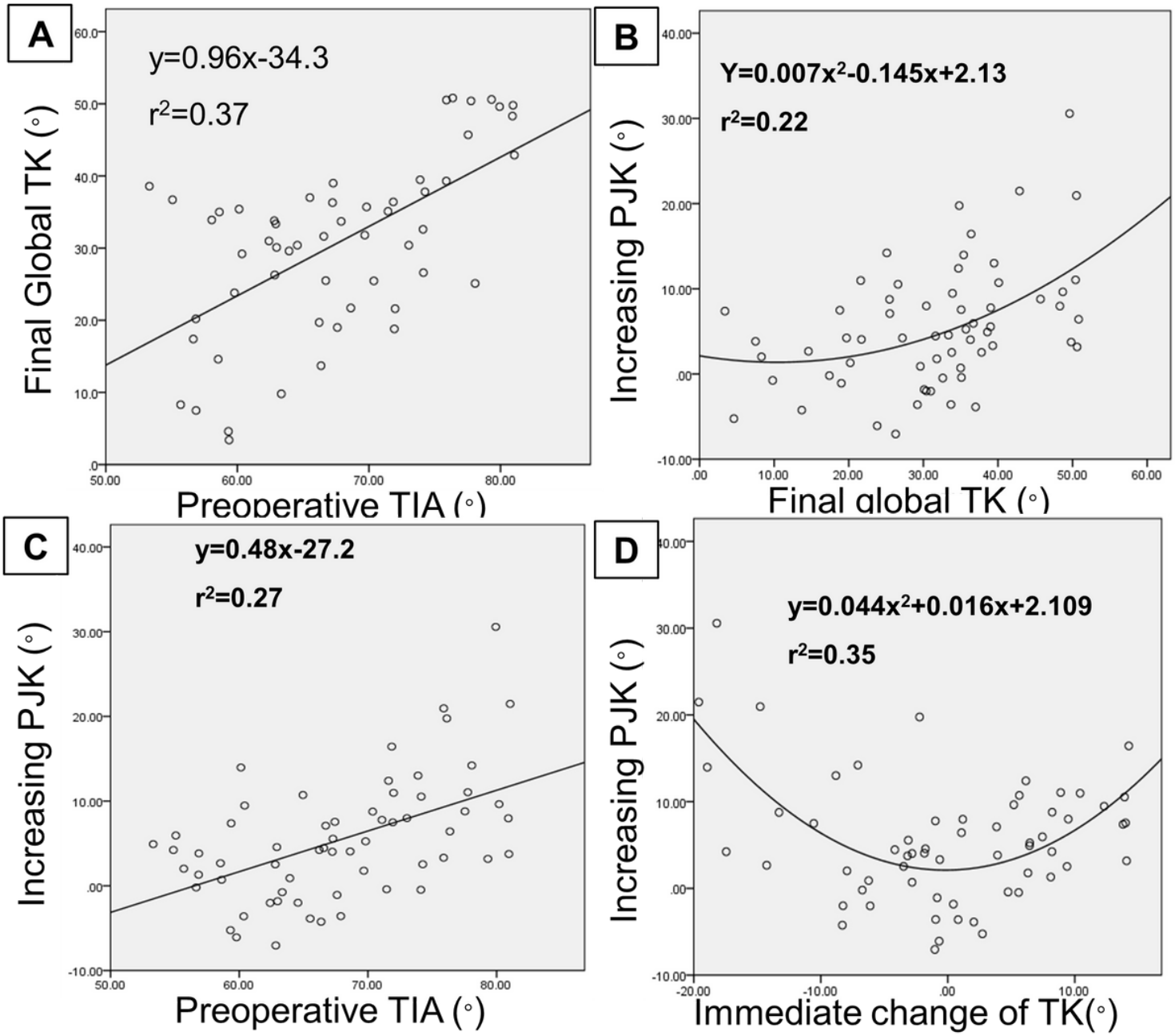

Figure 2

(a) Correlation of the preoperative TIA and the final GTK. (b, c) Increasing PJK angle is highly correlated with the final GTK ($p < 0.01$) and preoperative TIA ($p < 0.01$). (d) Correlation between immediate change of TK and increasing PJK angle.

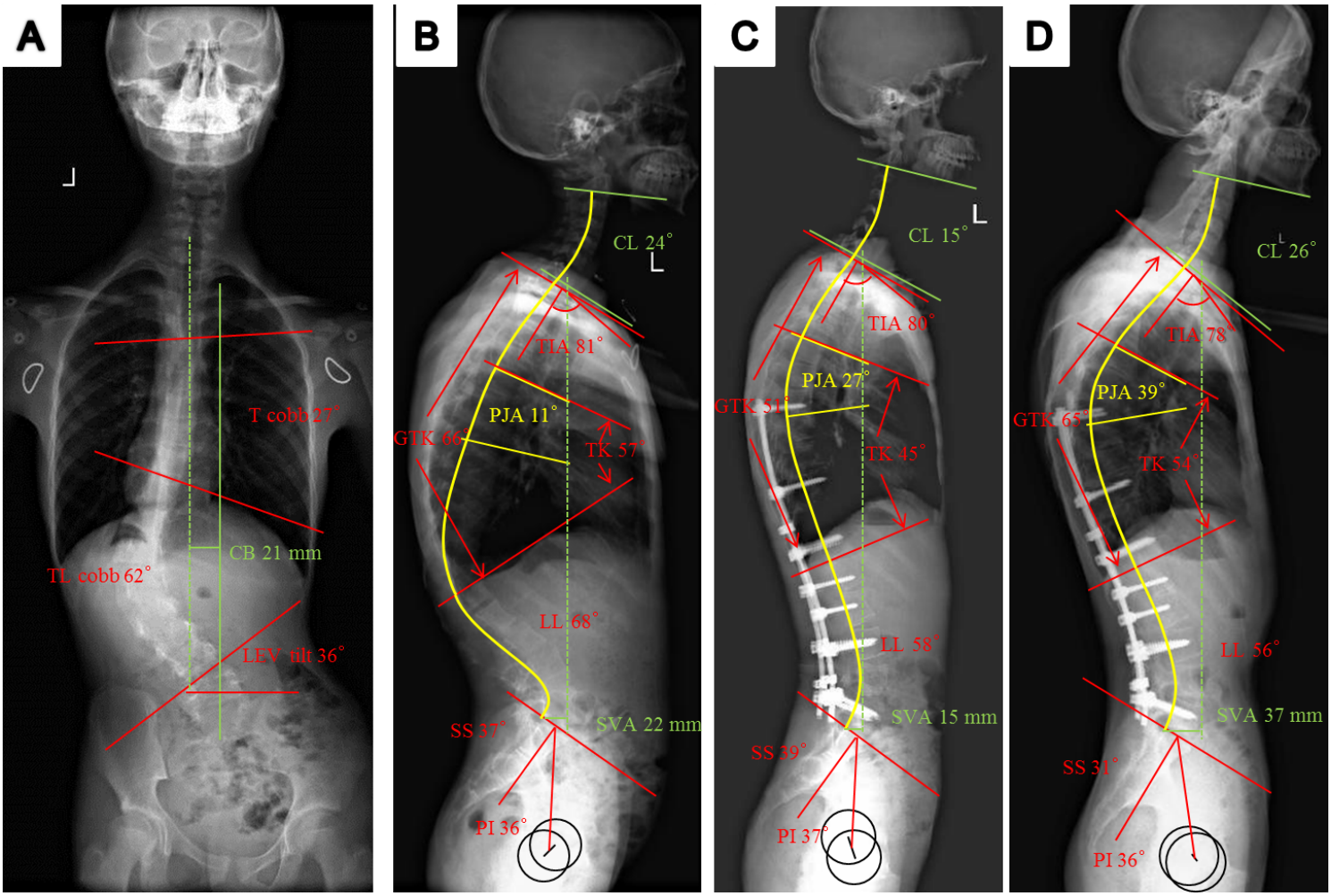

Figure 3

Standing PA and lateral radiographs of a 15-year-old male Lenke 5C patient with a structural lumbar curve of 62°. (a) Preoperative Cobb angle of thoracic curve was 27°, reduced to 18° at bending film. Preoperative C7PL–CSVL distance was 21 mm. (b) The preoperative radiograph showed large TIA (81°) and GTK (66°). The PJA was 11°. (c) At first follow-up: lateral radiograph illustrating GTK reduction to 51° in the sagittal plane, with PJA increased to 27°. (d) At 5-year follow-up, GTK returned to 65° and PJA increased to 39°; 28 degrees of increasing PJK angle was measured. TIA remained stable during the follow-up time.

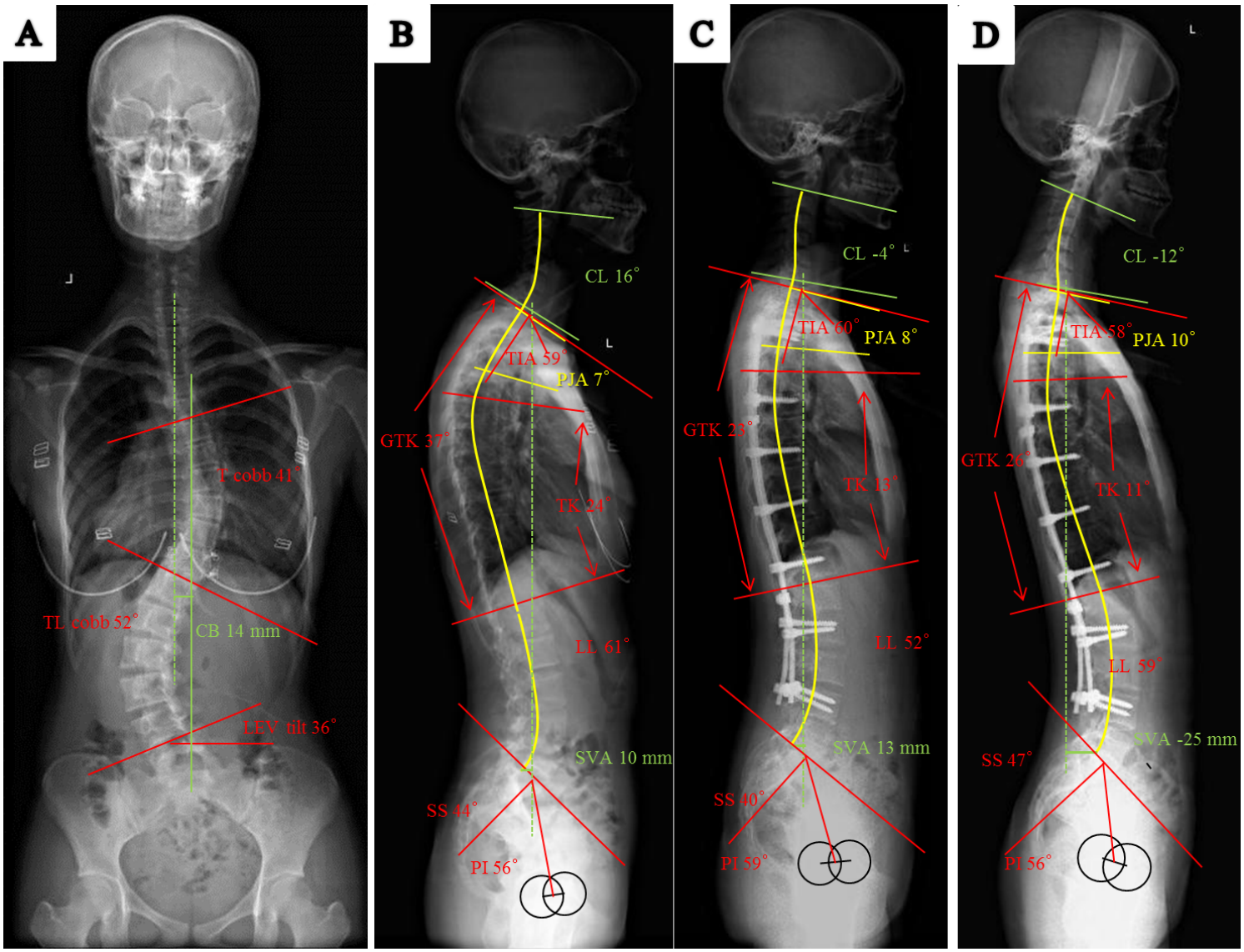

Figure 4

(a) Standing PA of a 14-year-old adolescent female. The structural lumbar curve was 52° before surgery. Preoperative thoracic curve was 41°. (b) The preoperative sagittal alignment showed a small TIA (59°). C2–7 CL was 16° and GTK was 37°. (c) The GTK decreased to 13° with cervical kyphosis (–4°) at first follow-up. (d) At 4-year follow-up. Patients develop large CK (–12°) and the GTK was 26°. TIA remained stable.

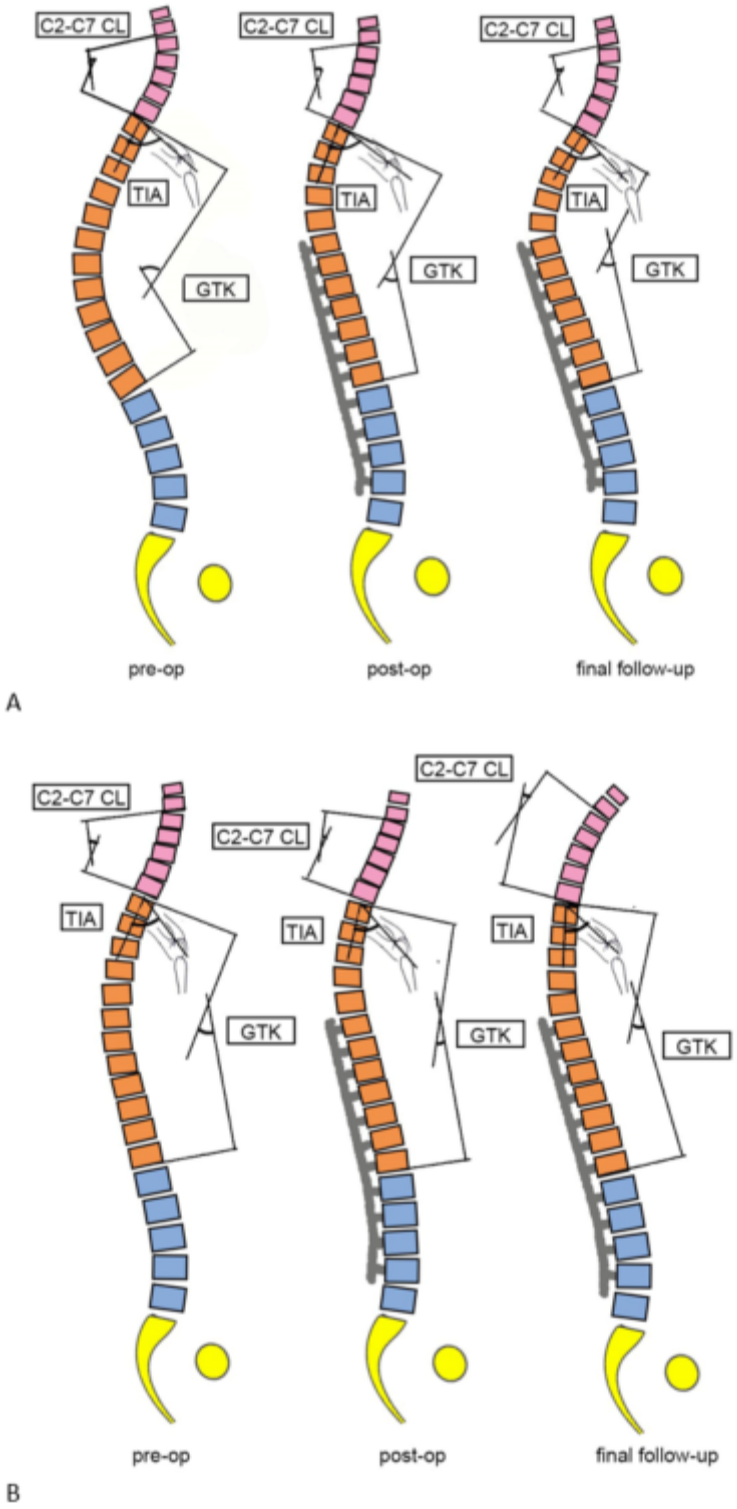

Figure 5

(a) Spontaneous change mechanism of the extending fusion in the patients with a large TIA. (b) Spontaneous change mechanism of the extending fusion in the patients with a small TIA.