Modified Tectonic Corneoscleral Graft For Management of Devastating Corneoscleral Infections

Xiaoyu Zhang
Eye Hospital of Shandong First Medical University
Xiaolin Qi
Eye Hospital of Shandong First Medical University
Miaolin Wang
Eye Hospital of Shandong First Medical University
Hua Gao (hgao@sdfmu.edu.cn)
Eye Hospital of Shandong First Medical University

Research Article

Keywords: Corneoscleral graft, Corneoscleral infection, Transplantation

Posted Date: January 4th, 2022

DOI: https://doi.org/10.21203/rs.3.rs-1149193/v1

Abstract

Purpose To analyze the clinical results and the efficacy of modified tectonic corneoscleral graft (TCG) in patients with devastating corneoscleral infections.

Methods Twenty-five eyes from 25 patients who underwent modified TCG were enrolled. The recurrence, best-corrected visual acuity (BCVA), ocular surface stability, postoperative complications and graft survival condition were recorded.

Results Among 25 patients, 19 cases were fungal infection and 6 cases were bacterial. The rate of recurrence was 8% with *Pythium Insidiosum* as a corresponding pathogen. The rate of monocular blindness declined from 100% to 57%. Changes in BCVA from preoperative to postoperative values were significant (Z=4.22, P 0.001). The survival of ocular surface stability was 73.6% and 43.9% at 1 and 3 years after surgery, respectively. Within the mean follow-up period of 17.5 ± 8.9 months, 21eyes (84.0%) had a stable ocular surface. The incidence rate of immune rejection was 36%. Corneal epithelial defects occurred in 7 patients and choroidal detachment occurred in 3 patients. No elevation of intraocular pressure was detected.

Conclusions The modified TCG is effective in eradicating infection, salvaging the eyeball and saving some useful vision for devastating corneoscleral infections. Regular application of tacrolimus, timely addition of glucocorticoid and good compliance may decrease the postoperative course challenging.

Introduction

Infectious keratitis is a leading cause of blindness in China[1–3] and the prevalence has been indicated to be 0.148%[4]. Severe corneal infections may result in acute perforation, scleritis, and endophthalmitis, with rapid visual loss[5]. With late diagnosis, delayed specific treatment and surgery, enucleation have been proved common[6, 7]. Penetrating keratoplasty is an essential treatment of choice to preserve the eyeball of corneoscleral infections. Recent studies on the management of advanced infectious keratitis have focused on large-diameter penetrating keratoplasty (8.75-15.0mm) and sclerokeratoplasty and have shown removing the complete pathology to be a critical step[8, 9]. But even then, reinfection was observed in 32%-65% patients and 17% had to be enucleated[8, 9]. Jing Zhong reported that full-thickness conjunctival flap covering surgery combined with amniotic membrane transplantation was used for severe fungal keratitis[10]. It may salvage an eyeball that might have otherwise been lost. It can hardly provide the opportunity for useful vision[8, 10, 11]. Postoperative complications of large-diameter corneoscleral transplantation should not be ignored. Hirst et al. showed that the incidence of secondary glaucoma after surgery is as high as 50%[12] .Here, we demonstrated a modified tectonic corneoscleral graft (TCG) that can optimize and alleviate these problems.

We used a modified graft and improved the suture method, which not only restored the integrity of the eyeball, but also reduced the occurrence of postoperative secondary glaucoma and preserved some useful vision. This study aimed at investigating the therapeutic effect, postoperative complications and

graft survival of this procedure for patients with devastating corneoscleral infections. At the same time, fungal infection and bacterial infection were analyzed respectively.

Materials And Methods

Patients

From June 2017 to June 2020, a consecutive series of 25 eyes (25 patients) underwent modified TCG for corneoscleral infections at eye hospital of shandong first medical university. These patients came from clinical studies approved by ethics committees and conducted in accordance with the Declaration of Helsinki. Corneoscleral infections was diagnosed using the following methods: (1) clinical slit-lamp examination revealed infection involving the entire cornea, limbus, and sclera; (2) the anterior segment optical coherence tomography (AS-OCT) of patients showed infiltration involving the whole cornea; (3) no significant vitreous turbidity or other intraocular inflammatory manifestations on the B-scan ultrasound. Patients were classified as fungal corneoscleral infection group (FCI) and bacterial corneoscleral infection group (BCI) according to the pathogen.

The included cases were queried on symptoms, onset time, history of corneal trauma, the disease diagnosed in local hospital, other systemic diseases and therapy received prior to presentation, especially glucocorticoid. The mean follow-up period was 17.5 ± 8.9 months (range, 3–31 months). In general, if the status of corneal ulcers deteriorated or did not improve after 5-7 days of topical and systemic therapy, TCG were recommended.

Definition

Graft survival was defined as the stable condition of the graft regardless of its transparency. Stable condition meant that graft integrity was maintained, without graft ulcer, perforation, or stroma melting. Graft failure was defined as recurrent infection, the need for additional surgery, eyeball enucleation due to unstable condition of the graft.

Clinical and Microbiological procedures

A clinical examination was performed on each patient by an ophthalmologist using a slit lamp. Clinical features were documented and results of AS-OCT and confocal laser microscopy (HRT3; Heidelberg Engineering, Dossenheim, Germany) were recorded.

Laboratory diagnosis was made by means of smear staining and culture. Patients with corneoscleral infection underwent corneal sampling. Smear direct microscopic evaluation was performed after fluorescent and gram staining. The microbial isolation and identification of relied on standard phenotypic techniques. The corneal tissue that was removed intraoperatively was subjected to hematoxylin and eosin (HE) staining and pathological examination.

Operative procedure

A fresh donor was required, and it was best to apply within 3 days. All operations were performed under local anesthesia. Different from penetrating keratoplasty, the preparation of donor is the first step in the TCG to minimize the opening time. The fresh donor corneal graft with a 2 mm wide scleral ring was cut off from the endothelial layer with 50% thickness of sclera tissue in advance.

A 360° bulbar conjunctival incision was made along the limbus. After clear surgical field of view is exposed, the hypopyon was flushed with a balanced saline solution. And then remove the infected cornea and sclera. Be careful not to damage the peripheral iris. For fungal infections, 1 mg/ml voriconazole was used to flush the anterior chamber angle, and there was no evidence of infection under the operating microscope. The scleral ring of donor was sutured overlapped on to the recipient sclera (Figure 1). The anterior chamber was formed and its angle separated by viscoelastic agent, but don't go for water tightness. The bulbar conjunctiva was sutured and fixed to the corneal limbus. Above is shown in Figure 2.

Postoperative treatment

To minimize the risk of postoperative immune rejection, tacrolimus eye drops were applied on first day after surgery. In patients with fungal keratitis, glucocorticoids were not used topically for 2 weeks, after which 0.1% fluorometholone eye drops were prescribed 3-4 times a day. While in patients with bacterial keratitis, glucocorticoid eye drops were used immediately after surgery. Long-term use of tacrolimus eye drops in combination with 0.02% fluorometholone was required.

The follow-up indexes included BCVA, intraocular pressure (IOP), and postoperative complications. Snellen visual acuity was recorded and approximations for visual acuity worse than 20/400 were determined considering the following: Counting fingers=20/2,000, hand motions=20/4,000, light perception= 20/8,000, and no light perception=20/16,000. Snellen vision was converted to logMAR values for statistical analysis.

Statistical analysis.

SPSS software version 21.0 (SPSS, Inc.,Chicago, IL, USA) was used for the statistical analysis. An unpaired, two-tailed Student's t-test was used to determine the statistical significance of BCVA preoperatively and postoperatively. Kaplan-Meier survival analysis was performed to evaluate the survival of ocular surface stability. $P<0.05$ was considered to indicate a statistically significant difference.

Results

Patients' characteristics

The patients' clinical and demographic characteristics are presented in Table 1. Twenty-five patients (25 eyes) were included, 19 (76%) had fungal corneoscleral ulcer and 6 (24%) had bacterial corneoscleral ulcer. In both groups, patients were mainly concentrated in 50–70 years old and showed a male

predominance (>65%). Their occupation was mainly farming, and ocular trauma was the main pathogenic factor. The depth of hypopyon in the FCI group was comparable to BCI group. Despite this severe infection, corneal perforation occurred in only 1 patient (16.7%) with bacterial keratitis. In our cohort, eight patients were misdiagnosed as viral keratitis and had application of local glucocorticoids.

Table 1
Preoperative basic information of patients.

Parameter	FCI (n=19)	BCI (n=6)
Age (years)	55.3±11.6	59.5±9.7
Gender (male/ female)	13/6	5/1
Farmers (%)	78.9%	66.7%
Ocular trauma (%)	47.4%	50.0%
Depth of hypopyon (mm)	4.7±2.1	4.7±1.9
Prep-perforation of cornea (%)	0	16.7%
Use of glucocorticoids before diagnosis (%)	36.8%	16.7%
FCI= Fungal corneoscleral infection; BCI=Bacterial corneoscleral infection;		
Preop=Preoperative; BCVA=Best-corrected visual acuity		

Microbiological investigations results.

Among 19 patients with fungal corneal ulcer, the specific fungal diagnosis included nine cases of *Fusarium*, four cases of *Aspergillus*, four cases of *Pythium Insidiosum*, one case of *candida*, and one negative culture with corneal scraping showing the fungal hyphae. Among 6 patients with bacterial corneal ulcer, the specific results of the culture included two cases of *pseudomonas aeruginosa*, one case of *Klebsiella*, one case of *Aeromonas hydrophila*, and two cases of negative culture with corneal scraping showing the Gram-negative bacteria.

Infection control and recurrence

In our study, the infection was controlled in 23 patients (92%), and recurred in two patients (8%) with severe fungal infection who received local glucocorticoids before diagnosis. What's more, the pathogen of infection in two patients was *Pythium Insidiosum*, which was so virulent and recurrence occurred within 4 to 6 days after surgery rapidly. The two patients still failed to response to repeat corneoscleral graft and had to be enucleated due to endophthalmitis.

A special case of recurrence was patient with aspergillus fumigatus corneoscleral infection. One month after TCG, there was a white exudation over the iris surface and lens at 12-2 points. Corneal edema was mild. The endothelial cell count was 2375/mm^2. Antifungal therapy included frequent Natamycin eye drops, subconjunctival and anterior chamber injection of 1 mg/ml voriconazole. The recurrence was controlled after 1 month of antifungal treatment. After 3 months of continued therapy, most of the

recurrent lesions in the anterior chamber disappeared and corneal endothelial cell count was 2208/mm^2. However, the iris texture was atrophic and the lens was white and cloudy. Fortunately, the CDVA increased from preoperative HM/BE to postoperative 0.7 after cataract surgery. (as shown in Fig. 3).

Visual acuity outcomes

Figure 2 showed 23 patients' preoperative and postoperative BCVA at the last of follow-up except for two patients who had to be enucleated. Before surgery, all eyes (100%) had a LogMAR BCVA>1.3, reaching the diagnosis criterion for monocular blindness, whose visions were light perception (LP) or hand movement (HM). These numbers decreased to 57% postoperatively. Changes in BCVA from preoperative to postoperative values were significant ($Z=4.22$, $P<0.001$;Figure 4). Patients with FC and HM vision were affected by complications during the follow-up period. The comparative photos of four patients with total suppurative keratitis before TCG, and 1 year after TCG are shown in Figure 5.

Indication of Intraocular pressure

Nine patients (36%) had elevation of intraocular pressure preoperatively, with IOP ranging from 24-55 (average: 32±10) mmHg. Nevertheless, the IOP after surgery was within the normal range of 9-21 (average 14.8±3.7) mmHg. UBM performed one month after surgery showed that most of the peripheral chamber angle was closed due to localized anterior synechia in all patients. But an obvious filter passage about 2 mm behind the corneal limbus was present at the junction between the donor and the recipient sclera in 2 patients (as shown by the arrow in Fig. 6).

Postoperative complications.

Table 2 lists the common complications after TCG for devastating corneoscleral infections.

Table 2
Postoperative complications in FCI and BCI group

Complication	FCI (n=19)	BCI (n=6)
Infection recurrence	3	0
Corneal epithelial defects	4	2
Secondary glaucoma	0	0
Choroidal detachment	3	0
Endophthalmitis	2	0
FCI= Fungal corneoscleral infection; BCI=Bacterial corneoscleral infection.		

Graft Immune rejection. Immune rejection occurred in 9 patients (36%) of which occurred within 1 months after surgery in 4 eyes, at 5 months in 3 eyes, and at 6 months in 2 eyes. Among them, 7 eyes with rejection within 5 months were patients with fungal keratitis. In two patients with bacterial keratitis, the corneal rejection occurred 6 months after the surgery. The above patients did not receive regular follow-up

examinations due to personal reasons, and so the tacrolimus eye drops were discontinued. These patients came to the hospital more than a week after the onset of graft rejection. The patients received anti-rejection treatment with systemic and local glucocorticoids and immunosuppressants after which the degree of conjunctival congestion and graft edema improved, but corneal transparency was not restored.

Corneal Epithelial Defects

During the follow-up period, corneal epithelial defects occurred 3 times in 2 eyes and 2 times in 2 eyes which resulting in graft ulcer. The patients had to accept permanent tarsorrhaphy. External punctiform roughness in central or inferior corneal epithelium occurred in 3 eyes. After treatment with 0.3% sodium hyaluronate eye drops and deproteinized calf blood extract eye gel, the epithelium was restored to being smooth.

Choroidal detachment. Seriously, shallow anterior chamber, low intraocular pressure and choroidal detachment occurred in 3 patients (3/25) at three to five weeks postoperatively. They all suffered from corneoscleral fungal infections preoperatively. This suggests that it is important for us to master the strength of overlap suture and to avoid choroidal detachment due to slack suture.

Graft survival condition

The follow-up period ended in June 2020 or when additional surgery or eyeball enucleation was required, whichever was earlier; the mean follow-up time was 17.5 ± 8.9 months. Successful epithelialization was achieved in all eyes in a period of 10.6 ± 3.9 days. At the last follow-up, 21eyes (84.0%) had a stable ocular surface. The graft survival curves of overall patient was presented in Figure 7. The survival of ocular surface stability was 73.6% and 43.9% at 1 and 3 years after surgery, respectively.

Discussion

Therapeutic keratoplasty is indicated in cases in which infectious corneal disease progresses despite maximal medical therapy, the globe integrity and useful vision are compromised[8, 11, 12]. We report the outcome of modified tectonic corneoscleral graft (TCG) with corneal infections involving the limbus and partial sclera. The existing literature looking particularly at this subset of patients is sparse. Moreover, these patients may be advised evisceration because of lower probability of a successful outcome and hopeless of eye salvation. This is one of the reasons why case-control studies cannot be designed. We hereby report our results of modified TCG in such devastating cases.

The finding of our study indicated that fungi was more common than bacteria, of which *Fusarium* was the most common. It was consistent with findings that fungal keratitis is the principal cause of blindness in Asia[13] and *Fusarium* was the most common causal agent causing fungal keratitis in developing country[14, 15]. More attention should be paid to *Pythium Insidiosum*, which needs to be confirmed by DNA sequencing. It had high rate of postoperative recurrence and enucleation[16, 17]. In this series, two patients with enucleation were *Pythium Insidiosum* infection.

In the current cohort, surgical modifications were made compared with Hirst's method[12] to improve the success rate and reduce postoperative complications. First, the diseased cornea along the corneal limbus and adjacent infected sclera were excised, to ensure that all pathogens were removed. Second, the fresh donor cornea with a thinned scleral ring was overlapped and fixed on the implant bed with sutures, and the anterior chamber was reformed with viscoelastic agent. It not only reduces the difficulty of the side-by-side suture at corneal limbus[12], but also reduces the risk of secondary glaucoma due to the 360° formation of anterior chamber with viscoelastic agents[18]. Remarkable improvement was noted that the IOP of all patients was within the normal range after surgery. Third, the donor was retained from 2mm scleral ring posterior to the limbus, making it possible to reconstruct the anterior segment structure.

The procedure is effective in eradicating infection, salvaging the eyeball and saving some useful vision. Previous reports revealed that the recurrence rate of infection ranged from 30.4–65.0% for end stage corneal disease[8, 9, 12]. Of those receiving therapeutic large-diameter keratoplasty, there may still be cases where the infection cannot be completely removed. In this study, there was a much better exception postoperatively that 23/25 cases got rid of infection and restored anatomic integrity of the eye. In addition, some studies have demonstrated poor visual outcomes because of the well-known risks of surgery and the consequences of the infectious disease itself[8, 10, 12]. Another study showed that large-diameter penetrating keratoplasty may reduce postoperative astigmatism and improve visual acuity outcomes[19]. In the present series, the rate of monocular blindness declined from 100–57%. There were 10 patients with best corrected visual acuity greater than 0.05. In 3 cases, the eyeballs were preserved, but the visual acuity was hand movement, which was related to the complicated cataract caused by inflammation and postoperative complications.

Previous studies of penetrating keratoplasty for the treatment of infectious keratitis have shown graft survival rates of 78.4%-95.0%[20–22]. But few reports have reported graft survival for large-diameter penetrating keratoplasty, which may be related to the rare cases of severe infection. Our study showed the survival of ocular surface stability declined gradually with time, from 73.6% at 1 year to 43.9% at 3 years. At the final follow-up (mean, 17.5±8.9 months), 84.0% of the eyes had a stable ocular surface, indicating better long-term results.

It is noteworthy that the occurrence of complications that may lead to transplantation failure, especially graft rejection [23, 24]. High risk factors include; (1) ultra-large diameter corneal graft[25, 26], (2) severe infection[27] and (3) fungal infection in which topical glucocorticoids are avoided in the early post-surgical period[28, 29]. For preventing graft rejection, we used tacrolimus and glucocorticoids locally with concentration gradients. In this series, the incidence rate of immune rejection was 36%, and higher than that of conventional penetrating keratoplasty (5%-18%) [24, 30]. However, our further analysis, we found that 16.7% of the patients did not have regular follow-ups and did not use the topical drugs regularly. 4 cases occurred immune rejection of corneal grafts 2 weeks to 1 month after surgery. All the four patients with fungal corneal ulcer did not receive topical glucocorticoids in the early postoperative period, which may be another reason for early postoperative immune rejection. Thus, tacrolimus is a potent

immunosuppressant[31–33] and should be the first choice for antirejection after TCG[25]. In addition, good compliance also reduces immune rejection after successful operation.

This study still needs to increase the number of cases and extend the follow-up time. The disadvantage is that the number of cases is small, as a single case may have a large impact on the outcome, so survival analysis of implant transparency and comparison of fungal and bacterial outcomes have not been performed.

In summary, as is evident from our study, modified TCG with scleral ring was an effective way to avoid primary evisceration, provide structural stability and preserve useful vision for devastating corneal ulcers involving limbus and sclera. Regular application of tacrolimus, timely addition of glucocorticoid and good compliance may decrease the postoperative course challenging.

Declarations

Financial Disclosure

The authors indicate no financial conflict of interest.

Conflicts of Interest

The authors have no conflicts of interest in this article.

Acknowledgments

The authors would like to thank all the professors and nurses in the Eye Hospital of Shandong First Medical University. This study was supported by the National Natural Science Foundation of China (81870639 81900907); Key Project of National Natural Science Foundation of China (81530027); Taishan Scholarship Program (20150215, 201812150).

References

1. Khor W, Prajna V, Garg P et al (2018) The Asia Cornea Society Infectious Keratitis Study: A Prospective Multicenter Study of Infectious Keratitis in Asia. Am J Ophthalmol 195:161–170
2. Pan X, Jiang T, Zhu H et al (2016) Corneal infection in Shandong peninsula of China: a 10-year retrospective study on 578 cases. International journal of ophthalmology 9:53–57
3. Song X, Xie L, Tan X et al (2014) A multi-center, cross-sectional study on the burden of infectious keratitis in China. PLoS ONE 9:e113843
4. Cao J, Yang Y, Yang W et al (2014) Prevalence of infectious keratitis in Central China. BMC Ophthalmol 14:43
5. Reynolds M, Alfonso E (1991) Treatment of infectious scleritis and keratoscleritis. Am J Ophthalmol 112:543–547

6. Czakó C, Sándor G, Popper-Sachetti A et al (2019) [Ocular manifestations and management of Fusarium and Sarocladium infections]. Orv Hetil 160:2–11
7. Zhao B, Xu X, Li B et al (2013) Eye enucleations in Beijing Tongren Hospital in the last 50 years. Br J Ophthalmol 97:107–108
8. Alfaro Rangel R, Szentmary N, Lepper S et al (2021) Large-Diameter Penetrating Keratoplasties are Mostly Due to Very Severe Infectious Keratitis and Cannot Always Prevent Secondary Enucleation. Klin Monbl Augenheilkd
9. Thatte S, Dube AB, Dubey T et al (2020) Outcome of Sclerokeratoplasty in Devastating Sclerocorneal Infections. J Curr Ophthalmol 32:38–45
10. Zhong J, Wang B, Li S et al (2018) Full-thickness conjunctival flap covering surgery combined with amniotic membrane transplantation for severe fungal keratitis. Experimental and therapeutic medicine 15:2711–2718
11. Cowden J, Copeland R, Schneider M (1989) Large diameter therapeutic penetrating keratoplasties. Refractive & corneal surgery 5:244–248
12. Hirst L, Lee G (1998) Corneoscleral transplantation for end stage corneal disease. Br J Ophthalmol 82:1276–1279
13. Srinivasan M (2004) Fungal keratitis. Curr Opin Ophthalmol 15:321–327
14. Mahmoudi S, Masoomi A, Ahmadikia K et al (2018) Fungal keratitis: An overview of clinical and laboratory aspects. Mycoses 61:916–930
15. Xie L, Zhong W, Shi W et al (2006) Spectrum of fungal keratitis in north China. Ophthalmology 113:1943–1948
16. Gaastra W, Lipman L, De Cock A et al (2010) Pythium insidiosum: an overview. Vet Microbiol 146:1–16
17. Hasika R, Lalitha P, Radhakrishnan N et al (2019) Pythium keratitis in South India: Incidence, clinical profile, management, and treatment recommendation. Indian J Ophthalmol 67:42–47
18. Schmitz K, Behrens-Baumann W (2000) Penetrating re-keratoplasty a chaud using healon 5 for stabilizing the anterior chamber. Der Ophthalmologe: Zeitschrift der Deutschen Ophthalmologischen Gesellschaft 97:566–570
19. Skeens H, Holland E (2010) Large-diameter penetrating keratoplasty: indications and outcomes. Cornea 29:296–301
20. Chen X, Li X, Zhang X et al (2021) Comparison of complications and visual outcomes between big-bubble deep anterior lamellar keratoplasty and penetrating keratoplasty for fungal keratitis. Clinical & experimental ophthalmology
21. Anshu A, Parthasarathy A, Mehta J et al (2009) Outcomes of therapeutic deep lamellar keratoplasty and penetrating keratoplasty for advanced infectious keratitis: a comparative study. Ophthalmology 116:615–623

22. Ayalew M, Tilahun Y, Holsclaw D et al (2017) Penetrating Keratoplasty at a Tertiary Referral Center in Ethiopia: Indications and Outcomes. Cornea 36:665–668
23. Gerber D, Bonham C, Thomson A (1998) Immunosuppressive agents: recent developments in molecular action and clinical application. Transplantation proceedings 30: 1573-1579
24. Abudou M, Wu T, Evans J et al (2015) Immunosuppressants for the prophylaxis of corneal graft rejection after penetrating keratoplasty. CD007603, The Cochrane database of systematic reviews
25. Armitage W, Goodchild C, Griffin M et al (2019) High-risk Corneal Transplantation: Recent Developments and Future Possibilities. Transplantation 103:2468–2478
26. Zhu B, Zhou J, Zheng J et al (2020) Corneal graft melting: a systematic review. International journal of ophthalmology 13:493–502
27. Stryjewski T, Chodosh J, Kim I et al (2017) Severe corneal ulcer with progression to endophthalmitis and high-grade bacteremia. American journal of ophthalmology case reports 6:30–32
28. Mundra J, Dhakal R, Mohamed A et al (2019) Outcomes of therapeutic penetrating keratoplasty in 198 eyes with fungal keratitis. Indian J Ophthalmol 67:1599–1605
29. Wang T, Li S, Gao H et al (2016) Therapeutic dilemma in fungal keratitis: administration of steroids for immune rejection early after keratoplasty. Graefe's archive for clinical and experimental ophthalmology = Albrecht von Graefes Archiv fur klinische und experimentelle Ophthalmologie. 254:1585–1589
30. Tabbara K (2008) Pharmacologic strategies in the prevention and treatment of corneal transplant rejection. Int Ophthalmol 28:223–232
31. Xiang D, Wang Y, Jia Y et al (2017) The observation of tacrolimus eye drops preventing the early immunological rejection after penetrating keratoplasty for fungal keratitis. Chinese journal of ophthalmology 53:305–310
32. Li X, Zhang Y, Yin M et al (2019) [The effectiveness and safety of topical 0.1% tacrolimus after high-risk penetrating keratoplasty]. Chinese journal of ophthalmology 55:419–427
33. Schreiber S, Crabtree G (1992) The mechanism of action of cyclosporin A and FK506. Immunol Today 13:136–142

Figures

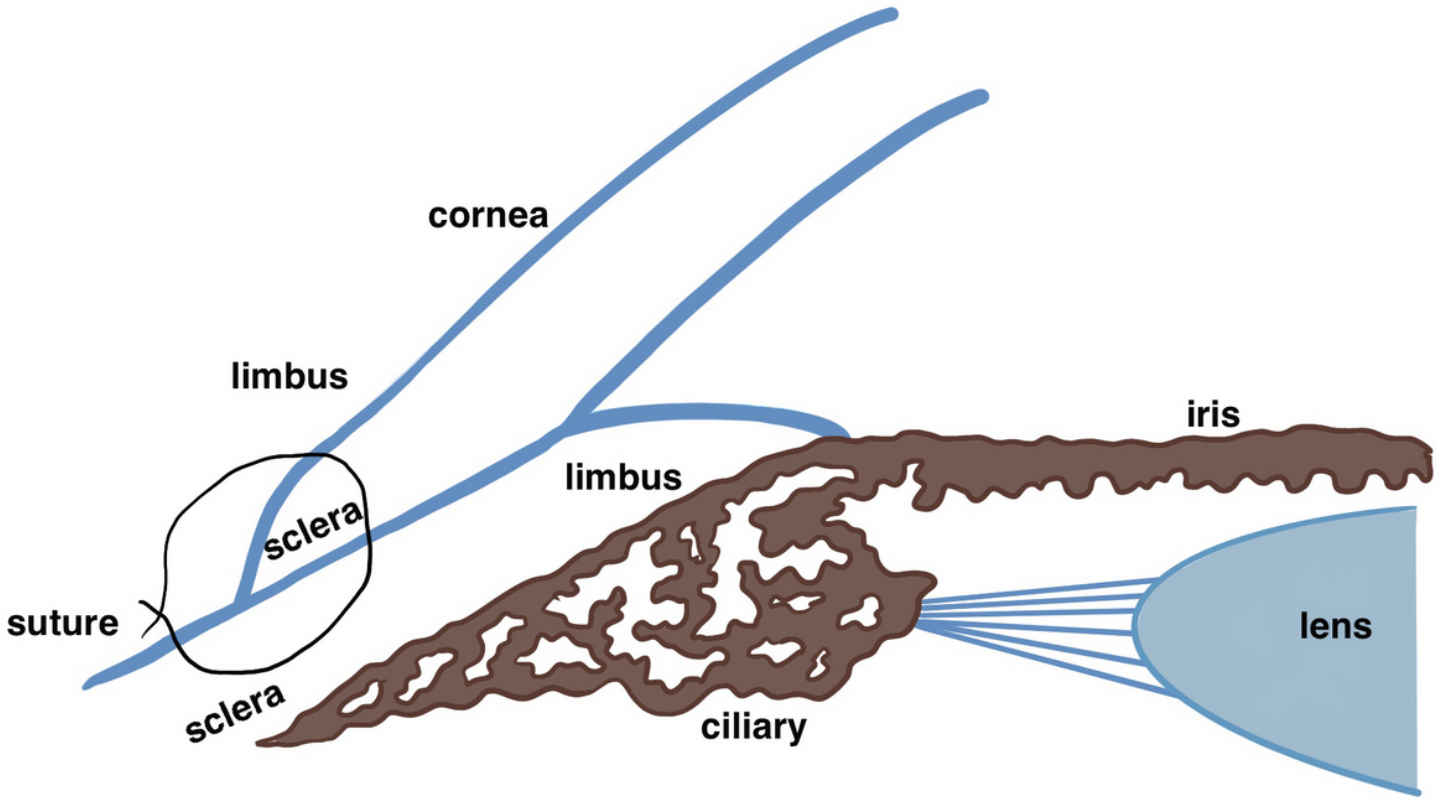

Figure 1

The scleral ring of donor was sutured overlapped on to the recipient sclera.

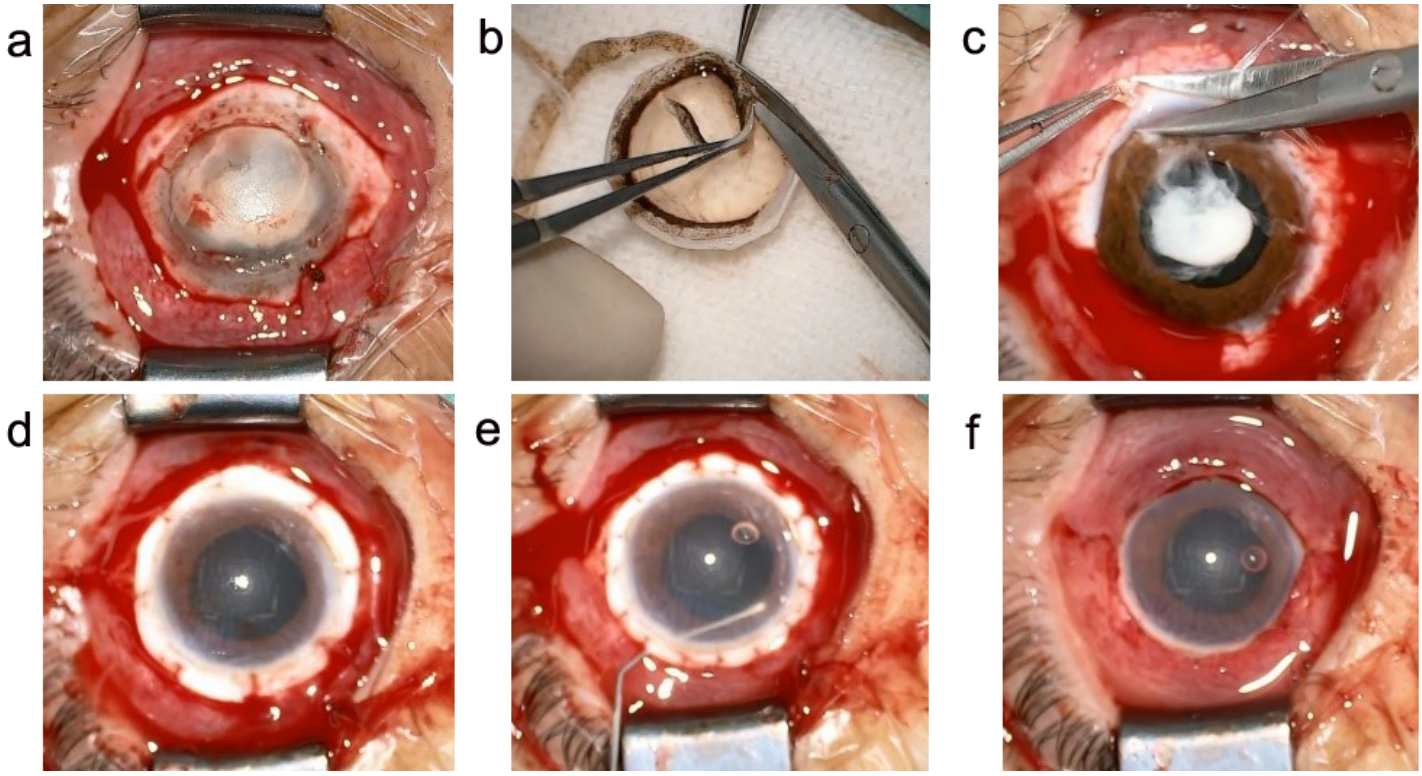

Figure 2

Operative procedure of anterior segment reconstruction (TCG). A 360° bulbar conjunctival incision was made along the limbus(a); The fresh donor corneal graft with a 2 mm wide scleral ring was cut off from the endothelial layer with 50% thickness of sclera tissue(b); A corneal scissors was used to remove the diseased cornea, and a scleral scissors was used to excise the infiltrated or infected scleral tissue until there was no evidence of infection under the operating microscope(c); The scleral ring was sutured overlapped on to the recipient scleral surface(d); The anterior chamber was formed and its angle separated by viscoelastic agent(e); The bulbar conjunctiva was sutured and fixed to the corneal limbus(f).

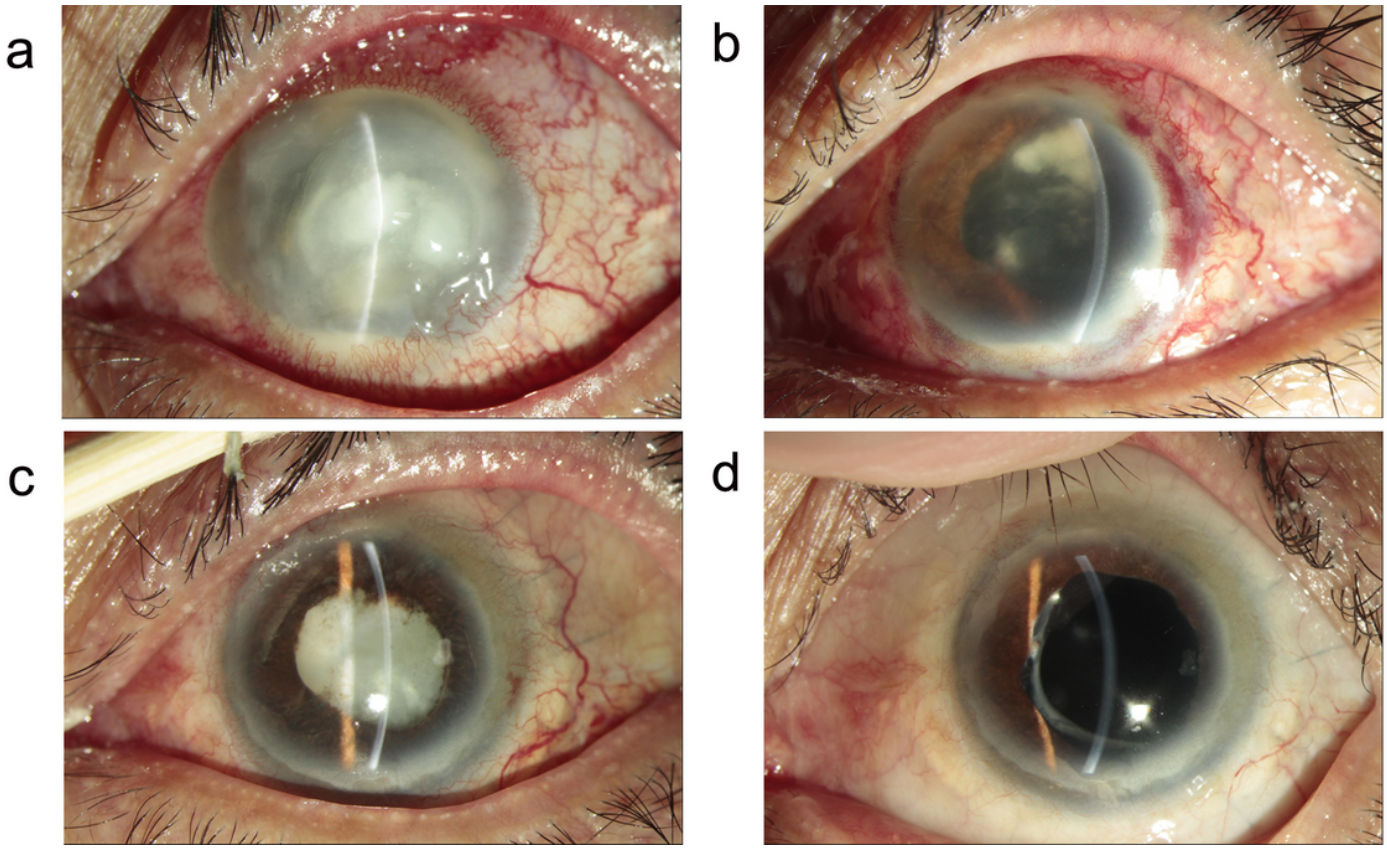

Figure 3

Photographs of patient with recurrent anterior chamber fungal infiltrates after TCG. Preoperative photograph of patient (a); One month after TCG, examination shows conjunctival congestion, corneal edema, and white exudation on the iris surface and lens at 12-2 points(b); After 3 months of treatment, the recurrent lesions in anterior chamber disappeared, but the iris is atrophied, and the lens has a white opacity(c); Intraocular lens replaces white lens after cataract surgery(d).

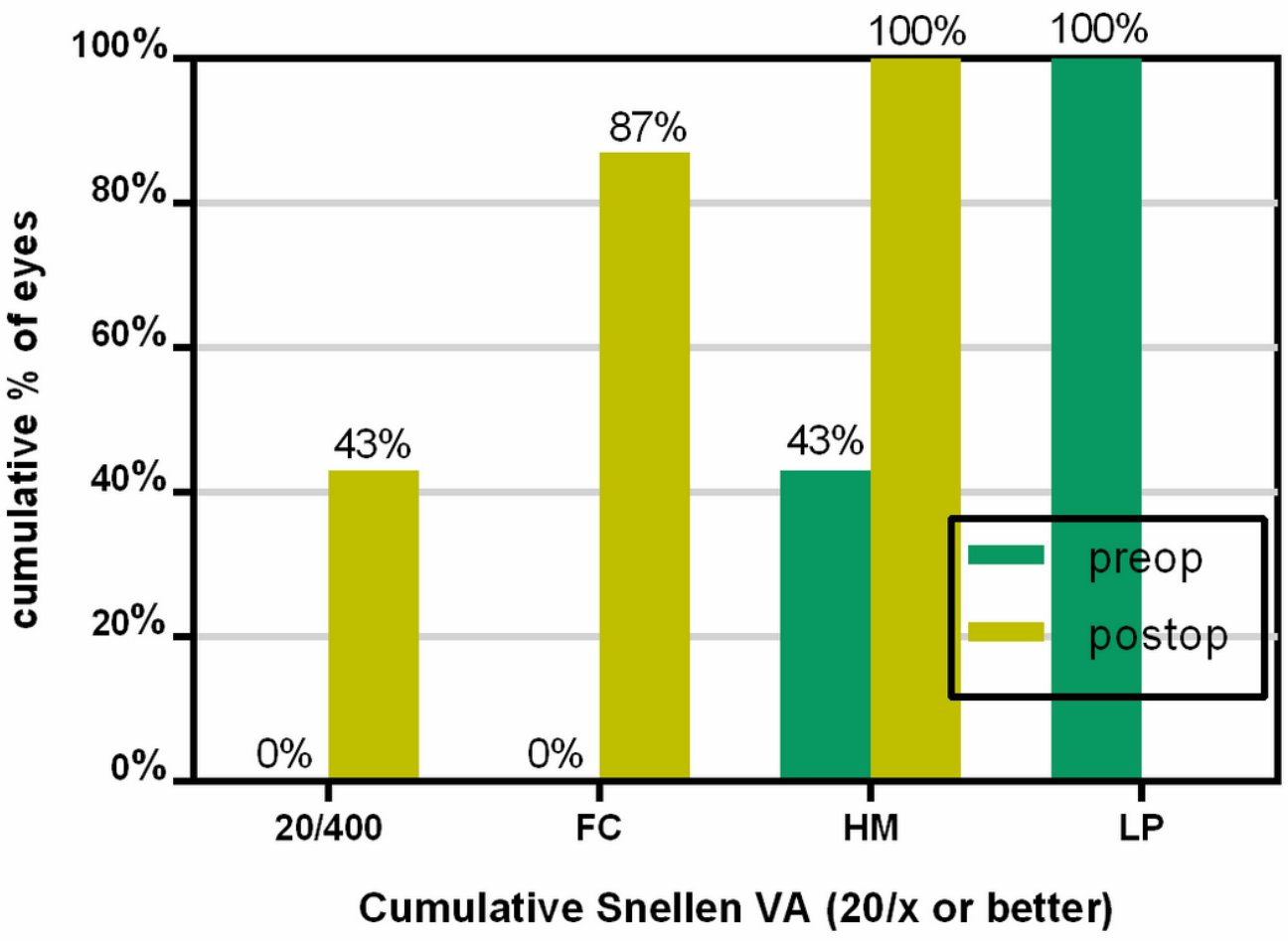

Figure 4

Patients' cumulative BCVA before and after TCG. Preop=preoperative; Postop=postoperative; FC=finger counting; HM=hand movement; LP=light perception.

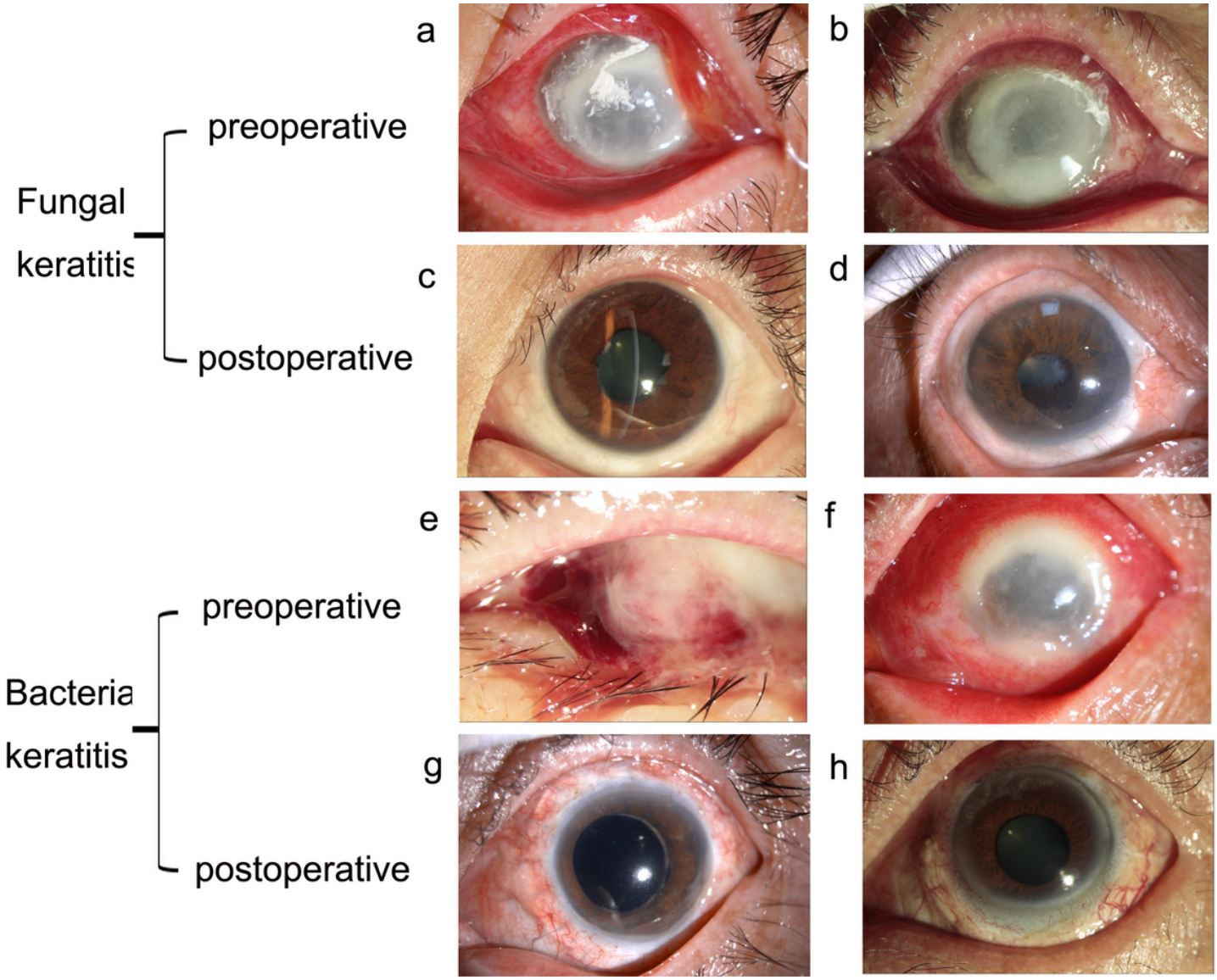

Figure 5

Photographs of four patients before and 2 year after TCG. The first group of pictures(a~d) show fungal keratitis while the second set of pictures(e~h) with bacterial keratitis before and 1 year after TCG.

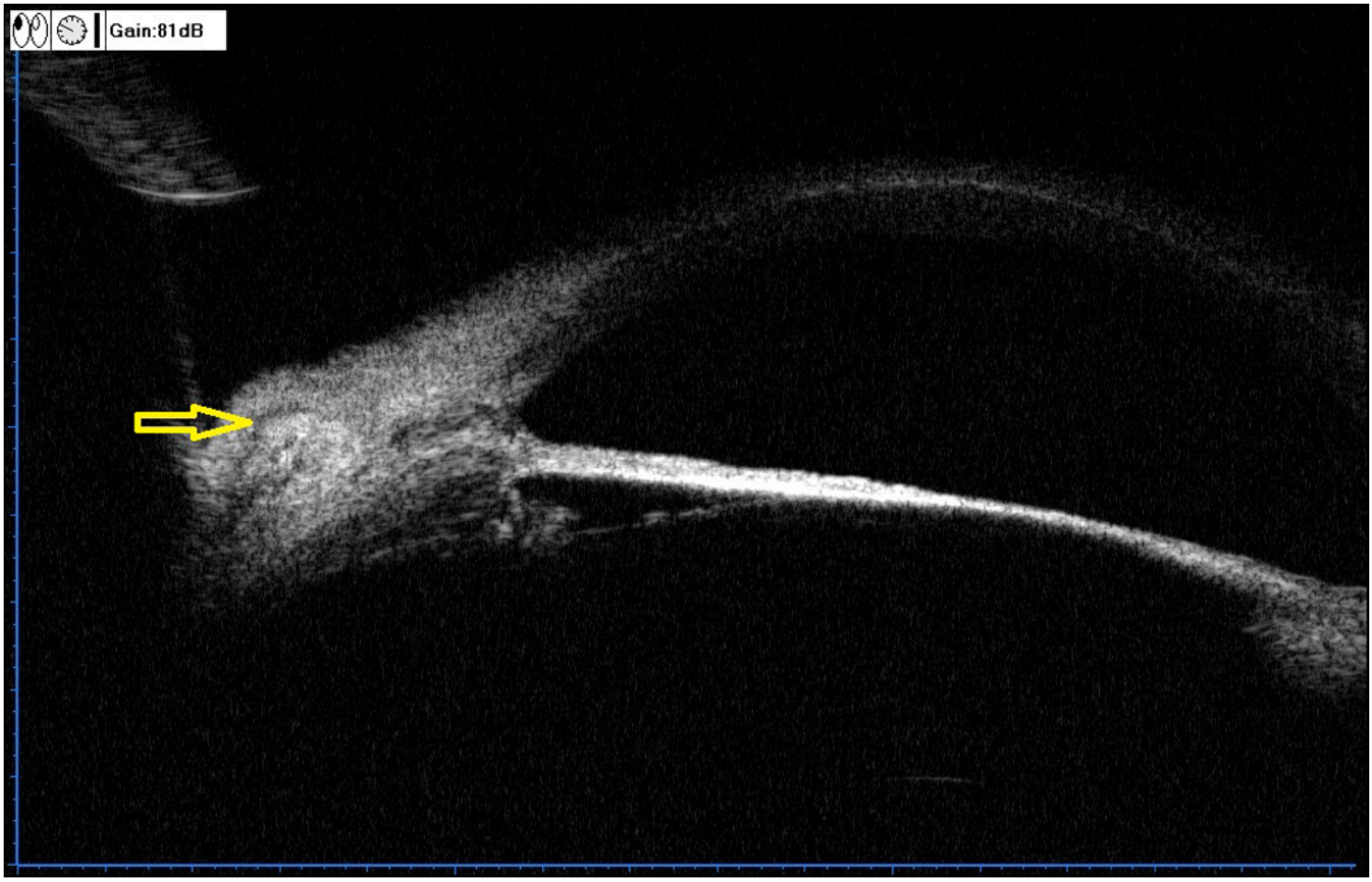

Figure 6

UBM examination after TCG. The picture shows closure of corneal angle, anterior synechia of iris, and filtering passage at the scleral junction of donor and recipient 2 mm behind corneal limbus (arrow).

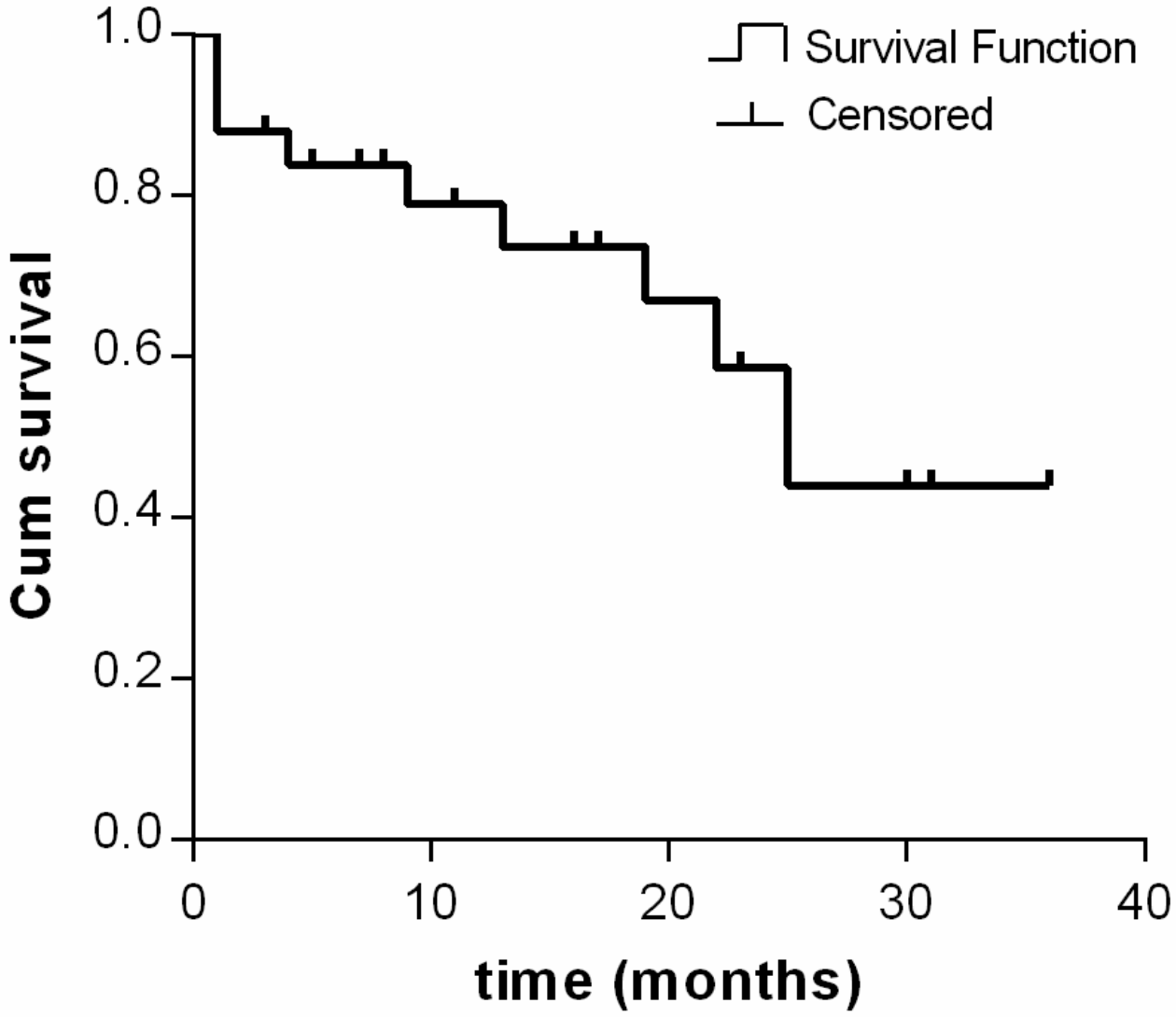

Figure 7

Graft survival curve of ocular surface stability.