Clinical Manifestations, Outcomes, and Histopathology of Recurrent Uveitis in Patients Underwent Pupil Coroplasty Combined with Cataract Surgery

Hui Lu
Capital Medical University

Doudou Chen
Ineye Hospital of Chengdu University of Traditional Chinese Medicine

Siquan Zhu (dr_siquan@163.com)
Capital Medical University

Research Article

Keywords: Uveitis, Cataract, histopathology, Recurrence, Immunosuppression

Posted Date: January 4th, 2022

DOI: https://doi.org/10.21203/rs.3.rs-1154195/v1

Abstract

Purposes: This study was aimed to evaluate the clinical manifestations of recurrent uveitis in patients underwent pupil coroplasty combined with cataract surgery, and discovery the histopathological changes of iris tissues.

Methods: There 28 patients with recurrent uveitis-induced cataract, who had underwent pupil coroplasty, phacoemulsification, and intraocular lens implantation were enrolled in this study. The clinical manifestations and outcomes of the enrolled patients were analyzed. The histopathological changes of iris tissues were observed by hematoxylin and eosin (HE) staining.

Results: The uveitis were idiopathic in 89.29% cases (n = 25). Before the surgery, 20 cases had no topical medication for at least 3 months. The preoperative BCVA was > 0.5 in all cases. During the follow-up of 5-10 years, no recurrence of uveitis was found in 96.43% cases (n = 27). Uveitis only recurred in one case along with the onset of ankylosing spondylitis at the 6th week after the surgery. HE staining showed obvious atrophy of iris stroma in all samples. The hyperplasia of pigment cells was observed in the pigment epithelium (n = 9) and even invaded into stroma (n = 19). The infiltration of inflammatory cells in iris tissues was found in 7 cases, and neovascularization in the surface of the iris was found in 2 cases.

Conclusion: Recurrent uveitis was characterized by the atrophy of iris stroma, and some cases also exhibited hyperplasia of pigment cells and infiltration of inflammatory cells. The surgery proposed in this study can effectively prevent the long-term recurrence of uveitis.

Background

Uveitis is a severe inflammatory ocular disease, which can lead to visual impairment and even irreversible blindness [28]. The prevalence of uveitis depends upon multiple factors, including the age, sex, race, geographic distribution, environment, genetics, and social habits [25]. The estimated annual incidence of uveitis is about 17-52 persons per 100,000 people, and a prevalence of approximately 38-284 cases per 100,000 people in some developed countries [9, 15, 18]. Uveitis is usually classified based on anatomical location, duration and course of inflammation, and nature of inflammation. Anterior uveitis is the most prevalent form of uveitis, accounting for approximately > 50% cases [7]. In clinical, the uveitis is idiopathic in most cases (48-70%), and the traumatic, inflammatory, and infectious immunologic disorders can also induce the occurrence of uveitis [10]. Until now, the main treatment strategy for uveitis is to protect the ocular tissues from damage through inhibiting inflammation, and activating immunosuppression to stop fueling T cell reactivity [26]. Topical corticosteroid is usually applied as the first-line therapy for uveitis. Conventional immunomodulatory agents are added as second-line therapy utilized for their durable control of ocular inflammation and as a steroid-sparing agent [24]. However, uveitis is easy to relapse even after effective treatment due to the reappearance of infectious organisms and the localization of immune complexes in the uveal tract [3, 14].

Uveitis can lead to a variety of complications, such as cataract, retinal neovascularization, choroiorentianl scars, cystoid macular edema, glaucoma/hypertension, epiretinal membranes, and retinal detachment [16]. Cataract is one of the most frequent complications of uveitis, and also a major cause of visual loss [5]. Both the intraocular inflammation and the long-term local or systemic use of corticosteroid contribute to the onset of cataract [6, 12]. Cataract surgery is one of the most common outpatient procedures performed in China, but it is still a great challenge for patients with uveitis. The outcomes of cataract surgery in cases with uveitis is not predictable due to diverse factors, including surgical techniques, uncertain inflammatory sequelaes, and the variable and unpredictable reversibility of complications [5]. Patients with a history of uveitis are at higher risk for post-operative and recurrent inflammation following cataract surgery [4, 8, 12]. Before cataract surgery, the quiescent uveitis for at least three months is generally accepted as the minimum amount of time prior to surgical intervention [12]. Scrupulous case selection and aggressive control of pre and postoperative intraocular inflammation are also important for the postoperative success [27]. Recently, some encouraging outcomes on visual acuity were revealed in patients with uveitic cataract after surgery. For example, Singh K et al. have shown that the best corrected visual acuity (BCVA) is improved in 92.58% (n = 50) eyes and cystoidmacular edema was only found in 5% (n = 3) eyes after cataract surgery [22]. Yangzes S et al. have revealed that all children with uveitic cataract had significant improvement in BCVA post cataract surgery, and 55.17% (n = 32) eyes achieved a visual acuity of 20/40 or more [27]. Balta O et al. have found that the BCVA of 20/40 or better was achieved in 81.8% eyes (n = 18) in idiopathic anterior uveitis, 80.0% eyes (n = 8) in herpes simplex virus-associated anterior uveitis, 90.0% eyes (n = 9) in Fuchs' heterochromic iridocyclitis, and 100% (n = 13) in anterior uveitis associated with collagen vascular diseases over the 4 years of follow-up [1]. However, it is worth noting that uveitis is usually not quiescent after cataract surgery, and the recurrence of uveitis can be observed at an uncertain time [1, 29].

In this study, we analyzed the baseline characteristics, preoperative intervention, postoperative care, outcome, and follow-up of 28 recurrent uveitis-suffered patients underwent pupil coroplasty, phacoemulsification with clear-cornea incision, and intraocular lens implantation. The histopathological changes of iris tissues in these patients were further analysed. Our findings may reveal the underlying histopathological mechanism of recurrent uveitis, and provide guidance for the clinical treatment of recurrent uveitis.

Materials And Methods

Subjects

Total 28 patients underwent cataract surgeries, including pupil coroplasty, phacoemulsification with clear-cornea incision, and intraocular lens implantation were screened from Beijing Tongren Hospital (Beijing, China) between July, 2009 and March, 2013. The cataract surgeries were performed by an experienced surgeon. The patients had suffered from anterior uveitis for twice at least, exhibiting pupil deformation and adhesion, and formation of organizational membrane. The uveitis-induced cataract (including age-related cataract) was diagnosed as any lens opacity with visual acuity of 20/40 or less in the absence of

other causes of visual loss according to Lens Opacities Classification System. The patients were followed up for 5-10 years. Both the preoperative and postoperative manifestations of the enrolled patients were analyzed, including the baseline characteristics, preoperative intervention, postoperative care, outcome, and follow-up. This study was approved by the ethics committee of Beijing Tongren Hospital in accordance with the Declaration of Helsinki (TRECKY2012-02). Written informed consents were obtained from all cases.

Histopathological examination

The iris tissues were collected from patients during cataract surgery. The isolated tissues were immediately fixed in 10% formaldehyde, dehydrated in graded ethanol (70 to 100%), cleared in xylene, paraffin-embedded, and sliced at 5 μm. After dewaxed in xylene and rehydrated in graded ethanol, the tissue sections were stained with Hematoxylin and Eosin (HE). The histopathological change of iris tissues was observed under a microscope (IX71, Olympus, Japan).

Results

Baseline characteristics and preoperative intervention

A total of 28 patients with an age range of 14-82 years old were enrolled in this study, among which 10 (35.71%) were males and 18 (64.29%) were females. All the enrolled patients had suffered from anterior uveitis. Except that in 2 cases with ankylosing spondylitis and 1 case with Sjogren's syndrome, the uveitis in the left 25 cases were all idiopathic. The uveitis-induced cataract (including age related cataract) was determined in all cases. There were 12 cases also had secondary glaucoma, and two of them lost control of intraocular pressure (intraocular pressure > 21 mmHg). The preoperative BCVA was 0.6 in 1 case, < 0.5 in 21 cases, and < 0.1 in 6 cases. All patients had no systemic medication within 3 months before the surgery. There 8 cases maintained topical eye drops for lowering intraocular pressure, and one of them also received eye drops of glucocorticoid for anti-inflammation at the same time. The other 20 patients had no topical medication for at least 3 months. In the perioperative period (3 days before the surgery), all cases received eye drops of levofloxacin four times a day. Two cases with uncontrolled intraocular pressure received intravenous injection of 20% mannitol. The intraocular pressure was immediately decreased to < 26 mmHg in 1 case after injection for 30 min, while it was not reduced to a normal level for another case (> 26 mmHg). By applying preoperative anterior chamber puncture, the following cataract surgery was successfully performed in this case. Iris hemorrhage was an intraoperative complication observed in 2 cases.

Postoperative care and follow-up

After surgery, all patients received 3 weeks of topical eye drops of tobramycin and dexamethasone for anti-inflammation, as well as topical eye drops of recombinant bovine basic fibroblast growth factor for nutrition. One case with aqueous flare continued to use the above topical eye drops until the inflammation was disappeared (at the 6th week after the surgery). There was an obvious improvement in

visual gain of call cases, with a preoperative BCVA of > 0.5. These patients also exhibited normal intraocular pressure, right position of intraocular lens, and no occurrence of the complications of posterior cataract, corneal edema, and corneal decompensation. In addition, postoperative keratic precipitates was found in 2 cases, which was recovered within 1 week. During the follow-up of 5-10 years, no recurrence of uveitis was found in 27 cases (96.43%). Notably, uveitis recurred in one case with the onset of ankylosing spondylitis at the 6th week after the surgery.

Histopathological manifestations

The histopathological changes of iris tissues were observed by HE staining. All samples exhibited obvious atrophy of iris stroma (Fig 1A and B). The hyperplasia of pigment cells was observed in the pigment epithelium (n = 9, 32.14%) and even invaded into stroma (n = 19, 67.86%) (Fig 1A and B). In addition, the infiltration of inflammatory cells in iris tissues was found in 7 cases (25.00%), and neovascularization in the surface of the iris was found in 2 cases (7.14%) (Fig 1A).

Discussion

Cataract is one of the most frequent complications of uveitis, which can be induced by chronic inflammatory response and use of corticosteroids [20]. Surgery is generally considered as the only effective therapeutic strategy for uveitis complicated with cataract, and the commonly used surgical strategies include extracapsular extraction, intracapsular extraction, lensectomy, and phacoemulsification [11]. At present, the surgical program for uveitic cataract mainly depends on the experience of doctors. There is still no clear standard for the selection of scrupulous cases, indications and contraindications, surgical techniques, and operation time [5, 27]. Foster et al. have described four indications for cataract surgery in patients with a history of uveitis, including phacoantigenic uveitis (active inflammation as a result of leak-age of lens proteins), visually significant cataract, cataract that impairs fundus assessment in cases with suspected fundus pathology, and cataract that precludes adequate visualization of the posterior segment in cases undergoing posterior segment surgical procedure [19]. In this study, all the enrolled patients with uveitis-induced cataract belong to the indication of visually significant cataract, and the phacoemulsification with clear-cornea incision combined with intraocular lens implantation were performed. Except the need of immediate mandatory cataract extraction for phacoantigenic uveitis, preoperatively control of inflammation for at least 3 months has become the guarantee of successful surgery. A meta-analysis based on 89 articles has shown that among uveitic eyes with quiet uveitis before cataract surgery, visual acuity of 20/40 or better was achieved in 68% following phacoemulsification, 72% following extracapsular cataract extraction, and 40% following pars plana lensectomy [13]. On the contrary, active uveitis at the time of cataract surgery was associated with worse visual outcomes [13]. Consistent with this consensus, all patients enrolled in this study had no systemic medication within 3 months, and 71.43% patients had no topical medication for at least 3 months before the surgery. Encouragingly, an obvious improvement in visual gain (BCVA > 0.5) was revealed in call cases. Glaucoma is another potentially blinding complication of uveitis, which can be induced by inflammation, secondary corticosteroid response, and angle abnormalities [23]. The surgery is thought to

be necessary for glaucoma patients who cannot control the inflammation by drugs. Here, obvious improvement in visual gain was also revealed in one case maintaining topical eye drops of glucocorticoid before the surgery. The surgery may be conducive to the excretion of immune complexes, prostaglandins, and toxic substances in aqueous humor, thereby controlling intraocular pressure and inflammatory reaction.

Although the cataract surgery achieves relatively good outcome on visual gain in patients with uveitic cataract, postoperative complications and recurrence are still difficult problem to solve. For example, Rahman I et al. have shown that during a minimum follow-up of 5 years, 24% macular oedema or scarring, 96% posterior capsule opacification, 15% glaucoma drainage were found in 61 patients underwent cataract extraction with intraocular lens implantation [17]. Yangzes S et al. have revealed that the complications of visual axis opacification (39.66%), cystoid macular edema (31.03%), and glaucoma (8.62%) were common in total 58 eyes underwent cataract surgery [27]. Here, only the occurrence of keratic precipitates was found in 2 cases after the surgery. This complication may be attributed to the prolonged inflammatory response induced by local dysimmunity. There is nothing to worry that the keratic precipitates was recovered within 1 week. On the other hand, the recurrence risk of uveitis remains. Zhang Y et al. have found that uveitis recurred in 14 eyes (18.9%) within 3 months and inflammation recurred in 34 eyes (45.9%) in the whole follow-up period [29]. Balta O et al. have determined that the incidence of postoperative recurrence of uveitis was 52.7% in 48 patients underwent cataract surgery during 4 years of follow-up [1]. Therefore, avoiding postoperative recurrence has become a great challenge in clinical practice. In this study, in addition to the phacoemulsification with clear-cornea incision, and intraocular lens implantation, pupil coroplasty was also performed in patients with uveitic cataract. Encouragingly, no recurrence of uveitis was found in 96.43% cases (n = 27) during the follow-up of 5-10 years. The findings on the underlying pathological mechanism of chronic uveitis showed that the lymphocytes in patients with uveitis exhibit great resistance to apoptosis, resulting in long-term existence of autoreactive lymphocytes, and subsequently leading to the chronicity and recurrence of uveitis. In addition, the destruction of blood aqueous barrier induced by inflammation leads to severe damage of iris microcirculation through enhancing the permeability of blood vessels and weakening the barrier function. Then freely released immune cells and inflammatory mediators directly contribute to the expansion of inflammatory injury. Therefore, we speculated that the low recurrence of uveitis revealed in this study may be attributed to the removal of pathological tissues to some degrees. Furthermore, the only patient with recurrent uveitis attributed to immunosuppression induced by the onset of ankylosing spondylitis. Our results indicated that pupil coroplasty may reduce the recurrent risk of uveitis due to iris inflammation. However, the inflammation induced by other immunologic disorders is still inevitable for the recurrence of uveitis.

A previous study based on equine experimental uveitis has observed the histopathological characteristics of engorgement of blood vessels, neovascularization, focal or diffuse mononuclear proliferation, exudative retinal detachment, and disorganization of retinal layers [21]. In order to discover the underlying pathological mechanism of uveitis in human, HE staining was performed to reveal the histopathological changes of uveitis-suffered iris tissues in this study. An obvious atrophy of iris stroma was observed in all

cases, which is considered as a prominent feature of uveitis. The inflammation-induced immune abnormality may contribute directly to the iris atrophy in uveitis. Notably, the iris atrophy can also be observed in uveitis at a quiescent period, which is considered as one of the potential causes of recurrence. Since iris cells have an ability to bind and accumulate drugs [2], the atrophy of iris tissues may also contribute to the recurrent of uveitis via inhibiting the combination and reactivity of drugs. In this study, we also observed the hyperplasia of pigment cells in the pigment epithelium and stroma in 32.14% and 67.86% cases, respectively. This phenomenon may be explained that the local immune injury greatly influences the normal structure of iris tissue, leading to the abnormal proliferation of pigment cells. Inflammation in iris tissues was the main pathological feature for uveitis, especially for uveitis at the active stage. Uveitis is known to be initiated by the recognition of T cells to retinal or cross-reactive antigens, and recruited inflammatory cells result in the damage of specific tissues. The inhibition of inflammation and immunosuppression has become the preferred therapeutic strategy for uveitis [26]. Here, we observed the infiltration of inflammatory cells in iris tissues in 25% cases. This phenomenon indicated that patients with a quiet uveitis also have an activated inflammation in iris. Recurrent uveitis is mediated by autoaggressive Th response, which could be induced by dysregulated immune response and T cells infiltration [21]. Therefore, the persistent inflammatory state in iris tissues may directly lead to the recurrence of uveitis after surgery in these cases. It is noteworthy that no recurrence of uveitis was revealed in these cases, except one case with ankylosing spondylitis. This phenomenon may directly attribute to the removal of pathological tissues. Surprisingly, although recurrent uveitis is characterized by a persistent inflammatory response, the inflammatory cell infiltration was not observed in the left 75% cases. It remains unclear why the inflammatory cells were disappeared somehow, and this is an urgent problem to be solved in future.

Conclusion

The atrophy of iris stroma was a prominent feature of uveitis. The hyperplasia of pigment cells and infiltration of inflammatory cells in iris could also be observed in some cases. During the follow-up of 5-10 years, there were no recurrence of uveitis was found in most cases underwent pupil coroplasty, phacoemulsification with clear-cornea incision, and intraocular lens implantation. Uveitis only recurred in one case along with the onset of ankylosing spondylitis after the surgery.

Declarations

Ethics Statement: This study was approved by the ethics committee of Beijing Tongren Hospital in accordance with the Declaration of Helsinki (TRECKY2012-02). Written informed consents were obtained from all cases.

Competing interests: The authors declare that they have no competing interests.

Funding: Not applicable.

Authors' Contributions: H. L., D. C., and S. Z. were involved in the conception and design of the study; H. L. and S. Z. were involved in the data collection; H. L. and D. C. were involved in the analysis and the interpretation of data; H. L. and D. C. were involved in writing the drafts of the manuscript. All authors critically revised the manuscript and gave final approval of the submitted manuscript.

Acknowledgement: Not applicable.

References

1. Balta O, Sungur G, Acar MA et al (2018) Long-term results of cataract surgery in patients with anterior uveitis. Int Ophthalmol 38:1399–1407
2. Barza M, Kane A, Baum J (1979) Marked differences between pigmented and albino rabbits in the concentration of clindamycin in iris and choroid-retina. J Infect Dis 139:203–208
3. Cai J, Qi L, Chen Y et al (2020) Evaluation of factors for predicting risk of uveitis recurrence in Behcet's disease patients. Braz J Med Biol Res 53:e9118
4. Chiu H, Dang H, Cheung C et al (2017) Ten-year retrospective review of outcomes following phacoemulsification with intraocular lens implantation in patients with pre-existing uveitis. Can J Ophthalmol 52:175–180
5. Chu CJ, Dick AD, Johnston RL et al (2017) Cataract surgery in uveitis: a multicentre database study. Br J Ophthalmol 101:1132–1137
6. Dick AD, Tundia N, Sorg R et al (2016) Risk of Ocular Complications in Patients with Noninfectious Intermediate Uveitis, Posterior Uveitis, or Panuveitis. Ophthalmology 123:655–662
7. Duplechain A, Conrady CD, Patel BC et al (2021)Uveitis
8. Elgohary MA, Mccluskey PJ, Towler HM et al (2007) Outcome of phacoemulsification in patients with uveitis. Br J Ophthalmol 91:916–921
9. Gritz DC, Wong IG (2004) Incidence and prevalence of uveitis in Northern California; the Northern California Epidemiology of Uveitis Study. Ophthalmology 111:491–500. discussion 500
10. Harthan JS, Opitz DL, Fromstein SR et al (2016) Diagnosis and treatment of anterior uveitis: optometric management. Clin Optom (Auckl) 8:23–35
11. Heiligenhaus A, Walscheid K, Pleyer U (2018) [Cataracts in Uveitis]. Klin Monbl Augenheilkd 235:568–575
12. Llop SM, Papaliodis GN (2018) Cataract Surgery Complications in Uveitis Patients: A Review Article. Semin Ophthalmol 33:64–69
13. Mehta S, Linton MM, Kempen JH (2014) Outcomes of cataract surgery in patients with uveitis: a systematic review and meta-analysis. Am J Ophthalmol 158:676–692e677
14. O'connor GR (1983) Factors related to the initiation and recurrence of uveitis. XL Edward Jackson memorial lecture. Am J Ophthalmol 96:577–599

15. Prete M, Dammacco R, Fatone MC et al (2016) Autoimmune uveitis: clinical, pathogenetic, and therapeutic features. Clin Exp Med 16:125–136
16. Prete M, Guerriero S, Dammacco R et al (2014) Autoimmune uveitis: a retrospective analysis of 104 patients from a tertiary reference center. J Ophthalmic Inflamm Infect 4:17
17. Rahman I, Jones NP (2005) Long-term results of cataract extraction with intraocular lens implantation in patients with uveitis. Eye (Lond) 19:191–197
18. Rim TH, Kim SS, Ham DI et al (2018) Incidence and prevalence of uveitis in South Korea: a nationwide cohort study. Br J Ophthalmol 102:79–83
19. Rojas B, Foster CS (1996) Cataract surgery in patients with uveitis. Curr Opin Ophthalmol 7:11–16
20. Sheppard JD Jr, Nguyen QD, Usner DW et al (2012) Post-cataract outcomes in patients with noninfectious posterior uveitis treated with the fluocinolone acetonide intravitreal implant. Clin Ophthalmol 6:79–85
21. Simeonova GP, Krastev SZ, Simeonov RS (2016) Immunological and pathological investigations in equine experimental uveitis. Vet Res Commun 40:107–115
22. Singh K, Shrestha S, Manandhar A (2019) Outcome of cataract surgery in eyes with uveitis. Nepalese journal of ophthalmology: a biannual peer-reviewed academic journal of the Nepal Ophthalmic Society : NEPJOPH 11:152–157
23. Sng CC, Ang M, Barton K (2015) Uveitis and glaucoma: new insights in the pathogenesis and treatment. Prog Brain Res 221:243–269
24. Trivedi A, Katelaris C (2019) The use of biologic agents in the management of uveitis. Intern Med J 49:1352–1363
25. Tsirouki T, Dastiridou A, Symeonidis C et al (2018) A Focus on the Epidemiology of Uveitis. Ocul Immunol Inflamm 26:2–16
26. Wildner G, Diedrichs-Mohring M (2019) Resolution of uveitis. Semin Immunopathol 41:727–736
27. Yangzes S, Seth NG, Singh R et al (2019) Long-term outcomes of cataract surgery in children with uveitis. Indian J Ophthalmol 67:490–495
28. Yuan Z, Chen X, Yang W et al (2019) The anti-inflammatory effect of minocycline on endotoxin-induced uveitis and retinal inflammation in rats. Mol Vis 25:359–372
29. Zhang Y, Zhu X, He W et al (2017) Efficacy of cataract surgery in patients with uveitis: A STROBE-compliant article. Med (Baltim) 96:e7353

Figures

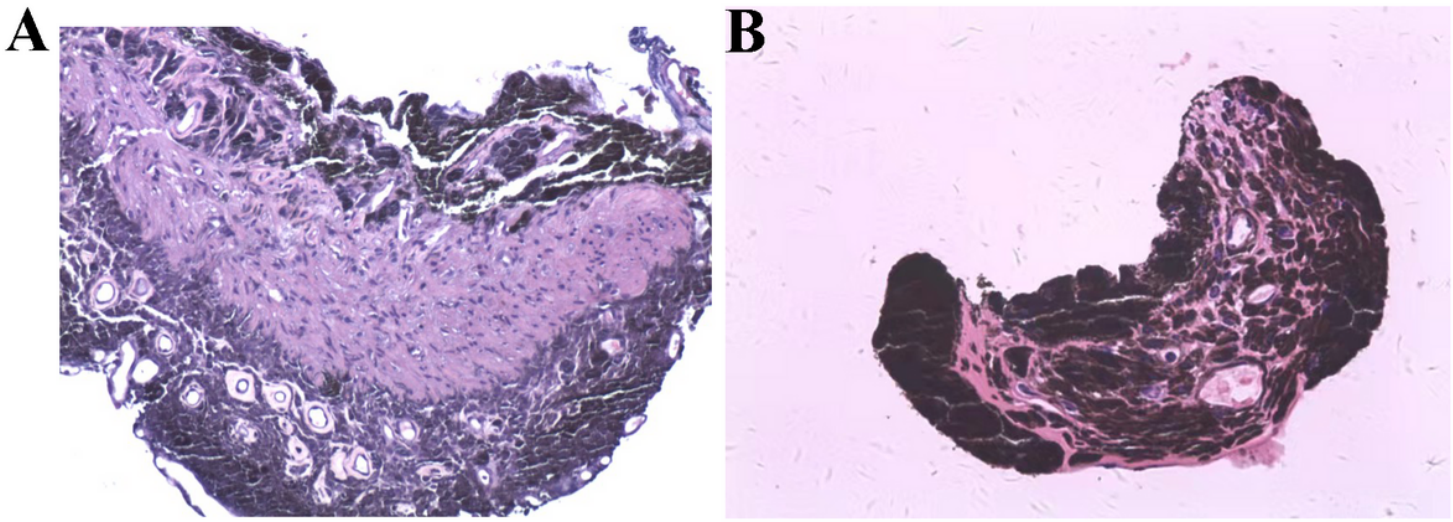

Figure 1

Hematoxylin and Eosin staining observation of the histopathological changes of iris tissues in two representative patients.