Comparison of the Effectiveness of Carotid Artery Endarterectomy and Carotid Endarterectomy + Patch Plasty in Preventing Restenosis and Stroke in Carotid Artery Occlusions.

Ziya Yıldız (ziyayildiz1976@gmail.com)
Erzurum Regional Training and Research Hospital

Taha Özkara
Erzurum Regional Training and Research Hospital

Research Article

Keywords: Stroke, Carotid Artery, Endarterectomy, Patch

Posted Date: December 29th, 2021

DOI: https://doi.org/10.21203/rs.3.rs-1164248/v1

Abstract

Background

Carotid artery stenosis is one of the most important causes of stroke, and atherosclerosis plays a role in one third of all strokes. It has been reported in some studies that the patency rate of carotid endarterectomies performed with patplasty is better than standard surgical treatment. In this retrospective study, we investigated vascular patency rates and strokes due to postoperative restenosis in patients who underwent classical carotid endarterctomy and patch plasty endarterctomy due to carotid artery stenosis.

We investigated 126 patients diagnosed with carotid artery occlusion between January 2015 and January 2021. We retrospectively analyzed and compared 44 patients who were operated on using carotid endarterectomy (CAE) with patch technique and 82 patients who underwent only carotid endarterectomy in terms of risk factors, restenosis and stroke. Color Doppler Ultrasonography (CDUS) and Computed Tomographic Angiography (CTA) were used in the diagnosis of carotid artery occlusions and the evaluation of restenosis.

Results:

The characteristics of the risk factors of the patients were examined and recorded. PTFE graft was used as a patch in patients. There were no significant complications during or after the operation. Restenosis and stroke were investigated at the 10th day, third month, sixth month, and first year after discharge, and mostly by imaging with CDUS. Restenosis was detected in one patient in the study group and in thirteen patients in the control group. Stroke was detected in none of the patients in the study group and in four patients in the control group.

Conclusion:

In our clinic, patch-based CAE is preferred to primary CAE due to its successful results and very low risk of restenosis. We think that CAE with the patch is a much more effective method in protecting patients from neurological pathologies.

Introduction

Carotid artery stenosis is one of the major causes of stroke. Atherosclerosis is involved in one-third of all stroke cases (1). Major neurological events such as stroke and death due to carotid artery atherosclerosis lead to serious socioeconomic consequences from a social perspective. Medical treatment alone is insufficient for patients with symptomatic and significant carotid artery stenosis. Invasive techniques are performed in the treatment of such patients. Carotid endarterectomy (CAE) and carotid artery stenting are two of these invasive techniques. Endovascular treatment of carotid artery stenosis is less invasive but is not superior to endarterectomy because of high rates of associated perioperative complications.

Therefore, CAE continues to be the gold standard intervention method in carotid artery occlusions (2). Some studies have reported that patency rates are better after CAE performed by patch angioplasty compared to standard surgical methods (3). CAE is recommended for patients with severe carotid artery stenosis when there are no contraindications considering the carotid artery lesion; when the patient's life expectancy is more than five years, and when complication rates of the respective centre to perform the intervention is low. In our clinic, carotid artery diseases have been treated with traditional surgical methods and patch technique for many years. In recent years, we have increasingly preferred CAE with patch technique in carotid artery occlusions because of the high patency rates we have found in such patients. In this retrospective study; we investigated and compared the frequency of restenosis and stroke during the follow-up period in patients who underwent patch graft angioplasty CAE and classical CAE due to carotid artery stenosis.

Methods

Patients and procedures:

The data of the study were obtained by searching retrospective patient files and hospital data with the permission of the ethics committee.

Between January 2015 and January 2021 we retrospectively investigated 44 patients who were operated on using the CAE and patch technique with carotid artery occlusion with full file information and 82 patients who underwent CAE only. Patients with a previous stroke were not included in this study. The patients were investigated in two groups and then the findings were compared between the groups. Color Doppler Ultrasonography (CDUS) and Computed tomographic angiography (CTA) were used in the diagnosis of carotid artery occlusions and the evaluation of restenosis. CTA was requested before the operation for possible difficult access and surgical planning for the surgical intervention. Preoperative coronary angiography was performed to exclude possible concomitant coronary artery disease and the presence of concomitant coronary artery disease. Patients who had an operation decision for coronary artery disease were not included in the study. Surgical procedures were performed under general anesthesia. Intraoperative shunt was used in ten patients. Systemic heparinization was not neutralized after operation. Intraoperative bleeding, new acute ischemic stroke, death etc. important findings were evaluated and recorded. Postoperatively the patients were followed up and treated in the cardiovascular surgery intensive care unit. Drainage follow-ups and neurological first examinations after extubation were routinely performed. Data on patient characteristics, stroke, mortality, restenosis and other surgical complications, and preoperative atherosclerotic risk factors were obtained from hospital records.

Definitions:

Stroke was defined as a clinical syndrome characterized by rapid settlement of signs and symptoms of focal loss of cerebral function for no apparent reason other than vascular causes. Preoperative carotid

artery stenosis was defined as 70% or more occlusion according to the vessel lumen in CTA and CDUS. Postoperative restenosis was defined as more than 50% lumen occlusion in the endarterectomy area in CTA and CDUS. Symptomatic carotid artery disease was defined amaurosis fugax (temporary vision loss after temporary ischemia), dysphasia, facial shift, extremity weakness, etc. due to carotid artery occlusion. Cerebral hyperperfusion syndrome was defined as severe headache, hypertension, seizures and focal neurological deficits after carotid artery stenting or endarterectomy.

Abbreviations, acronyms, symbols:

CAE; Carotid endarterectomy , CDUS; Color Doppler Ultrasonography, CTA; Computed Tomographic Angiography, PTFE; Polytetrafluoroethylene, LDL; Low-Density lipoprotein , HT; Hypertension , DM; Diabetus Mellitus , NASCET; North America Symptomatic Carotid Endarterectomy Trial ,ECST; European Carotid Surgery Trial , ICA; Internal Carotid Artery , ESVS; European Society for Vascular Surgery.

Patient Follow-up:

Presence of restenosis and stroke was investigated on the 10th day, 3rd month, 6th month and 1st year after discharge, or in the presence of patient complaints, mostly by imaging with CDUS and CTA and by examinations.

Surgical technique:

General anaesthesia was used in all of the patients. Antibiotics were administered intravenously at the time of induction as a routine procedure. The carotid artery was accessed through the incision along the anterior border of the sternocleidomastoid muscle. The hypoglossal nerve, the vagus nerve, and the ansa cervicalis were protected. Carotid arteries were found, everted, and suspended. Before clamping, unfractionated heparin at a dose of 5000 IU/ml was administered intravenously as a routine procedure and the vessel was opened by making a longitudinal incision. The atherosclerotic plaque was removed and fixation sutures were made for proximal and distal plaques when necessary. A biological or synthetic (Polytetrafluoroethylene: PTFE) patch was placed to prevent restenosis. After bleeding control; The drain was placed, the tissue layers were duly closed and the operation was terminated.

Limitations of the Research:

The most important limitation is that it is a single-center study.

Statistical analysis:

Statistical analysis was performed using IBM SPSS version 20.0 (IBM Corp., Armonk, NY, USA). Descriptive data were expressed as mean ± standard deviation (SD), median (min-max), or number and frequency. Group comparisons of numerical data were made with the Mann-Whitney U test and group comparisons of categorical data were made with the chi-square test. A two-way p value of less than 0.05 was considered a statistically significant difference.

Results

Working group:

Demographics and Treatment:

Thirty-two of the patients (n:44) were male (n:32 72.7%), and twelve (n:12 27.3%) were female. Mean age of male patients was 58.5±5.5 years (48-68), mean age of female patients was 64.5±3.3 years (60-68), mean age of all patients was 60.1±4.9 years (48- 66) was found. The surgically treated lesions were unilateral in all patients and were on the left in five patients (n:5 11%) and on the right side in thirty-nine patients (n:39 89%). Symptomatic carotid artery disease findings were detected in seven patients (n:7 15.9%), while the other patients were recorded as asymptomatic (n:37 84.1%). PTFE synthetic graft was preferred for patching in all patients.

When cardiac risk factors are examined; presence of atrial fibrillation was detected in only one (n:1 2.2%) patient. Congestive heart failure was not present in any of our patients.

When peripheral artery disease risk factors are investigated;

1-Smoking history; While it was absent in female patients (n:0), it was present in twenty-five (n:25 78.1%) male patients, and in total 56.8% of patients in the study group.

2-Low-density lipoprotein (LDL) value of the patients: 162.16±40.3 mg/dl (110-256)

3-Hypertension (HT); were present in twenty patients (n:20 45.4%)

4-Diabetus Mellitus (DM); was present in twelve patients (n:12 27.2%).

Follow-up:

All patients were admitted to the cardiovascular intensive care unit after the operation. The cross-clamp time of the patients during the operation was calculated as 24.63±5.1 minutes (18- 45). In only three of the patients (n:3 6.8%), shunt was used during the operation. After the operation, ten (n:10 22.7%) of the patients had drainage from the drain system during the intensive care follow-up, and the mean drainage was 10.8±18.5cc (0-75cc), and the drains were removed 2 days after the operation when the drainage did

not continue. Two patients (n:2 4.5%) had bleeding from the skin in the form of oozing at the wound site and the bleeding was stopped with a suture placed on the skin. No patient underwent revision (n:0).

Neurological examinations of the patients were performed after extubation; Facial slippage was detected in three patients (n:3 6.8%) and it was recorded that it disappeared spontaneously before the patient was discharged. The length of stay of the patients in the intensive care unit was recorded as 1.5±0.65 days (1-3 days) and the hospitalization period as 3.58±0.82 days (3-6 days). Hyperperfusion Syndrome, visual impairment due to retinal artery stenosis, and acute myocardial infarction in the postoperative period were not observed in any of the patients. No death or stroke was detected in any of the patients. Restenosis was investigated by imaging mostly with CDUS and CTA at day 10, third month, sixth month, and first year after discharge. At the end of the first year, restenosis was detected in a total of one patient (n: 2.2%), while stroke was not detected in any patient.

Control Group:

Demographics and Treatment:

Fifty-eight of the patients (n:82) were male (n:58 70.7%) and twenty-four (n:24 29.3%) were female. Mean age of male patients was 60.5±6.1 years (50-70), mean age of female patients was 65.2±3.6 years (58-70) and mean age of all patients was 61.8±5.3 years (50- 68) was found. The surgically treated lesions were unilateral in all patients and were on the left in fourteen patients (n:14 17%) and on the right side in 68 patients (n:68 83%). Twenty patients were registered as symptomatic (n:20 24.3%), and 62 patients were registered as asymptomatic (n:62 75.7%).

When cardiac risk factors are examined; presence of atrial fibrillation was detected in four (n:4 4.8%) patient. Congestive heart failure was not present in any of our patients.

When peripheral artery disease risk factors are investigated;

1-Smoking history; It was found in six (n:6 25%) female patients, thirty (n:30 51.7%) male patients, and 43.9% of the control group patients in totaly.

2-Low-density lipoprotein (LDL) value of the patients: 172.6±50.4 mg/dl (108-286)

3- Hypertension (HT); were present in twenty-eight patients (n:28 34.1%)

4-Diabetus Mellitus (DM); was present in nineteen patients (n:19 23.1%).

Follow-up:

All patients were admitted to the cardiovascular intensive care unit after the operation. The cross-clamp time of the patients during the operation was calculated as 20.5±4 minutes (15-36). Only seven of the patients (n:7 8.5%) had a shunt during the operation. Fourteen of the patients (n:14 17%) after the operation had drainage from the drain system during the intensive care follow-up, and the mean drainage was 9.2±12.8 (0-50cc), and the drains were removed 2 days after the operation when the drainage did not continue. Six patients (n:6 7.3%) had a small hematoma at the wound site, which was self-limiting and did not undergo surgical intervention and subsequently resorbed spontaneously. No patient underwent revision (n:0). Neurological examinations of the patients were performed after extubation; Facial slippage was detected in seven patients (n:7 8.5%) and it was recorded that it disappeared spontaneously before the patient was discharged. Mild redness occurred at the wound site in three patients (n:3.12.5%). The length of stay of the patients in the intensive care unit was recorded as 1.8±0.8 days (1-3 days) and the hospitalization times as 3.8±0.9 days (3-6 days). Hyperperfusion Syndrome was found in three patients (n:3 3.6%). In the postoperative period, retinal artery stenosis, acute myocardial infarction, death were not detected in the patients.

Restenosis was investigated by imaging mostly with CDUS and CTA at day 10, third month, sixth month, and first year after discharge. In the control examinations, two patients (n:2 2.5%) at the third month, five patients (n:5 6%) at the sixth month and six patients (n:6 7.3%) at the end of the first year, total (n:13). 15.8% restenosis was detected and recorded. Necessary treatments were applied to these patients. Postoperative stroke was detected in three patients (n:3 3.6%) who developed restenosis. Stroke after restenosis was detected in one patient in the third month, in one patient in the sixth month and in one patient in the first year.

Comparison of Groups:

When the groups were compared, it was seen that the patients were similar in terms of age, gender, location of carotid artery occlusion, presence of symptomatic carotid artery disease, duration of intensive care unit and hospital stay, postoperative complications and peripheral artery disease risk factors in terms of cross-clamp times during the operation. The most common peripheral artery risk factors in both the study group and the control group were smoking history and hypertension. Differently, three patients in the control group had Hyperperfusion Syndrome. Restenosis was found in only one of the patients in the study group (n:1 2.2%) and in thirteen (n:13 15.8%) patients in the control group. Stroke was not detected in any of the patients in the study group but stroke was detected in three of the thirteen patients who developed restenosis in the control group.

Demographic data and statistical comparison of the groups are shown in Table 1. The preoperative CTA image of one of our patients is shown in Image 1, the images of the operative endarterectomy and patch plasty with PTFA patch are shown in Image 2, and the CTA image of the same patient after discharge is shown in Image 3. Patients' intraoperative and postoperative findings shown in Table 2.

Table-1

Demographic data and findings of patients.

Characteristics of Patients	Study Group (n %)	Control Group (n %)	p
Gender			
Male	32 (%72,7)	58 (%70,7)	0,712
Female	12 (%17,3)	24 (%19,3)	0,695
Total	44	82	
Age (year)			
Average	60,1±4,9	61,8±5,3	0,747
Interval	48-66	50-68	0,782
Side			
Right	39 (%89)	68 (%83)	0,645
Left	5 (%11)	14 (%17)	0,680
Symptomatic	7 (%15,9)	20 (%24,3)	0,611
Asymptomatic	37 (%84,1)	62 (%75,7)	0,582
LDL (mg/dl)	162,16±40,3	172,6±50,4	0,772
Smoking	25 (%56,8)	36 (%43,9)	<0.05
Hypertension	20 (%45,4)	28 (%34,1)	<0.05
Diabetes Mellitus	12 (%27,2)	19 (%23,1)	0,632
Atrial Fibrillation	1 (%2.2)	4 (%4.8)	0,525
Congestive Heart Failure	0	0	
Previous stroke	0	0	

Table-2

Patients' intraoperative and postoperative findings.

Results	Study Group (n %)	Control Group (n %)	p
Cross Clamp Time (minutes))	24.63±5.1	20.5±4	0,710
Using Shunt	3 (%6,8)	7 (%8,5)	0,756
Akut Miyokard Enfarktüsü	0	0	
Intensive Care Hospitalization (days)	1,5±0,65	1,8±0,8	0,664
Length of Hospitalization (days)	3,58±0,82	3,8±0,9	0,692
Drainage Amount (cc)	10,8±18,5cc	9,2±12,8	0,742
Facial Paralysis	3 (%6,8)	7 (%8,5)	0,645
Reoperation	0	0	
Bleeding-Hematoma	2 (%4,5)	6 (7,3)	0,582
Visual Impairment	0	0	
Hyperperfusion Syndrome	0	3 (%3,6)	
Death	0	0	
Stroke (Post Operation):	0	3	
3 months/6 months/1 year	0	1(%1.2) / 1(%1.2) / 1(%1.2)	
Imaging Restenosis:			
10th day/3 months/ 6 months/1 year	0/0/0/1 (%2,2)	0/2 (%2,5)/5 (%6)/6 (%7,3)	
Restenosis (within 1 year)	1 (%2,2)	13 (%15,8)	<0.05
Openness (within first 1 year)	43 (%97,8)	69 (%84,2)	<0.05

Discussion

Carotid artery stenosis is an important health problem with major neurological complications such as stroke and death. We compared the patient groups who underwent endarterectomy and endarterectomy +patch plasty due to carotid artery occlusion and the effectiveness of these treatments in preventing stroke. When our study is examined, it is seen that the groups are similar with many risk factors. Demographic characteristics of the patients; complaints, peripheral risk factors, operation methods, cross-clamp times, average length of stay in the intensive care unit and hospital are very close to each other. The significant difference detected between the groups were in the frequency of vascular restenosis as a result of the surgical intervention. In the control radiological imaging examinations of the patients who underwent endarterectomy + patch plasty, restenosis was detected in a total of one patient in the

study group, while restenosis was detected in thirteen patients in the control group at different periods in one year. While restenosis developed in one patient in the study group, stroke did not occur in this patient. In the control group, restenosis developed in thirteen patients and stroke occurred in three patients. Carotid patch plasty reduced the frequency of restenosis after the operation and prevented possible strokes in the patients. This difference is statistically significant. It should not be forgotten that many personal factors are important in restenosis after the operation. In recent years the frequency of intervention with endarterectomy + patch plasty for carotid artery occlusions has been increasing. For this reason, many publications have reported that better results are obtained with endarterectomy + patch plasty in carotid artery opening, the frequency of restenosis is less and protecting patients are better against stroke. We support the accuracy of this information with the results we obtained in our own clinic and we don't prefer only endarterectomy in carotid artery occlusions at surgical treatment.

Carotid artery stenosis is associated with major neurological complications such as stroke and death. Since De Bakey performed the first thromboendarterectomy in 1953, CAE has been recognized as a safe and effective method that reduces the risk of stroke in patients with severe stenosis in the internal carotid artery (4). Two studies; North America Symptomatic Carotid Endarterectomy Trial (NASCET) and European Carotid Surgery Trial (ECST), have shown that CEA is superior to medical treatment in preventing stroke in symptomatic internal carotid artery (ICA) stenosis of more than 70%. Several multi-centre studies have shown that CAE is the most effective treatment method to prevent cerebrovascular events in patients with carotid artery stenosis (5).In recent studies on symptomatic patients, optimal medical treatment is recommended rather than revascularization in the presence of carotid stenosis of less than 50% but CAE followed by optimal medical treatment is recommended in patients with stenoses of 50% or more (6). Similarly; according to the recommendations of the European Society for Vascular Surgery (ESVS) guidelines, CAE is certainly recommended for symptomatic patients with stenoses of more than 70% and strongly recommended for symptomatic patients with stenoses of more than 50%. In a study, the frequency of restenosis was investigated in long-term follow-up and it was reported that the 5-year and 10-year restenosis rates were > 70% after CEA with primary closure (7).In a Cochrane review examining the results of CAE with primary closure and CAE with patch angioplasty, it was reported that the use of patches reduced rates of restenosis and neurological events in the follow-up period (8). It has been suggested in the literature that; compared to primary closure, CEA with patch angioplasty may reduce the combined risk of stroke and restenosis in the perioperative period in long-term (9). In a metaanalysis study by Paraskevas et al, perioperative outcomes and late stenosis rates (> 50%) of CEA with eversion and CEA with patch angioplasty were reported as superior to primary CEA (10). In a thesis study from our country comparing CAE with primary closure to CAE with patch angioplasty on 45 patients with carotid artery occlusions, it was reported that restenosis occurred less after CEA with patch angioplasty compared to CEA with primary surgery (11). In the meta-analysis performed by Lazarides et al.; where closure techniques for CAE were evaluated, it was reported that both short-term and late-term adverse outcomes following CEA with patch closure were lower and that CEA with patch closure represented the best option compared to other CEA closure techniques (12).

Any intervention on carotid arteries is associated with risks. The way to prevent such risks is to perform the procedure in experienced hands using surgical techniques attentively and carefully. CAE operations under general anaesthesia have been performed in our clinic for a long time. The review of our patients revealed that patients had atherosclerotic risk factors. There is no consensus on the use of intravascular shunts in carotid endarterectomy operations. Some surgeons use shunts in all patients; some surgeons never use shunts, and some surgeons use shunts selectively (13). We did not use shunts in our patients in the operations because it has been reported that the shunt placement procedure may cause a distal embolism, endothelial injury in the distal vascular bed, and shunt thrombosis (14).

Furthermore, we did not use shunts because we determined sufficient retrograde flow in the non-occluded contralateral carotid arteries on the CTA images of the patients. The cross-clamping times of the patients were reasonable. Mobilization of the patients was achieved on the first postoperative day. The length of hospitalization of the patients was very short. From the first postoperative day until the hospital discharge, low molecular weight heparin was given to all patients according to body weight. All patients took 100 mg acetylsalicylic acid, 75 mg clopidogrel, and 20 mg atorvastatin for at least 6 months after the hospital discharge. No permanent complications developed after the operation. Full patency was observed in all patients during the first year after the CAE surgery with patch angioplasty. Our patients were instructed to comply with the medical treatment and not to smoke after the hospital discharge. In the study performed by Garzon-Muvdi et al., it was reported that smoking, hyperlipidemia, and the presence of stroke in the family history were associated with the increased risk of restenosis (15).

CAE with patch angioplasty has increasingly become the preferred technique over primary CAE in many clinics. In CAE with patch angioplasty, the occluded part of the carotid artery is opened and the vessel lumen is widened. Thus, the risk of restenosis is reduced. We think that CAE with patch angioplasty is necessary to avoid restenosis that could potentially be caused by the surgery itself performed to eliminate the carotid artery stenosis. In our study, we found that outcomes for early patency rates were very good. We think that studies investigating long-term outcomes will report similar results. We believe that CAE with patch angioplasty is an effective treatment method in protecting the patient and preventing restenosis

Conclusions

CEA with patch angioplasty has recently become increasingly used for the treatment of carotid artery occlusions. It is an easy surgical method with short operative times and associated with short hospital stays. In short term, patency rates are high and restenosis rates are low. There are increasing numbers of papers reporting that long-term patency rates are favourable, too. CAE with patch angioplasty is preferred over primary CAE in our clinic based on the success of outcomes and the low restenosis risk. We think that CAE with patch angioplasty is effective in protecting patients from neurological pathologies.

Declarations

Scientific Consent:

Scientific permission was obtained from the ethics committee of our hospital with registration number E-37732058-514.10 and registration number 2021 / 05-104. In studies conducted with the permission of the ethics committee in our country, the data of the patients are obtained from patient files and hospital data. In such retrospective studies oral or written consent from the patients is not required. The research was conducted in accordance with the Declaration of Helsinki, which covers human, human substance (cell lines, tissues, or other biological samples) or human data (including retrospective studies).

Consent for publication:

Not Applicable.

Availability of data and material

The datasets generated and/or analysed during the current study are not publicly available due [The data were searched retrospectively from the hospital data bank with the permission of the ethics committee of our hospital and are not open to public access.] but are available from the corresponding author on reasonable request.

Competing interests

None of the authors has any real or potential conflicts of interest to disclose.

Funding

No funding was obtained for this study.

Authors contributions:

All authors have read and approved the manuscript.

Design of the work, the acquisition, analysis, interpretation of data, the creation of new software used in the work, have drafted the work: ZY. Substantively revised it: TO

References

1. Liapis CD, Bell PR, Mikhailidis D, Sivenius J, Nicolaides A, Fernandes e Fernandes J, et al. ESVS guidelines. Invasive treatment for carotid stenosis: indications, techniques. Eur J Vasc Endovasc

Surg 2009;37(4 Suppl):1–19.

2. Radak D, Ilijevski N, Djukic N. Carotid surgery today: An update after 14,000 carotid endarterectomy procedures. Vojnosanit Pregl. 2016;73(5):472–79
3. Paraskevas KI, Robertson V, Saratzis AN, Naylor AR: Editor's choice - an updated systematic review and meta-analysis of outcomes following Eversion vs. conventional carotid endarterectomy in randomised controlled trials and observational studies. Eur J Vasc Endovasc Surg 55: 465–473, 2018
4. Maharaj R. A review of recent developments in the management of carotid artery stenosis. J Cardiothorac Vasc Anesth 2008;22:277–89
5. Halliday A, Mansfield A, Marro J, Peto C, Peto R, Potter J, et al. Prevention of disabling and fatal strokes by successful carotid endarterectomy in patients without recent neurological symptoms: randomised controlled trial. Lancet 2004; 363:1491–502
6. Hıdıroğlu, Mete, et al. "Karotis arter hastalıklarında karotis endarterektomi erken sonuçları." *Turk Gogus Kalp Dama* 18 (2010): 190–5.
7. Lamba N, Zenonos GA, Igami Nakassa AC, Du R, Friedlander RM: Long-term outcomes after carotid endarterectomy: the experience of an average-volume surgeon. World Neurosurg 118: e52–e58, 2018
8. Akay OT. Periferik Arter ve Ven Hastalıkları-Ulusal Tedavi Kılavuzu. In: Bozkurt AK, editor. Karotis arter dalıkları. 1. Baskı. İstanbul: Bayçınar Tıbbi Yayıncılık; 2016. s. 85-105
9. Malas M, Glebova NO, Hughes SE, et al.: Effect of patching on reducing restenosis in the carotid revascularization endarterectomy versus stenting trial. Stroke 46: 757–761, 2015
10. Paraskevas KI, Robertson V, Saratzis AN, Naylor AR: Editor's choice - an updated systematic review and meta-analysis of outcomes following Eversion vs. conventional carotid endarterectomy in randomised controlled trials and observational studies. Eur J Vasc Endovasc Surg 55: 465–473, 2018
11. Durna, Fırat. "Karotis endarterektomi yapılan hastalarda primer tamir ile patch plastinin orta dönem sonuçları." Tez (2014).
12. Lazarides, Miltos K., et al. "Network meta-analysis of carotid endarterectomy closure techniques." European Journal of Vascular and Endovascular Surgery (2020).
13. Woodworth GF, McGirt MJ, Than KD, et al. Selective versus routine intraoperative shunting during carotid endarterectomy: a multivariate outcome analysis. Neurosurgery 2007;61:1170–7.
14. Beyazpınar, Deniz Sarp, et al. "Our treatment strategies of carotid artery restenoses." Turkish Journal of Vascular Surgery 27.2 (2018).
15. Garzon-Muvdi T, Yang W, Rong X, et al.: Restenosis after carotid endarterectomy: insight into risk factors and modification of postoperative management. World Neurosurg 89: 159–167, 2016

Figures

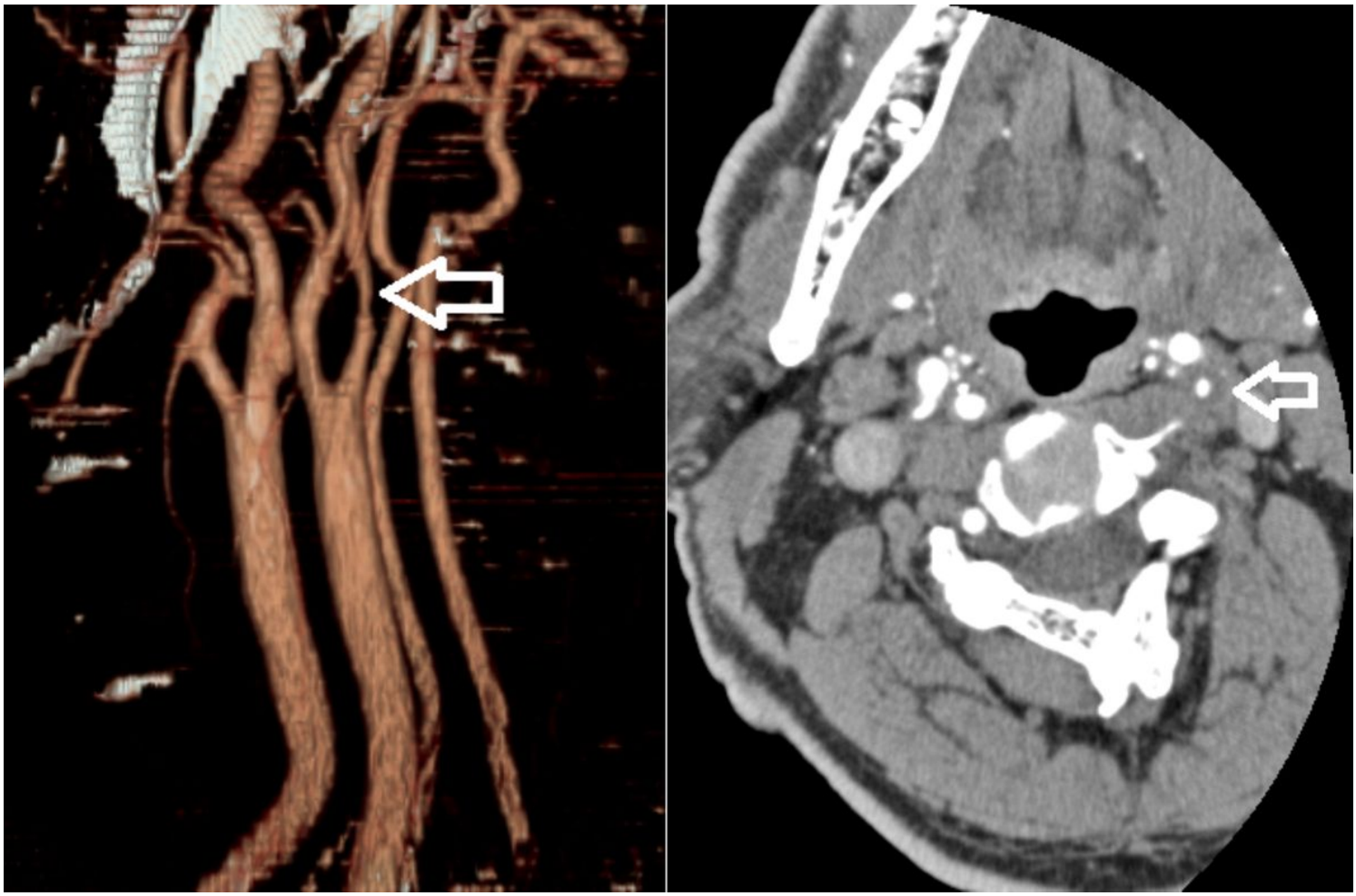

Figure 1

Preoperative Computed Tomographic Angiography image of one of our patients (Arrow shows the occluded vessel area).

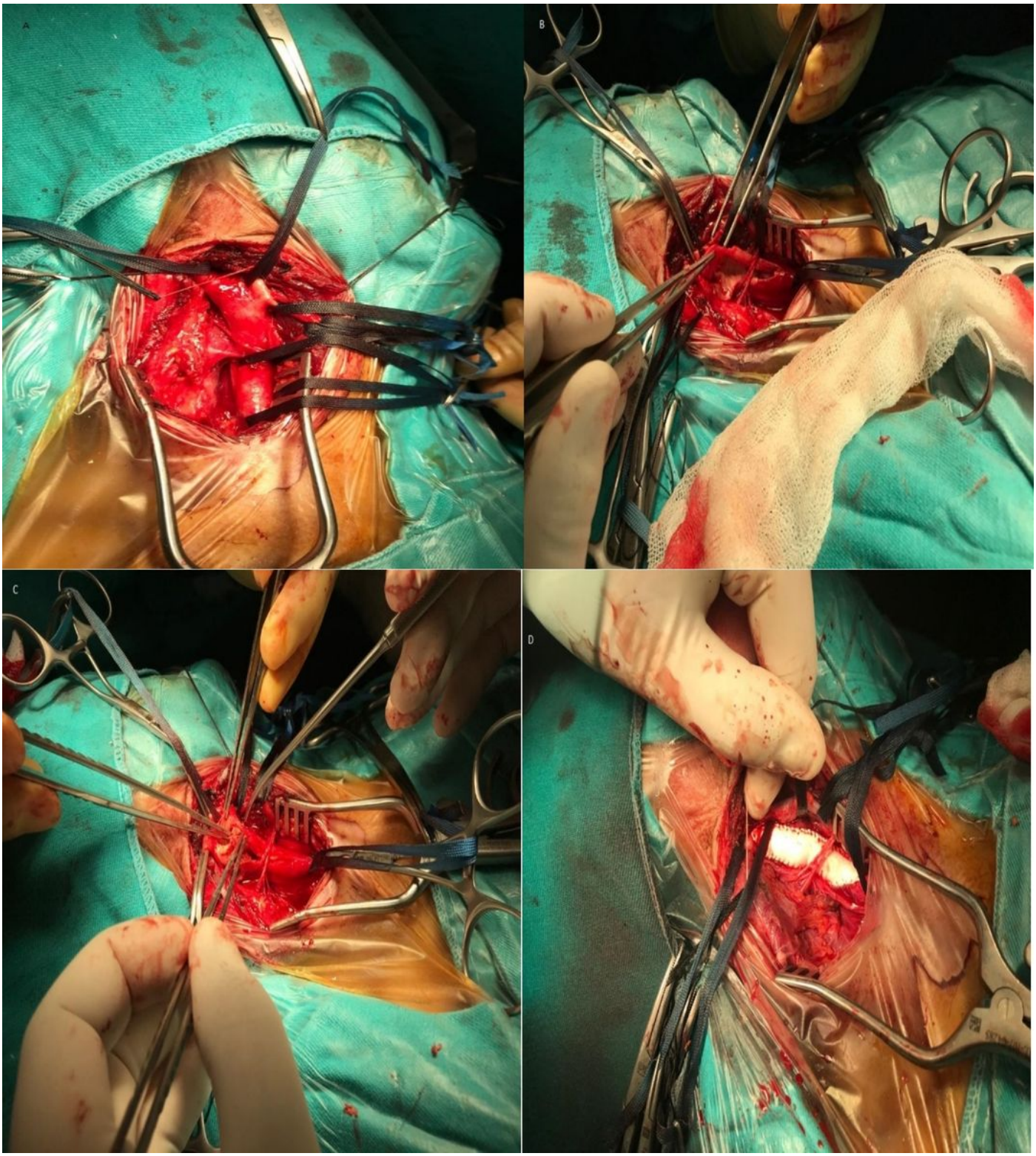

Figure 2

Images of the operation of one of our patients. A) Exploration of the carotid arteries. B) The incision made along the obstruction and the appearance of the atherosclerotic plaque. C) Removal of atherosclerotic plaque. D) Completing the repair with a PTFE patch and opening the cross clamps

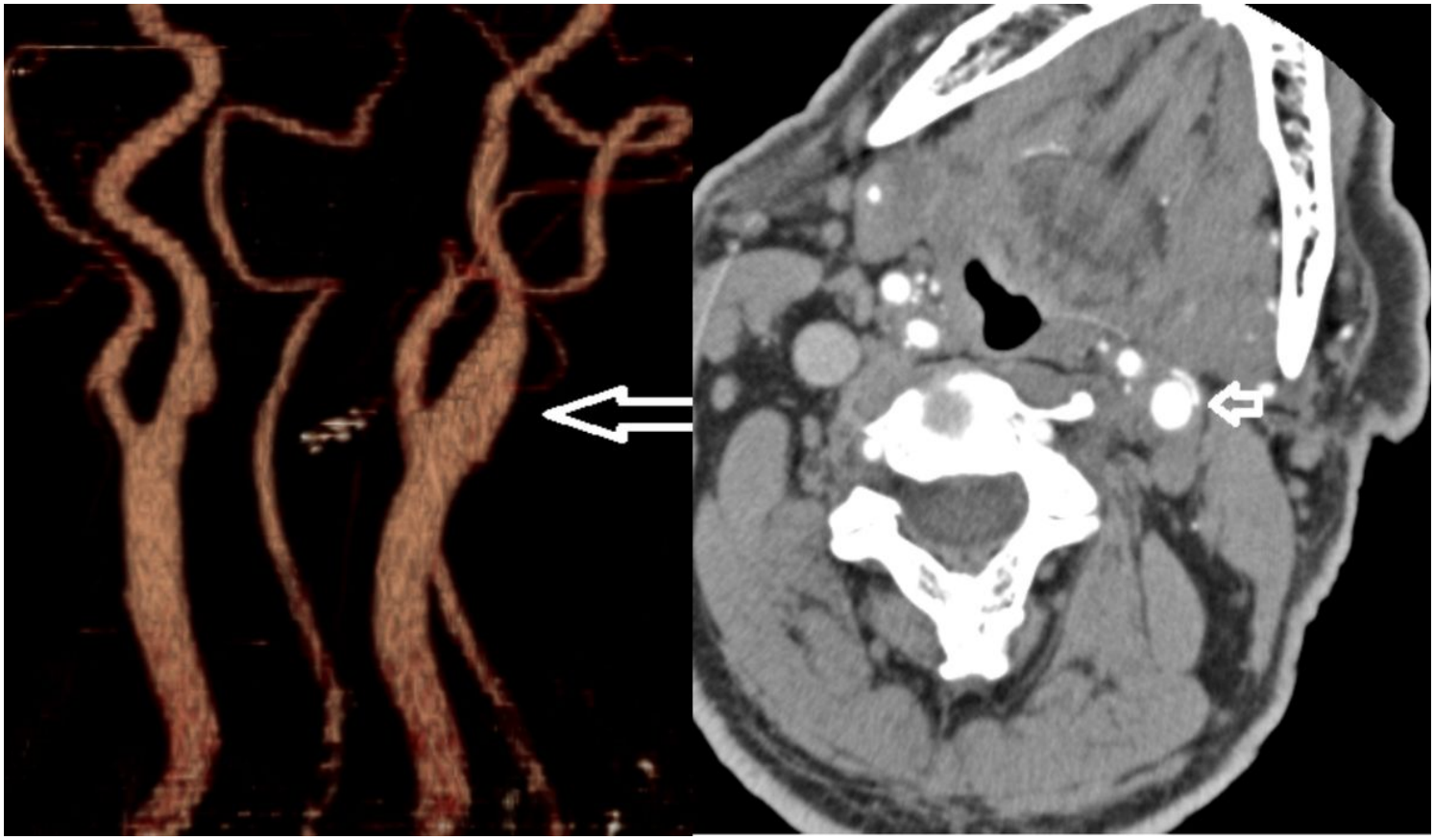

Figure 3

Computed Tomographic Angiography image of one of our patients after discharge (Arrow shows enlargement in the vascular area and PTFE graft after endarterectomy with patch).