The relationship of the type of intracerebral haemorrhage to early disease evolution and long-term prognosis after r-tPA thrombolysis

yungang cao
The Second Affiliated Hospital and Yuying Children's Hospital of Wenzhou Medical University
Hongfei Jing
Zhuozhou City Hospital
Xianda Lin
The Second Affiliated Hospital and Yuying Children's Hospital of wenzhou Medical University
Jueyue Yan
The Second Affiliated Hospital and Yuying Children's Hospital of Wenzhou Medical University
Zheng Zhang
First Affiliated Hospital of Wenzhou Medical University
Zusen Ye
First Affiliated Hospital of Wenzhou Medical University
Xiaoyan Huang
The Second Affiliated Hospital and Yuying Children's Hospital of Wenzhou Medical University
Zicheng Cheng
The Second Affiliated Hospital and Yuying Children's Hospital of Wenzhou Medcal University
Zhao Han (wzhanzhao@aliyun.com)
https://orcid.org/0000-0002-0901-9870

Research article

Keywords: Intracerebral haemorrhage; Thrombolysis; Cerebral infarction; Tissue plasminogen activator

Posted Date: June 3rd, 2019

DOI: https://doi.org/10.21203/rs.2.10048/v1

Abstract

Background: To investigate the relationship of different subtypes of intracerebral haemorrhage (ICH) to early disease evolution and long-term prognosis in patients with acute cerebral infarction after intravenous recombinant tissue plasminogen activator(r-tPA). Methods: Seventy ischaemic stroke patients treated with intravenous t-PA who underwent computed tomography (CT) within 24 hours after thrombolysis were divided into four types (haemorrhagic infarction type 1 [HI-1], HI-2, parenchymal haemorrhage type 1 [PH-1], or PH-2). Early evolution of the disease was observed by the change in the National Institutes of Health Stroke Scale (NIHSS) score within 24 hours after thrombolysis. The long-term prognosis was assessed by the modified Rankin Scale (mRS) score at the 3rd month. Results: There were 17 (24.3%) patients with ICH. Compared with patients in the non-ICH group, HI did not affect early neurological function or clinical outcome at the 3rd month. PH-1 did not increase the risk of early neurological deterioration; however, PH-1 could increase the risk of death at the 3rd month (50% vs 11.3%, P = 0.090). PH-2 was significantly related to early neurological deterioration (66.7% vs 3.8%, P <0.001) and mortality at the 3rd month (50.0% vs 11.3%, P = 0.040). Conclusion: Patients with different subtypes of ICH after thrombolysis have different clinical outcomes. PH-2 is significantly associated with early neurological deterioration and increases mortality at the 3rd month.

Background

Intracerebral haemorrhage (ICH) is one of the most common and severe complications of intravenous thrombolysis with recombinant tissue plasminogen activator (r-tPA)[1]. In particular, symptomatic ICH (sICH) may aggravate the injury to the brain tissue and is proven to be associated with poor clinical outcomes[2]. Therefore, correctly assessing early disease evolution and long-term prognosis of patients with ICH after thrombolysis is a major concern for clinicians. A previous study reported that subtypes of post-thrombolytic ICH were related to the clinical outcomes of patients with acute cerebral infarction after intravenous r-tPA thrombolysis[3]. Classifying the subtypes of post-thrombolytic ICH that can contribute to clinical outcomes after thrombolysis and the management of ICH is necessary. To date, few large sample studies have been conducted to analyse the occurrence of ICH after intravenous r-tPA in China. The purpose of our study was to review patients treated with r-tPA for acute ischaemic stroke and to investigate the relationship of different subtypes of ICH after thrombolysis to early disease evolution and long-term prognosis.

Methods

Subjects

We collected 70 acute ischaemic stroke patients who were treated with intravenous tPA at the Second Affiliated Hospital of Wenzhou Medical University and the First Affiliated Hospital of Wenzhou Medical University between December 2007 and February 2015. Seventeen of 70 patients received thrombolysis between 4.5 and 9 hours after stroke onset on the basis of multimodal imaging. The inclusion and

exclusion criteria for intravenous thrombolysis within 4.5 hours of onset were those proposed by guidelines from the American Heart Association/American Stroke Association[4]. The clinical inclusion criteria for patients with onset times between 4.5 to 9 hours were the same as those of patients with onset times between 0 and 4.5 hours. The radiographic inclusion and exclusion criteria were based on multimodal imaging. The radiographic inclusion criteria were as follows: (1) computed tomography (CT) perfusion imaging showing the maximum diameter of the abnormal perfusion zone >2 cm; (2) CT perfusion imaging/CT angiography showing a mismatch area ≥20%; and (3) CT angiography showing a thrombolysis in cerebral infarction (TICI) grade[5] of 0 or 1 (large vessel occlusion or severe stenosis). The radiographic exclusion criteria were as follows: (1) CT showing the presence of ICH or subarachnoid haemorrhage; (2) CT angiography showing an abnormal range of >1/3 of the middle cerebral artery supply range; (3) CT perfusion imaging showing no abnormal perfusion area; and (4) any contraindication for CT examination. This study was approved by the ethics committee of the hospital, and informed consent was obtained from all patients. Included patients received intravenous r-tPA (0.9 mg/kg; 10% bolus, remainder by infusion over 1 hour). During thrombolysis and 24 hours after thrombolysis, blood pressure was maintained below 180/105 mmHg. Antiplatelet or anticoagulant therapy was initiated only if the brain CT performed 24 hours after thrombolysis showed no ICH. If headache, confusion, or neurological worsening occurred during thrombolysis, the injection was ceased, and an emergent brain CT was performed. All patients or legally authorized representatives gave written informed consent before treatment.

Clinical Assessment

Any ICH detected by CT within 24 hours after injection was defined as post-thrombolytic ICH. In clinical practice, post-thrombolytic ICH includes symptomatic ICH and asymptomatic ICH. We defined sICH according to the definition provided by the National Institutes of Neurological Disorders (NINDS)[6] as any clinical suspicion of haemorrhage or any decline in neurological status. With respect to the radiological classification of post-thrombolytic ICH, we adopted the European Cooperative Acute Stroke Study II (ECASS II) criteria. Post-thrombolytic ICH was classified as haemorrhagic infarction (HI) or parenchymal haemorrhage (PH) according to the CT appearance. HI type 1 (HI-1) was defined as small petechiae along the margins of the infarct, and HI-2 was defined as confluent petechiae within the infarcted area without a space-occupying effect. PH type 1 (PH-1) was defined as blood clots in ≤30% of the infarcted area with a slight space-occupying effect, and PH-2 was defined as blood clots in >30% of the infarcted area with a mass space-occupying effect. CT scans were reviewed by a neuroradiologist with extensive experience in acute stroke who was blinded to the clinical details.

Outcome Measures

Early evolution of disease was evaluated by the change in the National Institutes of Health Stroke Scale (NIHSS) score within 24 hours after thrombolysis. Early neurological deterioration was defined as an increase of more than 4 points in the NIHSS score 24 hours after thrombolysis compared with the baseline.The long-term prognosis was assessed by the modified Rankin Scale (mRS) score at the 3rd

month. mRS scores of 0 to 2 were considered to indicate a favourable outcome, while scores of 6 indicated death.

Statistical Analysis

All statistical analyses were performed with SPSS software version 20 (IBM Corp, Armonk, NY). Continuous variables are described using the mean ± standard deviation and were analysed using Student's t-tests or Kruskal-Wallis tests. Categorical variables are described as percentages and were analysed using Pearson's chi-square or Fisher's exact tests. The NIHSS score was described using medians (ranges).

Results

Seventy patients with acute cerebral infarction who received intravenous r-tPA thrombolysis were included in our study. The baseline characteristics are shown in Table 1. There were 48 male patients (68.6%), the mean patient age was 65.44±10.37 years, and the median admission NIHSS score was 14 (4-34). Twenty-three (32.9%) patients were treated within the 3-hour time window, whereas 17 (24.3%) patients received thrombolysis >4.5 hours after stroke onset as determined by multimodal imaging. Seventeen (24.3%) patients developed ICH after intravenous r-tPA, and sICH occurred in 6 (8.6%) patients. According to the radiological criteria, there were 3 patients with HI-1 (4.3%), 4 patients with HI-2 (5.7%), 4 patients with PH-1 (5.7%) and 6 patients with PH-2 (8.6%). CT images from these patients are presented in Figure 1.Figure 2 shows changes in the NIHSS score at 24 hours according to the presence and type of post-thrombolytic ICH. There were significant differences among the 4 groups (P=0.002). Patients with PH-2 had a significant increase in NIHSS score at 24 hours (P=0.000, 0.014, 0.019), whereas patients with HI (HI-1 and HI-2), PH-1, or non-ICH showed unapparent changes. The mean ± standard deviation in the NIHSS score at 24 hours and the baseline scores of the four groups were as follows: non-ICH (-2.72±5.08), HI (0.57±8.08), PH-1 (-2.75±4.57), and PH-2 (11.67±11.59).Table 2 and Figure 3 illustrate the clinical outcomes of patients with different subtypes of post-thrombolytic ICH. HI and PH-1 were not associated with early deterioration of neurological function or the clinical prognosis as determined by the mRS score at the 3rd month. PH-2 significantly increased the risk of early neurological deterioration (66.7% vs 3.8%, P < 0.001) and death at 3 months (50% vs 11.3%, P=0.040).

Discussion

The incidence of ICH after intravenous r-tPA ranged from 10.6% to 48.4% in several large-sample, randomized, double-blind, placebo-controlled trials[6-9]. The incidence of ICH in our study was 23.4%, which is higher than that in the NINDS study (10.6%) but slightly lower than that in the ECASS III study (27%)[1]. In this study, we included patients who were treated between 0 and 9 hours of the onset of stroke symptoms, which may have increased the incidence of ICH. The mean time from onset to thrombolysis was 247.41±104.15 minutes, which is similar to that in the ECASS III study but much higher than that in the NINDS study[2]. The median admission NIHSS score was 14, which is consistent with

that of the NINDS study but higher than that of the ECASS III study[6, 9]. The incidence of sICH in our study was 8.7%, which is close to those in the NINDS and ECASS III studies (6.4% and 7.9%, respectively). The distribution of ICH subtypes occurring within the first 36 hours after intravenous r-tPA was as follows: HI-1 was identified in 3 patients (4.3%), HI-2 in 4 (5.7%), PH-1 in 4 (5.7%), and PH-2 in 6 (8.6%). The incidences of PH-1 and PH-2 were similar to those in the ECASS II study (3.7% and 8.1%, respectively), but the incidences of HI-1 and HI-2 were relatively lower (19.6% and 15.2%, respectively). This may be because we analysed ICH occurring within 36 hours after thrombolysis, while the ECASS II study included patients with ICH occurring within 7 days of intravenous thrombolysis[8].

We found that patients with different subtypes of ICH identified on images after thrombolysis had different clinical outcomes. There was no significant correlation between HI and early neurological deterioration or clinical prognosis at the 3rd month. This finding is in accordance with those of the ECASS I and ECASS II studies[7, 8]. Molina et al.[10] investigated the relationship between haemorrhagic transformation subtypes and thrombolytic efficacy in patients with proximal middle cerebral artery occlusion treated with intravenous r-tPA <3 hours after stroke onset. They suggested that HI represented a marker of early successful recanalization, leading to a reduced infarct size and improved clinical outcome. One pooled analysis[11] of six randomized placebo-controlled trials of intravenous r-tPA suggested that HI was not associated with r-tPA therapy. Overall, there is convincing evidence that HI occurs as part of the natural history of ischaemic stroke and is even a potential sign of vascular recanalization.

In contrast to HI, PH was closely related to clinical outcomes. In our study, PH-1 did not increase the risk of early neurological deterioration but showed a tendency to increase the risk of death at the 3rd month (50% vs 11.3%, P=0.090), although there was no statistically significant difference. This result indicated that a small haematoma may have a slight or no effect on clinical outcome. Moreover, we reported that in contrast to the outcomes of other subtypes of bleeding, PH-2 was significantly associated with early neurological deterioration and increased the risk of death at the 3rd month. Fiorelli et al.[7] also reported that PH-2 had a fatal impact on early neurological course after thrombolysis (odds ratio for deterioration, 32.3; 95% confidence interval (CI), 13.4 to 77.7) and on 3-month death (odds ratio, 18.0; 95% CI, 8.05 to 40.1). Similarly, Berger et al.[12] indicated that only PH-2 independently caused neurological deterioration and impaired prognosis compared with the absence of haemorrhagic transformation. This finding suggests that PH-2 is the only clinically relevant subtype of ICH after thrombolysis.

Conclusion

In conclusion, different subtypes of post-thrombolytic ICH were associated with diverse clinical prognoses. Only PH-2 was significantly associated with early neurological deterioration and increased mortality at the 3rd month. Therefore, patients with PH-2 should be monitored intensively, and active measures should be taken.

Abbreviations

ICH: intracerebral haemorrhage; r-tPA:recombinant tissue plasminogen activator; CT:computed tomography; HI-1:haemorrhagic infarction type 1;HI-2: haemorrhagic infarction type 2; PH-1: parenchymal haemorrhage type 1;PH-2: parenchymal haemorrhage type 2; NIHSS:the National Institutes of Health Stroke Scale score; mRS: the modified Rankin Scale; sICH:symptomatic ICH; TICI: thrombolysis in cerebral infarction; NINDS: the National Institutes of Neurological Disorders; ECASS: the European Cooperative Acute Stroke Study; HI:haemorrhagic infarction ; PH: parenchymal haemorrhage.

Declarations

Ethics approval and consent to participate

In this study each patient or their legal guardian provided a signed, informed consent to participate to the study. This consent was signed by the patient if possible, or by a third person in the presence of the full conscientious patient. These criteria were approved by the Second Affiliated Hospital of Wenzhou Medical University and the First Affiliated Hospital of Wenzhou Medical University ethics committee.

Consent for publication

Not applicable. This manuscript does not contain an individual person's data.

Availability of data and materials

The datasets used and/or analysed during the current study are available from the corresponding author on reasonable request.

Competing interests

The authors declare that they have no competing interests

Funding

This study was funded by the Wenzhou Municipal Sci-Tec Bureau Programs grant Y2004A014 and Clinical Scientific Research Fund of the Second Affiliated Hospital of Wenzhou Medical University (SAHoWMU-CR2017-01-212), the National Nature Science Foundation of China (Grant No. 81571114, 81771267). Those grant covered the staff fees, ie fees for evaluating investigators, research assistants and statistician. The funder had no influence on the study design, neither on writing the report nor on the decision to submit the report for publication.

Authors' contributions

YGC and ZH is the principal investigator of this study. YGC and HFJ drafted the manuscript. YGC and ZH contributed to developing the protocol, drafting the manuscript and checked the final draft of the manuscript. XDL,JYY,ZZ,ZSY,XYH and ZCC participated in data collection and in the preparation of the

manuscript. All authors read and approved the final manuscript.All authors read and approved the final manuscript.

Acknowledgements

Not applicable.

References

1. Derex L, Nighoghossian N: Intracerebral haemorrhage after thrombolysis for acute ischaemic stroke: an update. Journal of neurology, neurosurgery, and psychiatry. 2008; 79(10):1093-99.

2. Karaszewski B, Houlden H, Smith EE, Markus HS, Charidimou A, Levi C, Werring DJ: What causes intracerebral bleeding after thrombolysis for acute ischaemic stroke? Recent insights into mechanisms and potential biomarkers. Journal of neurology, neurosurgery, and psychiatry .2015; 86(10):1127-36.

3. Yaghi S, Eisenberger A, Willey JZ: Symptomatic intracerebral hemorrhage in acute ischemic stroke after thrombolysis with intravenous recombinant tissue plasminogen activator: a review of natural history and treatment. JAMA neurology. 2014; 71(9):1181-85.

4. Adams HP, Jr., del Zoppo G, Alberts MJ, Bhatt DL, Brass L, Furlan A, Grubb RL, Higashida RT, Jauch EC, Kidwell C et al: Guidelines for the early management of adults with ischemic stroke: a guideline from the American Heart Association/American Stroke Association Stroke Council, Clinical Cardiology Council, Cardiovascular Radiology and Intervention Council, and the Atherosclerotic Peripheral Vascular Disease and Quality of Care Outcomes in Research Interdisciplinary Working Groups: the American Academy of Neurology affirms the value of this guideline as an educational tool for neurologists. Stroke .2007; 38(5):1655-11.

5. Higashida RT, Furlan AJ, Roberts H, Tomsick T, Connors B, Barr J, Dillon W, Warach S, Broderick J, Tilley B et al: Trial design and reporting standards for intra-arterial cerebral thrombolysis for acute ischemic stroke. Stroke .2003; 34(8):e109-37.

6. Tissue plasminogen activator for acute ischemic stroke. The New England journal of medicine. 1995; 333(24):1581-87.

7. Fiorelli M, Bastianello S, von Kummer R, del Zoppo GJ, Larrue V, Lesaffre E, Ringleb AP, Lorenzano S, Manelfe C, Bozzao L: Hemorrhagic transformation within 36 hours of a cerebral infarct: relationships with early clinical deterioration and 3-month outcome in the European Cooperative Acute Stroke Study I (ECASS I) cohort. Stroke. 1999; 30(11):2280-84.

8. Hacke W, Kaste M, Fieschi C, von Kummer R, Davalos A, Meier D, Larrue V, Bluhmki E, Davis S, Donnan G et al: Randomised double-blind placebo-controlled trial of thrombolytic therapy with intravenous

alteplase in acute ischaemic stroke (ECASS II). Second European-Australasian Acute Stroke Study Investigators. Lancet .1998; 352(9136):1245-51.

9. Hacke W, Kaste M, Bluhmki E, Brozman M, Dávalos A, Guidetti D, Larrue V, Lees K, Medeghri Z, Machnig T et al: Thrombolysis with alteplase 3 to 4.5 hours after acute ischemic stroke. N Engl J Med. 2008; 359(13):1317-29.

10. Molina CA, Alvarez-Sabin J, Montaner J, Abilleira S, Arenillas JF, Coscojuela P, Romero F, Codina A: Thrombolysis-related hemorrhagic infarction: a marker of early reperfusion, reduced infarct size, and improved outcome in patients with proximal middle cerebral artery occlusion. Stroke. 2002; 33(6):1551-56.

11. Hacke W, Donnan G, Fieschi C, Kaste M, von Kummer R, Broderick JP, Brott T, Frankel M, Grotta JC, Haley EC, Jr. et al: Association of outcome with early stroke treatment: pooled analysis of ATLANTIS, ECASS, and NINDS rt-PA stroke trials. Lancet. 2004; 363(9411):768-74.

12. Berger C, Fiorelli M, Steiner T, Schabitz WR, Bozzao L, Bluhmki E, Hacke W, von Kummer R: Hemorrhagic transformation of ischemic brain tissue: asymptomatic or symptomatic? Stroke. 2001; 32(6):1330-35.

Tables

Table 1: Baseline characteristics of 70 patients treated with r-tPA

Characteristics		Characteristics	
1. Demographic data		Platelet (×109/L)	180.3±65.11
Male	48(68.6%)	INR	1.04±0.16
Age (year)	65.44±10.37	5. Brain CT	16(22.9%)
Weight (kg)	68.38±7.71	Early ischaemic changes	15(21.4%)
2. Previous history		Hyperdense artery sign	13(18.6%)
Hypertension	50(71.4%)	Insular ribbon sign	
Diabetes	16(22.9%)	ASPECT scores	59(84.3%)
Hyperlipidaemia	14(20.0%)	10	5(7.1%)
Transient ischaemic attack	11(15.7%)	8-9	7(10.0%)
Stroke	10(14.3%)	≤7	
Atrial fibrillation	22(31.4%)	6. Clinical classification	
Atrial fibrillation	12(17.1%)	TOAST classification	
Congestive heart failure	9(12.9%)	LAA	39(55.7%)
Smoke	23(32.9%)	CE	25(35.7%)
3. Concomitant medication		LS	1(1.4%)
24 hours before thrombolysis		Other	2(2.9%)
Antiplatelet therapy		Unknown	3(4.3%)
Aspirin	7(10.0%)	OCSP classification	
Clopidogrel	3(4.3%)	TACI	24(34.3%)
Aspirin and clopidogrel	3(4.3%)	PACI	35(50.0%)
Anticoagulant therapy	2(2.9%)	POCI	10(14.3%)
Antihypertensive therapy		LACI	1(1.4%)
Intravenous	9(12.9%)	7. Time (minutes)	
Oral	11(15.7%)	Time from onset to	120.07±88.33
4. Clinical assessment and		arriving at the hospital	
laboratory examination		Time from arriving at the	125.73±56.59
NIHSS score	14(4-34)	hospital to thrombolysis	
4-10	16(22.9%)	Time from onset to	247.41±104.15

11-15	28(40.0%)	thrombolysis	
16-20	19(27.1%)	0-90	0
>20	8(11.4%)	91-180	23(32.9%)
Systolic blood pressure (mmHg)	150.2±22.27	181-270	27(38.6%)
Diastolic blood pressure (mmHg)	85.90±12.07	271-360	10(14.3%)
Blood glucose (mmol/L)	8.00±3.67	>360	11(15.7%)

Table 2: Clinical outcomes of patients with different subtypes of post-thrombolytic ICH

	non-ICH (n=53)	HI (n=7)	PH-1 (n=4)	PH-2 (n=6)
Early neurological deterioration	2(3.8)	1(14.3)		4(66.7) ▼
Favourable outcome at 3 months	24(45.3)	3(42.9)	1(25.0)	
Disability or death at 3 months	8(15.1)	2(28.6)	2(50.0)	4(66.7)
Death at 3 months	6(11.3)	2(28.6)	2(50.0)	3(50.0) ▼

"▼"indicates that there is a statistically significance between PH-2 and non-ICH, P>0.05;

Figures

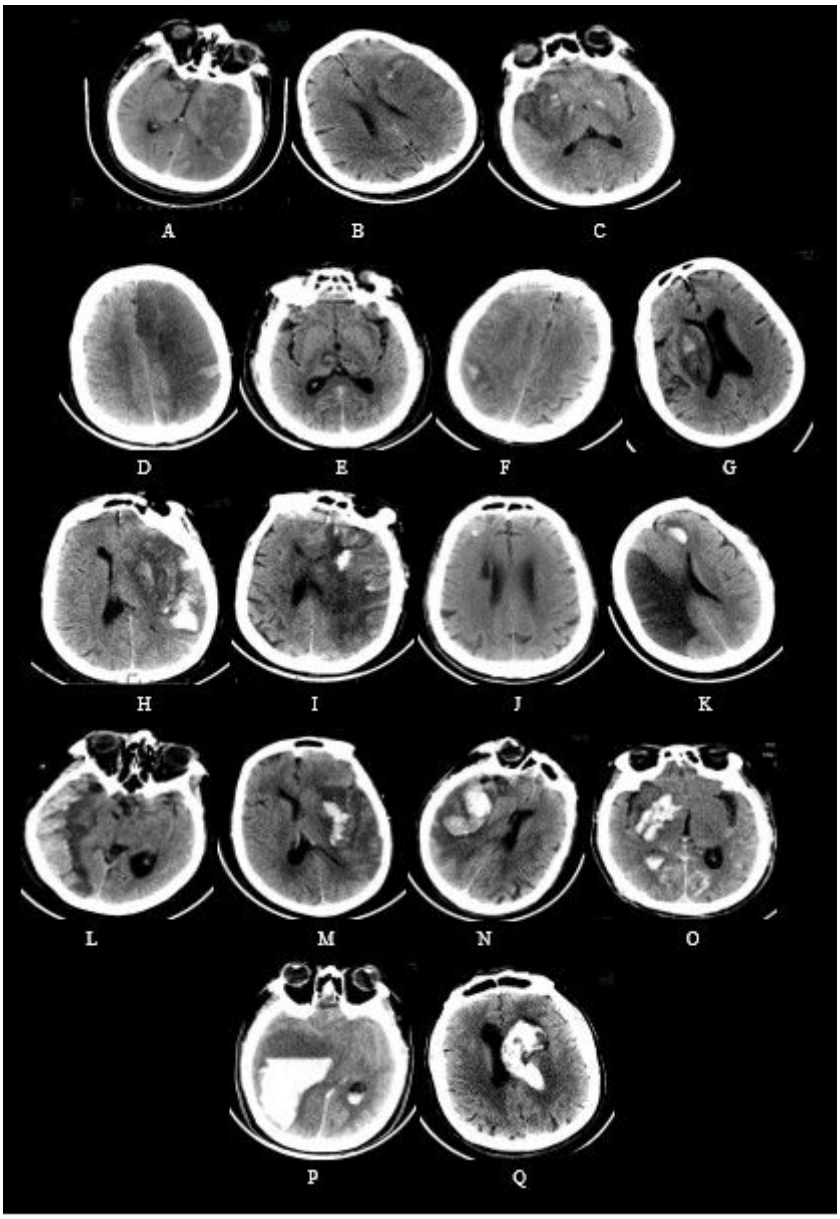

Figure 1

CT images of 17 patients with post-thrombolytic ICH. (A-C) are HI-1, (D-G) are HI-2, and (H-K) are PH-1. (H,I) Irregular and scattered hematomas are seen in the infarct area. (J) The infarcted area is located in the right basal ganglia, and the hematoma is located in the right frontal lobe, which is distant from the infarcted area. (K) The patient had a massive right cerebral infarction with a small hematoma in the left frontal lobe.(L-Q) are PH-2 and sICH. (L-O) The hematomas are located in the infarct area. (M,N) CT shows HI-2 10 hours after thrombolysis. Twenty-four hours after thrombolysis, CT shows that the hematoma has enlarged, which resulted in the deterioration of the patient's clinical symptoms. This finding suggests that some cases of PH may develop from HI. (O) The patient had a right temporal lobe infarction with hemorrhage in the infarct area breaking into the ventricle. (P) The patient had a right cerebral hemisphere infarction accompanied by a huge hematoma in the infarct area and another hematoma in the left thalamus breaking into the ventricle. (Q) The hematoma is distant from the right parietal lobe infarction, which is located in the left basal. ganglia and breaking into the ventricle.

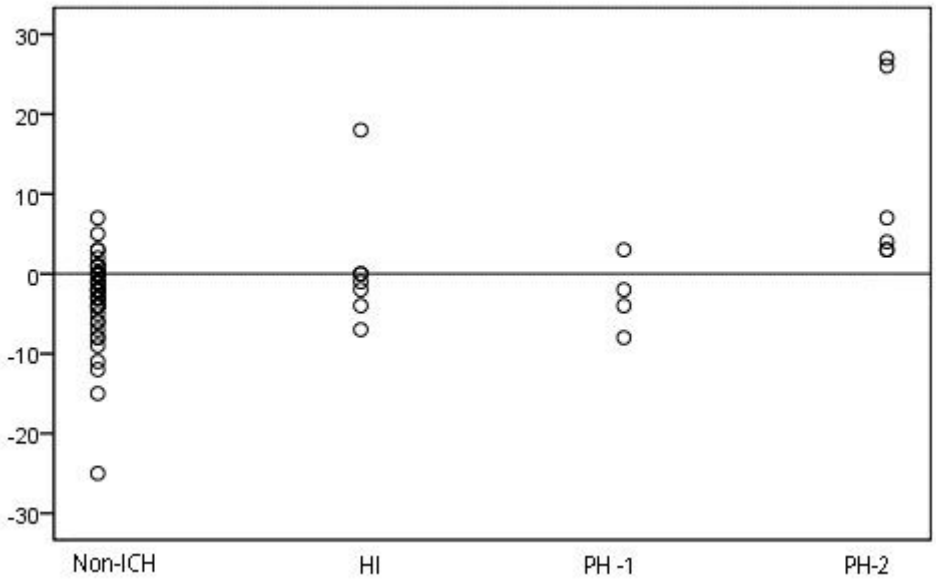

Figure 2

Changes in NIHSS score at 24 hours according to the presence and type of post-thrombolytic ICH.

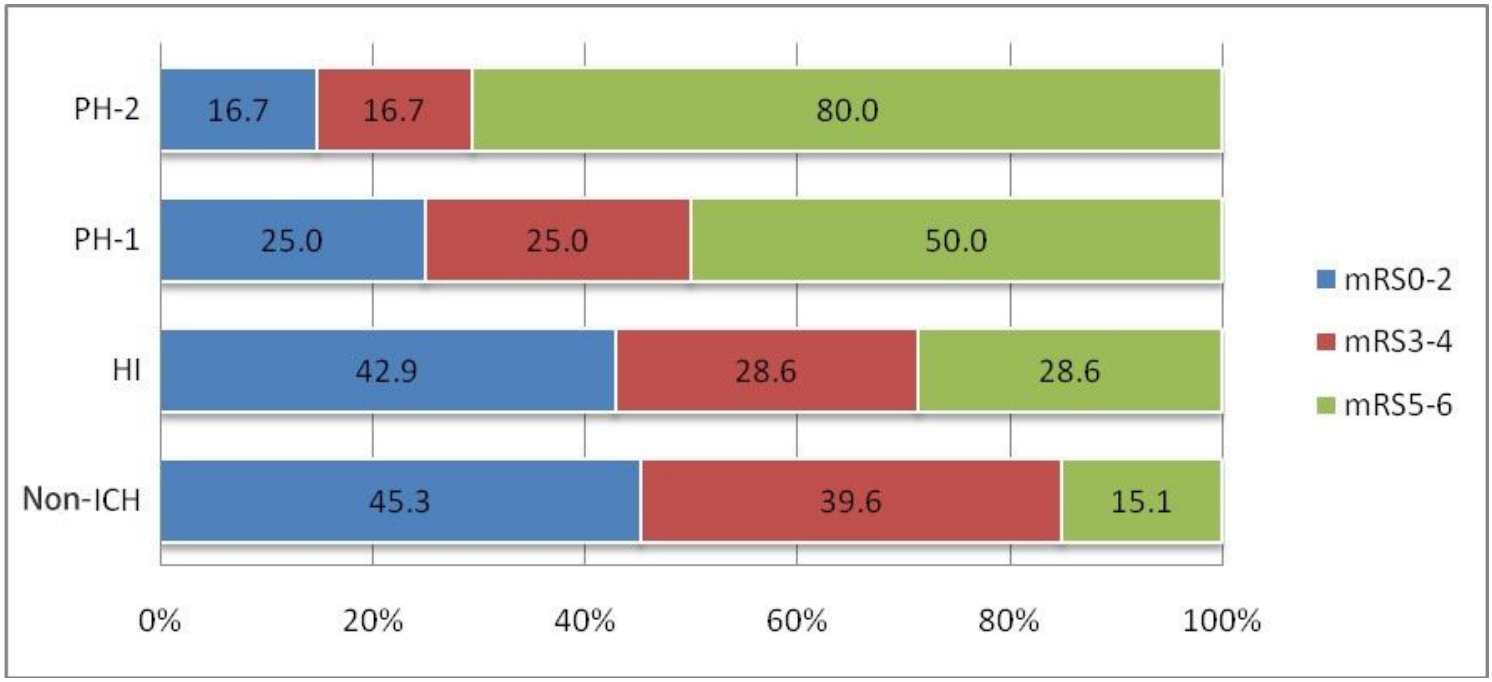

Figure 3

Distribution of mRS scores according to presence and type of post-thrombolytic ICH