Research Square

Preprints are preliminary reports that have not undergone peer review. They should not be considered conclusive, used to inform clinical practice, or referenced by the media as validated information.

Investigations on the Potential of Optical Coherence Tomography as an Imaging Tool for Eustachian Tube

Xiao-Mei Sun, MD
Sixth Affiliated Hospital of Sun Yat-sen University
Jia-Qi Luo, MD
Sixth Affiliated Hospital of Sun Yat-sen University
Zhi-Wen Xiao, MD
Sixth Affiliated Hospital of Sun Yat-sen University
Qing-Yu Gu, BA
Sixth Affiliated Hospital of Sun Yat-sen University
Lin-Chan Lan, BA
Sixth Affiliated Hospital of Sun Yat-sen University
Hui-Qing Zhang, MD
Sixth Affiliated Hospital of Sun Yat-sen University
Guan-Ping Zhang, MD (zhguanp@mail.sysu.edu.cn)
Sixth Affiliated Hospital of Sun Yat-sen University

Research Article

Keywords: eustachian tube optical coherence tomography (ET-OCT), ET-OCT examination, distinct lumen

Posted Date: December 9th, 2020

DOI: https://doi.org/10.21203/rs.3.rs-118445/v1

License: This work is licensed under a Creative Commons Attribution 4.0 International License. Read Full License

Version of Record: A version of this preprint was published at Scientific Reports on April 13th, 2021. See the published version at https://doi.org/10.1038/s41598-021-87637-6.

Abstract

The purpose of this study was to explore the feasibility of eustachian tube optical coherence tomography (ET-OCT) for the pharyngeal region of the eustachian tube. Ten subjects with ear complaint accepted ET-OCT with the guidance of nasal endoscopy, and ET-OCT examination was performed on both sides of each subject's eustachian tubes. Operation process and images were analyzed. 10 subjects ranged from 21 to 73 years old (45 ± 14.77) were enrolled in this study. Eighteen ET-OCT imaging were completed. The mean duration of each examination was 2.80 ± 1.62 min (ranged from 2 to 7min). There was no adverse event or complication. In some subjects, the ET-OCT images presented clear eustachian tube wall microstructure, including distinct lumen, mucosa, submucosa, cartilage and plica. But in some subjects, it showed different characteristics, such as unclear hierarchy, secretions in the lumen. ET-OCT may help to distinguish eustachian tube structural composition and elucidate its pathophysiological mechanism. It is a valuable imaging tool suit for the eustachian tube, and it shows potential diagnostic value in determining luminal morphology, intraluminal mucosa and submucosal tissue in the pharyngeal region of the eustachian tube.

Introduction

Optical coherence tomography (OCT) is a non-invasive microscopic imaging technique with high spatial resolution cross-sectional images of tissue microstructure(1). It can make up the shortcomings of microscopy and ultrasound in terms of transmittance and resolution, respectively. Due to its non-invasive, radiation-free and high-resolution features, OCT is widely used in the ophthalmology, respiratory system and gynecology (2-4). Endovascular diagnosis of coronary artery disease and tortuous cerebrovascular of brain by luminal optical coherence tomography technology have also been well developed(5-9). However, there are few reports on the clinical application of OCT in the ear and eustachian tube. Considering OCT is a valuable imaging technology in which suiting for the application scenario of narrow lumen observation, we speculate eustachian tube should also be applied.

The current evaluation of the eustachian tube mainly focused on measuring the pressure of the eustachian tube and evaluating the patency of the eustachian tube. At present, the images obtained by imaging examinations such as CT and MRI cannot show the status of mucous membranes. Biopsy is needed to obtain detailed tissue structure hierarchy, which may cause secondary eustachian tube dysfunction, so the morphology research remains a challenge. Understanding the luminal surface and the surrounding soft tissue of the eustachian tube will help to figure out the etiology of diseases associated with abnormal eustachian tube function. Hence, as a non-invasive, real-time imaging method, OCT may be a promising option to inspect the eustachian tube.

This study aimed to investigate the feasibility of ET-OCT in the eustachian tube via eustachian orifice, and confirm the image can show distinctive organizational hierarchy of eustachian tube wall.

Materials And Methods

Subjects

Patients with ear complaint, who visited the department of otorhinolaryngology of the sixth Affiliated Hospital of Sun Yat-sen University between July and October 2020, were enrolled in this research before treatment. Clinical data and ET-OCT imaging acquisition were performed under a protocol approved by the Ethics Committee of the Sixth Affiliated Hospital of Sun Yat-Sen University (2020ZSLYEC-155), following informed consent.

ET-OCT imaging

A commercial nasal endoscope (TC200, Karl Storz, Germany) was used to collect high resolution images of the nasal cavity and nasopharynx. An eustachian tube insufflation catheter with an outer diameter of 4mm and an inner diameter of 3mm was used to guide the ET-OCT probe to the pharyngeal region of the eustachian tube correctly.

Scans were performed using OCT imaging system (YSD-OCTIS-R-A1), Guangzhou Winstar Medical Technology Company Limited, Guangzhou, China). The equipment emits a central wavelength of 1310 nm, with a measured lateral resolution of 25 μm and axial resolution of 15 μm. The probe (YSD-LC1715RA) is 1.7mm in diameter and 1.5m in length. There is a 5mm gap between the scanner and the tip.

ET-OCT scanning protocol

Right nasal cavity, turbinate and nasopharynx were examined by nasal endoscopy, after superficial anesthesia and images were collected. Then ET-OCT probe is inserted into the lumen of the eustachian tube slowly through the pharyngeal opening of eustachian tube with the guidance of nasal endoscope. And when the operator feels resistance, continuous image acquisition begins from the inside to the outside, until the probe is out of the eustachian tube. (Fig 1). Exit the instruments from the nasal cavity. A case of ET-OCT image acquisition was completed. Then left OCT image acquisition was performed in the same manner. Each image is generated every 0.5 mm at a line scan rate of 5mm per second. The image can provide an penetrate depth of 2mm from the ET mucosal surface, with resolution of 1024*1024 pixels.

Statistical Analysis

Statistical analysis was performed by SPSS version 20.0 software package (IBM Corporation, Armonk, NY, USA). Data were expressed as mean ± standard deviation. And categorical data was expressed as percentages (%).

Results

patient characteristics

10 subjects were enrolled in this study. The mean age was 45 ± 14.77 years old (range 21 to 73 years). Bilateral ET-OCT imaging was performed on each subject. Eighteen ET-OCT imaging were completed. The patient characteristics, reasons for failure are shown in Table 1. The mean duration of each OCT examination was 2.80 ± 1.62 min (ranged from 2 to 7min). There was no adverse events or complications, such as severe pain, bleeding, mucosal injury, ear fullness and so on. Both the tip and probe extending part of the eustachian tube insufflation catheter was calculated as the depth of the probe into the eustachian tube. Our research showed the average depth of ET-OCT probe entering the ET lumen was 10.98±0.48mm.

Image characteristics obtained by ET-OCT examination of the microarchitecture

ET-OCT image is illustrated in Figure 2. And the image quality was very good. According to the histological section characteristics of eustachian tube in the previous literature, we found that OCT images can clearly show corresponding hierarchical characteristics. It showed clear hierarchical structure with smooth ET wall, distinct lumen, mucosa, submucosa, cartilage and plica. The microarchitectures were clearly identified.

High quality ET-OCT images showed clear hierarchical structure with smooth ET wall in normal subjects. But in some subjects showed different characteristics, such as unclear hierarchy, secretions in the lumen, mucosa thickening, submucosa thickening, ET wall thickening (Fig 3).

Discussion

Eustachian tube serves to equalize the air pressure between the middle ear and the atmospheric pressure (10, 11). In adults, the eustachian tube is about 31~39mm in length. The lower 2/3 is cartilage segment and the upper 1/3 is bony segment. Epithelial lining of the eustachian tube is pseudostratified ciliated columnar epithelium with goblet cells near the pharynx. Under the ET epithelial lining, lateral region was filled with the ET glands, Ostmann's fatty tissue (OF), connective tissue, cartilage, tensor veli palatin (12). Specialist used OCT to evaluate the normal and pathological tympanic membrane of patients with secretory otitis media, showing that OCT can measure a high-resolution image of the three layers of the tympanic membrane(13-15). These studies were the initial applications in the field of otology. Then, a study firstly used OCT to explore the application on sheep body's ET, the result presented that OCT images were highly correlated with the histological cross-sectional images, from the inner cavity to the eustachian tube (16). In this study, ET-OCT is used to investigate the microstructure of the ET. The ET-OCT image presented a clear hierarchy of structure of mucosa, submucosa, plica and cartilage, mimicking the previous characteristics of histological sections.

In this study, we applied nasal endoscope navigation to send the ET-OCT probe into the eustachian tube accurately in human firstly. And it showed that it worked. Furthermore, the probe can enter the eustachian tube with a maximum depth of 10.20~11.77mm. According to the anatomical characteristics of the ET, the ET-OCT probe is mainly located in the cartilage segment and does not reach the isthmus of the eustachian tube. Therefore, ET-OCT images present the structure of cartilage segment ET. Patient

complained of mild tolerable swelling pain, without bleeding and other side effects. Furthermore, due to the short recording time, subjects were able to accept ET-OCT test accompanied with nasal endoscopy under the nasal surface anesthesia. But in patients with a deviated septum and a narrow nasal cavity on one side, the probe failed be placed into the ET, because the inspection procedure could induce pain. Therefore, subjects with narrow nasal are not proper candidates for the ET-OCT.

ET-OCT images showed diversified characteristics in this study. Li et al used the point-by-point comparison between endobronchial optical coherence tomography (EB-OCT) images and pathological findings of animal model of tracheal stenosis, showing that EB-OCT could distinctly display the morphological abnormalities of the mucosal and submucosal layers and airway cartilage(17). According to the human's small airways researches, OCT can produce high-resolution airway morphology images and it is well or even better correlated with CT scanning and histopathological results(3, 10, 18-20).

Based on the experience of identifying the characteristics of OCT images from these previous literatures, we found that some ET-OCT images presented characteristics similar to that of airways, such as unclear hierarchy, secretions in the lumen, mucosa thickening, ET wall thickening. Images presented unclear hierarchy mimics the mucous membrane fibrosis caused by chronic inflammation. ET wall thickening with clear hierarchy may correspond to mucosal edema with acute inflammatory changes. ET-OCT imaging can provide differentiated images, which is similar to the morphological features of ET. This new approach may expand the application of OCT in the ET dysfunctional disease.

So far, there is no reliable study that can definitively evaluate the eustachian tube in clinical practice. Tubomanometry (TMM), Eustachian Tube Dysfunction Patient Questionnaire (ETDQ-7), otoscope, temporal bone CT and acoustical impedance test are generally required for comprehensive judgment(21, 22). These examinations main emphasize on the functional opening movement and subjective feeling, but no information about the statement of mucosa and eustachian tube lumen wall are involved. Our study showed that ET-OCT can provide high resolution images of ET wall with clear hierarchy. Meanwhile, diverse image characteristics emerged. These new findings may indicate the real statement of ET. Investigating the eustachian tube wall morphological abnormalities, can further help us understand the mechanism of different type of diseases with ET dysfunction. It also can help clinicians to make proper therapeutic option.

Conclusion

ET-OCT may help to distinguish eustachian tube morphological composition and elucidate its pathophysiological mechanism. It is a valuable imaging tool suit for the eustachian tube. And it shows potential diagnostic value in determining the morphology of luminal, mucosa and submucosal tissue in the pharyngeal region of the eustachian tube.

Based on our research, ET-OCT is a potential imaging tool to facilitate assessment of eustachian tube function. Although further clinical trials are needed, this groundwork shows that ET-OCT can complement or even potentially replace the current tests. And further study with a large sample and quantitative

measurements are warranted. The identification of tissue characteristics automatically, based on optical attenuation coefficients, machine learning algorithms, and deep learning techniques, can improve the prospect of ET-OCT.

Declarations

Acknowledgements

We thank Guangzhou Winstar Medical Technology Company, who supported us with the technical operation of the OCTICS Imaging System.

Author contributions

Authors' contributions: XMS was a major contributor in writing the manuscript. JQL checked the figure and images. ZWX collected the data of the patients. QYG assisted in the operation. LCL performed clinical examination. HQZ prepared and communicated with the patient prior to the examination. GPZ designed the study. All authors read and approved the final manuscript.

Competing interests

The authors declare no competing interests.

References

Due to technical limitations, Reference Section is not available.

Tables

Table1. Patient characteristics.

No	Sex	Age	Time (min)	Diagnosis	Characteristics		Reasons for NC
					R	L	
1	M	49	2	Left cholesteatoma	Normal	ET wall thickening	
2	M	26	2	right cholesteatoma	ET wall thickening	Not completed	septum deviated to left and the left nasal cavity is narrow
3	F	40	7	Bilateral chronic otitis media	Submucosal thickening	Blurred boundary	
4	F	44	2	left chronic otitis media	Submucosal thickening	ET wall thickening and blurred boundary	
5	F	40	4	left eustachian tube is dysfunctional	Normal	Mucosal thickening and layer unclear, secretion in lumen	
6	M	55	2	Bilateral chronic otitis media	Normal	Blurred mucosal layer	
7	M	50	2	left chronic otitis media	Not completed	Normal	the septum deviated to right and the right nasal cavity is narrow
8	M	73	2	Right secretory otitis media	Submucosal layer thickening	Normal	
9	M	21	2	Chronic rhinitis, Epstein Barr virus positive	Normal	The mucous layer thinning	
10	F	52	3	right chronic otitis media	Submucosal layer is unclear	Normal	

NC, not completed.

Figures

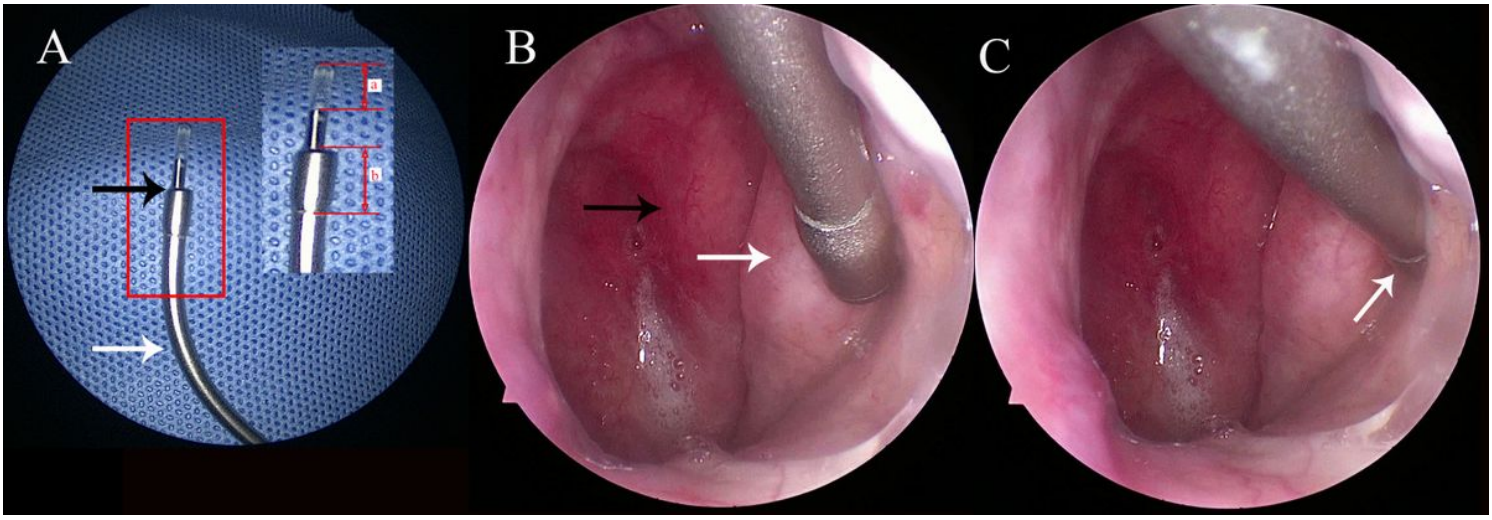

Figure 1

The ET-OCT probe was inserted into the eustachian tube with the guidance of nasal endoscopy. A. An ET-OCT probe was inserted into the eustachian tube insufflation catheter. White arrow, eustachian tube insufflation catheter. black arrow, OCT probe; a, gap between the light source and the tip (5mm), b, the end of the eustachian tube insufflation catheter (5mm). B. ET-OCT probe reached the pharyngeal orifice of the eustachian tube. White arrow, torus tubarius; black arrow, nasopharynx. C. the ET-OCT probe was inserted into the eustachian tube, image acquisition begins. White arrow, pharyngeal orifice.

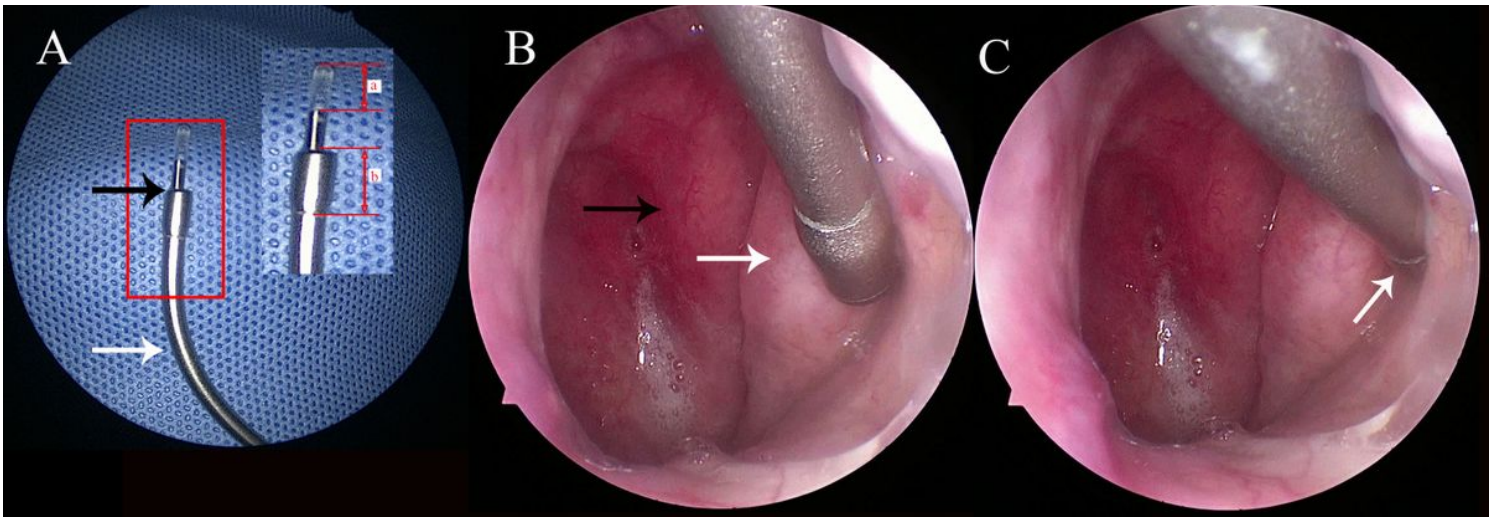

Figure 1

The ET-OCT probe was inserted into the eustachian tube with the guidance of nasal endoscopy. A. An ET-OCT probe was inserted into the eustachian tube insufflation catheter. White arrow, eustachian tube insufflation catheter. black arrow, OCT probe; a, gap between the light source and the tip (5mm), b, the end of the eustachian tube insufflation catheter (5mm). B. ET-OCT probe reached the pharyngeal orifice of the

eustachian tube. White arrow, torus tubarius; black arrow, nasopharynx. C. the ET-OCT probe was inserted into the eustachian tube, image acquisition begins. White arrow, pharyngeal orifice.

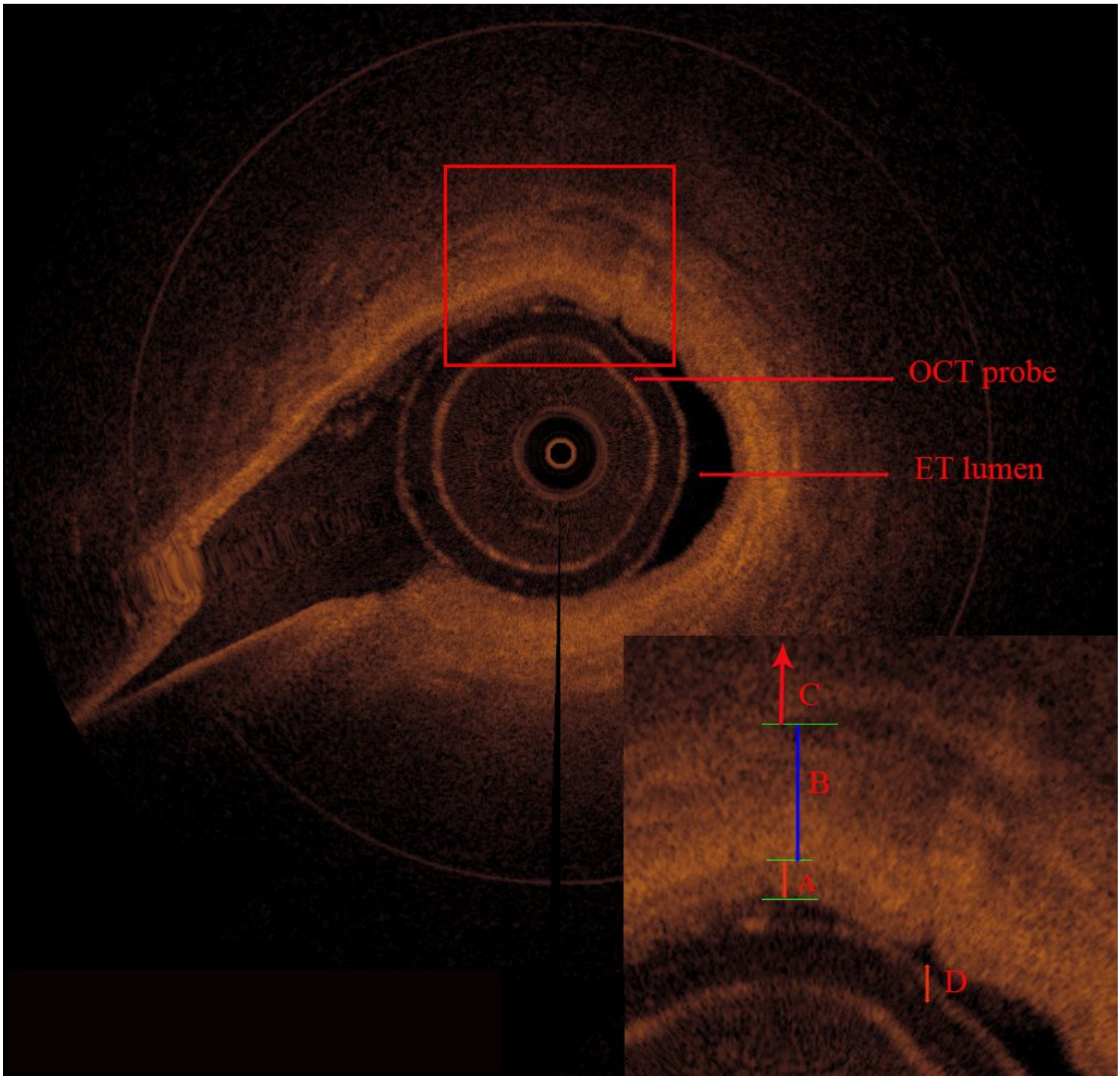

Figure 2

Optical coherence tomography image of eustachian tube. A, mucosa; B, submucosa; C, cartilage, D, plica.

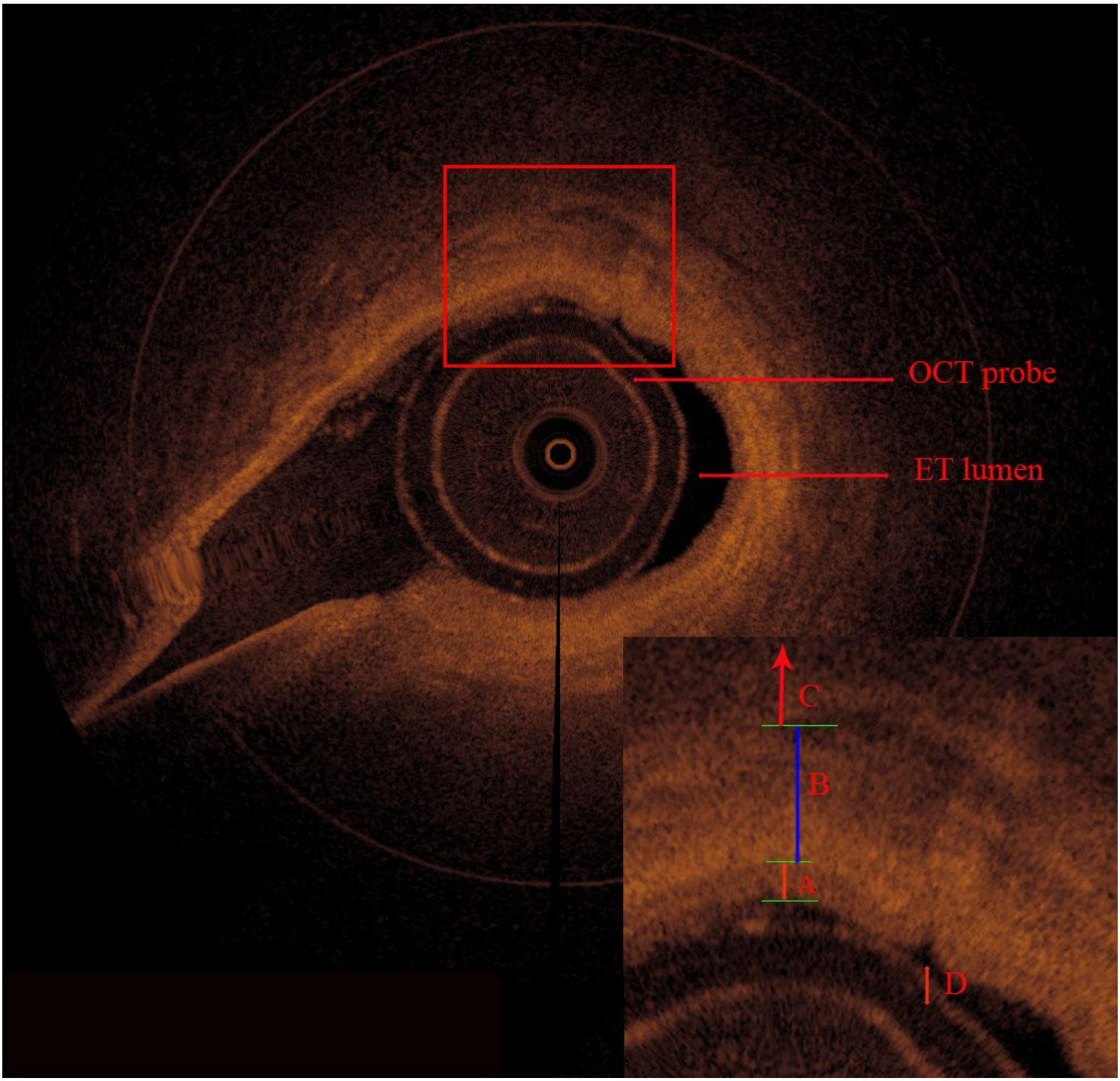

Figure 2

Optical coherence tomography image of eustachian tube. A, mucosa; B, submucosa; C, cartilage, D, plica.

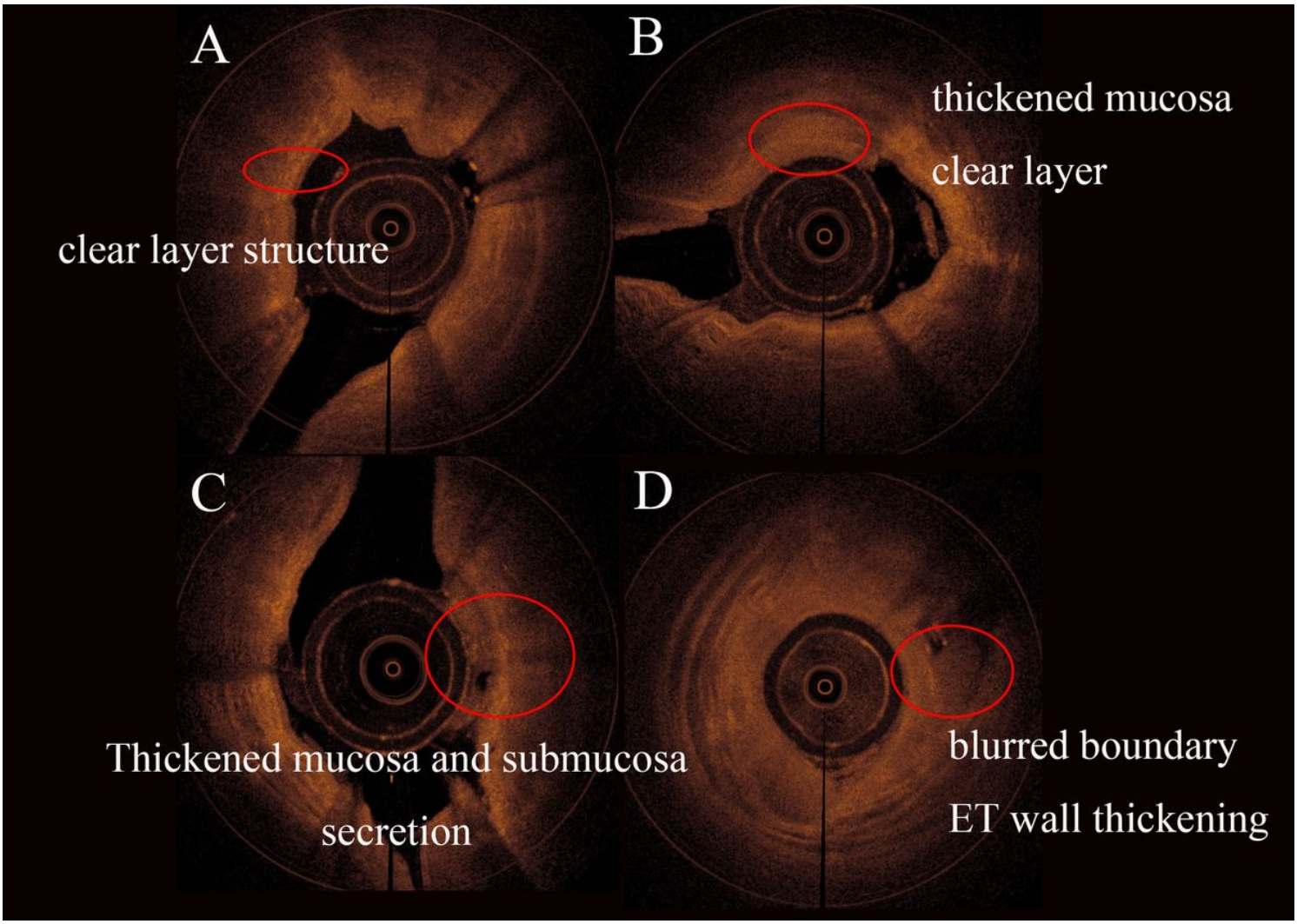

Figure 3

ET-OCT images with diverse characteristics. A. Normal: mucosa, submucosa, and cartilage were well bedded. B. Thickened mucosa and clear layer. C. Thickened mucosa and submucosa with secretions in the ET lumen D. ET wall thickening and blurred boundary.

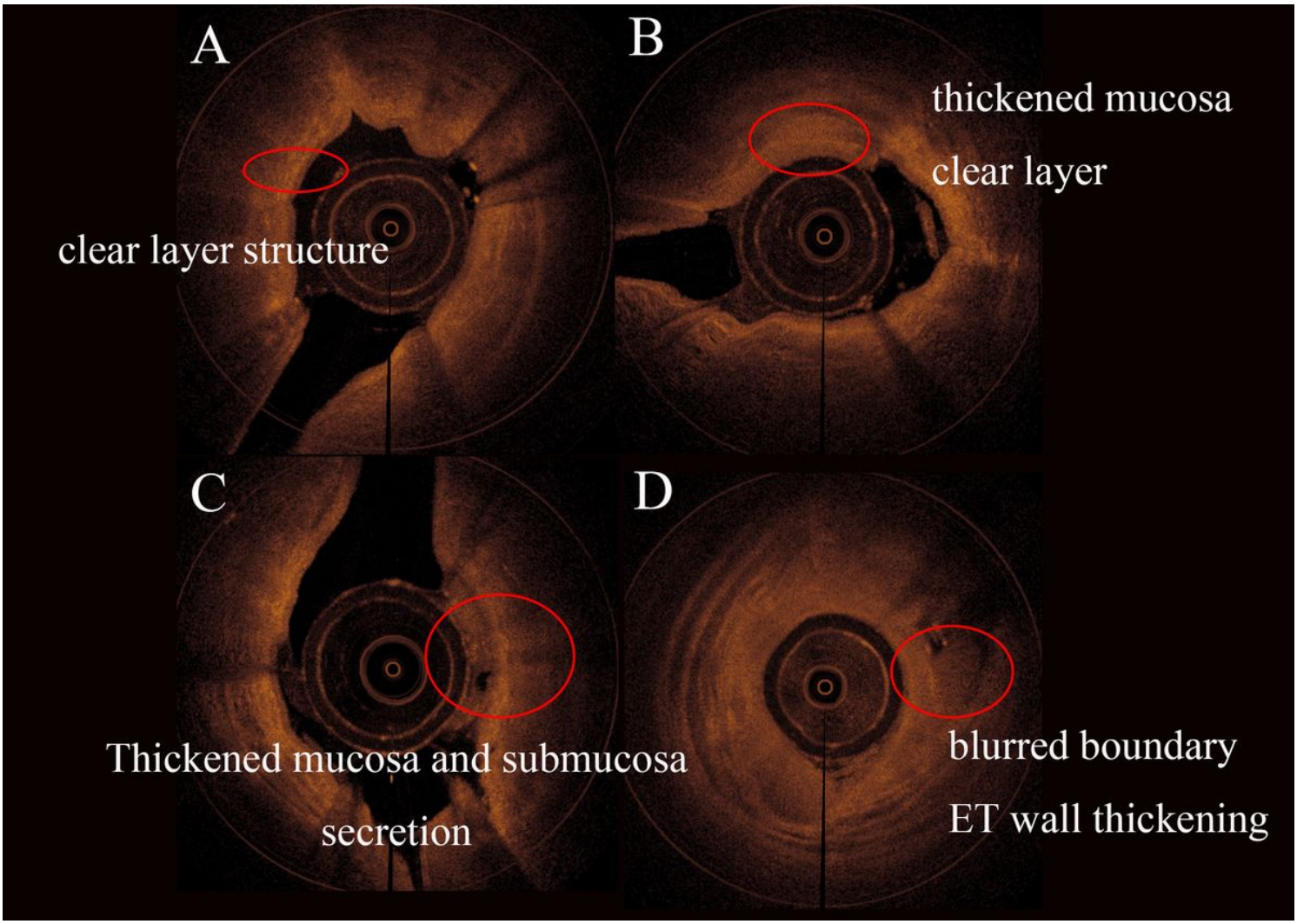

Figure 3

ET-OCT images with diverse characteristics. A. Normal: mucosa, submucosa, and cartilage were well bedded. B. Thickened mucosa and clear layer. C. Thickened mucosa and submucosa with secretions in the ET lumen D. ET wall thickening and blurred boundary.

Supplementary Files

This is a list of supplementary files associated with this preprint. Click to download.

- Additionalinformation.docx
- Additionalinformation.docx