Long-term outcomes after endoscopic retrograde pancreatic drainage for symptomatic pancreaticojejunal anastomotic stenosis

Akihiko Kida (kidaakihiko@yahoo.co.jp)
JA Toyama Kouseiren Takaoka Hospital

Taro Kawane
Toyama Prefectural Central Hospital

Hitoshi Omura
Toyama Prefectural Central Hospital

Tatsuo Kumai
Saiseikai Kanagawa Prefecture hospital

Masaaki Yano
Toyama Prefectural Central Hospital

Fumitaka Arihara
Toyama Prefectural Central Hospital

Yuji Hodo
Saiseikai Kanagawa Prefecture hospital

Koichiro Matsuda
Toyama Prefectural Central Hospital

Kohei Ogawa
Toyama Prefectural Central Hospital

Yukihiro Shirota
Saiseikai Kanagawa Prefecture hospital

Mitsuru Matsuda
Toyama Prefectural Central Hospital

Akito Sakai
Toyama Prefectural Central Hospital

Mitsuhiro Terada
JA Toyama Kouseiren Takaoka Hospital

Tokio Wakabayashi
Saiseikai Kanagawa Prefecture hospital

Research Article

Keywords: pancreaticojejunostomy, anastomotic stenosis, endoscopic retrograde pancreatic drainage, pancreatic stent

Posted Date: December 10th, 2020

DOI: https://doi.org/10.21203/rs.3.rs-119255/v1

Version of Record: A version of this preprint was published at Scientific Reports on February 24th, 2021. See the published version at https://doi.org/10.1038/s41598-021-84024-z.

Abstract

Background There is limited evidence demonstrating the usefulness of endoscopic retrograde pancreatic drainage (ERPD) for symptomatic pancreaticojejunal anastomotic stenosis (sPJS). We examined the usefulness of ERPD for sPJS.

Methods We conducted a retrospective analysis of 10 benign sPJS patients. Following items were evaluated: technical success, adverse events and clinical outcome of ERPD.

Results Technical success rate was 100% (10/10); 9 patients had a pancreatic stent (no-internal-flap: n=4, internal-flap: n=5). Median follow-up was 920 days. Four patients developed recurrence. Among them, 3 patients had a stent with no-internal-flap in initial ERPD and the stent migrated in 3 patients at recurrence, and a stent was not placed in 1 patient in initial ERPD. Four follow-up ERPD were performed. No recurrence was observed in 6 patients. Among them, none of the stents migrated (no-internal-flap: n=1, internal-flap: n=5), and none were replaced stents due to stent failure. A stent placement with no-internal-flap was associated with recurrence (p=0.042). Mild adverse events developed in 14.3% (2/14).

Conclusions ERPD was performed safely with high technical success. Recurrence was common in a stent placement with no-internal-flap, which was associated with stent migration. Long-term stent placement didn't result in stent failure.

Introduction

Pancreaticojejunal anastomotic stenosis (PJS) is an important late complication associated with pancreaticoduodenectomy (PD), with a reported incidence rate of 1.4-11.4%.[1] The most common symptoms of PJS were abdominal pain and recurrent acute pancreatitis, followed by impaired pancreatic function.[1] Interventions for symptomatic PJS (sPJS) include surgery and endoscopic procedures. Surgery is performed as a revision to the initial PD and is thus considered highly invasive. Therefore, endoscopic interventions are often preferred as the initial treatment strategy for sPJS. Endoscopic retrograde pancreatic drainage (ERPD) and endoscopic ultrasound-guided pancreatic duct drainage (EUS-PD), including the rendezvous technique using EUS-guided puncture, are commonly reported as an effective endoscopic interventions for sPJS. More recently, EUS-PD is preferred for the treatment of sPJS.[2] There are several reasons for selecting EUS-PD over ERPD. For example, a multicenter international collaborative study demonstrated that EUS-PD is an effective treatment strategy with a surgical success rate of 89% (71/80) and clinical efficacy of 81% (65/80).[3] On the other hand, ERPD requires identification of the anastomotic site, which is technically challenging. As a result, the reported success rate of ERPD is below 30%.[4-7] However, EUS-PD is associated with a relatively high adverse events (AE) rate of 20% and these AE are known to be moderate to severe.[3] Considering the high success rate and risk of severe AE demonstrated in the retrospective study, it is recommended that only experts with technical competency perform EUS-PD.[3] On the other hand, we previously reported in a relatively small patient population that ERPD is a safe and effective treatment for sPJS.[8]

In the present study, we report 10 consecutive cases of sPJS. The anastomotic site was identified endoscopically and ERPD was performed successfully in all cases. Our study suggests that, in contrast to previous reports, ERPD is technically feasible as an endoscopic intervention for sPJS. Furthermore, we were able to perform long-term follow-up of patients after ERPD to examine the incidence of sPJS recurrence. Thus, we retrospectively examined the efficacy and safety of ERPD for sPJS in 10 patients.

Results

Patient characteristics

A total of 10 patients who were diagnosed with sPJS underwent ERPD. Study subjects had a median age of 64.5 (45-83), and consisted of 6 male and 4 female patients. Primary diseases that led to the surgery included pancreatic cancer (n=3), intraductal papillary mucinous neoplasm (n=4), biliary tract cancer (n=2), and papillary carcinoma of the duodenum (n=1). Surgical procedures and reconstruction methods employed included pylorus-preserving pancreaticoduodenectomy (PpPD) with modified-Child's reconstruction (n=8), PpPD with Cattell's reconstruction (n=1), and subtotal stomach-preserving PD (SSpPD) with modified-Child's reconstruction (n=1). The cause of sPJS was benign stenosis in all 10 patients. Clinical symptoms of sPJS included recurrent acute pancreatitis (n=8), and glucose intolerance and exocrine pancreatic insufficiency (n=2) (Table. 1).

Endoscopic identification of the anastomotic site

The anastomotic site was accessible and identified in all 10 patients. In 9 patients who underwent PpPD and SSpPD with modified-Child's reconstruction, the anastomotic sites were located tangent to the endoscopic view. In the remaining 1 patient who underwent PpPD with Cattell's reconstruction, the anastomotic site was located frontward to the endoscopic view. Anastomotic sites were characterized by the presence of erosion (n=1), pitted scars (n=6), and slit (n=3) (Figure.1). A tip attachment was used for all 10 patients to facilitate identification of the anastomotic sites. In 1 patient whose anastomotic site was characterized by the presence of pitted scars, the site was identified by imaging the remnant main pancreatic duct by EUS using a small-diameter probe. In the other 3 patients whose anastomotic site was characterized by the presence of pitted scars, the sites were identified by contrast imaging of the pancreatic duct using an injection needle (Table. 2).

ERPD for sPJS

For patients with symptoms of pancreatitis, ERPD was performed only after those symptoms improved. A tip attachment was applied to an endoscope (GIF-H290, GIF-2TQ260M, PCF-PQ260I, PCF-H290I, PCF-H290ZI, CF-HQ290ZI, and SIF-H290S; Olympus Medical Systems, Tokyo, Japan, and EN450BI5, and EI530B; Fujifilm Medical, Tokyo, Japan). When the anastomotic site was able to be identified, endoscopic retrograde pancreatography (ERP) was performed using a contrast cannula (TandemXL, and Swish ERCP cannula; Boston Scientific Japan, Tokyo, Japan, and PR-109Q, PR-110Q, and PR-V234Q; Olympus Medical Systems, and MTW ERCP-Catheter; MTW Endoscopie Manufaktur, Wesel, Germany). After ERP, a

guidewire (VisiGlide, and VisiGlide2 angle; Olympus Medical Systems, and Roadrunner; Cook Medical, Wilston-Salem, NC, United States, and M-Through; Medico's Hirata, Tokyo, Japan) was placed in the pancreatic duct. When ERP was unable to be directly applied, wire-guided technique (WGT) was concomitantly employed. In some cases, the anastomotic site was identified by pancreatography of the suspected site using an injection needle (23G Top endoscopic injection needle, TOP, Tokyo, Japan) to ensure that the remnant main pancreatic duct can be observed or by EUS using a small-diameter probe (UMQ240; Olympus Medical Systems) to identify the remnant main pancreatic duct. When cannulation was challenging due to scarring of the anastomotic site, it was effective to either make an incision to the anastomotic site using a needle knife (KD-1L-1; Olympus Medical Systems) or insert a 19G needle (EZ Shot 3 Plus; Olympus Medical Systems) into the anastomotic site using a forward-viewing echoendoscope (TGF-UC260J; Olympus Medical Systems). After placing the guidewire in the pancreatic duct, the anastomotic site was dilated using a cannula or a balloon dilator (MaxPass; Olympus Medical Systems, and Hurricane RX Biliary Balloon Dilatation Catheter, and CRE PRO GI Wireguided; Boston Scientific Japan, and ZARA EPBD balloon; KANEKA, Tokyo, Japan) or a dilator (ES dilator; Zeon Medical, Tokyo, Japan). When a pancreatic calculi was present, it was removed using a basket catheter (Xemex lithotripsy basket; Zeon Medical, and Memory II 8 Fr Eight Wire Double Lumen Baskets; Cook Medical) or electrohydraulic lithotripsy by pancreatoscopy (SpyGlass DS; Boston Scientific Japan). Lastly, either a pancreatic stent with no-internal-flap or with internal-flap (Geenen Pancreatic Stent, and Zimmon Pancreatic Stent; Cook Medical, and Advanix Pancreatic Stent; Boston Scientific Japan) was placed (Figure. 2).

ERP was performed and a guidewire was placed successfully in all 10 patients after identifying the anastomotic sites. The methods of ERP and guidewire placement for each anastomotic site are summarized in Table. 3. In one patient whose anastomotic site was characterized by the presence of erosion, ERP and guidewire placement were facilitated by the use of WGT. Among 3 patients whose anastomotic site was characterized by the presence of a slit, ERP and guidewire placement were successfully performed with cannulation alone in 2 patients, whereas the use of WGT was required in 1 patient. Among 6 patients whose anastomotic site was characterized by the presence of pitted scars, ERP and guidewire placement were successfully performed with cannulation alone in 1 patient, whereas the remaining patients required the use of WGT (n=1), WGT and incision of the anastomotic site with a needle knife (n=1), the use of an injection needle and WGT (n=1), and the use of an injection needle, WGT, and incision of the anastomotic site with a needle knife (n=2).

Following the placement of a guidewire, anastomotic sites were successfully dilated in all 10 patients. Anastomotic sites were dilated with a balloon (n=7), a dilator (n=1), and a dilation for contrast cannula (n=2). For the 7 patients who underwent dilation of their anastomotic sites with a balloon, the median diameter of the remnant main pancreatic duct was 7 mm (5-9 mm) and that of the balloon dilation was 6 mm (3.3-8 mm). The median ratio of the diameters of balloon dilation to that of the remnant main pancreatic duct was 0.86 (0.47-1.60), and waist disappearance was observed in 5 patients. There were 2 patients who were performed balloon dilations exceeding the ratio of 1.00 (1.33 and 1.60). In these two patients, balloon dilations with the diameters of balloon exceeding that of the remnant main pancreatic

duct were needed to obtain waist disappearance. A pancreatic stent was placed in 9 patients (with no-internal-flap: n=4, with internal-flap: n=5). The sizes of these stents were 4 Fr (n=1), 5 Fr (n=6), and 7 Fr (n=2). In the remaining 1 patient, a stent was not placed because waist disappearance was observed with a balloon and dilation of the anastomotic site was confirmed on endoscopy. Pancreatic calculi were removed from 2 patients (Table. 3).

Recurrence of sPJS after ERPD

The median follow-up after initial ERPD was 920 days (137-2,223 days). Of the 10 patients, 4 developed recurrent sPJS in a median of 540 days (33-1,865 days) after initial ERPD. For 4 recurrent sPJS, anastomotic sites of the initial ERPD were characterized by the presence of pitted scars (n=2) and slit (n=2). Although all 4 patients underwent balloon dilation of the anastomotic site in initial ERPD, only 2 achieved waist disappearance. Pancreatic calculi were identified in one patient with recurrent sPJS, even though calculi were removed in initial ERPD. Pancreatic stents with no-internal-flap were used in 3 of 4 patients in initial ERPD, and the stent migrated in all 3 patients at recurrence. These stents were 5 Fr (n=2) and 7 Fr (n=1) in size. A pancreatic stent was not placed in the remaining 1 patient in initial ERPD (Table. 4). A total of 4 follow-up ERPD were performed in 3 of 4 patients with recurrent sPJS. Two patients underwent 1 follow-up ERPD and were treated successfully, whereas the remaining 1 patient required 2 follow-up ERPD. Another 1 patient did not wish to undergo follow-up ERPD. ERPD was therefore not performed and the patient has had multiple recurrences of sPJS. In one of the patients who was successfully treated by 1 follow-up ERPD, the anastomotic site was characterized by the presence of a slit in initial ERPD. However, at recurrence, significant scarring was observed at the anastomotic site and an incision with a needle knife was required. In the patient who required 2 follow-up ERPD, the anastomotic site was initially characterized by the presence of pitted scars. However, there was significant scarring at the anastomotic site at recurrence. Thus, the first follow-up ERPD was not successful. In the second follow-up ERPD, a forward-viewing echoendoscope was inserted into the anastomotic site, and the anastomotic site was punctured with a 19G needle and subsequently dilated with a dilator to successfully perform ERPD.[9]

Six patients didn’t have recurrent sPJS. The median follow-up in these patients was 292 days (137-1,000 days). None of the pancreatic stents placed in these patients migrated and none were replaced pancreatic stents during the follow-up period. Among them, 5 patients had pancreatic stents with internal-flap and 1 patient had a pancreatic stent with no-internal-flap. The sizes of these stents were 4 Fr (n=1), 5 Fr (n=4), and 7 Fr (n=1).

On univariate analysis, the use of a pancreatic stent with no-internal-flap was identified as a risk factor for sPJS recurrence (p=0.042) (Table. 5).

AE after ERPD

AE developed in 14.3% of all cases (2/14). These AE were mild post endoscopic retrograde pancreatography pancreatitis (PEP) (n=1) and anastomotic leak due to balloon dilation (n=1). The patient

with mild PEP did not have a pancreatic stent placed. In the second patient, anastomotic leak was identified after the patient presented with abdominal pain after ERPD. Both of these AE were treated successfully by conservative treatments.

Discussion

ERPD is generally considered challenging to perform in patients with sPJS. However, we demonstrated that ERPD was feasible in 10 consecutive sPJS patients. The efficacy of ERPD was evaluated by technical success and clinical success, whereas its safety was evaluated based on the incidence of AE. Our study suggested that the following are essential in improving the technical success of ERPD: 1) identification of the anastomotic site and 2) ERP of the remnant main pancreatic duct followed by the placement of a guidewire. After successfully placing a guidewire, it is possible to dilate the anastomotic site and to place a pancreatic stent.

Identification of the anastomotic site in sPJS is considered technically challenging. However, we were able to identify anastomotic sites in 10 consecutive cases. Thus, we demonstrated that it is possible to identify anastomotic sites by having a good understanding of the characteristics of their location and types. Ideally, a tip attachment should be used because it stretches the gastrointestinal folds to facilitate identification of anastomotic sites that may otherwise be hidden between the folds. In the present study, the tip attachment was used for all 10 cases and facilitated the process. In terms of the location of anastomotic sites, we previously demonstrated that they are typically found tangent to the endoscopic view in patients who underwent PD with modified-Child's reconstruction and frontward to the endoscopic view in patients who underwent PD with Cattell's reconstruction.[8] Consistent with previous studies, we demonstrated that the anastomotic sites were located tangent to the endoscopic view in 9 patients who underwent PD with modified-Child's reconstruction and frontward to the endoscopic view in 1 patient who underwent PD with Cattell's reconstruction. Thus, these characteristics may be useful in identifying anastomotic sites.

The type of anastomotic site was classified into those with erosion, pitted scars, or slit. Anastomotic sites with erosion and slits were relatively easy to identify because they were open. In contrast, those with pitted scars were difficult to identify because they were closed. In such cases, it is beneficial to identify the remnant main pancreatic duct on either EUS or contrast imaging using an injection needle prior to identifying the anastomotic site. Collectively, our study suggests that these characteristics and modifications to the procedures enable identification of anastomotic sites, which is otherwise challenging.

We also demonstrated that the type of anastomotic site determines the technical difficulties associated with ERP and placement of a guidewire. Although it was relatively easy to perform ERP and place a guidewire into anastomotic sites with erosion or slits, those with pitted scars required additional, highly technical procedures such as incision of the anastomotic site with a needle knife and puncture of the

anastomotic site with a forward-viewing echoendoscope. Thus, technical modifications may be needed to perform ERP and place a guidewire into anastomotic sites with scarring.

We performed long-term follow-up of patients who underwent ERPD, and found that sPJS recurred in patients who had no pancreatic stents placed in initial ERPD and in those whose pancreatic stents migrated. Stent migration was specific to pancreatic stents with no-internal-flap in our patients, and the use of pancreatic stents with no-internal-flap was associated with sPJS recurrence. This suggests that pancreatic stents with internal-flap should be selected over pancreatic stents with no-internal-flap to prevent stent migration. As recurrent sPJS requires additional ERPD procedures that are technically challenging and more complex than initial ERPD, we recommend using a pancreatic stent with internal-flap in initial ERPD to prevent recurrence.

In our study, none of the patients without sPJS recurrence required replacement of their stents within the follow-up period of approximately 10 months. However, none of the patients developed sPJS recurrence due to occlusion or failure of their stents. Previous studies revealed that long-term placement of pancreatic stents for patients with chronic pancreatitis can result in stent occlusion and subsequent pancreatitis at least 6 months after the pancreatic stenting.[10-12] Thus, it is common to replace pancreatic stents every 3 months.[13] The clinical pathogenesis of sPJS that developed as a result of postoperative benign stenosis of the anastomotic site is different from that of chronic pancreatitis characterized by the reduced output of pancreatic juice or by the presence of pancreatic calculi and mucous plug that developed as a result of increased viscosity of pancreatic juice. These differences may underlie the relatively low risk of stent occlusion or failure due to long-term placement of a pancreatic stent in patients with sPJS. Thus, patients with sPJS may not require replacement of the pancreatic stent, which is otherwise recommended for patients with chronic pancreatitis. Collectively, our study suggests that regular pancreatic stent replacement is not necessary in patients with sPJS. As such, pancreatic stents with internal-flap should be selected over pancreatic stents with no-internal-flap for the patients with sPJS.

AE related to ERPD were rare and relatively mild. A previous study of EUS-PD revealed that early AE were identified in 20% of patients (16/80), while late AE were identified in 11% of patients (9/80).[3] It also identified both moderate (abdominal pain: n=3, bleeding: n=1) and severe (pancreatitis: n=6, pseudocyst: n=4, pancreatic fistula: n=1, perforation: n=1) AE in the early stage, and abdominal pain (n=1), perforation (n=1), pancreatitis (n=2), pancreatic fistula (n=1), and pancreatic abscess (n=4) in the late stage.[3] Thus, ERPD may be safer than EUS-PD, which is associated with mild to severe AE.

Several limitations of this study must be acknowledged. First, this study was a retrospective study. Second, since this study consisted of the data from only two institutions, selection bias may have affected the results of patient characteristics and treatment choice. Third, since these data were retrospectively extracted from medical records, undescribed data were inevitable limitations.

In conclusion, we demonstrated that ERPD can be performed safely with a high technical success rate for patients with sPJS based on appropriate identification of anastomotic sites and procedural modifications. Recurrence of sPJS was more common in patients who had a pancreatic stent with no-internal-flap, which was associated with a high risk of migration. Our study suggests that pancreatic stents with internal-flap should be selected for the patients with sPJS to prevent stent migration. We also found that long-term placement of pancreatic stents did not result in occlusion or failure of stents during the follow-up period.

Materials And Methods

Patients and definition of sPJS

The registration system for national insurance reimbursement claims and discharge summaries at Toyama Prefectural Central Hospital and Saiseikai Kanazawa Hospital were searched to identify patients who presented with clinical symptoms, such as pancreatitis, exocrine pancreatic insufficiency, and glucose intolerance, between April 2014 and May 2020. Among them, patients with sPJS were defined as those who 1) underwent PD, 2) developed main pancreatic duct dilation of the remnant pancreas due to PJS based on imaging findings, 3) developed any of the clinical symptoms listed above, and 4) were referred to the department of gastroenterology for consultation. Among patients with sPJS, those who underwent ERPD were included in the analysis. The study was approved by the ethics committees of Toyama Prefectural Central Hospital (No. 58-115) and Saiseikai Kanazawa Hospital (No. R2-9), and was conducted in accordance with the ethical standards described in the latest revision of the Declaration of Helsinki. Informed consent for patient participation was received in the form of an opt-out in-hospital notice.

Clinical data

Clinical data were obtained from medical records of patients. The following characteristics of patients were evaluated: age, sex, primary disease for which the surgery was performed, surgical procedure and reconstruction method employed, causes of PJS, and symptoms of PJS.

ERPD was considered successful if 1) the anastomotic site was identified, 2) the main pancreatic duct was identified on imaging and a guidewire was placed, and 3) the anastomotic site was dilated successfully.

The degree of dilation was evaluated based on the ratio of the maximum diameter of the balloon with respect to the maximum diameter of the remnant main pancreatic duct proximal to the anastomotic site before balloon dilation. Waist disappearance was also considered in the evaluation of balloon dilation. The remaining waist was confirmed by fluoroscopy. Lastly, the type (with no-internal-flap or with internal-flap) and size of the pancreatic stents were evaluated.

Clinical success of ERPD was defined as having no recurrent sPJS during the follow-up period after ERPD. Recurrent sPJS was defined as having imaging findings of the dilation of the remnant main pancreatic duct and clinical symptoms during the follow-up period.

Lastly, the following AE associated with ERPD were examined: bleeding, and perforation due to scope insertion, and bleeding, perforation and PEP due to ERPD. The severity of these AE was graded according to the American Society for Gastrointestinal Endoscopy guidelines.[14]

Statistical analysis

The recurrence-free time after ERPD was calculated from the day of first ERPD to the date of first recurrence or the last day of the follow-up period. Cumulative recurrence was calculated using the Kaplan-Meier method and differences in the risk factors of sPJS recurrence were evaluated using the log-rank test. The following factors were examined as risk factors for sPJS recurrence: age, sex, surgical procedure and reconstruction methods employed, characteristics of the anastomotic site, and factors related to the endoscopic treatment of the anastomotic site. Specifically, the following factors related to the endoscopic treatment were examined: use of a needle knife, use of a balloon, ratio of the maximum diameter of balloon to that of the remnant main pancreatic duct, waist disappearance due to balloon dilation, presence of pancreatic calculi, pancreatic stent placement, type and size of pancreatic stent, ERPD-related AE, and pancreatic stent migration. A p-value of <0.05 was considered to be significant and all tests were two-sided. All statistical analyses were carried out using the SPSS statistical software program package (SPSS version 26.0 for Windows).

Abbreviations

PJS: pancreaticojejunal anastomotic stenosis

PD: pancreaticoduodenectomy

sPJS: symptomatic pancreaticojejunal anastomotic stenosis

ERPD: endoscopic retrograde pancreatic drainage

EUS-PD: endoscopic ultrasound-guided pancreatic duct drainage

AE: adverse events

PpPD: pylorus-preserving pancreaticoduodenectomy

SSpPD: subtotal stomach-preserving pancreaticoduodenectomy

ERP: endoscopic retrograde pancreatography

WGT: wire-guided technique

PEP: post endoscopic retrograde pancreatography pancreatitis

Declarations

ACKNOWLEDGMENTS

None.

AUTHORS' CONTRIBUTIONS

Conception and design: Kida A, Kumai T, Yano M, Arihara F, Hodo Y, Matsuda K, Ogawa K, Shirota Y, Matsuda M, Sakai A, Terada M, and Wakabayashi T. Development of methodology: Kida A, Matsuda K, Hodo Y, and Shirota Y. Acquisition of data: Kida A, Kawane T, Omura H, and Shirota Y. Analysis and interpretation of data: Kida A, and Shirota Y. Writing and review of the manuscript: Kida A, and Shirota Y. Administrative, technical, or material support: Kida A, Kumai T, Arihara F, Hodo Y, Matsuda K, and Shirota Y. Study supervision: Sakai A, Terada M, and Wakabayashi T.

ADDITIONAL INFORMATION

Conflict of interest statement: All the authors have declared that no conflict of interest exist.

Financial support statement: None to report.

Ethical statements: This study was approved by the ethics committees of Toyama Prefectural Central Hospital (No. 58-115) and Saiseikai Kanazawa Hospital (No. R2-9), and was conducted in accordance with the ethical standards described in the latest revision of the Declaration of Helsinki.

Patient consent for patient participation and publication: Informed consent for patient participation and publication was received in the form of an opt-out in-hospital notice.

Data availability statements: All data relevant to the study are included in the article.

Clinical trial register and their clinical registration number:

No. 58-115 and No. R2-9

References

1. Le Bian AZ, Cesretti M, Tabchouri N, and Fuks D. Late pancreatic anastomosis stricture following pancreaticoduodenectomy: a systematic review. *J Gastrointest Surg*. **22**, 2021-2028 (2018).
2. Itoi T, Sofuni A, Tsuchiya T, Ishii K, Ikeuchi N, and Tanaka R, et al. Initial evaluation of a new plastic pancreatic duct stent for endoscopic ultrasonography-guided placement. *Endoscopy*. **47**, 462-465 (2015).

3. Tyberg A, Sharaiha RZ, Kedia P, Kumta N, Gaidhane M, and Artifon E, et al. EUS-guided pancreatic drainage for pancreatic duct strictures after failed ERCP: a multicenter international collaborative study. *Gastrointest Endosc*. **85**, 164-169 (2017).
4. Chahal P, Baron TH, Topazian MD, Peterson BT, Levy MJ, and Gostout CJ. Endoscopic retrograde cholangiopancreatography in post-Whipple patients. **38**, 1241-1245 (2006).
5. Kikuyama M, Itoi T, Ota Y, Matsumura K, Tsuchiya T, and Itokawa F et al. Therapeutic endoscopy for stenotic pancreatodigestive tract anastomosis after pancreatoduodenectomy (with videos). *Gastrointest Endosc.* **73**, 376-382 (2011).
6. Barkay O, Sherman S, McHenry L, Yoo BM, Fogel EL, and Watkins JL et al. Therapeutic EUS assisted endoscopic retrograde pancreatography after failed pancreatic duct cannulation at ERCP. *Gastrointest Endosc.* **71**, 1166-1173 (2010).
7. Kinney TP, Li R, Gupta K, Mallery S, Hunter D, and Jensen E et al. Therapeutic pancreatic endoscopy after Whipple resection requires rendezvous access. *Endoscopy*. 41, 898-901 (2009).
8. Kida A, Shirota Y, Houdo Y, and Wakabayashi T. Endoscopic characteristics and usefulness of endoscopic dilatation of anastomotic stricture following pancreaticojejunostomy: case series and a review of the literature. *Therap Adv Gastroenterol.* **9**, 913-919 (2016).
9. Hodo Y, Shirota Y, Suda T, and Wakabayashi T. Successful EUS-guided retrograde pancreatic duct stent placement for refractory pancreaticojejunostomy stricture after pancreaticoduodenectoy with a forward-viewing echoendoscope. *Video GIE.* **3**, 196 (2018).
10. Cremer M, Deviere J, Delhaye M, Baize M, and Vandermeeren A. Stenting in severe chronic pancreatitis: results of medium-term follow-up in seventy-six patients. **23**, 171-176 (1991).
11. Smith ME, Badiga SM, Rauws EA, Tytgat GN, and Huibregtse K. Long-term results of pancreatic stents inchronic pancreatitis. *Gastrointest Endosc*. **42**, 461-467 (1995).
12. Morgan DE, Smith JK, Hawkins K, and Wilcox CM. Endoscopic stent therapy in advanced chronic pancreatitis: relationships between ductal changes, clinical response, and stent patency. *Am J Gastroenterl*. **98**, 821-826 (2003).
13. Ukita T. Pancreatic stenting for the preservation of pancreatic function in chronic pancreatitis with stricture. *Dig Endosc*. **15**, 108-112 (2003).
14. Cotton PB, Eisen GM, Aabakken L, Baron TH, Hutter MM, and Jacobson BC et al. A lexicon for endoscopic adverse events: report of an ASGE workshop. *Gastrointest Endosc.* 71, 446-454 (2010).

Tables

Table. 1 Characteristics of patients

No. of Patients	10
Age, years	64.5 (45-83)
Sex, M/F	6/4
Surgical procedure and reconstruction method employed	
PpPD with modified-Child's / Cattell's reconstruction	8/1
SSpPD with modified-Child's reconstruction	1
Etiology requiring surgery	
Pancreatic cancer	3
Intraductal papillary mucinous neoplasm	4
Biliary tract cancer	2
Papillary carcinoma of the duodenum	1
Cause of PJS	
Benign stenosis	10
Clinical symptom of sPJS	
Recurrent acute pancreatitis	8
Glucose intolerance and exocrine pancreatic insufficiency	2

Abbreviations; M: male, F: female, PpPD: pylous-preserving pancreaticoduodenectomy,

SSpPD: subtotal stomach-preserving pancreaticoduodenectomy, PJS: pancreaticojejunal anastomotic stenosis,

sPJS: symptomatic pancreaticojejunal anastomotic stenosis

Table. 2 Anastomotic site of sPJS

Successful identification of anastomotic site	10/10
Anastomotic site position by surgical procedure and reconstruction method	
PpPD and SSpPD with modified-Child's reconstruction	9
Tangent to the endoscopic view	9
PpPD with Cattell's reconstruction	1
Frontward to the endoscopic view	1
Anastomotic site characteristics	
Erosion / Pitted scars / Slit	1/6/3
Procedural modification to identify the anastomotic site	
Use of tip attachment	10
Endoscopic ultrasound with small-diameter probe	1
Contrast imaging of the remnant pancreatic duct with injection needle	3

Abbreviations; sPJS: symptomatic pancreaticojejunal anastomotic stenosis,

PpPD: pylous-preserving pancreaticoduodenectomy, SSpPD: subtotal stomach-preserving pancreaticoduodenectomy

Table. 3 ERPD

Successful ERP and placement of a guidewire	10/10
ERP and placement of a guidewire by anastomotic site characteristics	
Anastomotic site with erosion	1
Concurrent use of WGT	1
Anastomotic site with slit	3
Cannulation alone / Concurrent use of WGT	2/1
Anastomotic site with pitted scars	6
Cannulation alone / Concurrent use of WGT / Concurrent use of WGT + incision of the anastomotic site with a needle knife / Concurrent use of injection needle + WGT / Concurrent use of injection needle + WGT + incision of the anastomotic site with a needle knife	1/1/1/1/2
Successful ERPD	10/10
Dilation of the anastomotic site	10
Dilation with contrast cannula / balloon / dilator	2/7/1
Balloon dilation of the anastomotic site	7
The median ratio of diameters of balloon to that of remnant main pancreatic duct	0.86 (0.47-1.60)
Waist disappearance: yes / no	5/2
Pancreatic calculus	2
Removed: yes / no	2/0
Pancreatic stent placement	9
Type (with no-internal-flap / with internal-flap)	4/5
Size (4 / 5 / 7 Fr)	1/6/2

Abbreviations; ERPD: endoscopic retrograde pancreatic drainage, ERP: endoscopic retrograde pancreatography,

WGT: wire-guided technique

Table. 4 Recurrent sPJS after ERPD

Median follow-up since ERPD (n=10, days)	920 (137-2,223)
sPJS recurrence: yes / no	4/6
Median follow-up to sPJS recurrence (n=4, days)	540 (33-1,865)
Characteristics of sPJS recurrence (n=4)	
Anastomotic site in initial ERPD: erosion / pitted scars / slit	0/2/2
Balloon dilation in initial ERPD: yes / no	4/0
Waist disappearance by balloon dilation in initial ERPD: yes / no	2/2
Pancreatic calculus in initial ERPD: yes / no	1/3
Pancreatic stent placement in initial ERPD: yes / no	3/1
Type of pancreatic stent: with no-internal-flap / with internal-flap	3/0
Size of pancreatic stent: 4 / 5 / 7 Fr	0/2/1
Pancreatic stent migration at recurrence: yes / no	3/0

Abbreviations; sPJS: symptomatic pancreaticojejunal anastomotic stenosis, ERPD: endoscopic retrograde pancreatic drainage

Table. 5 Factors associated with sPJS recurrence

Factors associated with sPJS recurrence	*p*
Age (≥64.5 years vs <64.5 years)	0.060
Sex (male vs female)	0.752
Reconstruction method employed (modified-Child's reconstruction vs Cattell's reconstruction)	0.382
Characteristics of the anastomotic site (pitted scars vs erosion + slit)	0.998
Use of a needle knife (yes vs no)	0.936
Balloon dilation (yes vs no)	0.782
Balloon diameter (≥0.86 vs <0.86)	0.502
Waist disappearance following balloon dilation (yes vs no)	0.561
Pancreatic calculus (yes vs no)	0.157
Pancreatic stent placement (yes vs no)	0.142
Type of pancreatic stent (with no-internal-flap vs with internal-flap)	0.042
Pancreatic stent size (4 Fr□5 Fr vs 7 Fr)	0.317
ERPD-associated AE (yes vs no)	0.808
Pancreatic stent migration (yes vs no)	0.062

Abbreviations; sPJS: symptomatic pancreaticojejunal anastomotic stenosis, ERPD: endoscopic retrograde pancreatic drainage,

AE: adverse events

Figures

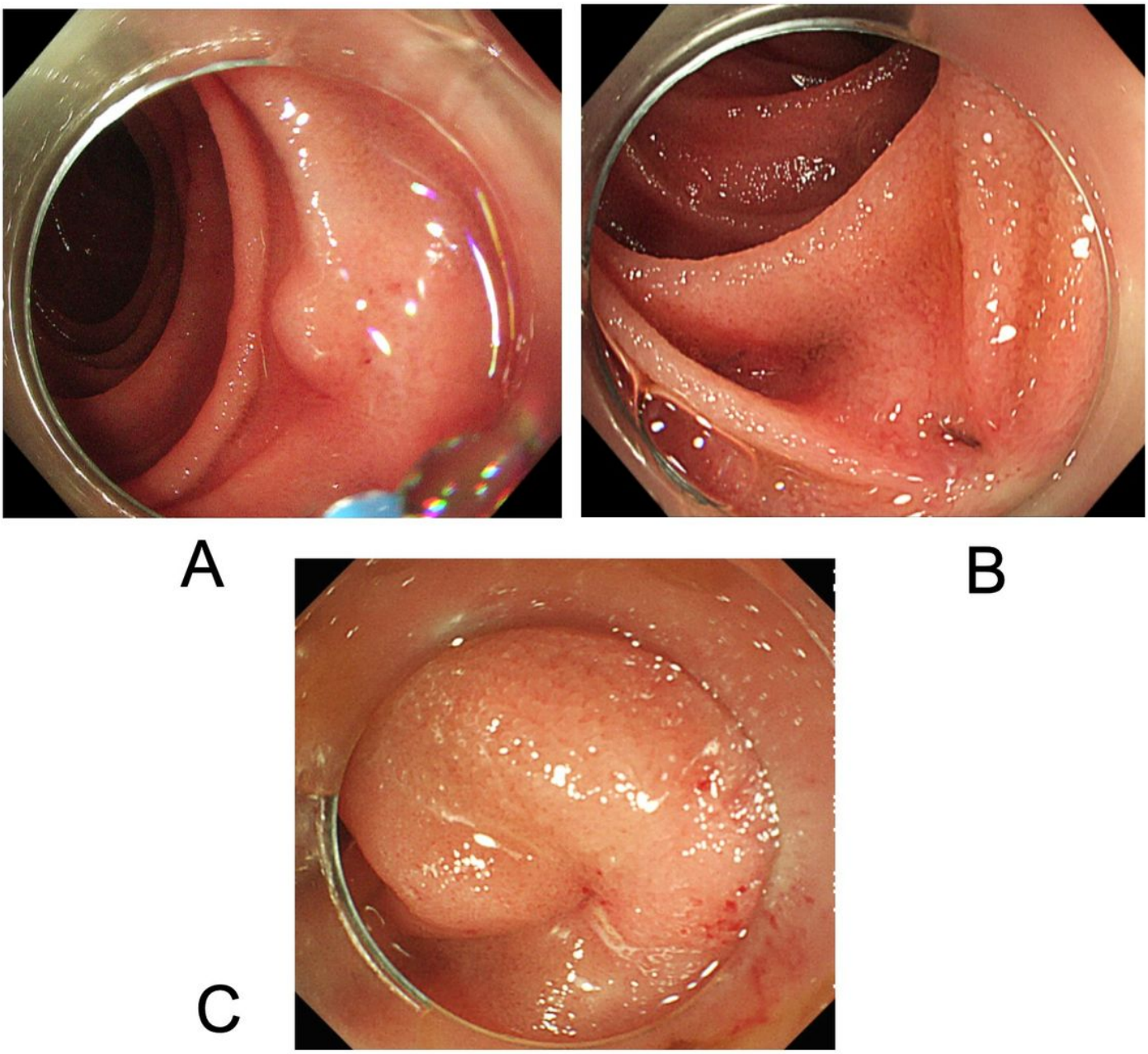

Figure 1

Endoscopic findings at the anastomotic site. A. Anastomotic site with erosion. B. Anastomotic site with slit. C. Anastomotic site with pitted scars.

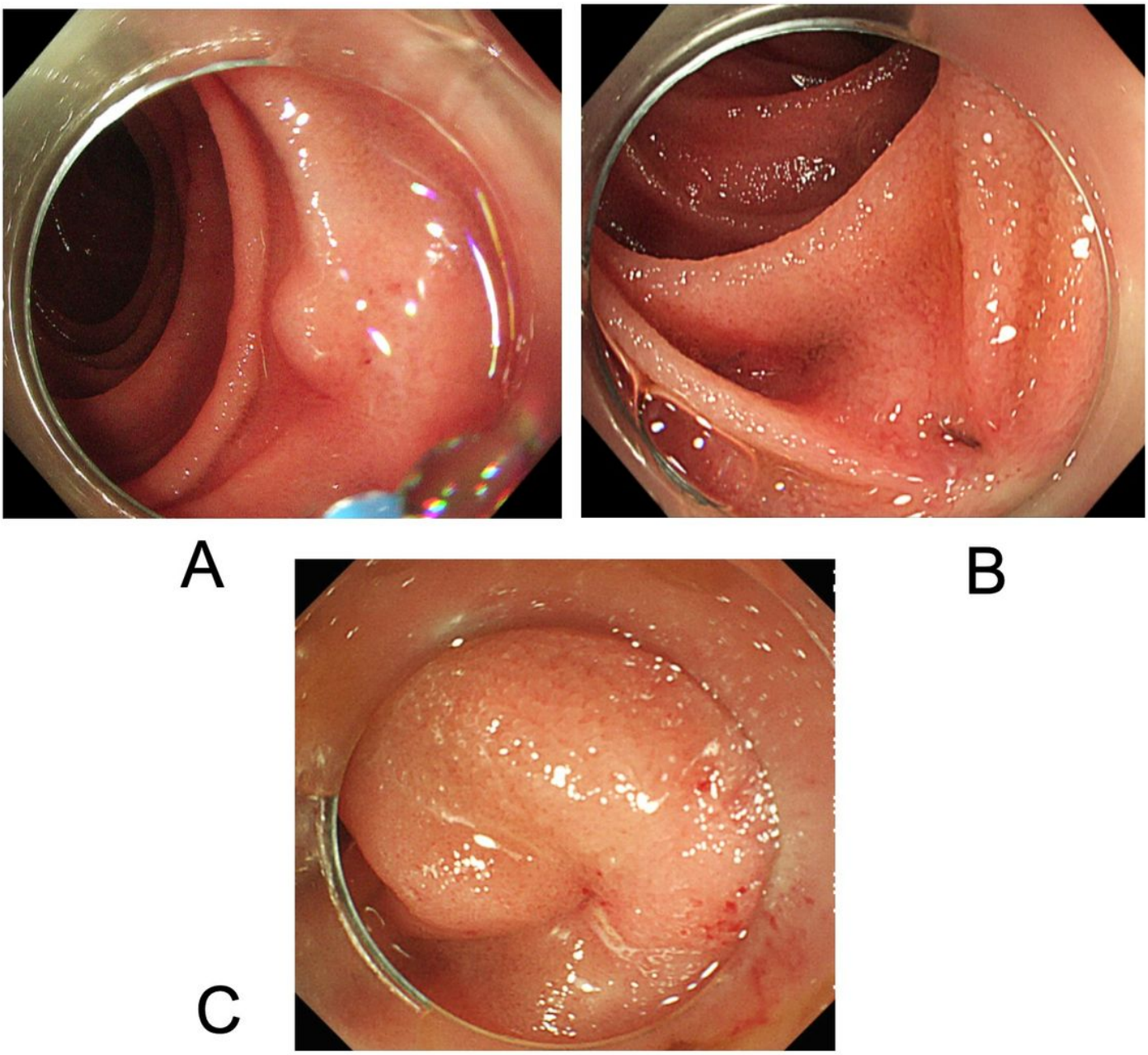

Figure 1

Endoscopic findings at the anastomotic site. A. Anastomotic site with erosion. B. Anastomotic site with slit. C. Anastomotic site with pitted scars.

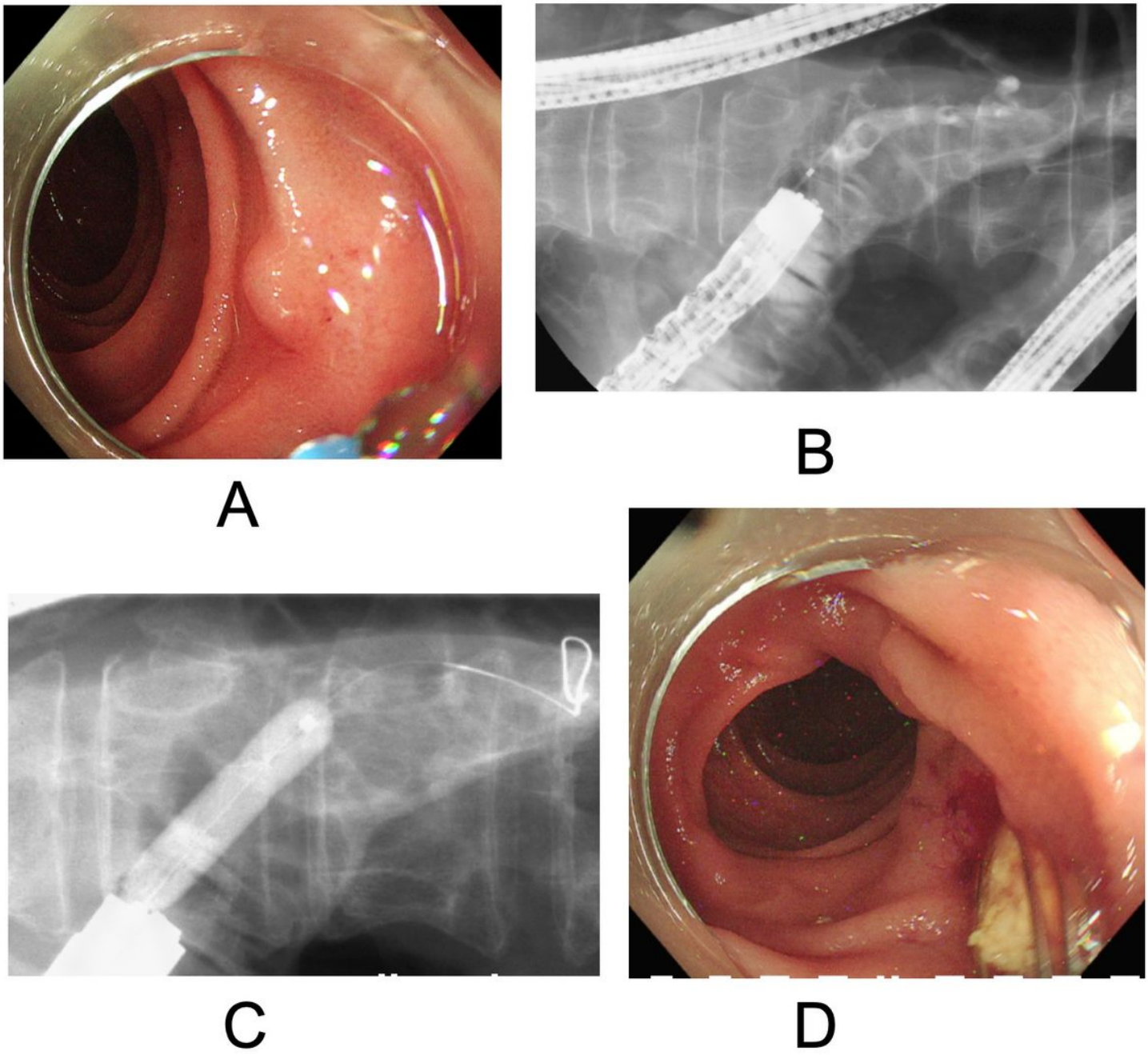

Figure 2

The procedures of endoscopic retrograde pancreatic drainage. A. Endoscopy revealed erosion at the anastomotic site. There were no apparent tumor lesions. B. Two pancreatic calculi were identified in the remnant main pancreatic duct on endoscopic retrograde pancreatography. C. Balloon dilation was performed at the anastomotic site to achieve waist disappearance. D. Pancreatic calculi were removed using baskets, and a 4 Fr x 5 cm pancreatic stent with internal-flap was placed.

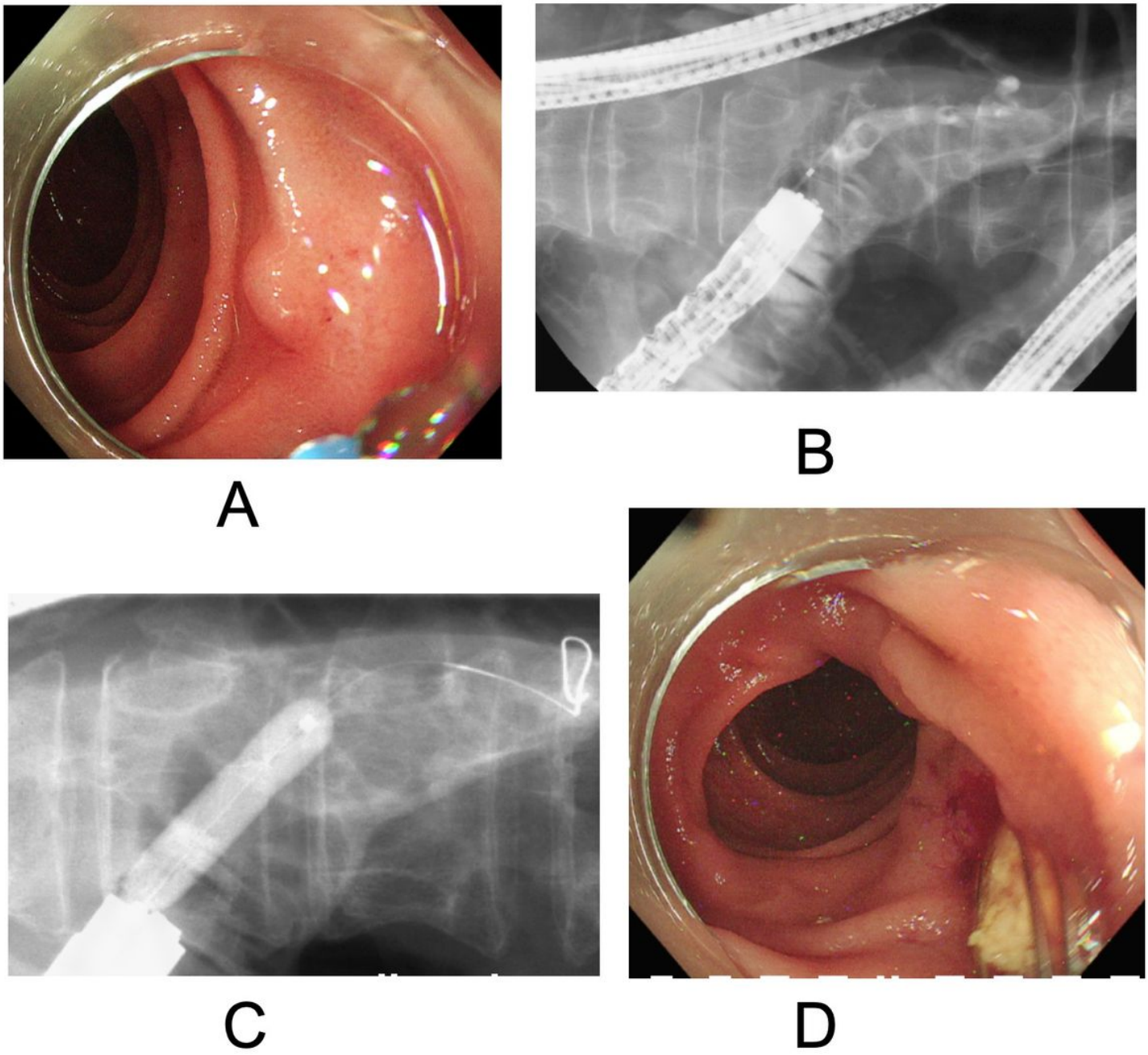

Figure 2

The procedures of endoscopic retrograde pancreatic drainage. A. Endoscopy revealed erosion at the anastomotic site. There were no apparent tumor lesions. B. Two pancreatic calculi were identified in the remnant main pancreatic duct on endoscopic retrograde pancreatography. C. Balloon dilation was performed at the anastomotic site to achieve waist disappearance. D. Pancreatic calculi were removed using baskets, and a 4 Fr x 5 cm pancreatic stent with internal-flap was placed.