Posterior Laminectomy and Lateral Mass Screw Fixation for the Treatment of Severe Cervical Spondylotic Myelopathy

Chuang Li
Orthopaedic Hospital of Union Hospital, Huazhong University of Science and Technology Wuhan

Bin Wu
Orthopaedic Hospital of Union Hospital, Huazhong University of Science and Technology Wuhan

Yongchao Wu
Orthopaedic Hospital of Union Hospital, Huazhong University of Science and Technology Wuhan

Haitao Pan
Orthopaedic Hospital of Union Hospital, Huazhong University of Science and Technology Wuhan

Qixin Zheng (zheng-qx@163.com)
Orthopaedic Hospital of Union Hospital, Huazhong University of Science and Technology Wuhan

---

Research Article

Keywords: Severe and complex cervical spondylotic myelopathy, laminectomy, lateral mass screw internal fixation, cervical spine

Posted Date: January 11th, 2022

DOI: https://doi.org/10.21203/rs.3.rs-1202516/v1

Abstract

Background

Severe and complex cervical spondylotic myelopathy(CSM) requires surgical treatment. The common methods of posterior cervical spine surgery are laminoplasty and laminectomy with lateral mass screw internal fixation. However, the operative effect of this surgical approach is unclear owing to the complexity and severity of CSM in patients who undergo this surgical treatment.Therefore, we aimed to evaluate the clinical effects of posterior cervical laminectomy and lateral mass screw internal fixation in patients with severe and complex CSM.

Methods

We retrospectively analysed 60patients (48men,12women; mean age59.7 years) with severe and complex CSM who underwent posterior cervical laminectomy and lateral mass screw internal fixation from May 2013 to June 2020. Forty-eight patients underwent laminectomy and lateral mass screw internal fixation;12 patients underwent laminectomy and lateral mass screw internal fixation with 1–2 segmental laminoplasty. C-spine radiographs, computed tomography (CT) scans, and magnetic resonance imaging (MRI) were used to detect any curvature and fusion of the cervical spine, restenosis, and loose/broken internal fixation screws.Clinical efficacy was evaluated using Japanese Orthopaedic Association (JOA)scores, neck disability index(NDI), Odom's classification, and the visual analogue scale(VAS) for pain.

Results

Overall effect was satisfactory at the last follow-up (average, 3.6 years [range, 6 months–6 years]), with no restenosis or loosened, slipped, or broken internal fixations. The anterior curvature angle of lordosis (n=46)was not significantly different from baseline at the last follow-up($P>0.05$). The cervical kyphosis angle (n=14)was significantly improved at the last follow-up compared with the baseline value ($P<0.05$), as were the JOA, NDI, and VAS scores(all $P<0.05$). Odom's classifications at the last follow-up were excellent, good, and fair in 45, 12, and three patients, respectively.

Conclusions

Posterior cervical laminectomy and lateral mass screw internal fixation achieved satisfactory clinical results in severe and complex CSM cases.Combining this surgical method with laminoplasty of 1–2 spinal segments stabilised the cervical spine and provided spinal decompression while preventing excessive backward drift of the cervical spinal cord, resulting in fewer complications.

Background

Severe and complex cervical spondylotic myelopathy(CSM) requires surgical treatment. The most common surgical approaches include the anterior, posterior, and combined anterior and posterior approaches. A specific surgical approach is chosen according to the patient's condition. An anterior approach to the cervical spine is widely used to remove anterior compressive material; however, it does not provide sufficient decompression for CSM with severe compression of the anterior and posterior long segments[1].Some patients with CSM have cervical spinal deformities or instability, requiring posterior surgery.

The common methods of posterior cervical spine surgery are laminoplasty and laminectomy with lateral mass screw internal fixation. The latter is a safer and more adequate treatment option for patients with severe, indirect, multilevel cervical cord compression. It allows for removal of the lamina and ligamentumflavum, and cervical spinal canal enlargement. The dural sac and cervical spinal cord are able to drift backward, relieving or eliminating the compression from the anterior and posterior sides of the spinal cord and achieving direct and indirect decompression [2].This procedure is used to treat CSM caused by severe complex degeneration, posterior longitudinal ligament ossification, ligamentumflavum thickening, or congenital stenosis of the cervical spinal canal. The operative effect of posterior laminectomy and lateral mass screw fixation is unclear owing to the complexity and severity of the disease in patients who undergo this surgical treatment[3].

Thus, this study aimed to evaluate the clinical effects of this surgical procedure in 60 patients with severe and complex CSM.We hypothesised that posterior laminectomy and lateral mass screw fixation (PLF) would result in favourable clinical outcomes.

Methods

Patients and study design

Data for patients with complex and severe CSM who underwent posterior cervical laminectomy and lateral mass screw internal fixation from May 2013 to June 2020 at our hospital were retrospectively reviewed.The Ethics Committee of our institution approved this study, and informed consent was obtained from the patients.

The inclusion criteria were as follows:multilevel CSM (no less than three levels) combined with instability (sigmatic vertebral translation in hyperflexion and hyperextension surgery segment>3mm or angle>11°) or deformity (kyphosis angle<20°,with mild lateral or anteroposterior displacement); severe medullary symptoms and signs, including Hoffman's sign and ankle clonus, increased muscle tone, and significant decrease in muscle strength; severe stenosis of the cervical spinal canal suggested on imaging with obvious ischaemic changes in the cervical spinal cord; posterior longitudinal ligament ossification with severe anterior and posterior compression; and contraindications for anterior or posterior laminoplasty.

Patients with severe anterior and posterior cervical compression with≥60% anterior compression requiring anterior and posterior surgeries were excluded from the study.

The patients were routinely examined using cervical spine lateral and hyperextension radiographs, three-dimensional computed tomography (CT), and cervical magnetic resonance imaging (MRI). The postoperative follow-up period ranged from 6 months to 6 years (mean 3.6 years).

Surgical methods

Laminectomy and lateral mass screw internal fixation were performed with the patient in the prone position under general anaesthesia. First, a posterior medial incision of the cervical spine was made. The fascia and paravertebral muscles were removed from the spinous process bilaterally to fully expose the lateral mass surface. Lateral mass nails were implanted in C3–7 bilaterally. A grinding drill was used to create a 3-mm wide slot in the inner lamina of the facet joint to reach the inner cortex, and a 1–2-mm thick lamina rongeur was used to bite the inner cortex to complete the slot. Kocher forceps were used to clamp the spinous process and carefully lift the entire lamina from the spinal canal. The lamina was moved to either side, and lamina forceps were used to bite the ligamentumflavum to ensure complete separation from the dural sac. Complete removal of the lamina exposed the sides of the dural sac and entire surface of the facet joints.If the patient had nerve root-type symptoms, foraminal incision decompression was performed. The connecting rod and horizontal connections were installed.C-arm fluoroscopy was used to confirm the ideal position of the internal fixation. Bone granules were implanted bilaterally on the surfaces of the spine to promote bone fusion.All operations were performed by the same surgeon.

Modified surgery

Laminectomy and lateral mass screw internal fixation were combined with 1–2 level laminoplasty to prevent excessive cervical spine drift. The C5 and upper or lower segment were used for the laminoplasty. If the patient had severe neurological symptoms, laminoplasty was approached on the symptomatic side. A drill was used to grind the outer cortex and create a groove at the transition of the lamina and lateral mass. After thinning, the rongeur was used to bite the inner cortex and simultaneously open a door. The lateral ligamentumflavum was completely loosened and separated. A grinding drill was used on the side of the portal axis to grind off the outer cortex at the junction of the lamina and the lateral mass to form a hinge. The lamina was gently opened at the door until the laminectomy was completed, and the width of the door was12–14mm.A curved-arch titanium plate (Synthes, GmbH,Switzerland) was fixed to both ends of the door. Bone granules were implanted in the hinge area to promote bone fusion and form a permanent spinal canal.All operations were performed by the same surgeon.

Postoperative treatment

Antibiotics, mannitol, dexamethasone, nebulised inhalation medications, and other symptomatic therapies were administered to the patients for the first 3–5 days postoperatively. The drainage tube was removed on postoperative day 3–5, and patients were encouraged to ambulate by postoperative day 3–5.

Patients wore an immobilising cervical brace for 6 weeks. Cervical spine radiographs and MR images were obtained6 weeks postoperatively.

Effect analysis

Imaging evaluations

Cobb's angle was measured on lateral radiographs of the cervical spine. A positive value indicated lordosis, and a negative value indicated kyphosis. The preoperative and postoperative angles were compared.

Cervical MRI

Cervical MR images were used to detect the degree of backward drift of the cervical spinal cord, recompression, and obstruction of the cerebrospinal fluid.

Evaluation of clinical efficacy

The Japanese Orthopaedic Association (JOA)scores at baseline and final follow-up were compared to evaluate the improvement in neurological symptoms, the visual analogue scale (VAS) was used to evaluate pain severity, and the cervical neck disability index (NDI) was used to assess the degree of cervical dysfunction.Odom's classification was used to evaluate the comprehensive clinical efficacy at the last follow-up. The clinical efficacy was classified as follows:*excellent* in patients whose preoperative symptoms disappeared completely and whose daily lives were no longer affected by their condition, *good* in patients whose preoperative symptoms were significantly relieved with no obvious limitations in daily life, *general* in patients whose preoperative symptoms were partially relieved and whose daily lives were partially limited, and *poor* in patients whose preoperative symptoms did not improve or worsened.

Postoperative complications

The following postoperative complications were evaluated: fusion of the surgical segments, restenosis, loosened or broken internal fixations, cerebrospinal fluid leakage, incision infection, allergic reactions to implant materials, and vascular, nerve, or spinal injuries.

Statistical methods

All analyses were performed with SPSS version 20.0 statistical software (IBM Inc., Chicago, IL, USA). Statistical significance was set at $P<0.05$. Data are expressed as mean ± standard deviation. The baseline and final cervical physiological curvatures, JOA scores, VAS scores, and NDI scores were compared using the intra-group t-test.

Results

In the 60patients included in this study(Table 1), there were no reports of vascular, nerve, or spinal injuries, cerebrospinal fluid leakage, infection, allergies to implant materials, restenosis, loosening or breakage of

the internal fixation, compression of the spinal cord, or obstructed cerebrospinal fluid.

Table 1. General characteristics of the patient groups

	PLF group (n□60)
Sex(M/F)	48/12
Age, years (range)	59.7 (36-76)
Type of cervical spondylosis	
Instability	36
Kyphosis	14
Ossification of the posterior longitudinal ligament	10
Operated level	
C3–7	40
C4–7	8
C3–6	12
Operative method	
PLF	48
Modified	12
F/U period, years	3.6 0.5-6

Abbreviations: PLF, posterior lumbar fusion; F/U, follow-up; M, male; F, female

Among the46patients with cervical lordosis, the lordosis angle at the last follow-up was not significantly different compared to the angle at baseline(P>0.05). Among the 14 patients with cervical kyphosis, the kyphosis angle was significantly improved at the last follow-up compared with the angle at baseline (P<0.05) (Table 2). The JOA, NDI, and VAS scores were significantly improved at the last follow-up compared with the baseline scores (all P<0.05) (Table 3). According to Odom's classification, the clinical efficacy at the last follow-up was excellent in 45patients, good in 12patients, and general in three

patients. No patients had poor clinical efficacy. Overall, 95% of the patients achieved excellent or good clinical efficacy.

Table 2. Cervical angle measurements

	Cervical lordosis(n=46)	Cervical kyphosis(n=14)
Preoperative	20.83°±2.67°	9.42°±1.80°
Last follow-up	19.17°±2.44°	3.25°±1.64°
Significance	P>0.05	P<0.05

Table 3. Neurological function scores

	JOA	VAS	NDI
Preoperative	9.90±2.44	5.40±0.78	20.13±4.15
Last follow-up	14.90±1.73	0.70±0.46	8.94±3.27
Significance	P<0.05	P<0.05	P<0.05

Abbreviations: JOA, Japanese Orthopaedic Association; VAS, visual analogue scale; NDI,neck disability index

Two patients experienced mild posterior cervical axial pain that resolved over the course of 3 months. Unilateral C5 nerve palsy occurred in three patients and resolved after a few weeks. Two patients with limb muscle weakness required medication and rehabilitation. One patient experienced limb muscle loss due to a fall, which occurred 1monthpostoperatively and recovered after several months. None of the 12patients who underwent laminectomy and lateral mass screw fixation combined with 1–2 level laminoplasty developed C5 palsy.

Discussion

In this study, 95% of the patients had excellent or good clinical efficacy, and the JOA, VAS, and NDI scores at the last follow-up were all significantly improved compared with those recorded preoperatively. No cervical MR images revealed cervical spinal cord compression or cerebrospinal fluid obstruction. No loosening, withdrawal, or fractures were observed at the site of the internal fixation. In this study, patients with cervical kyphosis had significantly improved cervical spine curvature at the last follow-up than at baseline, indicating that laminectomy with lateral mass screw internal fixation with or without laminoplasty can significantly improve cervical kyphosis. In contrast, patients with cervical lordosis did not have significantly different cervical spine curvature at the last follow-up compared with that at

baseline, indicating that laminectomy with lateral mass screw internal fixation with or without laminoplasty is able to maintain the physiological curvature of the cervical spine (Fig. 1).

Laminoplasty and laminectomy with lateral mass screw internal fixation are two surgical options that use a posterior approach to treat CSM. Each surgery has different indications: laminoplasty is indicated for patients with developmental cervical spinal stenosis, cervical disc herniation, and more than three segments of ossification of the posterior longitudinal ligament; laminectomy with lateral mass screw internal fixation is indicated for patients with CSM and long-segment compression, severe compression, cervical instability, or cervical deformity. Laminectomy with lateral mass screw internal fixation has a higher incidence of C5 nerve palsy than laminoplasty, as an excessive backward drift of the cervical spinal cord is not prevented. While axial pain is more common in patients who undergo laminoplasty due to the stability of laminectomy with lateral mass screw internal fixation, laminoplasty results in a greater range of motion of the cervical spine. Previous studies observed no significant difference in the effectiveness of the recovery of neurological function between the two surgical methods [4, 5]; however, recurrent nerve compression injuries are more common after laminoplasty, as this surgical method results in a less stable cervical spine [6].

Laminectomy with lateral mass screw internal fixation has replaced the previous simple posterior cervical laminectomy procedure and is widely used to treat multi-segment CSM or posterior longitudinal ligament ossification. A simple laminectomy leads to a significant increase in the incidence of postoperative kyphosis. Laminectomy with lateral mass screw internal fixation stabilises the cervical spine to prevent complications, including cervical kyphosis [7]. The latter also provides good stability of the cervical spine to prevent the progression or recurrence of lesions at the surgical segment and allows surgeons to correct mild, rigid cervical kyphosis to restore the physiological curvature of the cervical spine. The operation is relatively safe, and intervertebral disc-osteophyte complexes can be reduced postoperatively to reduce anterior compression [8]. Compared with laminoplasty, laminectomy with lateral mass screw internal fixation delays the progression of ossification of the posterior longitudinal ligament (OPLL) [9].However, laminectomy with lateral mass screw internal fixation can lead to posterior cervical axial symptoms, which are mainly caused by the imbalance of the muscles of the posterior neck, adhesions, scar compression, and excessive cervical spinal cord drift. This procedure may also result in C5 nerve palsy (excessive traction caused by drift of the dural sac and cervical spinal cord, especially in the presence of nerve root canal stenosis), cervical spinal cord drift, and unstable activity. Delayed and excessive cervical spinal cord drift can lead to injuries, especially in patients with existing cervical spinal cord disease [10].

The risk of C5 nerve palsy after laminectomy with lateral mass screw internal fixation can be reduced by using a precise surgical protocol, including precise laminectomy widths (not to exceed the width of the spinal cord by >2–3 mm or the width of the dural sac) to limit the drift of the dural sac [11].Identifying risk factors to predict complications is also necessary. C5 nerve traction paralysis has been associated with the presence of C4–5 intervertebral foraminal stenosis, and preventive decompression of the intervertebral foraminal area can help expand the nerve root canal space [12].

Improvements to the surgical methods of laminectomy with lateral mass screw internal fixation can help reduce the complication rate. Therefore, we combined laminectomy with lateral mass screw internal fixation with laminoplasty of 1–2 spinal segments to prevent excessive cervical spinal cord drift. A previous study reported that laminectomy and internal fixation were performed at the same time as selective blocking, single-doorlaminoplastiesin1–2 spinal segments [13].The spinous processes were suspended with the lateral mass screw with a thread in this previous study. Our results indicate that the selective blocking of laminoplasty combined with laminectomy with lateral mass screw internal fixation can prevent excessive backward drift of the cervical spinal cord, thereby significantly reducing the incidence of postoperative C5 paralysis and cervical spinal cord injuries. Inpatients with severe anterior and posterior compression and an anterior occupancy≤60%, the volume of the corresponding segment of the spinal canal can be controlled by adjusting the width of the blocking plate to open the door, thereby preventing excessive posterior drift of the cervical spinal cord. None of the 12 patients who underwent laminectomy and lateral mass screw fixation combined with 1–2 level laminoplasty developed C5 palsy(Fig. 2).

The surgical method used to treat severe and complex CSM is important. In routine cases, the operative method is selected according to the operative indications. Laminectomy with lateral mass screw fixation is the first choice for patients with severe symptoms or injuries to the cervical spinal cord or canal space. Decompression results in a significantly increased spinal canal space and good cervical spine stability, and the procedure is relatively safe. After laminectomy with lateral mass screw internal fixation, the compression in patients with severe anterior and posterior compression cannot change, as the cervical spine has been stabilised. Therefore, anterior surgery is not required. No patients in this study required anterior surgery.

Laminectomy with lateral mass screw internal fixation can also correct mild kyphosis with some mobility (kyphosis angle <20°). The K-line, the straight line connecting the midpoint of the spinal canal from C2 to C7, is often utilised in clinical practice and can be used as a reference index for the indication of posterior cervical surgery. When the OPLL range does not exceed the K-line on a standard lateral radiograph, the K-line is positive, and posterior decompression surgery is indicated. When the OPLL range exceeds the K-line on a standard lateral radiograph, the K-line is negative, indicating insufficient spinal cord drift. When the spinal canal invasion rate is≥60%, anterior surgery is indicated. However, when the K-line is positive and the spinal canal invasion rate is≥60%, posterior decompression is not contraindicated [14].Two main factors affect the K-line: cervical spine curvature and spinal canal pressure. Changes in these factors affect the selection of surgical method. We believe that the curvature of the cervical spine can be changed to affect the K-line to indicate posterior surgery, which is safer and more effective than anterior surgery. When the cervical kyphosis is >10°–13°, it affects the drift of the cervical spinal cord, and posterior surgery is not indicated. The cervical spine is generally unstable in these patients, and the kyphotic deformity of the cervical spine can be corrected through fixation with side mass screws (Fig. 3).

This study has notable limitations. First, the sample size of the follow-up cases was small. Second, the follow-up time was insufficient. Further follow-up is needed to verify procedural efficacy.

Conclusions

In conclusion, several surgical methods can be used to treat CSM. Posterior cervical laminectomy combined with lateral mass screw fixation has excellent clinical efficacy. Combining this surgical method with laminoplasty of 1–2 spinal segments stabilises the cervical spine and spinal decompression while preventing excessive backward drift of the cervical spinal cord, resulting in fewer complications.

List Of Abbreviations

CSM: cervical spondylotic myelopathy

CT: computed tomography

JOA: Japanese Orthopaedic Association

MRI: magnetic resonance imaging

NDI: neck disability index

OPLL: ossification of the posterior longitudinal ligament

VAS: visual analogue scale

Declarations

We declare that experimental research on humans or the use of human tissues comply with international guidelines. We confirm that all methods were carried out in accordance with relevant guidelines and regulations.

Ethics approval and Consent to Participate: The Ethics Committee of of Union Hospital, Tongji Medical College, Huazhong University of Science and Technology approved this study. Informed consent was obtained from the patients.

Consent for publication: Written informed consent for publication was obtained from all participants.

Availability of data and materials: The data sets supporting the results of this article are included within the article and its additional files.

Competing Interests: The authors declare that they have no competing interests. I declare that the authors have no competing interests as defined by BMC, or other interests that might be perceived to influence the results and/or discussion reported in this paper.

Funding: Not applicable

Authors' contributions: First author is Chuang Li Corresponding author is Qixin Zheng. CL, BW, and QXZ developed the idea of the study, participated in its design and coordination and helped to draft the manuscript. YCW and HTP contributed to the acquisition and interpretation of data.QXZ provided critical review and substantially revised the manuscript. All authors read and approved the final manuscript.

Acknowledgment Not applicable

Author's Information First author:Chuang Li 8613554221397 862785351626 lc3820292@163.com

Second author:Bin Wu 8617771818099 862785351626 tougao2004@163.com

Third autho: Yongchao Wu 8613886046105 862785351626 prof_wu @163.com

Fourth author:Haitao Pan 8615994276638 862785351626 phtsuperman@163.com

Corresponding author:Qixin Zheng 8613507138613 862785351626 zheng-qx@163.com

References

1. Sasso RC, Ruggiero RA Jr, Reilly TM, Hall PV. Early reconstruction failures after multilevel cervical corpectomy. Spine (Phila Pa 1976) 2003;28:140–2. DOI: 10.1097/00007632-200301150-00009
2. Robinson RA, Smith GW. Anterolateral cervical disc removal and interbody fusion for cervical disc syndrome.SAS J2010;4:34–5. DOI: 10.1016/j.esas.2010.01.003
3. Bhalla A, Rolfe KW.Inadequate surgical decompression in patients with cervical myelopathy: a retrospective review. Glob Spine J2016;6:542–7. DOI: 10.1055/s-0035-1569463
4. Deora H,Kim SH,Behari S, Rudrappa S, Rajshekhar V, Zileli M, ParthibanJKBC. Anterior surgical techniques for cervical spondylotic myelopathy:WFNS spine committee recommendations.Neurospine2019;16:408–20. DOI: 10.14245/ns.1938250.125
5. Phan K, Scherman DB, Xu J, Leung V, Virk S, Mobbs RJ. Laminectomy and fusion vs laminoplasty for multi-level cervical myelopathy: a systematic review and meta-analysis.Eur Spine J2017;26:94–103. DOI: 10.1007/s00586-016-4671-5
6. Blizzard DJ, Caputo AM, Sheets CZ,Klement MR, Michael KW, Isaacs RE, Brown CR. Laminoplasty versus laminectomy with fusion for the treatment of spondylotic cervical myelopathy: short-term follow-up. Eur Spine J2017;26:85–93. DOI: 10.1007/s00586-016-4746-3
7. Rodriguez-FeoJA,Leas D,Odum SM, Angerame M, Kurd M, Darden BV, Milam RA. Reoperation rates following open-door cervical laminoplasty. IntJ Spine Surg2018;12:751–6. DOI: 10.14444/5094
8. Boniello A,Petrucelli P,Kerbel Y, Horn S, Bortz CA, Brown AE, PierceKE, Alas H, Khalsa A, Passias P. Short-term outcomes following cervical laminoplasty and decompression and fusion with instrumentation. Spine(Phila Pa 1976)2019;44:E1018-23. DOI: 10.1097/BRS.0000000000003057
9. AjiboyeRM, Zoller SD, Ashana AA, Sharma A, Sheppard W, Holly LT. Regression of disc-osteophyte complexes following laminoplasty versus laminectomy with fusion for cervical

spondyloticmyelopathy. Int J Spine Surg2017;11:17. DOI: 10.14444/4017

10. Lee JJ, Shin DA, Yi S, Kim KN, Yoon DH, Shin HC, Ha Y. Effect of posterior instrumented fusion on three-dimensional volumetric growth of cervical ossification of the posterior longitudinal ligament: a multiple regression analysis. Spine J2018;18:1779–86. DOI: 10.1016/j.spinee.2018.03.002
11. Nori S, Aoyama R, Ninomiya K, Yamane J, Kitamura K, Ueda S, Shiraishi T. Cervical laminectomy of limited width prevents postoperative C5 palsy: a multivariate analysis of 263 muscle-preserving posterior decompression cases. Eur Spine J2017;26:2393–403. DOI: 10.1007/s00586-017-5202-8
12. Kang KC, Suk KS, Kim HS, Moon SH, Lee HM, SeoJH, Kim SM, Jin SY, Mella P. Preoperative risk factors of C5 nerve root palsy after laminectomy and fusion in patients with cervical myelopathy: analysis of 70 consecutive patients. Clin Spine Surg2017;30:419–24. DOI: 10.1097/BSD.0000000000000505
13. Kim GU,Lee GW.Selective blocking laminoplasty in cervical laminectomy and fusion to prevent postoperative C5 palsy.Spine J2019;19:617–23. DOI: 10.1016/j.spinee.2018.11.001
14. Fujiyoshi T,Yamazaki M,Kawabe J, Endo T, Furuya T, Koda M, Okawa A, Takahashi K, Konishi H. A new concept for making decisions regarding the surgical approach for cervical ossification of the posterior longitudinal ligament:the K-line.Spine(Phila Pa 1976)2008;33:E990-3. DOI: 10.1097/BRS.0b013e318188b300

Figures

Figure 1

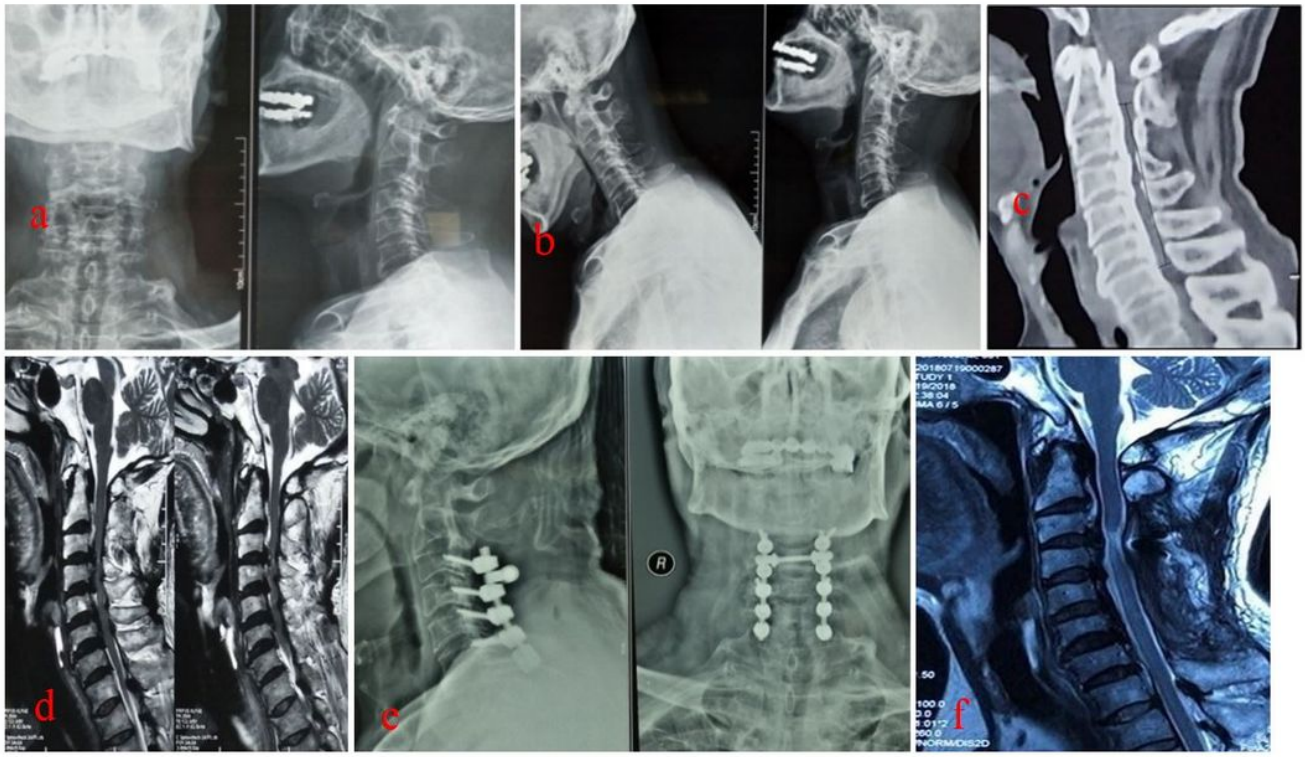

Figure 1

Posterior laminectomy and lateral mass screw fixation

A 65-year-old man with cervical spondylotic myelopathy with incomplete paralysis and ossification of the posterior longitudinal ligament underwent C3–7 laminectomy and lateral mass screw internal fixation and fusion. (**a**)Preoperative radiograph: good physiology of the cervical spine.(**b**) Preoperative cervical spine radiograph: no obvious instabilities. (**c**) Intraoperative CT of the anterior cervical spine:extensive ossification of the posterior longitudinal ligament. (**d**)Preoperative cervical MRI:multi-segment cervical spinal cord compression and ischaemic changes. (**e**) Lateral cervical spine radiograph obtained 1week postoperatively:good internal fixation position. (**f**) Cervical MRI:uncompressed cervical spinal cord and unobstructed cerebrospinal fluid 2 years postoperatively.

Figure 2

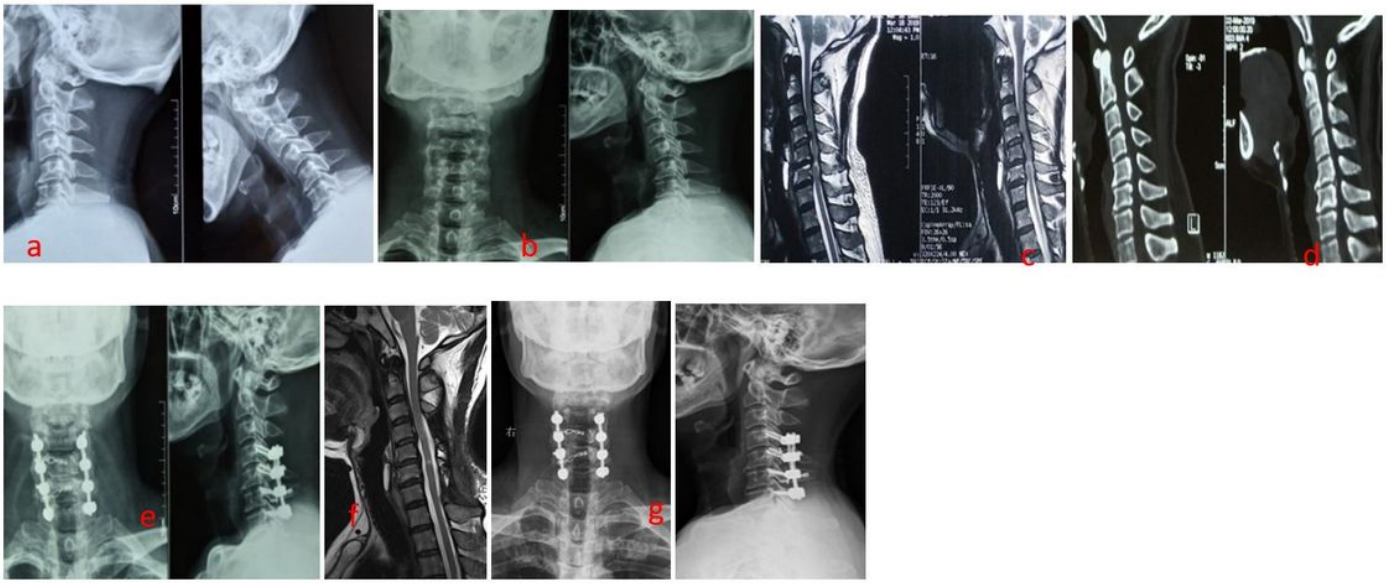

Figure 2

Laminectomy and lateral mass screw internal fixation combined with 1–2 level laminoplasty

A 51-year-old man with cervical spondylotic myelopathy with incomplete paralysis underwent C4–7 lateral mass screw internal fixation and fusion, C4 and C7 laminectomy, andC5 and C6 laminoplasty.(**a**) Preoperative dynamic cervical spine radiograph: cervical spine instability.(**b**) Preoperative cervical spine lateral radiograph:mild kyphosis.(**c**) Preoperative cervical MRI: multi-segment disc herniation and ischaemic changes in the cervical spinal cord. (**d**) Preoperative CT of the cervical spine:no obvious ossification of the posterior longitudinal ligament.(**e**) Lateral cervical spine radiograph 1week postoperatively:the cervical kyphosis is corrected. (**f**) Cervical spine MRI 2 years postoperatively:the

cervical spinal cord is not compressed, and the cerebrospinal fluid is unobstructed. (**g**)Cervical spine radiograph 2 years postoperatively:favourable positioning of the internal fixation with no kyphosis.

Figure 3

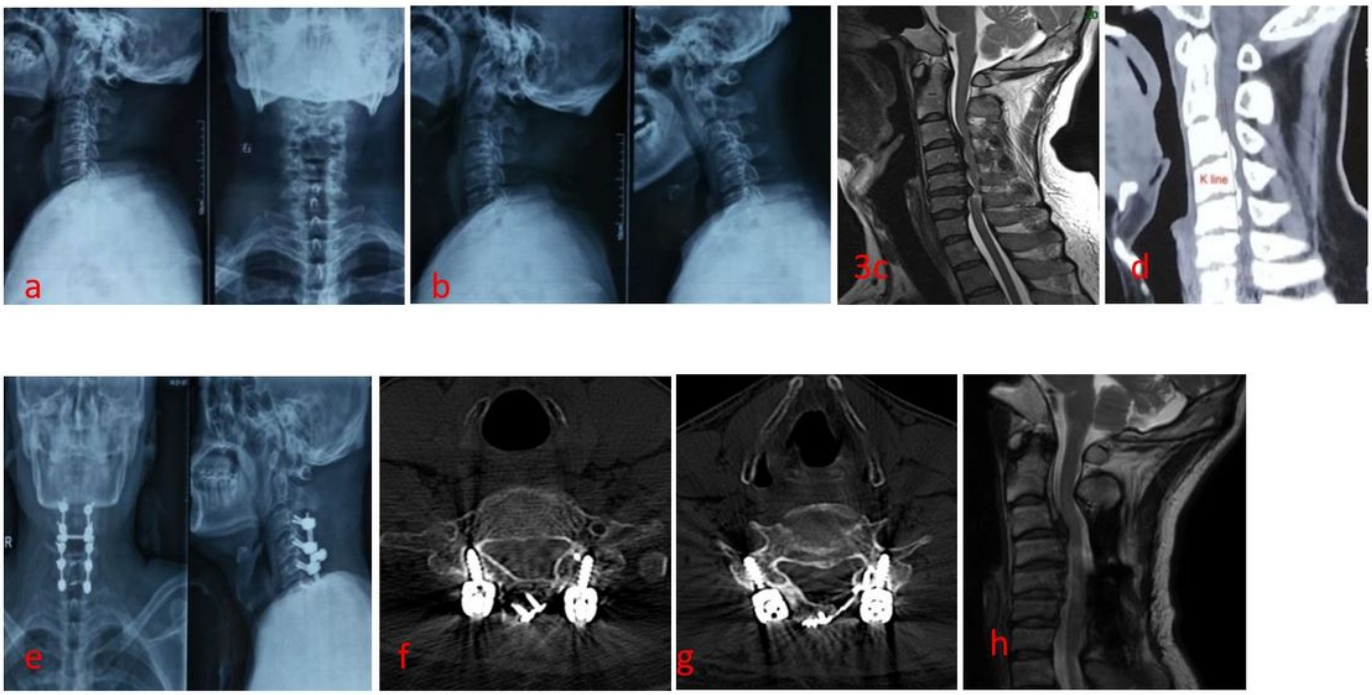

Figure 3

Laminectomy and lateral mass screw internal fixation were combined with 1–2 level laminoplasty

A 36-year-old man with cervical spondylotic myelopathy with incomplete paralysis, ossification of the posterior longitudinal ligament of the cervical spine, and cervical kyphosis underwent C3–7 lateral mass screw internal fixation and fusion; C3, C4, and C5 total laminectomy; and C6-7laminoplasty. (**a**)Preoperative cervical spine radiograph: mild cervical kyphosis.(**b**)Preoperative dynamic cervical spine radiograph: cervical spine instability. (**c**) Preoperative cervical spine MRI:multiple sites of cervical spinal cord compression. No ischaemic changes were noted in the cervical spinal cord. (**d**) Preoperative cervical CT:ossification of the posterior longitudinal ligament with a negative K-line. (**e**) Cervical spine radiograph 2 years postoperatively:cervical kyphosis is corrected. (**f, g**) The lateral mass screw is located at C6 and C7 at 2 years postoperatively.(**h**)Cervical MRI 2 years postoperatively:no compression of the cervical spinal cord and no obstruction of the cerebrospinal fluid.