Different Surgical Options for the Management of Intracranial Arachnoid Cysts

Sait Kayhan
Republic of Turkey Ministry of Health: Turkiye Cumhuriyeti Saglik Bakanligi

Adem Doğan (dradem dogan@yahoo.com)
Republic of Turkey Ministry of Health: Turkiye Cumhuriyeti Saglik Bakanligi https://orcid.org/0000-0003-0933-6072

Research Article

Keywords: Arachnoid cyst, Surgery, Endoscopy, Fenestration

Posted Date: March 15th, 2022

DOI: https://doi.org/10.21203/rs.3.rs-1210965/v1

Abstract

Background: The aims of this study are to present our results and determine the most effective method on the surgical treatment of intracranial arachnoid cysts.

Methods: The data of 44 patients who underwent surgical treatment for intracranial arachnoid cyst between 2011 and 2019 were retrospectively reviewed. Age, gender, location of the cyst, clinical presentation, surgical technique and outcomes of patients were recorded and analyzed. The results were compared statistically.

Results: Among the 44 patients, 36 were male and 8 were female with a mean age of 19.77 years. Twelve patients were children and 32 were adults. Signs of increased intracranial pressure were observed in 35 patients and epilepsy in 9 patients. The most frequent locations were temporal, frontotemporal and frontoparietal regions. Cyst fenestration was used in 34 patients while, cystoperitoneal shunt+fenestration in 8 and only shunt in 2 patients. Subdural effusion was seen in 5 patients and wound dehiscence in 6 patients after surgery. Forty patients were improved after surgery while 4 patients remained symptomatic during the follow-up period.

Conclusions: Cyst fenestration is the most effective treatment method for intracranial arachnoid cysts. It may be performed using either microscopic or endoscopic technique. Re-closure of the fenestration is the main problem especially when performed in young children.

Introduction

Arachnoid cysts are benign and mostly asymptomatic intracranial lesions. They are generally accepted as congenital cysts but may also develop in childhood and the adulthood [1]. There are several theories on the development of arachnoid cysts such as ball-valve mechanism, osmotic gradient between the intra- and extracystic space, and fluid hypersecretion by the lining cells of the cyst wall. But no concensus has been reached on the exact pathophysiology of these benign lesions [2].

Although arachnoid cysts are mainly diagnosed incidentally, headache and seizure are most frequent symptoms of arachnoid cysts. A computed tomography (CT) scan after a mild head trauma may reveal an arachnoid cyst. It is usually sufficient for the identification of an intracranial cyst. But, magnetic resonance imaging (MRI) is the gold standard for the accurate diagnosis of arachnoid cysts [3]. MRI can reveal the exact location, extent, and relationship of the arachnoid cyst. It can also differentiate arachnoid from epidermoid tumors and other intracranial lesions. Porencephalic cysts, encephalomalasia, hydatic cysts, and epidermoid tumors are in the differential diagnosis of arachnoid cysts [4]. Fluid-attenuated inversion recovery (FLAIR) as well as diffusion weighted sequences of MRI are used to differentiate these lesions from arachnoid cysts [2, 5]. Although arachnoid cysts may develop in any part of the brain, they are usually located in the temporal lobe, suprasellar region and posterior fossa. Sylvian fissure is the most common location for intracranial arachnoid cysts [6].

Follow-up is the main strategy on the management arachnoid cysts which are incidentally diagnosed. But in cases of epilepsy, subdural hematoma, intracystic hemorrhage, neurological deficit or increased intracranial pressure, surgical treatment should be performed as soon as possible [7]. Bony scalloping may indicate the presence of an arachnoid cyst, especially in children. Currently, there are 3 different surgical methods for the treatment of arachnoid cysts. First is the microsurgical removal of cyst walls and fenestration with subarachnoid (or basal) cisterns, second is the endoscopic fenestration of arachnoid cysts and the third is cystoperitoneal shunt application [6, 8]. Each approach has its own advantages and disadvantages and selection of the approach depends on the patient's clinical and radiological characteristics and surgeon's experience.

The aim of this study is to present our experience on the surgical treatment of arachnoid cysts with different techniques and to discuss the surgical options in the light of current literature.

Methods

Approval was obtained for the study from a local ethics committee (30.06.2020/298).

The data of 44 patients who underwent surgical treatment between 2011 and 2019 for intracranial arachnoid cyst were retrospectively reviewed. Ethical approval for this study was obtained from the ethics committee of our institution.

The patients were identified from a prospectively collected data base of our department and their medical records were retrospectively analyzed. The data on basic demographics, signs and symptoms at admission, and surgical details were collected.

Patients who had the symptoms or signs of increased intracranial pressure or epilepsy underwent surgical treatment. Three different surgical techniques were used in 44 patients. Cystoperitoneal shunt, cyst fenestration (endoscopic or microsurgical) (Figs. 1 and 2) and combined techniques (fenestration+shunt) (Figs. 3 and 4) were performed based on the clinical and radiological characteristics of patients.

Theclinical and radiological outcome at discharge was also recorded. The patients were followed-up radiologically and clinically after the discharge. The mean follow-up period of patients was 10.8 months (ranged between 3 and 25 months). The periods of postoperative radiological examinations were between 3 and 6 months. After the first year, annual scans were performed to detect cyst recurrence or enlargement. CT and MRI were used for the diagnosis and follow-up of patients with arachnoid cyst.

SPSS 20.0 for Windows was used for statistical analysis. The surgical groups were compared statistically using t-test and Kruskall-Wallis test. P value less than 0.05 was accepted as statistically significant.

Results

A total of 44 patients underwent surgical treatment for intracranial arachnoid cyst over a 9-years period. Thirty-six (81.8%) patients were male and 8 were female witha mean age of 19.77 years (ranged between 1 and 67 years). Twelve (27.3%) patients were children (younger than 18 years) and 32 patients were adults. Most frequent cyst locations were; temporal lobe in 19 (43.2%) patients, followed by frontoparietal region (n=7), frontotemporal region (n=6), posterior fossa (n=6), parietal lobe (n=3), frontal lobe (n=2) and suprasellar region (n=1) (Table 1).

Table 1
Demographic features of patients, cyst locations and surgical techniques.

		Mean±SD	Min-Max	Test/p
Age (Years)		19.77±12.73	1-67	10.298/0.001[t]
		n	**%**	
Sex	Male	36	81.8	20.093/0.001[t]
	Female	8	18.2	
Surgical Side	Left	19	43.2	17.694/0.001[t]
	Right	22	50.0	
	Midline	3	6.8	
Location	Temporal	19	43.2	
	Frontoparietal	7	15.9	
	Frontotemporal	6	13.6	
	Cerebellar	6	13.6	7.872/0.001[t]
	Parietal	3	6.8	
	Frontal	2	4.5	
	Suprasellar	1	2.3	
Shunt	Yes	10	22.7	27.739/0.001[t]
	No	34	77.3	
Surgical Technique	Fenestration	34	77.3	15.518/0.001[t]
	Fenestration+Shunt	8	18.2	
	Shunt Alone	2	4.5	

[t]t test

Surgical technique was cystoperitoneal shunt insertion in 2 patients, cyst fenestration in 34 (77.3%) patients and combined fenestration+shunt in 8 patients (Table 2).

Table 2
Comparison of the surgical techniques based on the cyst location.

	Fenestration	**Fenestration+ Shunt**	**Shunt Alone**	**p**
	n (%)	**n (%)**	**n (%)**	
Location				
Temporal	16 (47.1)	1 (12.5)	2 (100)	
Frontoparietal	5 (14.7)	2 (25.0)	0 (0)	
Frontotemporal	5 (14.7)	1 (12.5)	0 (0)	**6.758/0.034***
Cerebellar	2 (5.9)	4 (50.0)	0 (0)	
Parietal	3 (8.8)	0 (%0)	0 (0)	
Frontal	2 (5.9)	0 (%0)	0 (0)	
Suprasellar	1(2.9)	0 (%0)	0 (0)	

*Kruskall- Wallis test

Improvement ofclinical symptoms or cyst volume reduction was observed in all patients at the early postoperative period. There was no relationship between the type ofsurgical approachand clinical outcome. Forty(90.9%) patients had partial or complete clinical improvementand 4 patients remained symptomatic despite the surgical treatment at the time of discharge. Subdural effusion developed in 5 patients and wound problems were observed in 6 patients. Therewere no permanent neurological complications.No mortality was observed in our series.

Based on the statistical evaluations, arachnoid cysts are more frequently observed in male patients when compared with female patients and this difference was statistically significant (p=0.01). In addition, there was a statistically significant difference between the surgical technique and cyst location. This difference was due to fenestration group (p=0.034).

Discussion

We presented our series of intracranial arachnoid cysts. Most of our patients were male and adults. Fenestration was the most preferred technique and 90% of patients were improved after surgery. Subdural effusion and wound dehiscence were most common complications, but we not observed re-closure of cyst fenestration. In addition, there is no mortality in our series.

Arachnoid cysts are benign and cystic intracranial lesions which were more often diagnosed in children than adults. They constitute approximately 1% of all intracranial mass lesions. Most of them are located in the supratentorial region and middle cranial fossa. But they may also occur in the posterior fossa, cerebellopontine angle and spinal region [6, 8, 9].

These cystic lesions are usually asymptomatic but, in some patients, symptoms may develop such as nausea, vomiting, headache, neurological deficits and seizures. Radiological techniques such as CT scan and MRI are widely used for the diagnosis of intracranial arachnoid cyst [6, 7].

Management of arachnoid cysts is still controversial today. Follow-up is the main option in patients with incidentally diagnosed arachnoid cyst. Enlargement of the arachnoid cyst may be seen in every period of life because of a slit valve mechanism, an osmotic gradient, or cerebrospinal fluid (CSF) production by the cyst walls [10]. It is well known that the rate of cyst enlargement is very low in asymptomatic arachnoid cysts during the follow-up period. Meanwhile, periodical radiological imaging is also indicated in asymptomatic patients for the risk of obstructive hydrocephalus and intracystic hemorrhage, especially in the pediatric population [10].

There are mainly 2 different surgical approaches for the treatment of arachnoid cysts as cyst fenestration and cystoperitoneal shunt [2, 6]. Cystoperitoneal shunts divert CSF from the cysts to the abdomen, helping decrease of the intracranial or intracystic pressure [5, 11]. This technique is a safeand practical procedure and most neurosurgeons are familiar with shunting. But shunt is a mechanical device and patient becomes dependent to shunt. In addition, it carries many risks such as obstruction, infection and overdrainage. Cyst fenestration using either microsurgical or endoscopic technique decreases CSF pressure within the cyst and allows brain expansion especially in young children [12–15]. Microsurgical technique may also help larger cyst wall removal in association with fenestration [16]. Other advantages of microsurgical technique are direct inspection of the cyst borders and vital neurovascular structures, adequate biopsy sampling, multiples fenestration sites especially in multilocular arachnoid cysts [17]. Endoscopic fenestration is a minimally invasive method and aims to fenestrate the cyst with basal cisterns or ventricular system. But cyst fenestration may not be satisfactory with endoscopic technique because it is performed using a narrow corridor and rapid cyst wall closure may occur especially in children. It is obvious that the cyst wall removal is not satisfactory using endoscopic technique. Moreover, surgical area in endoscopic technique is very limited because of the proximity of the neural and vascular structures in basal cisterns [18]. Gangemi et al. performed pure endoscopic fenestration in 18 patients and concluded that suprasellar, quadrigeminal and posterior fossa arachnoid cysts are the best candidates for pure neuroendoscopic approach [18]. They also pointed out that cortical cysts are best treated by microsurgical fenestration or shunting. Hall et al. performed a retrospective study in 82 patients and emphasized that endoscopic and microsurgical approaches cysts produce comparable clinical and radiological outcomes in arachnoid cysts [19]. But endoscopic fenestration is associated with a shorter length of hospital stay. Today, arachnoid cysts are frequently treated with endoscopic fenestration procedure. Cystoperitoneal shunts are usually reserved for patients who did not benefit from the fenestration alone. But the shunt dependence is the main disadvantage of cystoperitoneal shunts. In

our series, we performed cystoperitoneal shunt in only 2 patients who were previously underwent endoscopic fenestration in another center. Fenestration or combined fenestration+shunt were the main surgical approaches in our series and we obtained 90% success after surgery.

Combined technique such as endoscopic fenestration and cystoperitoneal shunt placement in the same operation is another surgical option for neurosurgeons. The importance of this technique is related to the fact that the shunt can induce the collapse of the cyst and that the endoscopic fenestration could make it possible to remove the shunt, avoiding the phenomenon of shunt dependence. Mottolese et al. reported combined use of endoscopic fenestration and a cystoperitoneal shunt in 35 pediatric patients and they pointed out that this is a short and useful procedure for the treatment of arachnoid cysts in all locations [15]. In our series, we performed cyst fenestration and shunt placement in the same session in 8 (18.18%) patients. These patients were also children because of the avoidance of cyst wall re-closure. But we did not removed shunts in case of cyst collapse because of continuous CSF diversion and improvement of the symptoms.

There are also some studies suggesting that surgery did not contribute to the treatment of arachnoid cysts. Kim et al. reported long-term outcome of patients with large sylvian arachnoid cyst in 60 children and they concluded that there is no difference in the outcomes between the surgery and non-surgery groups regardless of the size of the arachnoid cysts when patients had no hydrocephalus or papilledema [13]. Our surgical indications are same with Kim et al., as we also operated patients with the signs of increased intracranial pressure or seizure due to cyst.

Arachnoid cysts should not be operated until they become symptomatic. Meanwhile, close follow-up with periodical MRIs is required in order to detect any cyst enlargement or intracystic hemorrhage. Severe headache, convulsion, and nausea-vomiting are alert signs for patients with arachnoid cysts. Electroencephalography may be used for the detection of any abnormal electrical discharges secondary to cysts. But this test is not a criterion for the decision of surgery. Cyst fenestration is the main option for surgical treatment. It may be performed using either endoscopic technique with a small burr hole or microsurgical technique with craniotomy. The decision usually depends on the cyst size and presence of increased intracranial pressure. Large cysts with midline shift or intracystic hemorrhage especially in children require microsurgical approach with craniotomy. Removal of a large cyst wall is crucial for adequate cerebral decompression. Moderate or small arachnoid cysts which are presenting with seizure in adult patients are best candidates for endoscopic fenestration through a small burr hole.

This study describes our institutional experience over a 9-years period. The major limitation of our study is the retrospective nature. Lack of comparison group and small number of patient are other limitations.

Conclusion

Arachnoid cysts should be operated when they become symptomatic. Cyst fenestration, either endoscopic or microsurgical, is the most common and effective treatment method for intracranial arachnoid cysts. Microscopic fenestration through a craniotomy is the first option for large arachnoid

cysts in young children while endoscopic technique through a small burr hole should be reserved for relatively small arachnoid cysts presented with seizure in adults. Re-closure of the fenestration is the main problem especially when performed in young children.

Declarations

Funding

No funding

Conflicts of interest/Competing interests

None declared.

Ethics approval (include appropriate approvals or waivers)

Approved by the local ethics committee (30.06.2020/298).

Consent to participate (include appropriate statements)

Not applicable

Consent for publication (include appropriate statements)

Not applicable

Availability of data and material (data transparency)

Not applicable

Code availability (software application or custom code)

Not applicable

Authors' contributions

Concept: A.D. ; Design: S.K. ;Data: S.K.; Analysis: A.D.; Literature search: S.K.; Writing: S.K., A.D.; Critical revision: A.D.

Acknowledgments

The authors thank all the neurosurgery staff for their cooperation.

References

1. Logan C, Asadi H, Kok HK, Looby S, O'Hare A, Thornton J, Brennan P. Arachnoid cysts-common and uncommon clinical presentations and radiological features. J Neuroimaging Psychiatry Neurol 2016;1: 79-84.
2. Cincu R, Agrawal A, Eiras J. Intracranial arachnoid cysts: current concepts and treatment alternatives. Clin Neurol Neurosurg 2007;109:837-43.
3. Massimi L, Caldarelli M, Di Rocco C. Intracranial congenital arachnoid cysts. In: Di Rocco C., Pang D., Rutka J. (editors) Textbook of Pediatric Neurosurgery. Springer, Cham. 2017, 39-1.
4. Pereira RG, Ribeiro BNF, Hollanda RTL, de Almeida LB, Simeão TB, Marchiori E. Non-neoplastic intracranial cystic lesions: not everything is an arachnoid cyst. Radiol Bras 2021;54:49-55.
5. Baysefer A, Izci Y, Erdoğan E. Lateral intrathoracic meningocele associated with a spinal intradural arachnoid cyst. Pediatr Neurosurg 2001;35:107-10.
6. Mustansir F, Bashir S, Darbar A. Management of arachnoid cysts: a comprehensive review. Cureus 2018;10:e2458.
7. Atalar MH, Karakuş K, Yıldız B, Şalk İ. Location, sidedness, and sex distribution of incidental intracranial arachnoid cysts in childhood: An MRI study. Cumhuriyet Medical Journal 2018;40:25-33.
8. Amelot A, Beccaria K, Blauwblomme T, Bourgeois M, Paternoster G, Cuny ML, Zerah M, Sainte-Rose C, Puget S. Microsurgical, endoscopic, and shunt management of pediatric temporosylvian arachnoid cysts: a comparative study. J Neurosurg Pediatr 2019;23:749-57.
9. Gönül E, Izci Y, Onguru O. Arachnoid cyst of the cerebellopontine angle associated with gliosis of the eighth cranial nerve. J Clin Neurosci 2007;14:700-2.
10. Hall S, Smedley A, Sparrow O, Mathad N, Waters R, Chakraborty A, Tsitouras V. Natural history of intracranial arachnoid cysts. World Neurosurg 2019;126:e1315-20.
11. Martínez-Lage JF, Ruíz-Espejo AM, Almagro MJ, Alfaro R, Felipe-Murcia M, López-Guerrero AL. CSF overdrainage in shunted intracranial arachnoid cysts: a series and review. Childs Nerv Syst 2009;25:1061-9.
12. Jafrani R, Raskin JS, Kaufman A, Lam S. Intracranial arachnoid cysts: Pediatric neurosurgery update. Surg Neurol Int 2019;10:15.
13. Kim KH, Lee JY, Phi JH, Kim SK, Cho BK, Wang KC. Long-term outcome of large sylvian arachnoid cysts: the role of surgery has been exaggerated. J Neurosurg Pediatr 2020;26:221-7.
14. Linares Torres J, Ros López B, Iglesias Moroño S, Ibáñez Botella G, Ros Sanjuán Á, Arráez Sánchez MÁ. Neuroendoscopic treatment of arachnoid cysts in the paediatric population. Series results for 20 patients. Neurocirugia (Astur) 2020;31:165-72.
15. Mottolese C, Szathmari A, Simon E, Ginguene C, Ricci-Franchi AC, Hermier M. The parallel use of endoscopic fenestration and a cystoperitoneal shunt with programmable valve to treat arachnoid cysts: experience and hypothesis. J Neurosurg Pediatr 2010;5:408-14.
16. Raffel C, McComb JG. To shunt or to fenestrate: which is the best surgical treatment for arachnoid cysts in pediatric patients? Neurosurgery 1988;23:338-42.

17. Saura Rojas JE, Horcajadas Almansa Á, Ros López B. Microsurgical treatment of intracranial arachnoid cysts. Neurocirugia (Astur) 2016;27:24-7.
18. Gangemi M, Seneca V, Colella G, Cioffi V, Imperato A, Maiuri F. Endoscopy versus microsurgical cyst excision and shunting for treating intracranial arachnoid cysts. J Neurosurg Pediatr 2011;8:158-64.
19. Hall S, Smedley A, Rae S, Mathad N, Waters R, Chakraborty A, Sparrow O, Tsitouras V. Clinical and radiological outcomes following surgical treatment for intra-cranial arachnoid cysts. Clin Neurol Neurosurg 2019;177:42-6.

Figures

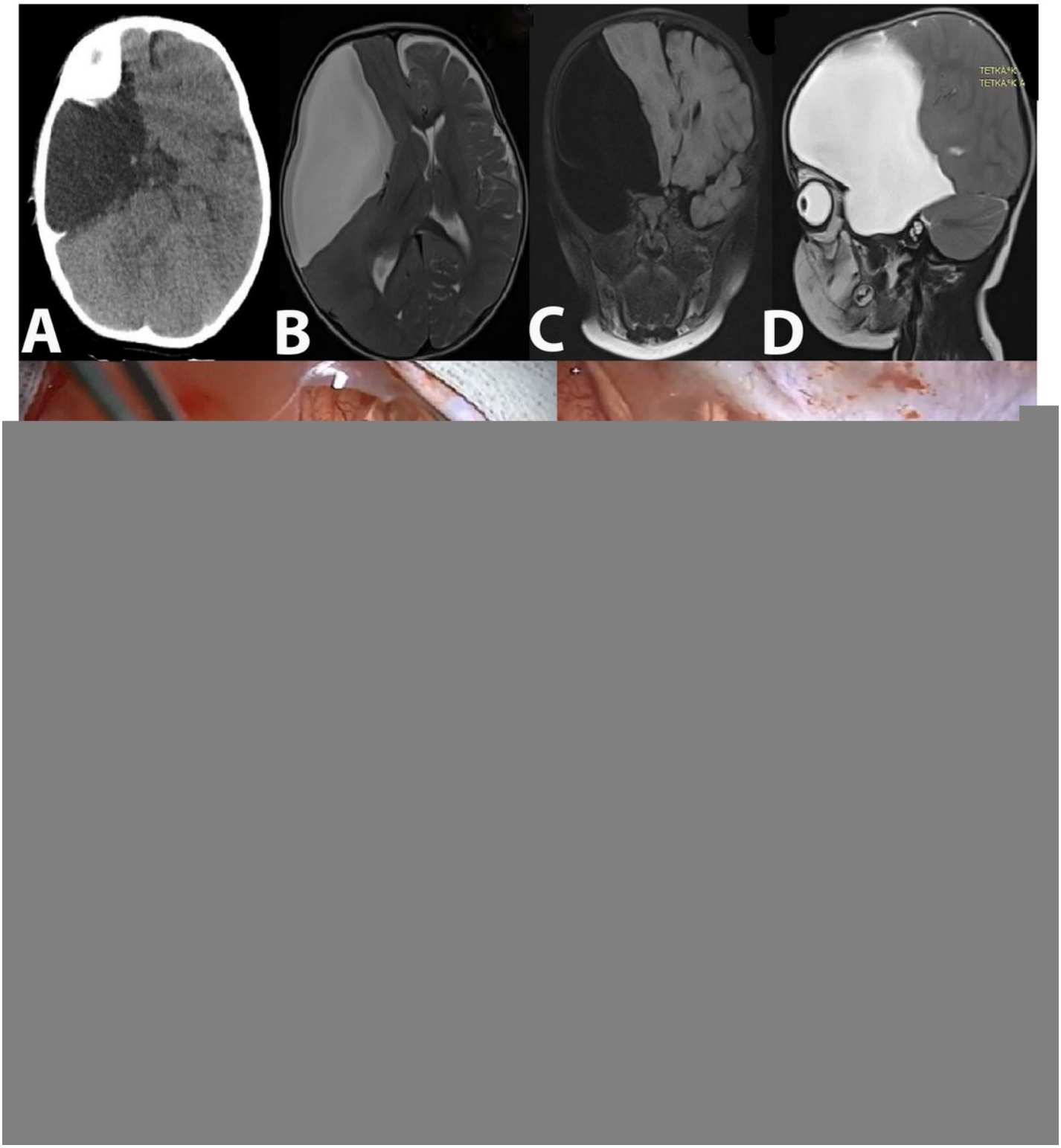

Figure 1

Axial CT scan **(A)**, axial **(B),** coronal **(C)** and sagittal **(D)** MRI of a child with large left frontotemporal arachnoid cyst with midline shift. In the first step of surgery, the outer wall of the cyst was extesively removed **(E).** It was obvious that the carotid artery and optic nerve were surrounded with dense arachnoid membrane **(F).** Microsurgical fenestrations were made from the multiple sites **(G)** and the internal carotid

artery (ICA), olfactory nerve, optic nerve and oculomotor nerve became clearly visible after the removal of arachnoid membranes **(H).**

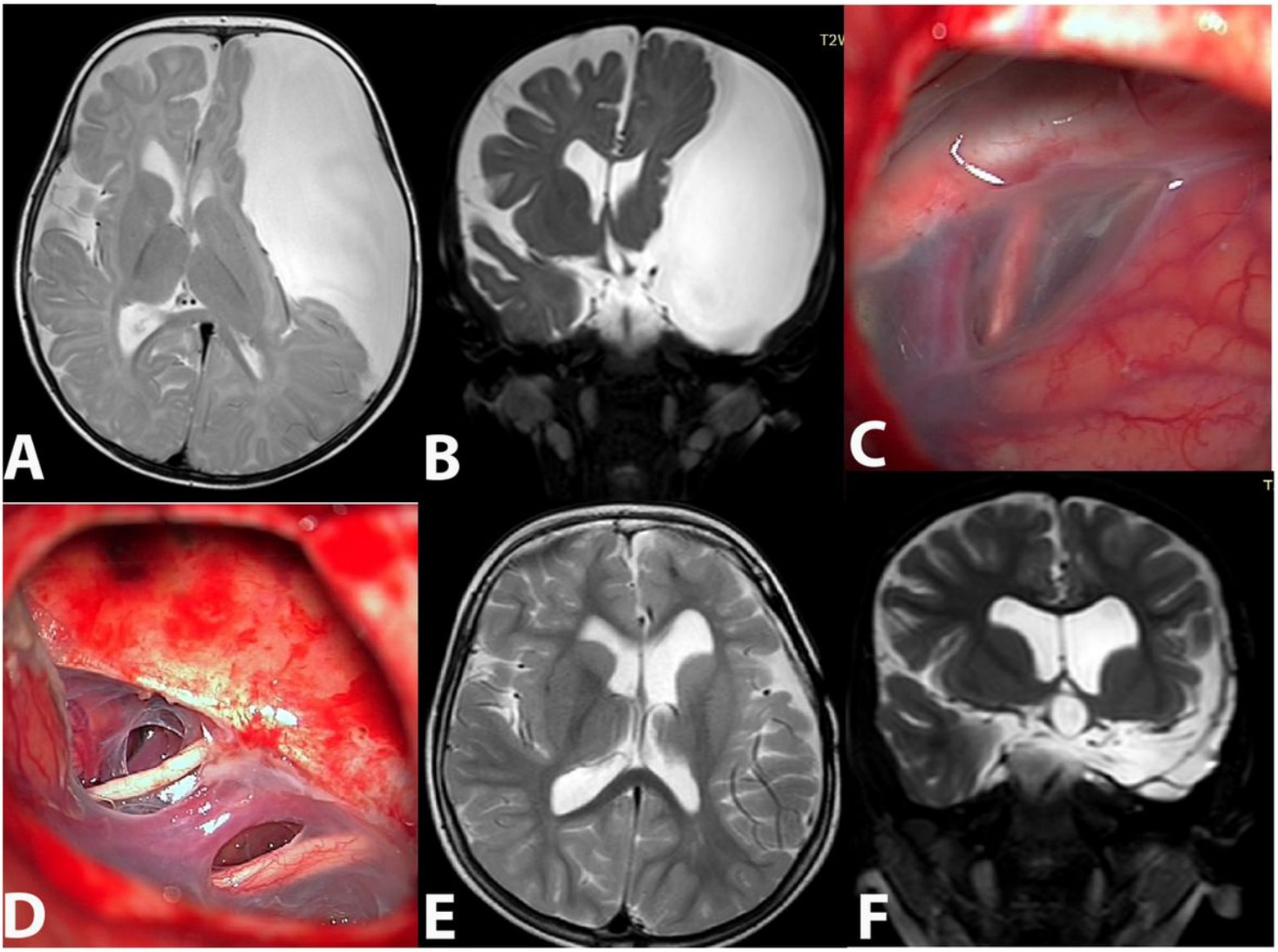

Figure 2

Axial **(A)** and coronal **(B)** MRI scans show large right frontotemporal arachnoid cyst causing midline shift. The blurred view of carotid artery and optic nerve before the fenestration **(C).** These structures became clearly visible after microsurgical multiple fenestrations **(D).** Postoperative axial **(E)** and coronal **(F)** MRI scans revealed improvement of the midline shift and arachnoid cyst.

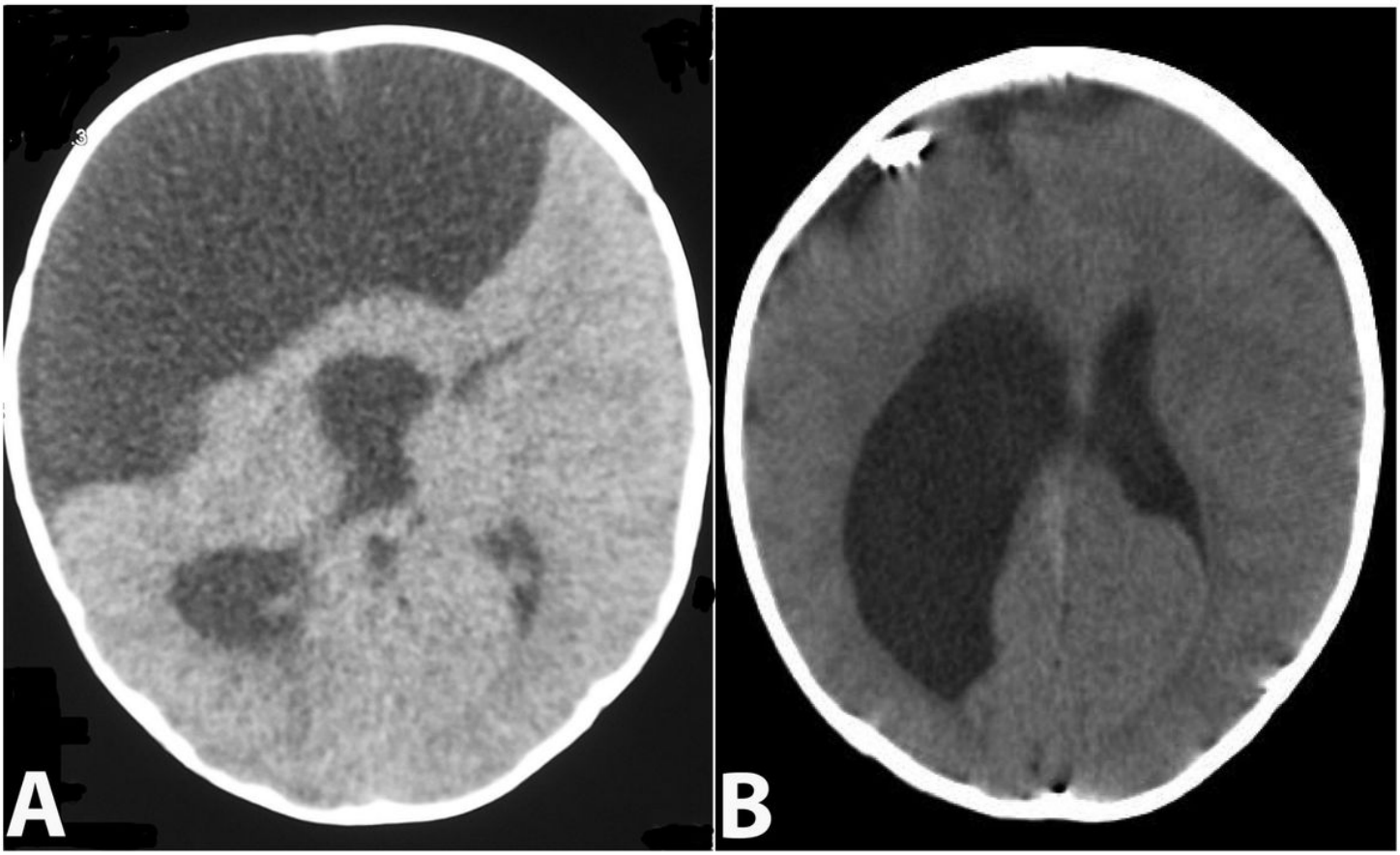

Figure 3

Preoperative axial CT scans of patient with large frontoparietal arachnoid cyst **(A).** The patient underwent combined endoscopic fenestration and shunt application. Postoperative axial CT scans revealed shrinkage of the cyst and enlargement of the left side lateral ventricle secondary to CSF drainage **(B**).

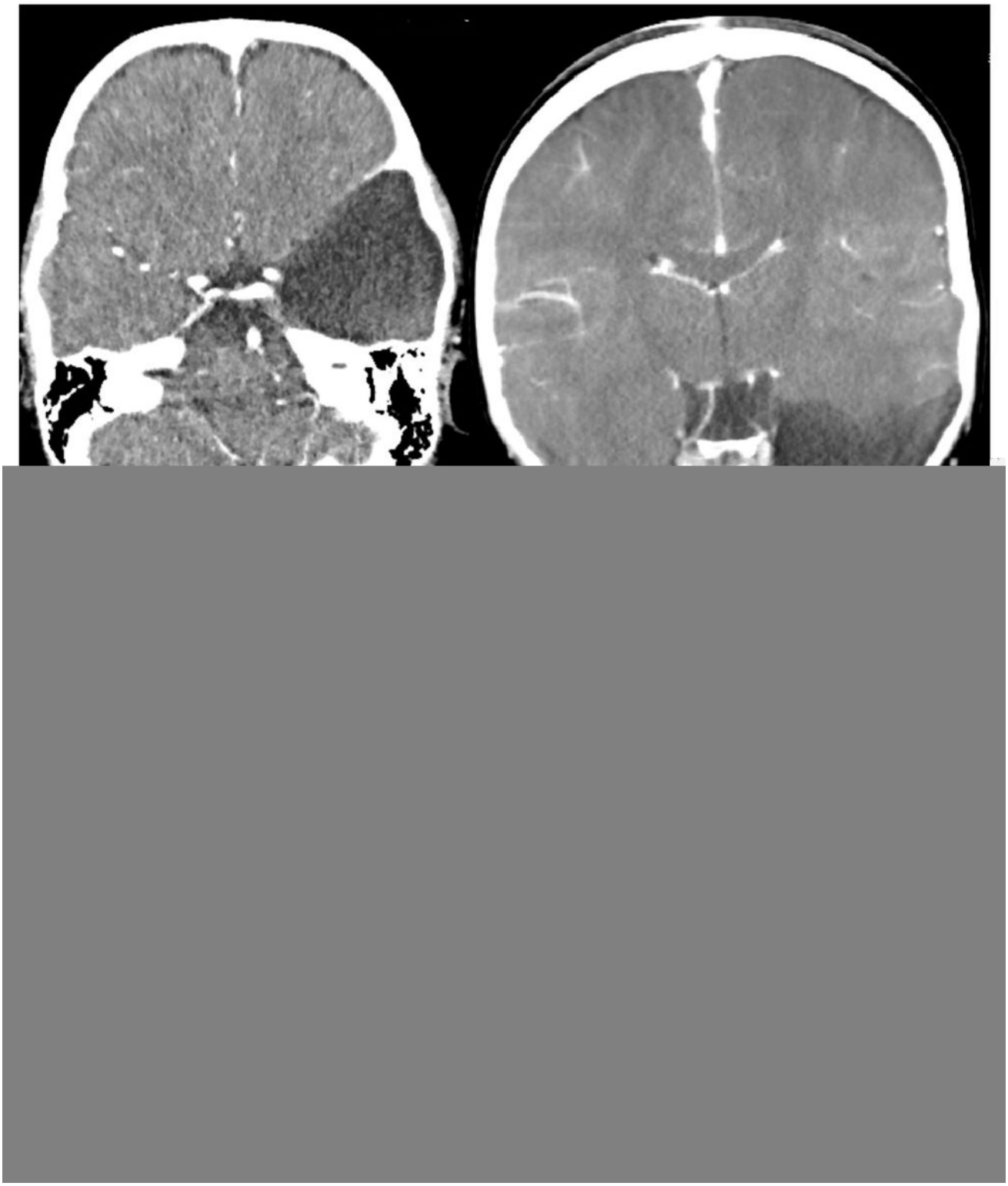

Figure 4

Axial **(A)** and coronal **(B)** CT scans of patient with right temporal arachnoid cyst. The patient underwent combined endoscopic fenestration and shunt insertion. Postoperative axial **(C)** and coronal **(D)** CT scans show expansion of the right temporal lobe secondary to shrinkage of the arachnoid cyst.