Traumatic diaphragmatic hernia: 28-years analysis at a Brazilian university hospital

Vitor Kruger (vitorfkruger@gmail.com)
State University of Campinas

Thiago Calderan
State University of Campinas

Rodrigo Carvalho
State University of Campinas

Elcio Hirano
State University of Campinas

Gustavo Fraga
State University of Campinas

Research Article

Keywords: Traumatic diaphragmatic hernia, diaphragm, hernia, diaphragmatic injury

Posted Date: December 17th, 2020

DOI: https://doi.org/10.21203/rs.3.rs-121284/v1

Abstract

Background The objective of the study is evaluate the approach to patients with acute traumatic diaphragmatic hernia at a Brazilian university hospital during a 28-year period. Traumatic diaphragmatic hernia is an uncommon injury, however its real incidence may be higher than expected. Sometimes is missed in trauma patients, and is usually associated with significant morbidity and mortality, this analysis may improve outcomes for the trauma patient care.

Methods Retrospective study of time series using and analisys database records of trauma patients at HC- Unicamp was performed to investigate the incidence, trauma mechanism, diagnosis, herniated organs, associated injuries, trauma score, morbidity, and mortality of this injury.

Results Fifty-five cases were analyzed. Blunt trauma was two-fold frequent than penetrating trauma, are associated with high grade injury and motor vehicle collision was the most common mechanism. Left side hernia was four-fold frequent than right side. Diagnose was mostly performed by chest radiography (31 cases; 56%). Associated intra-abdominal injuries were found in 37 patients (67.3%) and extra-abdominal injuries in 35 cases (63.6%). The mortality was 20% (11 cases).

Conclusions Computed tomography scan identified associated injuries and had high specificity. Isolated injuries were rare, and the presence of associated injuries increased morbidity and mortality. Despite advances in imaging methods, chest radiography in the trauma bay is useful as an initial approach. Despite the use of laparoscopy in a few cases, laparotomy was the most frequent approach for repair.

Background

A traumatic diaphragmatic hernia (TDH) is defined as the protrusion of abdominal structures through an injured diaphragm into the thoracic cavity. Traumatic diaphragmatic injuries (TDI) without diaphragmatic hernias are present in 3% of all abdominal injuries. Data suggest that TDI are present in 1-7% of patients with blunt trauma (BT), and in 10-15% of those with penetrating wounds [1]. Gunshot wounds (GSW) are commonly (66%) involved in penetrating trauma, and motor vehicle collisions (MVC) (63%) in BT [2]. A diagnosis of TDI can be initially missed by computed tomography (CT-scan) in up to 60% of cases [3].

TDH is an uncommon injury; however, its real incidence may be slightly higher than expected [4]. Some collective reviews suggest that the incidence of TDH due to BT is as high as 75% because it involves more energy dissipation [5].

The clinical diagnosis of TDI is challenging for trauma and acute care surgeons, who depend on a high index of suspicion, mechanism of trauma, and interpretation of radiological images for the diagnosis.

Although uncommon, TDH are sometimes missed in trauma injuries and are associated with significant morbidity and mortality. It is essential to diagnose in the acute phase of trauma, avoiding missed injuries and delayed diagnosis. The increased number of trauma patient is a challenge for public health

authorities. We performed a retrospective analysis of the records of our trauma department patients to investigate the incidence, trauma mechanism, diagnosis, herniated organs, associated injuries, complications, morbidity, and mortality of this injury, evaluating the diagnosis, treatment and outcomes.

Methods

Descriptive retrospective analysis of the medical records between January 1990 and December 2017 of patients from the trauma database of the Division of Trauma Surgery at University (DCT) of Campinas. Since 1987, the DCT has a team of specialists in trauma and acute care surgery actively working on training residents, teaching trauma league students, and promoting trauma prevention programs. The metropolitan area of Campinas has a population of 3.8 million, encompassing 20 cities. HC-Unicamp is one of the reference hospitals for the population using the public health system in this region, is a level 1 trauma center, has about 500 beds and a specific Trauma-ICU for patients with high complexity injuries.

The medical records of 3.003 patients treated by exploratory laparotomy for penetrating or blunt abdominal trauma were reviewed. The records of patients with TDI were analyzed for demographic data, trauma mechanism, hemodynamic status at admission, grade and location of the diaphragmatic injury, herniated organs, diagnostic methods, interval between surgery, length of stay, trauma scores, associated injuries, morbidity, and mortality. The trauma scores were calculated using the Revised Trauma Score (RTS), Injury Severity Score (ISS), and the Trauma Injury Severity Score (TRISS).

TDI were graded according to the American Association for the Surgery of Trauma (AAST) injury scale [6] as follows: grade I, diaphragm contusion; grade II, laceration less than or equal to 2 cm; grade III, laceration greater than 2 cm and less than 10 cm; grade IV, laceration greater than 10 cm, with tissue loss less than or equal to 25 cm^2; and grade V, laceration with tissue loss greater than 25 cm^2. Grade I injuries and chronic hernias (> 180 days) were excluded.

Our institutional protocol for treatment of TDI involves repair with a nonabsorbable suture, such as polypropylene, placement of an ipsilateral chest tube for drainage, and a nasogastric tube. The research protocol of this study was approved without restrictions, all methods were committee complies with all regulations, following the Helsinki statement and the Committee of Research Ethics and Institutional Review Board (IRB), School of Medical Sciences, Unicamp, under the number 2.692.996 in 06/05/2018.

Results

Of the 3.003 reviewed patients, 425 had TDI (14.1%). A diagnosis of TDH was established in 55 cases (1.8%). All further analyses were performed in theses 55 cases. TDH was predominant in males with 46 cases (83%).

BT was most common with 40 cases (72.7%). MVC was the most common blunt mechanism (26 cases, 65%), followed by pedestrian-hit-by-car (11 cases, 27.5%), assault (5%), and falls (2.5%). Among the 15

cases of penetrating trauma (27.3%), stab wounds (SW) were present in 9 (60%), and GSW in 6 (40%) (Figure 1).

Diagnosis was mostly performed by chest radiography (CXR) in 31 cases (56%).

The administration of a water-soluble contrast by nasogastric tube was performed in 2 cases, supporting the diagnosis of TDH.

Since 2008, at HC-Unicamp, hemodynamically stable trauma patients had access to a multi-slice CT scan, which was used to diagnose 7 cases (12%) (Figure 2 and 3). TDH was observed intraoperatively in 17 cases (32%); 14 of these were diagnosed by laparotomy and had associated intra-abdominal injury or hemodynamically unstable (Figure 4); and 3 by laparoscopy.

Diagnostic peritoneal lavage (DPL) was performed in 5 cases, 3 were positive for intra-abdominal injury, 2 negative, and all cases of DPL were subjected to exploratory laparotomy. In the 2 negative cases of DPL, laparotomy was performed due to the suggestive herniation image in CXR and worsening of the patient's hemodynamics. Surgical procedures were performed within 24 hours in 42 cases (76%), between 24-72 h in 8 (14%), and 72-96 h in 3 cases (5%) Two cases were diagnosed and treated 60 and 180 days after the trauma, respectively.

Laparotomy was the most performed procedure (49 cases, 89%), followed by thoracolaparotomy (5 cases, 9%) and laparoscopy (1 case, 2%).

Left side hernia was the most common (44 cases, 80%), followed by right side (10 cases, 18%), and bilateral (1 case, 2%). Right side most common mechanism was MVC (6 cases).

Diaphragmatic grade III injury occurred in 21 patients (38%), grade IV in 19 (34%), grade V in 9 (17%), and grade II in 6 (11%) (Figure 5). In SW, grade III injury was the most common, followed by grade II. In GSW, grades II, III, and IV had proportionally equal cases. In BT, grade IV was most common followed by grade III.

The stomach was the most common herniated organ (38 cases), followed by the spleen (18 cases), colon (15 cases), small bowel (6 cases), and liver (5 cases). Twenty-five (45.5%) cases had more than one herniated abdominal structure.

Associated intra-abdominal injuries were found in 37 patients (67.3%). Spleen was the most injured (19 cases), followed by the liver (16 cases), stomach (8 cases), colon (6 cases), small bowel and urinary bladder (3 cases each), kidney (2 cases), and pancreas (1 case).

Associated extra-abdominal injuries were found in 35 cases (63.6%). The most common was pelvic fracture (14 cases), and others included long bone fractures (12 cases), traumatic brain injury (TBI) and face trauma (5 cases each), and spinal cord trauma (3 cases). Associated intrathoracic injuries were identified in 13 cases (23.6%). The most common injury was hemopneumothorax and fracture of the ribs

(6 cases), followed by lung contusion (4 cases), cardiac injury (2 cases), and thoracic aorta injury (1 case).

About the trauma scores, the maximum RTS was 7.84 (38 cases) and the minimum was 3.26. ISS > 15 was found in 43 cases (78.2%) and > 25 in 21 (38.2%). In cases of ISS > 25, the most prevalent trauma mechanism was BT with 20 cases (95.2%) and 1 case (4.8%) had GSW. Of the 37 patients (67.3%) with systolic blood pressure (SBP) > 90 mmHg, 11 (29.7%) had ISS > 25. Of the 18 patients with hemodynamic instability (SBP < 90 mmHg) in the trauma bay, 11 (61.1%) had ISS > 25. In 21 cases with ISS > 25, the grade of diaphragmatic injury in most was IV (8 cases, 38.1%), followed by grade III (7 cases, 33.3%), and grade V (6 cases, 28.6%).

Seven cases (12.7%) had TRISS < 0.50, and 48 (87.3%) had TRISS > 0.50.

Related to morbidity, 32 cases (58.2%) had postoperative complications. Of these, 71% with ISS > 25 had complications during hospitalization, and 45% with ISS < 25 had complications. Pneumonia was the most frequent complication (15 cases), followed by empyema and acute coagulopathy associated with trauma (7 cases each), and atelectasis (3 cases).

The length of stay included a maximum of 61 days, and the average was 14 days.

The mortality rate was 20% (11 cases), and the most common cause was the lethal triad (coagulopathy, hypothermia, and acidosis) in 6 cases (54.5%), followed by multiple organ failure syndrome in 3 (27.3%), TBI and pulmonary embolism (1 case each). Mortality was observed in 10 cases (25%) with BT and 1 case (15%) with penetrating trauma. Overall mortality was 20%.

Discussion

A recent review by the National Bank Trauma Date [2] showed that a majority of diaphragmatic injuries in BT cases were due to MVC (63%) and pedestrian-hit-by-car accidents (11%). In penetrating trauma, diaphragmatic injuries were due to GSW (66%). Penetrating wounds lead to minor lacerations, and take time to present any complications; however, large linear ruptures are common in BT, leading to immediate diaphragmatic herniation [7,8]

BT injuries on the left side were more common than on the right side. In the literature, the incidence of left diaphragmatic injury was reported in 75% of cases, as opposed to right in 25% and bilateral in less than 2%, corroborating the findings of our analysis [9,10] Explanation for this would be muscle weakness in the posterolateral area of the left diaphragm [11,12,13]. The lower incidence of injury to the right side is attributed to the protective effect of the liver [13]. Patients with rupture of the right hemidiaphragm had a higher prehospital mortality as a result of greater trauma severity and high grade of injury, typically associated with significant vascular tears in the inferior or retro-hepatic vena cava [8].

Nowadays, diagnosing a right-side hernia in severe trauma cases is possible due to efficient prehospital teams, which stabilize and transport the patient to a hospital timeously, due to the technology used in

obtaining quality CT-scan images. Aun et al. [14] compared 97 cases of TDHs treated surgically with 146 cases seen in 12.276 consecutive autopsies of patients who died because they did not receive medical care. There was a higher incidence of diaphragmatic lacerations on the right side in the autopsy group (49.6%) than in the hospitalized group (14.4%) and hemorrhagic shock (80%) being the main cause of death in the autopsy group.

The diaphragm is closely related to the intrathoracic and intra-abdominal organs. At least 50% of patients with diaphragmatic injury also experience associated injuries [15]. Our series presented results similar to the literature [25] when evaluate the associated injuries.

Associated injuries include pelvic and long bone fractures, and injuries to intra-abdominal structures, such as the spleen and liver.

Meyers and McCabe [16] reported an 8% incidence of traumatic aortic injury and 32% traumatic brain injury in 68 patients with diaphragmatic rupture and recognized the importance of TDH as a marker of serious injury. There are few signs and symptoms for the immediate clinical diagnosis of an acute diaphragmatic rupture.

Hirano et al. [17] concluded that a diaphragmatic hernia should be suspected on the basis of the trauma mechanism and physical examination. Symptoms and signs attributable to diaphragmatic injury include respiratory distress, shock, shoulder pain, and the presence of bowel sounds in the chest, which can be unnoticed by environmental noise. The diagnosis of diaphragmatic injuries through imaging presents a challenge for trauma surgeons and radiologists [17]. A delayed diagnosis of a traumatic diaphragmatic injury resulting in diaphragmatic hernia is problematic due to the associated morbidity and mortality [18]. This mandates aggressive diagnostic evaluation of patients at risk for diaphragmatic injury to avoid long-term sequelae [19]. Despite advances in imaging methods, CXR is still useful in diagnosing or suspecting traumatic diaphragmatic hernia, and is the initial step for evaluation [17,20]. CXR allows the diagnosis in 30-60% of cases with left-sided lesions, against 17% with right-sided lesions [21,22]. A review of the literature reported that diagnosis on the basis of CXR was made in only 40.7% of cases [5].

Currently, for a broad assessment of associated injuries and the possibility of non-operative treatment, most hemodynamically stable patients should undergo a CT-scan. A multidetector CT-scan with multiple coronal and sagittal reforms contributes to the accuracy of the diagnosis [18,23-25]. Image findings such as diaphragmatic discontinuity, collar and dependent viscera sign, and intrathoracic herniation of the abdominal structures have a good sensitivity and high specificity for the diagnosis [3,20,26]. Magnetic resonance imaging, despite offering excellent resolution images for viewing the diaphragm, is not suitable for trauma patients in the acute phase, is not used in our hospital.

Focused assessment with sonography for trauma (FAST) is an essential propaedeutic tool in the initial assessment of a traumatized patient. Currently, extended FAST (e-FAST) is considered important in the diagnosis of thoracic cavity injuries, such as pneumothorax, pulmonary contusion, hemothorax, and

abdominal or pericardial free fluid; however, there is insufficient evidence of its use in the diagnosis of diaphragmatic injuries.

Ivatury et al. [27,28] reported that the diagnostic accuracy of laparoscopy was excellent for hemoperitoneum and diaphragmatic lacerations, validating laparoscopy as an excellent tool to evaluate the diaphragm in penetrating injuries. Thus, expanding the spectrum of minimally invasive surgery can play an important role in the diagnosis and treatment of patients with diaphragmatic herniation, but minimally invasive approach is highly dependent on the surgeon's expertise to be safe and have better outcomes. DPL was propaedeutic for the evaluation of blunt abdominal trauma in the past. However, the literature demonstrates the inadequacy of DPL in the diagnosis of acute diaphragmatic rupture [29]. Although 5 cases underwent this method, it has not been used in our hospital since 2010 due to low specificity, large number of false negative findings in isolated diaphragmatic injuries, and high rates of non-therapeutic laparotomies.

Treatment of TDH involves surgical repair, either laparoscopy or laparotomy. Acutely, laparotomy is the preferred approach because many cases have associated intra-abdominal injuries. Herniated viscera must be reduced into the abdominal position and the thoracic cavity must be inspected. Lacerations are sutured with non-absorbable monofilaments, followed by the placement of an ipsilateral chest tube for drainage, and a nasogastric tube for stomach decompression. For large defects, the use of prosthetic materials such as mesh may be necessary.

The morbidity rate in the literature varies between 31% and 65% [30-33], similar to our results of 40%. Most complications are related to associated injuries, not attributed to the diaphragmatic injury itself. Patients with hemodynamic instability during admission and BT had higher complication rates [13].

This collective review reflects a mortality rate of 20%, being higher in the group with BT and ISS > 25. In the literature, mortality rates range from 17% to 51% [5,16,30,31]. High morbidity and mortality were mainly related to associated injuries, characterizing diaphragmatic injury as a marker of potentially serious and lethal injuries.

This study has limitations related to its retrospective design. The potential biases may occur because the analysis of established data shows the change in perspectives and tendencies of patient assessment. Data collection also relied on chart review at the participating institution which may contain errors or omissions.

Conclusion

Traumatic diaphragmatic hernias are uncommon but significant in trauma patients. Isolated injuries were rare, and the presence of associated injuries increased morbidity and mortality. Despite advances in imaging methods, chest radiography in the trauma bay is useful as an initial approach. CT identified associated injuries and had high specificity. Despite the use of laparoscopy, laparotomy was the most frequent approach for repair.

Abbreviations

TDH: traumatic diaphragmatic hernia, TDI: traumatic diaphragmatic injuries, BT: Blunt trauma, GSW: Gunshot wounds, MVC: motor vehicle collisions, CT-scan: computed tomography, DCT: Diivision of Trauma Surgery, HC-Unicamp: Clinics Hospital University of Campinas, Trauma-ICU: Trauma intensive care unit, RTS: Revised trauma score, ISS: Injury severity score, TRISS: Trauma Injury Severity Score, AAST: American Association for the Surgery of Trauma, IRB: Committee of Research Ethics and Institutional Review Board, SW: Stab wounds, CXR: chest radiography, DPL: Diagnostic peritoneal lavage, SBP: systolic blood pressure, TBI:traumatic brain injury, FAST: Focused assessment with sonography for trauma, e-FAST: extended Focused assessment with sonography for trauma.

Declarations

Ethical approval statement: The present study was approved by the Unicamp Institutional Research Board (research ethics committee – University of Campinas), Campinas, SP, Brazil, under the number 2.692.996 in 06/05/2018. – CAAE ID: 89045118.5.0000.5404. All methods were committee complies with all regulations, following the Helsinki statement.

Consent for publication: Our study is retrospective design (from 1990 to 2017) with long collection data, there is no **participant in current follow-up to which the informed consent form can be applied** or any subsequent intervention. Was a request for release of informed consent term. After analyzing the Institutional Research Board (research ethics committee – University of Campinas), this release of the term was approved.

For used images (intraoperative and CT-scan) the consent informed term is attached in the supplementary documents.

Attachments also include the director of HC-Clinics UNICAMP consent to carry out the evaluation of medical records and research with the medical records studied. All methods were committee complies with all regulations, following the Helsinki statement.

Available data or materials: All data generated or analysed during this study are included in this published article and its supplementary information files.

Competing interests: The authors declare that they have no competing interests

Funding: The author(s) received no specific funding for this work

Authors contributions: VFK participated in the acquisition, analysis and interpretation of data, participated in the study's design and drafted the manuscript. TAC: contributed to the study's design and the revision of the manuscript. RBC: revision of the manuscript. ESH: interpretation of data, contributed to the study's design and the revision of the manuscript. GPF conceived the study, and participated in its

design and coordination and helped to draft the manuscript. All authors read and approved the final manuscript.

Acknowledgments: The authors would like to thank all the medical staff and residents of the Division of Trauma Surgery, University of Campinas, who, during 33 years of work, were tirelessly present in the care and treatment of the patients analyzed in the present study.

Authors information: VFK: Staff, MD. Division of Trauma Surgery, Department of Surgery, School of Medical Sciences, University of Campinas (Unicamp), Campinas, São Paulo, Brazil. TAC: Staff, MD. Division of Trauma Surgery, Department of Surgery, School of Medical Sciences, University of Campinas (Unicamp), Campinas, São Paulo, Brazil. RBC: Staff, MD. Division of Trauma Surgery, Department of Surgery, School of Medical Sciences, University of Campinas (Unicamp), Campinas, São Paulo, Brazil. ESH: PhD., Division of Trauma Surgery, Department of Surgery, School of Medical Sciences, University of Campinas (Unicamp), Campinas, São Paulo, Brazil. GPF: Professor, Chief, PhD. Division of Trauma Surgery, Department of Surgery, School of Medical Sciences, University of Campinas (Unicamp), Campinas, São Paulo, Brazil; and Postdoctoral Fellow at University of California, San Diego (UCSD.

References

1. Petrone P, Asensio JA, Marini CP. Diaphragmatic injuries and post-traumatic diaphragmatic hernias. Curr Probl Surg 2017;54:11-32 doi:10.1067/j.cpsurg.2016.11.001
2. Fair KA, Gordon NT, Barbosa RR, et al. Traumatic diaphragmatic injury in the American College of Surgeons National Trauma Data Bank: a new examination of a rare diagnosis. Am J Surg 2015;209:864-869 doi: 10.1016/j.amjsurg.2014.12.023
3. Panda A, Kumar A, Gamanagatti S, et al. Traumatic diaphragmatic injury: A review of CT signs and the difference between blunt and penetrating injury. Diagn Interv Radiol 2014;20:121-128 doi: 10.5152/dir.2013.13248
4. Kearney PA, Rouhana SW, Burney RE. Blunt rupture of the diaphragm: Mechanism, diagnosis, and treatment. Ann Emerg Med 1989;18:1326-1330 doi: 10.1016/s0196-0644(89)80270-7
5. Shah R, Sabanathan S, Mearns AJ, et al. Traumatic rupture of diaphragm. Ann Thorac Surg 1995;60:1444-1449 doi: 10.1016/0003-4975(95)00629-Y
6. Moore EE, Malangoni MA, Cogbill TH, et al. Organ injury scaling IV: thoracic vascular, lung, cardiac, and diaphragm. J Trauma 1994;36:229-230 doi:10.1097/00005373-199403000-00002
7. Degiannis E, Levy RD, Sofianos C, et al. Diaphragmatic herniation after penetrating trauma. Br J Wurg 1996;83:88-91 doi:10.1002/bjs.1800830128
8. Boulanger BR, Milzman DP, Rosati C, et al. A comparison of right and left blunt diaphragmatic rupture. J Trauma 1993;35:255-260 doi: 10.1097/00005373-199308000-00014.
9. Voeller GR, Reisser JR, Fabian TC, et al. Blunt diaphragm injuries. A five-year experience. Am Surg 1990;56:28-31

10. Smithers BM, O'Loughlin BO, Strong RW. Diagnosis of ruptured diaphragm following blunt trauma: results from 85 cases. Aust N Z J Surg 1991;61:737-741
11. Flancbaum L, Dauber M, Demas C, et al. Early diagnosis and treatment of blunt diaphragmatic injury. Am Surg 1988;54:195-199
12. Ward RE, Flynn TC, Clark WP. Diaphragmatic disruption secondary to blunt abdominal trauma. J Trauma 1981;21:35-38 doi: 10.1097/00005373-198101000-00006
13. Andrus CH, Morton JH. Rupture of the diaphragm after blunt trauma. Am J Surg 1970;119:686-693 doi: 10.1016/0002-9610(70)90240-0
14. Aun F, Lourenção JL, Younes RN, et al. Contribuição ao estudo da história natural e dos fatores de risco das hérnias diafragmáticas traumáticas. Rev Hosp Clin Fac Med 1982;37:265-270
15. Williams M, Carlin MA, Tyburski JG, et al Predictors of mortality in patients with traumatic diaphragmatic rupture and associated thoracic and/or abdominal injuries. Am Surg 2004;70:157-162
16. Meyers BF, McCabe CJ. Traumatic diaphragmatic hernia: occult marker of serious injury. Ann Surg 1993;218:783-790 doi:10.1097/00000658-199312000-00013
17. Hirano ES, Silva VG, Bortoto JB, et al. Exame radiográfico convencional do tórax no diagnóstico de hérnia diafragmática pós-traumática. Rev Col Bras Cir 2012;39:280-285. doi:10.1590/S0100-69912012000400007
18. McDonald AA, Robinson BRH, Alarcon L, et al. Evaluation and management of traumatic diaphragmatic injuries: A Practice Management Guideline from the Eastern Association for the Surgery of Trauma. J Trauma Acute Care Surg 2018;85:198-207 doi: 10.1097/TA0000000000001924
19. Kaw LL Jr, Potenza BM, Coimbra R, et al. Traumatic diaphragmatic hernia. J Am Coll Surg 2004;198:668-669 doi: 10.1016/jamcollsug.2003.08.027
20. Shanmuganathan K, Killeen K, Mirvis SE, et al. Imaging of Diaphragmatic Injuries. J Thoracic Imaging 2000;15:104-111 doi: 10.1097/00005382-200004000-00005
21. Iochum S, Ludig T, Walter F, et al. Imaging of diaphragmatic injury: a diagnostic challenge? Radiographics 2002;22:103-116 doi: 1148/radiographics.22.suppl_1.g02oc14s103
22. Shanmuganathan K, Mirvis SE. Imaging diagnosis of nonaortic thoracic injury. Radiol Clin North Am1999; 37:533-551 doi: 10.1016/s0033-8389(05)70110-x
23. Trésallet C, Menegaux F, Izzillo R, et al. Usefulness of CT reconstructed pictures for diaphragmatic rupture after blunt trauma. J Am Coll Surg 2004;198:666-667
24. Rees O, Mirvis S.E, Shanmuganagthan K. Multidetector-row CT of right hemidiaphragmatic rupture caused by blunt trauma: a review of 12 cases. Clin Radiol 2005;60:1280-1289 doi:10.1016/j.crad.2005.06.013
25. Brink JA, Heiken JP, Semenkovich J, et al. Abnormalities of the diaphragm and adjacent structures: findings on multiplanar spiral CT scans. Am J Roentgenol 1994;163:307-310 doi:10.2214/ajr.1632.8037020

26. Bergin D, Ennis R, Keogh C, et al. The “dependent viscera” sign in CT diagnosis of blunt traumatic diaphragmatic rupture. Am J Roentgenol 2001;177:1137-1140 doi 10.2214/ajr.177.5.1771137
27. Ivatury RR, Simon RJ, Weksler B, et al. Laparoscopy in the evaluation of the intrathoracic abdomen after penetrating injury. J Trauma 1992;33:101-109 doi 10.1097/00005373-199207000-00019
28. Ivatury RR, Simon RJ, Stahl WM. A critical evaluation of laparoscopy in penetrating abdominal trauma. J Trauma 1993;34:822-828 doi:10.1097/00005373-199306000-00013
29. Freeman T, Fischer RP. The inadequacy of peritoneal lavage in diagnosing acute diaphragmatic rupture. J Trauma 1976;16:538-542 doi:10.1097/00005373-197607000-00004
30. Rodriguez-Morales G, Rodriguez A, Shatney CH. Acute rupture of the diaphragm in blunt trauma: analysis of 60 patients. J Trauma 1986;26:438-444 doi: 10.1097/00005373-198605000-00005
31. Wiencek RG, Wilson RF, Steiger Z. Acute injuries of the diaphragm. An analysis of 165 cases. J Thorac Cardiovasc Surg. 1986;92:989-993 doi: 10.1016/S0022-5223(19)35814-3
32. Chen JC, Wilson SE. Diaphragmatic injuries: recognition and management in sixty-two patients. 1991;Am Surg 57:810-815
33. Beal SL, McKennan M. Blunt diaphragmatic rupture: A morbid injury. Arch Surg 1988;123:828-832 doi:10.1001/archsurg.1988.01400310042007

Figures

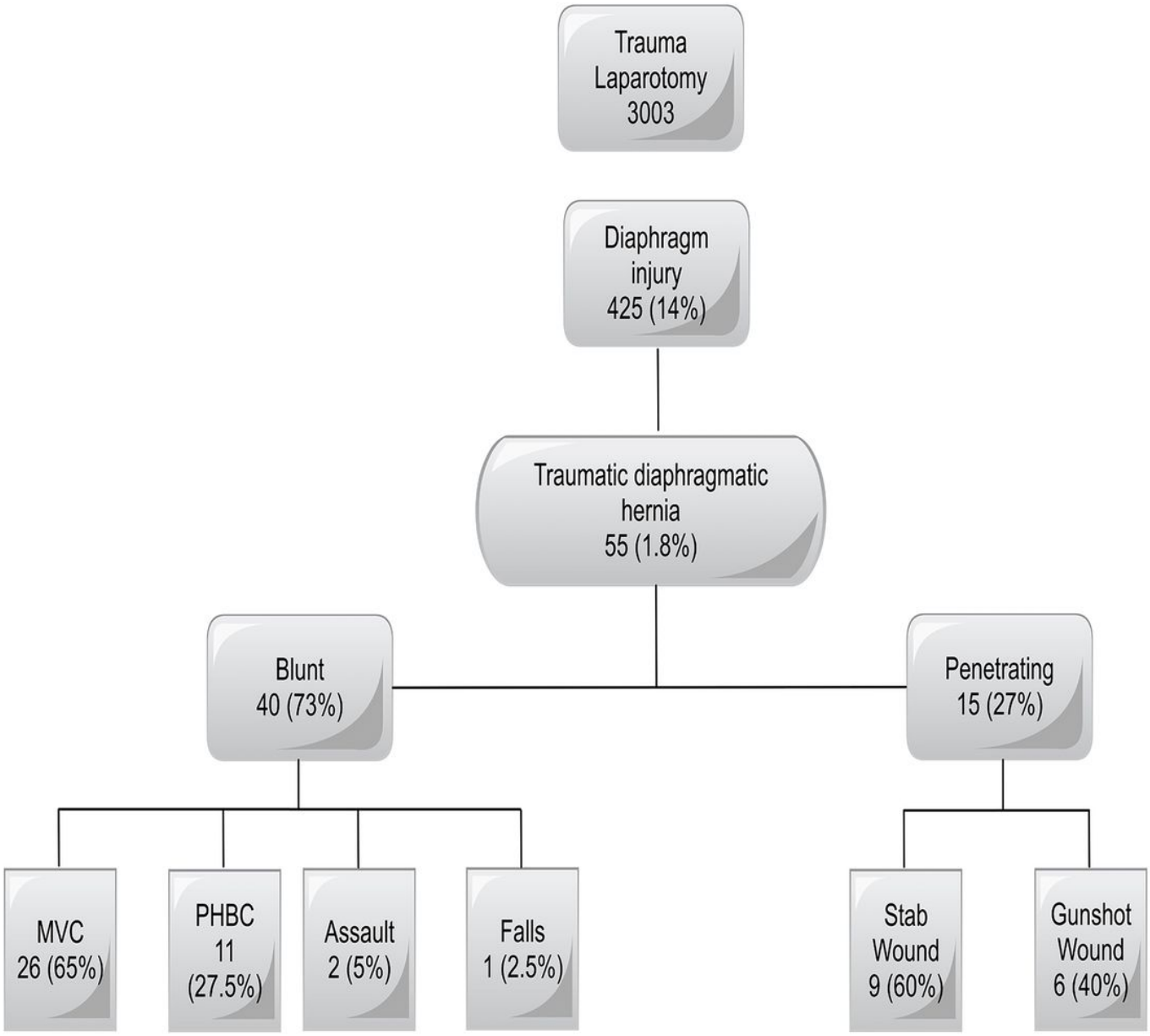

Figure 1

Epidemiology and trauma mechanism flow chart. MVC: motor vehicle collision; PHBC: pedestrian hit by car

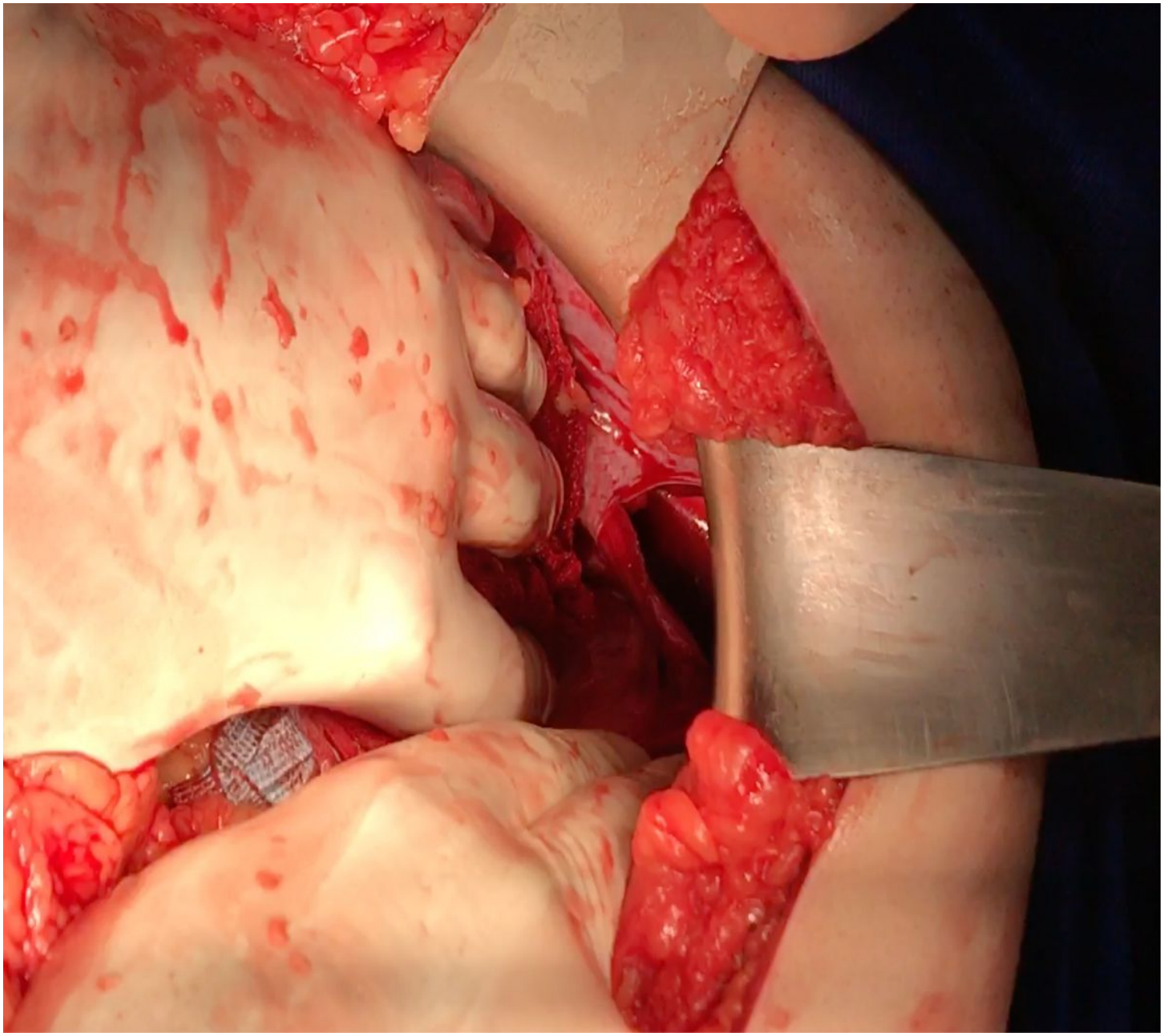

Figure 1

Intraoperative finding of grade IV left diaphragmatic hernia after blunt abdominal trauma

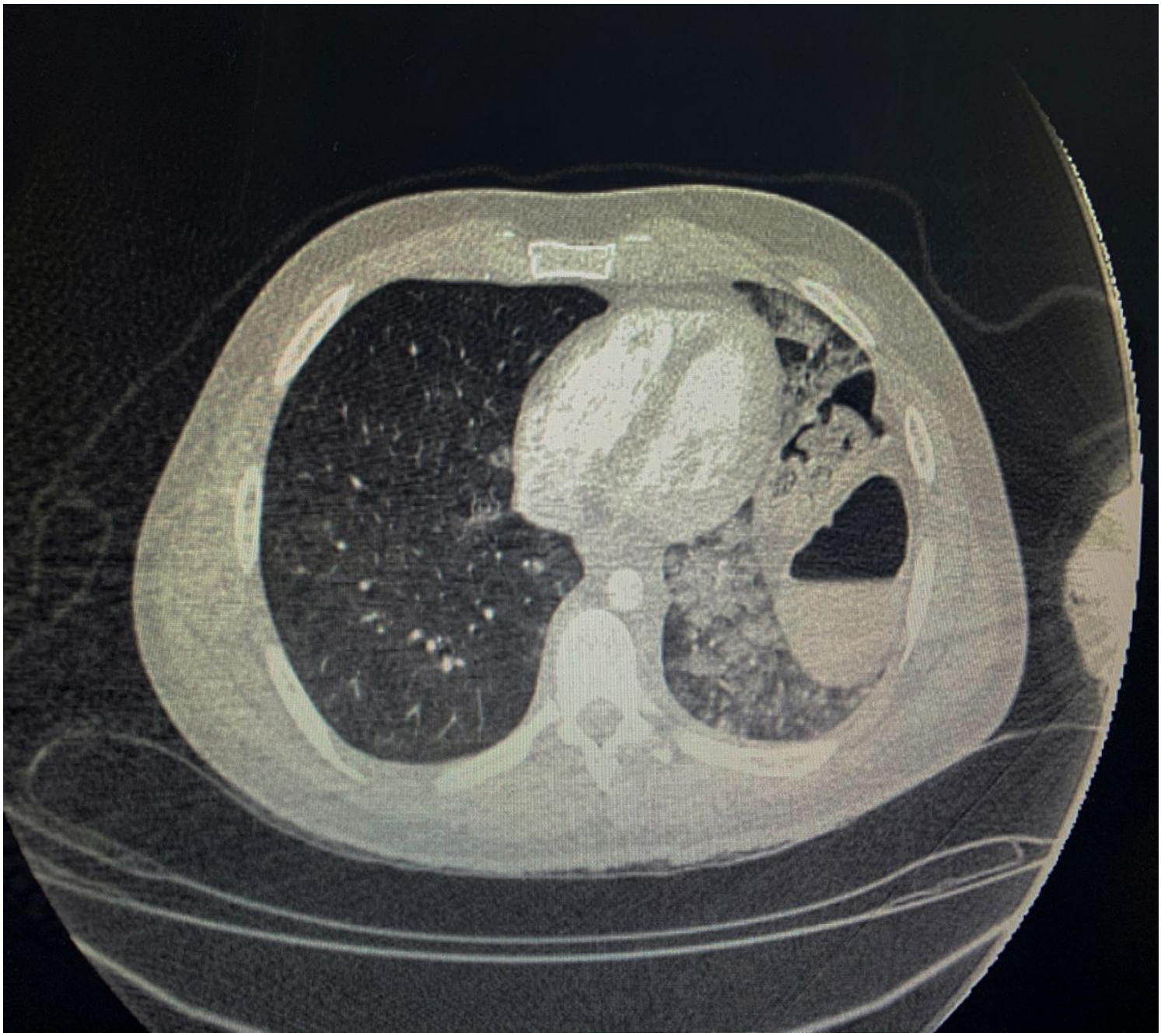

Figure 1

A 21-year-old man who sustained blunt trauma to the torso after MVC. Abdominal CT scan obtained after IV injection of contrast medium shows in axial section herniation of upper part of stomach into the chest. MVC: motor vehicle collision; CT:computed tomography; IV:intravenous

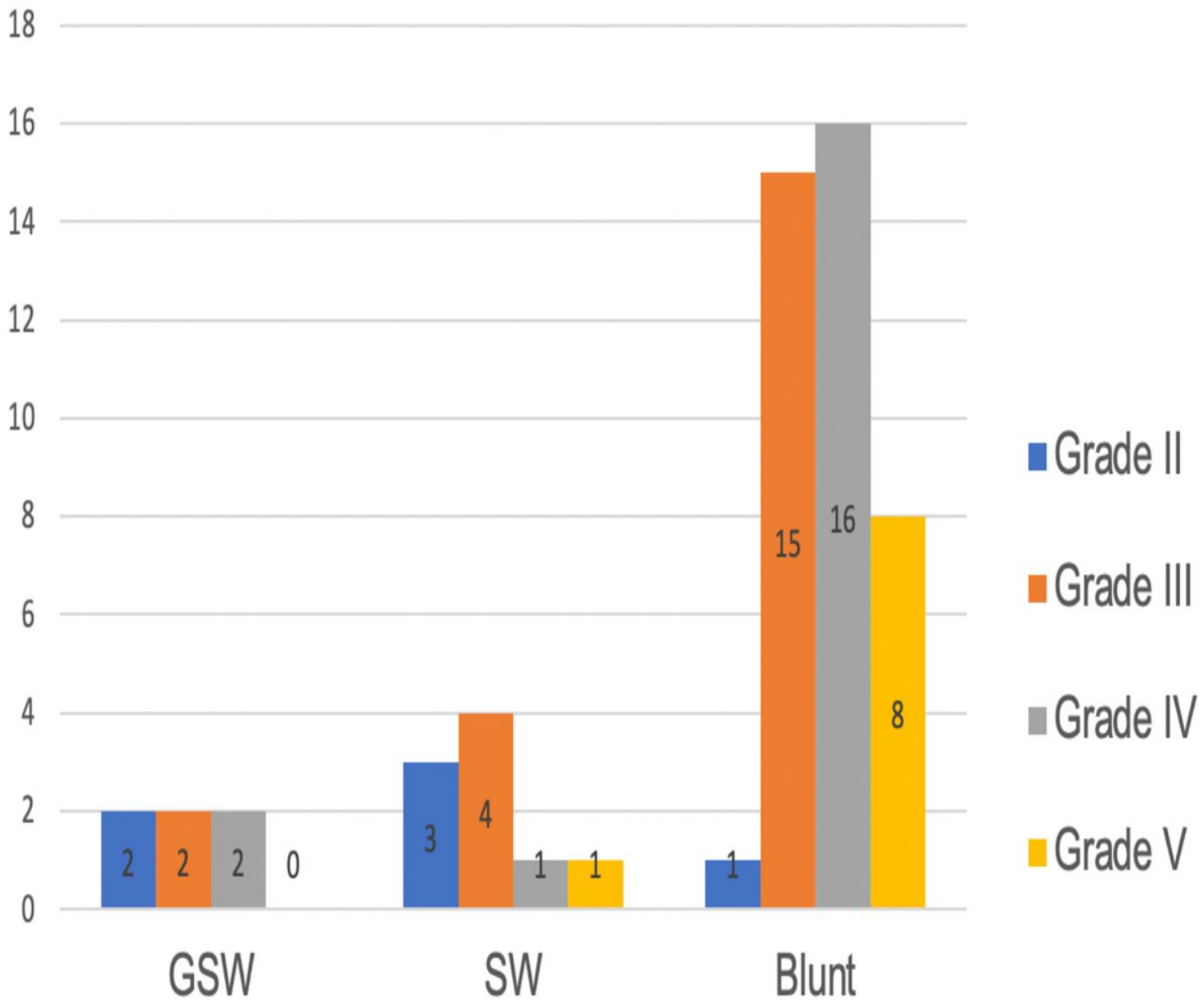

Figure 1

Diaphragmatic grade vs trauma mechanism SW: stab wound; GSW: gunshot wound

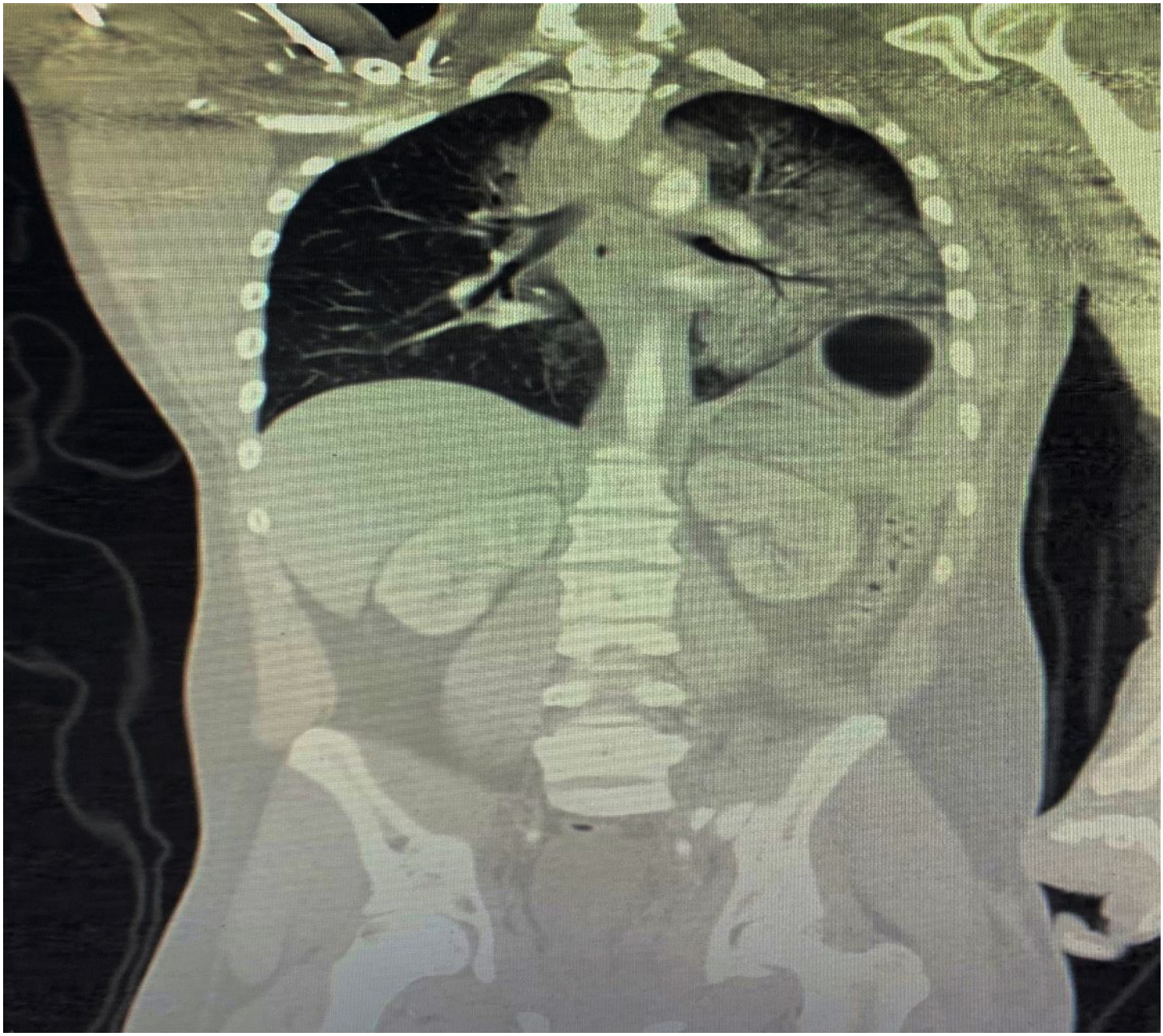

Figure 3

Coronal section: sign of the collar, loss of diaphragmatic contour, and pulmonary contusion.

Supplementary Files

This is a list of supplementary files associated with this preprint. Click to download.

- DATABASE2017TABLE01.xlsx