Risk factors for ellipsoid zone integrity after macula-off rhegmatogenous retinal detachment repair

Wei Fang
The Eye Hospital of Wenzhou Medical University, School of Opthalmology & Optometry, WMU, Zhejiang Eye Hospital https://orcid.org/0000-0002-2471-3932

Miao Chen
Haiyan People's Hospital

Jing Zhai
The Eye Hospital of Wenzhou Medical University

Jiuke Li
Aier Eye Hospital Hangzhou

Yiqi Chen
The Eye Hospital of Wenzhou Medical University

Haidong Li
The Eye Hospital of Wenzhou Medical University

Zhenbin Qian
The Eye Hospital of Wenzhou Medical University

Mengdi Wang
The Eye Hospital of Wenzhou Medical University

Xiaohong Jin (jin_xiaohong@163.com)
Aier Eye Hospital Hangzhou

Yumin Li
Aier Eye Hospital Hangzhou

Research article

Keywords: ellipsoid zone, risk factors, retinal detachment repair

Posted Date: January 22nd, 2020

DOI: https://doi.org/10.21203/rs.2.21554/v1

Abstract

Background: ellipsoid zone (EZ) layer plays a vital role in visual performance of human retina, hereby we try to find some risk factors for EZ integrity after primary macula-off rhegmatogenous retinal detachment (RRD) repair.

Methods: a retrospective cases study. Patients with macula-off RRD undergoing successful primary retinal repair surgery were reviewed and spectral domain optical coherence tomography images of them were analyzed. Comprehensive preoperative, intraoperative and postoperative clinical factors were screened.

Results: A total of 118 patients (118 eyes) were enrolled in this study. The mean age of those patients was 52.16 years old (52.16 ±12.87 years). The follow-up time ranged from 0.1 to 84 months (10.21 ±14.81 months). 54 cases (45.76%) had their EZ fully reconstructed at final visit. The mid-quartile time of EZ reconstruction was 14.0 months (95% CI: 11.3 ~20.0 months). Multivariate proportional haphazard regression test revealed that the independent factors were: silicone oil tamponade (Hazard ratio=0.414, p=0.0400), posterior staphyloma (Hazard ratio=0.141, p=0.0021) and disorganization of retinal inner layer (Hazard ratio=0.167, p=0.0166).

Conclusion: After successful retinal reattachment for macula-off retinal detachment, the mid-quartile time of EZ recovery was about 14 months. The independent risk factors for EZ recovery might include silicone oil tamponade, posterior staphyloma and disorganization of retinal inner layer.

Background

Ellipsoid zone (EZ) is a thin layer of outer retina, the component of which is considered as the mitochondrial complex recently. As we all know the mitochondria serve as the power plant in all animal cells, accordingly the EZ layer plays a key role in visual performance of human retina. When the neural retina detaches from the pigmental epithelium during retinal detachment, the EZ layer is partially or totally destroyed, with poor visual outcome during this pathophysiologic procedure. In the past several years, many studies have revealed that restoration of the integrity of EZ associated strongly with visual outcome after retinal detachment repair [1 2]. However, to our knowledge, there are rare studies carried on the reconstruction process of EZ reconstruction and the predictive factors for this process, especially in macula-off retinal detachment patients so far. So, in this study, we aimed to find out some factors that could to some degree help clinicians to predict the EZ recovery after retinal detachment repair surgery.

Methods

Patients selection

Enrollment criteria: ① primary rhegmatogenous retinal detachment (RRD) undergoing uneventful retinal repair surgery; ② macula detachment confirmed by ultrasonic B scan or spectral domain optical coherence

tomography (SD-OCT) before operation. Exclusion criteria: ▯ recurrent retinal detachment; ▯ traumatic retinal detachment; ▯ chronic retinal detachment, defined as: ▯ no acute history of chief symptoms like vision loss or visual field defect, ▯ chief symptoms lasted more than 3 months and corresponded to the detached retina, ▯ fundus examination revealed detached retina with concentric demarcation lines around retinal hole accompanied by retina thinning or fixed; ▯ diabetes mellitus; ▯ macular hole or other maculopathy; ▯ other intraocular diseases or intraocular surgery that could affect the retinal structure. All the patients were selected between May 2011 and September 2017.

SD-OCT scan protocol and main measurements

SD-OCT image of all patients at final visit was reviewed. A 6mmX6mm image centered on the fovea was captured and the horizontal section passing through the foveal bulge was analyzed (in cases where the foveal bulge was not visible, a horizontal line passing through the steepest part of the foveal excavation was chosen). The disruption of EZ integrity was defined as the cases in which the integrity could not be evaluated because of folding, undulation, edema, and/or the cases in which ELM continuity was disrupted, obviously.

Main factors selected

Preoperative factors included: age, macula-off duration, axis length, intraocular lens (IOL), detached extension, degree of proliferative vitreoretinopathy (PVR), posterior staphyloma, vitreous hemorrhage, choroidal detachment. Intraoperative factors included: surgery time, surgery type, silicone oil (SO) tamponade, perfluorocarbon liquids (PFCL) injection. Postoperative factors included: subretinal fluid, disorganization of retinal inner layer (DRIL). Both previously IOL implantation and simultaneous intraoperative IOL implantation were classified in IOL group. The degree of PVR was classified according to the classification of the Retina Society Terminology Committee in 1983. Viscosity of SO used in this study was 5000 centistokes (Baush & Lomb). Surgery type was grouped as scleral buckling (SB, including extrascleral explant and subretinal fluid drainage) and par plana vitrectomy (PPV, with or without phacoemulsification and IOL implantation). DRIL was defined as derangement of the normal laminar inner retinal structure, when it was not possible for the reader to identify any of the boundaries of the ganglion cell layer, inner plexiform layer, inner nuclear layer, and outer plexiform layer.

Statistical analysis

A survival analysis (K-M method) was used to describe the EZ reconstruction rate after surgery. Fully reconstruction of the EZ layer was considered as the endpoint event. Nonparametric Wilcoxon two-sample test and Chi-square test was used to screen relative factors preliminarily. Cox proportional haphazard regression test was applied to confirm the independent risk factors for the EZ recovery. Significant value threshold was 0.05 during univariate analysis, while entry p value was 0.1 and elimination p value was 0.05 in multivariate analysis. All of those analyses were done by software SAS 9.2 (SAS Institute Inc, Cary, North Carolina, USA).

Results

A total of 118 patients (118 eyes) were enrolled in this study, with 72 males and 46 females, 73 right eyes and 45 left eyes. The mean age of these patients was 52.16 years old (52.16 ±12.87 years). The follow-up time ranged from 0.1 to 84 months (10.21 ±14.81 months). 54 cases (45.76%) had their EZ fully reconstructed at final visit. The mid-quartile time of EZ recovery was 14.0 months, with a 95% confidential interval from 11.3 to 20.0 months (Figure 1).

Univariate analysis screened out the relative factors as follows: age ($Z = -2.8242$, $p = 0.0047$), detached extension ($X^2 = 8.1858$, $p = 0.0383$), PVR ($X^2 = 10.5031$, $p = 0.0052$), IOL ($X^2 = 11.5361$, $p = 0.0007$), posterior staphyloma ($X^2 = 5.5711$, $p = 0.0183$), SO tamponade ($X^2 = 3.9528$, $p = 0.0468$), DRIL ($X^2 = 9.2493$, $p = 0.0024$) (table 1). Multivariate proportional haphazard regression test revealed that the independent risk factors were: SO tamponade (Hazard ratio = 0.414, $X^2 = 4.2158$, $p = 0.0400$), posterior staphyloma (Hazard ratio = 0.141, $X^2 = 9.4682$, $p = 0.0021$) and DRIL (Hazard ratio = 0.167, $X^2 = 5.7407$, $p = 0.0166$) (table 2).

Discussions

In this study, we described the EZ reconstruction process after macula-off retinal detachment surgery. To our knowledge, it has the largest population of cases so far. After retinal detachment, retinal neural cells apoptosis was observed in 24 hours, which peaked by 2 days and dropped to a low level by 7 days [3]. Lewis GP found that the inner and outer retinal could regenerate after retina reattached in animal experiment, and recently Ra E also confirmed in vivo that the photoreceptor outer segment could regenerate using adaptive optics fundus camera [4 5]. However, this microstructure recovery after successful repair is a time-consuming process. According to the survival function curve in our study, the mid-quartile time was about 14 months, which meant that generally about half of the patients would get their EZ zone fully reconstructed about one year after surgery. Moreover, this recovery rate was much faster in the first two years, and dropped to a much lower level after two or three years postoperatively.

SO has been used world widely in complicated vitreoretinopathy, meanwhile many toxic effects on intraocular structures were substantialized, including iris, ciliary body, trabecular meshwork, retina and optic nerve, etc [6 7]. Recently many authors have proved foveal thickness decreasing, EZ disruption, and even choroidal thickness decreasing after SO endotamponade [8–10]. The exact mechanism of SO toxicity is still unknown. Slight to moderate immunologic inflammation of SO microbubble in different area is probably acceptable as proved by Wickham L [11]. Another explanation is that the ions exchange function of the muller cells between retina and vitreous fluid is barred by the SO which constricts the little space between these two interfaces, reported in vitro-experiments [12]. It should be highlighted that postponed SO endotamponade could damage the whole retinal structure, which should be avoided by clinicians.

A posterior staphyloma is an outward protrusion of all layers of the posterior eye, usually occurring in pathological myopia, in which all layers of retina and choroid degenerate irreversibly, from

microvasculature to large vessels in fundus. Yuichiro Tanaka has reported extreme thinning or loss of inner neural retina along the edge of staphyloma [13]. As a result of the whole eyewall atrophy, the regenerative potential of the neuroretina is very limited obviously, so it is very difficult for those cases to aqcuire a satisfied EZ integrity. Meanwhile, in some previous studies the variable of axis length was revealed as a risk factor for visual function recovery or retinal microstructural integrity, but it was not the case in this study, either in univariate ($p = 0.6002$) or multivariate analysis ($p = 0.7774$, not presented). In our point, though posterior staphyloma often accompanies with longer axis, but the damages to retinal structure of them are not parallel. The patient with long axis but without posterior staphyloma could still remain prosperous anatomical outcomes after retina repair, maybe due to less atrophic changes on the fundus structure.

Recently DRIL get its focus in many studies. It was reported that DRIL associated with cystoid macular edema in uveitis, and also correlated with anatomical and functional outcomes of macular epiretinal membrane peeling surgery [14–16]. DRIL is a condition of disarrangement of inner retinal layers, which represent the transmission pathway from photoreceptor to ganglion cells. However, the mechanism of DRIL formation is also unclear. DRIL may be a generic finding of tissue damage in a variety of retinal pathophysiological procedures, including ischemia, vasculopathy, and blunt trauma. In this study, we found a strong correlation between DRIL and EZ integrity, however it could not be further clarified whether DRIL was a causative factor for EZ recovery or both of them just shared a common pathogenesis process, which needed future researches

We presumed before this study that postoperative subretinal fluid might affect EZ recovery, as some other authors proposed. However, in this study subretinal fluid was not significantly correlated with EZ integrity. The relatively rare cases of subretinal fluid in this study might contribute to this discrepancy, as we only confirmed 9 cases (9/118) of subretinal fluid (6 in fully reconstruction group and 3 in the other group) through OCT scan, so even larger population should be planned.

As a retrospective study, though we have a relatively large number of cases in this study, it was still not satisfied to comprehensively confirm the risk factors for EZ integrity after RRD repair. Furthermore, as mentioned above, we cannot confirm the causal relationship of some key factors in this study. So, prospective studies or multicenter studies need to be carried out.

Conclusion

After successful retinal reattachment for macula-off retinal detachment, the mid-quartile time of EZ recovery was about 14 months. The independent risk factors for EZ recovery might include SO tamponade, posterior staphyloma and DRIL.

List Of Abbreviations

EZ Ellipsoid zone

RRD rhegmatogenous retinal detachment

SD-OCT spectral domain optical coherence tomography

IOL intraocular lens

PVR proliferative vitreoretinopathy

SO silicone oil

PFCL perfluorocarbon liquids

DRIL disorganization of retinal inner layer

Declarations

Ethics and consent to participate

The study was approved by the ethics committee of The Eye Hospital of Wenzhou Medical University (2019-220-K-197) and a supplementary material of this approval was uploaded. A written consent document was obtained from each participant.

Consent to publish

Not applicable. We have anonymized all the identifiable information of patients in the text and supplementary data, including name, medical record number, age, etc.

Competing interests

One of our authors (the first author F.W.) is an associate editor of BMC Ophthalmology. The other authors declare that they have no competing interests.

Funding

This research was funded by Wenzhou Municipal Science and Technology Bureau (Y20180730), which supported expenditure on literature search, purchase and labor cost.

Authors' contributions

F.W.: design, conduction of the study; collection and analysis of clinical data; preparation, review and approval of this manuscript.

C.M., Z.J., L.HD., Q.ZB.: clinical data collection and analysis, review and approval of this manuscript

L. JK., L.YM.: essential review and approval of this manuscript.

C.YQ., W.MD: interpretation of OCT data, review and approval of this manuscript.

J. XH.: design of the study, review and approval of this manuscript.

Availability of data and materials

A form of original clinical data without patients' confidential information that supports these findings is uploaded in the supplementary materials.

Acknowledgements

No

Authors' information

Prof. L.YM. is the director of Aier Eye Hospital (Hangzhou), also a well-known specialist majoring vitreoretinopathy and cataract in China. J.XH. and L.JK. are senior attendings at Aier Eye Hospital. C.M. is a resident at Haiyan People's Hospital, who is getting further education at The Eye Hospital of Wenzhou Medical University. F.W., Z.J., C.YQ., L.HD. and Q.ZB. are fellows at The Eye Hospital of Wenzhou Medical University, while W.MD. is a senior resident at this eye hospital. All members of this group have experience in clinical treatment, animal models, cells culture, and genetic maneuvers of vitreoretinopathy.

References

1. Park DH, Choi KS, Sun HJ et al. Factors associated with visual outcome after macula-off rhegmatogenous retinal detachment surgery. Retina. 2018 Jan;38(1):137–147.
2. Kobayashi M, Iwase T, Yamamoto K et al. Association between photoreceptor regeneration and visual acuity following surgery for rhegmatogenous retinal detachment. Invest Ophthalmol Vis Sci. 2016;57:889–898.
3. Cook B, Lewis GP, Fisher SK et al. Apoptotic photoreceptor degeneration in experimental retinal detachment. Invest Ophthalmol Vis Sci 1995;36:990–6
4. Lewis GP, Charteris DG, Sethi CS et al. Animal models of retinal detachment and reattachment: identifying cellular events that may affect visual recovery.Eye 2002;16:375–87
5. Ra E, Ito Y, Kawano K et al. Regeneration of Photoreceptor Outer Segments After Scleral Buckling Surgery for Rhegmatogenous Retinal Detachment.Am J Ophthalmol. 2017 May;177:17–26.
6. Papp A, Kiss EB, Tímár O et al. Long-term exposure of the rabbit eye to silicone oil causes optic nerve atrophy.Brain Res Bull. 2007 Sep 14;74(1–3):130–3.
7. Grzybowski A, Pieczynski J, Ascaso FJ. Neuronal complications of intravitreal silicone oil: an updated review.Acta Ophthalmol. 2014 May;92(3):201–4.
8. Karimi S, Entezari M, Nikkhah H et al. Effects of Intravitreal Silicone Oil on Subfoveal Choroidal Thickness.Ophthalmologica. 2018;239(2–3):159–166.

9. Durrani AK, Rahimy E, Hsu J. Outer Retinal Changes on Spectral-Domain Optical Coherence Tomography Pre- and Post-Silicone Oil Removal.Ophthalmic Surg Lasers Imaging Retina. 2017 Dec 1;48(12):978–982.
10. Lee SH, Han JW, Byeon SH et al. Retinal layer segmentation after silicone oil or gas tamponade for mucula-on retinal detachment using optical coherence tomography. Retina. 2018 Feb;38(2):310–319.
11. Wickham L, Asaria RH, Alexander R et al. Immunopathology of intraocular silicone oil: enucleated eyes.Immunopathology of intraocular silicone oil: enucleated eyes. Br J Ophthalmol. 2007 Feb;91(2):253–7.
12. Winter M, Eberhardt W, Scholz C et al. Failure of potassium siphoning by Müller cells: a new hypothesis of perfluorocarbon liquid-induced retinopathy.Invest Ophthalmol Vis Sci. 2000 Jan;41(1):256–61.
13. Yuichiro Tanaka, Noriaki Shimada, and Kyoko Ohno-Matsui.Extreme. Thinning or Loss of Inner Neural Retina Along the Staphyloma Edge in Eyes With Pathologic Myopia.Am J Ophthalmol. 2015 Apr;159(4):677–82.
14. Grewal DS, O'Sullivan ML, Kron M et al. Association of Disorganization of Retinal Inner Layers With Visual Acuity In Eyes With Uveitic Cystoid Macular Edema.Am J Ophthalmol. 2017 May;177:116–125.
15. Das R, Spence G, Hogg RE et al. Disorganization of Inner Retina and Outer Retinal Morphology in Diabetic Macular Edema. JAMA Ophthalmol. 2018 Feb 1;136(2):202–208.
16. Dinah Zur, Matias Iglicki, Lital Feldinger et al. Disorganization of Retinal Inner Layers as a Biomarker for Idiopathic Epiretinal Membrane After Macular Surgery—The DREAM Study.Am J Ophthalmol. 2018 Dec;196:129–135.

Tables

Table 1. Relative factors for EZ reconstruction from univariate analysis

Variables	Without fully reconstruction	With fully reconstruction		
	Mean±SD/ Numbers	Mean±SD/ Numbers	X^2/Z	p
Age (yrs)	54.93 ±13.01	48.87 ±12.01	-2.8242	0.0047
Macula-off duration (m)	0.63 ±0.62	0.51 ±0.40	-0.8412	0.4003
Axis length (mm)	25.84 ±2.78	25.35 ±1.99	-0.5241	0.6002
Surgery time (min)	73.89 ±23.63	66.67 ±20.28	-1.6711	0.0947
Detached extension			8.1858	0.0383
1	1	4		
2	21	18		
3	13	26		
4	19	6		
PVR			10.5031	0.0052
B	40	43		
C	13	11		
D	11	0		
IOL			11.5361	0.0007
Yes	39	16		
No	25	38		
Staphyloma			5.5711	0.0183
Yes	15	4		
No	49	50		
Vitreous hemorrhage			0.0601	0.8064
Yes	13	10		
No	51	44		
Choroidal detachment			0.2037	0.6518
Yes	14	10		
No	50	44		
Surgery type			0.3764	0.7303
SB	4	5		
PPV	60	49		
SO tamponade			3.9528	0.0468
Yes	39	23		
No	25	31		

PFCL			1.3962	0.3734
Yes	4	1		
No	60	53		
Subretinal fluid			1.7153	0.2976
Yes	3	6		
No	61	48		
DRIL			9.2493	0.0024
Yes	15	2		
No	49	52		

PVR=proliferative vitreoretinopathy, IOL=intraocular lens, SO=silicone oil, PFCL=Perfluorocarbon liquids, DRIL=disorganization of retinal inner layer. Threshold *p* value was 0.05.

Table 2. Multivariate analysis for the risk factors from Cox proportional hazard regression test

Variables	Hazard ratio	95% CI	χ^2	*p*
Age	0.981	0.949~0.949	1.1977	0.2378
Surgery time	0.990	0.971~1.010	0.9364	0.3332
Detached extension	1.256	0.756~2.089	0.7735	0.3791
PVR	0.630	0.324~1.225	1.8531	0.1734
IOL	2.492	0.936~6.636	3.3385	0.0677
Staphyloma	0.141	0.041~0.491	9.4682	0.0021
SO tamponade	0.414	0.178~0.961	4.2158	0.0400
DRIL	0.167	0.039~0.722	5.7407	0.0166

PVR=proliferative vitreoretinopathy, IOL=intraocular lens, SO=silicone oil, PFCL=Perfluorocarbon liquids, DRIL=disorganization of retinal inner layer. Entry p value was 0.1 and elimination p value was 0.05

Figures

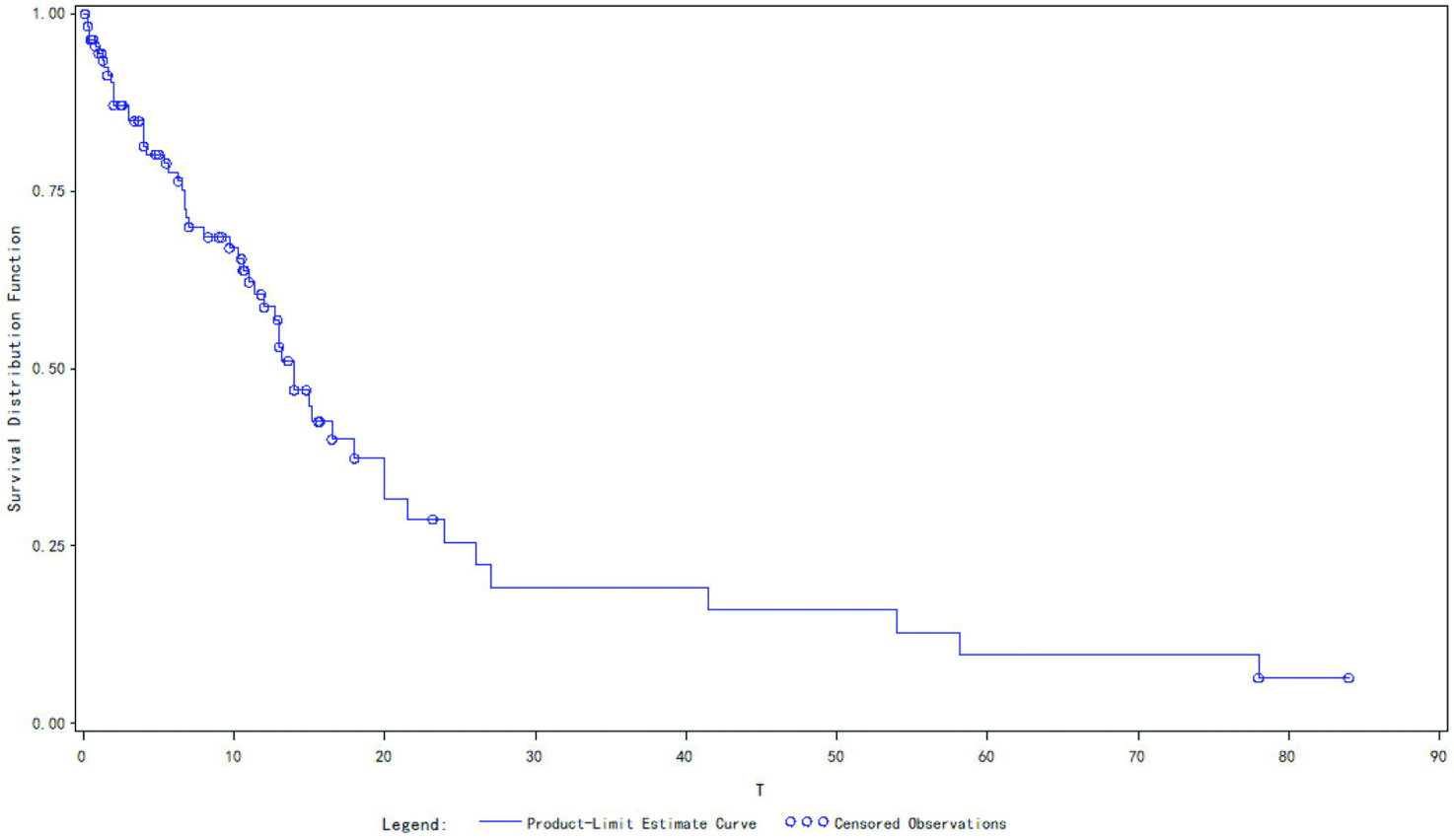

Figure 1

Survival analysis of EZ integrity K-M method Fully reconstruction of the EZ layer was considered as the endpoint event. In the 118 patients, 54 cases (45.76%) had their EZ fully reconstructed at final visit. The mid-quartile time of EZ recovery was 14.0 months, with a 95% confidential interval from 11.3 to 20.0 months. This recovery rate was much faster in the first two years, and dropped to a much lower level after two or three years postoperatively.

Supplementary Files

This is a list of supplementary files associated with this preprint. Click to download.

- supplementarymaterialoriginaldataR2.xlsx